

World Journal of *Clinical Cases*

World J Clin Cases 2021 May 26; 9(15): 3487-3795



OPINION REVIEW

- 3487 COVID-19 combined with liver injury: Current challenges and management
Deng ML, Chen YJ, Yang ML, Liu YW, Chen H, Tang XQ, Yang XF

MINIREVIEWS

- 3498 Cholesterol gallstones: Focusing on the role of interstitial Cajal-like cells
Fu BB, Zhao JN, Wu SD, Fan Y
- 3506 Association of hidradenitis suppurativa with Crohn's disease
Zhang M, Chen QD, Xu HX, Xu YM, Chen HJ, Yang BL
- 3517 Surgical treatment of hepatocellular carcinoma in the era of COVID-19 pandemic: A comprehensive review of current recommendations
Fancellu A, Sanna V, Scognamiglio F, Feo CF, Vidili G, Nigri G, Porcu A

ORIGINAL ARTICLE

Retrospective Cohort Study

- 3531 Critical prognostic value of the log odds of negative lymph nodes/tumor size in rectal cancer patients
Xie JB, Pang YS, Li X, Wu XT
- 3546 Effectiveness of adjunctive corticosteroid therapy in patients with severe COVID-19: A retrospective cohort study
Xiong B, He LM, Qin YY, Du H, Zhan Z, Zhou YH, Chen YK, Zhang A

Retrospective Study

- 3559 Multifactor study of efficacy and recurrence in laparoscopic surgery for inguinal hernia
Chen WL, Deng QQ, Xu W, Luo M
- 3567 Ultrasound-guided, direct suprainguinal injection for fascia iliaca block for total hip arthroplasty: A retrospective study
Wang YL, Liu YQ, Ni H, Zhang XL, Ding L, Tong F, Chen HY, Zhang XH, Kong MJ
- 3576 Changes in endoscopic patterns before and during COVID-19 outbreak: Experience at a single tertiary center in Korean
Kim KH, Kim SB, Kim TN

Observational Study

- 3586 Cleansing efficacy and safety of bowel preparation protocol using sodium picosulfate/magnesium citrate considering subjective experiences: An observational study
Liu FX, Wang L, Yan WJ, Zou LC, Cao YA, Lin XC

- 3597** Clinically significant endoscopic findings in patients of dyspepsia with no warning symptoms: A cross-sectional study

Mao LQ, Wang SS, Zhou YL, Chen L, Yu LM, Li M, Lv B

META-ANALYSIS

- 3607** Effect of antifoaming agent on benign colorectal tumors in colonoscopy: A meta-analysis

Zhang H, Gong J, Ma LS, Jiang T, Zhang H

CASE REPORT

- 3623** Subchondral bone as a novel target for regenerative therapy of osteochondritis dissecans: A case report

Zhang SY, Xu HH, Xiao MM, Zhang JJ, Mao Q, He BJ, Tong PJ

- 3631** Progressive familial intrahepatic cholestasis — farnesoid X receptor deficiency due to *NR1H4* mutation: A case report

Czubkowski P, Thompson RJ, Jankowska I, Knisely AS, Finegold M, Parsons P, Cielecka-Kuszyk J, Strautnieks S, Pawłowska J, Bull LN

- 3637** Postoperative pain due to an occult spinal infection: A case report

Kerckhove MFV, Fiere V, Vieira TD, Bahroun S, Szadkowski M, d'Astorg H

- 3644** Combined cesarean delivery and repair of acute aortic dissection at 34 weeks of pregnancy during COVID-19 outbreak: A case report

Liu LW, Luo L, Li L, Li Y, Jin M, Zhu JM

- 3649** Brucellosis of unknown origin with haemophagocytic syndrome: A case report

Tian LH, Dong ZG, Chen XY, Huang LJ, Xiao PP

- 3655** Recalcitrant paradoxical pustular psoriasis induced by infliximab: Two case reports

Xia P, Li YH, Liu Z, Zhang X, Jiang Q, Zhou XY, Su W

- 3662** Needle tract seeding of papillary thyroid carcinoma after fine-needle capillary biopsy: A case report

Shi LH, Zhou L, Lei YJ, Xia L, Xie L

- 3668** Metachronous pulmonary and pancreatic metastases arising from sigmoid colon cancer: A case report

Yang J, Tang YC, Yin N, Liu W, Cao ZF, Li X, Zou X, Zhang ZX, Zhou J

- 3675** Infiltrating ductal breast carcinoma with monoclonal gammopathy of undetermined significance: A case report

Ma Y, Cui S, Yin YJ

- 3680** Roxadustat as treatment for a blood transfusion-dependent maintenance hemodialysis patient: A case report and review of literature

Fei M, Wen XQ, Yu ZL, Kang T, Wu WH, Ou ST

- 3689** Small bowel ulcer bleeding due to suspected clopidogrel use in a patient with clopidogrel resistance: A case report

Lee SH, Ryu DR, Lee SJ, Park SC, Cho BR, Lee SK, Choi SJ, Cho HS

- 3696** Recurrent abdominal pain due to small bowel volvulus after transabdominal preperitoneal hernioplasty: A case report and review of literature
Man Y, Li BS, Zhang X, Huang H, Wang YL
- 3704** Malignant giant cell tumor in the left upper arm soft tissue of an adolescent: A case report
Huang WP, Zhu LN, Li R, Li LM, Gao JB
- 3711** Anesthetic management of bilateral pheochromocytoma resection in Von Hippel-Lindau syndrome: A case report
Wang L, Feng Y, Jiang LY
- 3716** Sarcomatoid carcinoma of the pancreas — a rare tumor with an uncommon presentation and course: A case report and review of literature
Toledo PF, Berger Z, Carreño L, Cardenas G, Castillo J, Orellana O
- 3726** Fulminant amebic colitis in a patient with concomitant cytomegalovirus infection after systemic steroid therapy: A case report
Shijubou N, Sumi T, Kamada K, Sawai T, Yamada Y, Ikeda T, Nakata H, Mori Y, Chiba H
- 3733** Maisonneuve injury with no fibula fracture: A case report
Liu GP, Li JG, Gong X, Li JM
- 3741** Alopecia treatment using minimally manipulated human umbilical cord-derived mesenchymal stem cells: Three case reports and review of literature
Ahn H, Lee SY, Jung WJ, Lee KH
- 3752** Pheochromocytoma in a 49-year-old woman presenting with acute myocardial infarction: A case report
Wu HY, Cao YW, Gao TJ, Fu JL, Liang L
- 3758** Lymphangiomatosis associated with protein losing enteropathy: A case report
Ding XL, Yin XY, Yu YN, Chen YQ, Fu WW, Liu H
- 3765** *De novo* multiple primary carcinomas in a patient after liver transplantation: A case report
Rao W, Liu FG, Jiang YP, Xie M
- 3773** Contralateral hemopneumothorax after penetrating thoracic trauma: A case report
İşcan M
- 3779** Bilateral posterior scleritis presenting as acute primary angle closure: A case report
Wen C, Duan H
- 3787** Bilateral cerebral infarction in diabetic ketoacidosis and bilateral internal carotid artery occlusion: A case report and review of literature
Chen YC, Tsai SJ

ABOUT COVER

Editorial Board Member of *World Journal of Clinical Cases*, Wei Wang, MD, PhD, Associate Professor, Key Laboratory on Technology for Parasitic Disease Prevention and Control, Jiangsu Institute of Parasitic Diseases, Wuxi 214064, Jiangsu Province, China. wangwei@jipd.com

AIMS AND SCOPE

The primary aim of *World Journal of Clinical Cases* (WJCC, *World J Clin Cases*) is to provide scholars and readers from various fields of clinical medicine with a platform to publish high-quality clinical research articles and communicate their research findings online.

WJCC mainly publishes articles reporting research results and findings obtained in the field of clinical medicine and covering a wide range of topics, including case control studies, retrospective cohort studies, retrospective studies, clinical trials studies, observational studies, prospective studies, randomized controlled trials, randomized clinical trials, systematic reviews, meta-analysis, and case reports.

INDEXING/ABSTRACTING

The WJCC is now indexed in Science Citation Index Expanded (also known as SciSearch®), Journal Citation Reports/Science Edition, Scopus, PubMed, and PubMed Central. The 2020 Edition of Journal Citation Reports® cites the 2019 impact factor (IF) for WJCC as 1.013; IF without journal self cites: 0.991; Ranking: 120 among 165 journals in medicine, general and internal; and Quartile category: Q3. The WJCC's CiteScore for 2019 is 0.3 and Scopus CiteScore rank 2019: General Medicine is 394/529.

RESPONSIBLE EDITORS FOR THIS ISSUE

Production Editor: Ji-Hong Lin; Production Department Director: Xiang Li; Editorial Office Director: Jin-Lai Wang.

NAME OF JOURNAL

World Journal of Clinical Cases

ISSN

ISSN 2307-8960 (online)

LAUNCH DATE

April 16, 2013

FREQUENCY

Thrice Monthly

EDITORS-IN-CHIEF

Dennis A Bloomfield, Sandro Vento, Bao-Gan Peng

EDITORIAL BOARD MEMBERS

<https://www.wjgnet.com/2307-8960/editorialboard.htm>

PUBLICATION DATE

May 26, 2021

COPYRIGHT

© 2021 Baishideng Publishing Group Inc

INSTRUCTIONS TO AUTHORS

<https://www.wjgnet.com/bpg/gerinfo/204>

GUIDELINES FOR ETHICS DOCUMENTS

<https://www.wjgnet.com/bpg/GerInfo/287>

GUIDELINES FOR NON-NATIVE SPEAKERS OF ENGLISH

<https://www.wjgnet.com/bpg/gerinfo/240>

PUBLICATION ETHICS

<https://www.wjgnet.com/bpg/GerInfo/288>

PUBLICATION MISCONDUCT

<https://www.wjgnet.com/bpg/gerinfo/208>

ARTICLE PROCESSING CHARGE

<https://www.wjgnet.com/bpg/gerinfo/242>

STEPS FOR SUBMITTING MANUSCRIPTS

<https://www.wjgnet.com/bpg/GerInfo/239>

ONLINE SUBMISSION

<https://www.f6publishing.com>

Maisonneuve injury with no fibula fracture: A case report

Guang-Ping Liu, Ji-Gang Li, Xiao Gong, Jian-Min Li

ORCID number: Guang-Ping Liu 0000-0002-4363-8368; Ji-Gang Li 0000-0002-3659-4184; Xiao Gong 0000-0003-1302-7336; Jian-Min Li 0000-0001-9789-9232.

Author contributions: Liu GP was the patient's surgeon, reviewed the literature, and contributed to manuscript drafting; Li JG reviewed the literature and drafted the manuscript; Gong X analyzed and interpreted the imaging findings; Li JM was responsible for the revision of the manuscript for important intellectual content; all authors issued final approval for the version to be submitted.

Informed consent statement: Informed written consent was obtained from the patient for publication of this report and any accompanying images.

Conflict-of-interest statement: The authors declare that they have no conflict of interest to report.

CARE Checklist (2016) statement: The authors have read the CARE Checklist (2016), and the manuscript was prepared and revised according to the CARE Checklist (2016).

Open-Access: This article is an open-access article that was selected by an in-house editor and fully peer-reviewed by external reviewers. It is distributed in accordance with the Creative

Guang-Ping Liu, Jian-Min Li, Department of Orthopedics, Qilu Hospital, Cheeloo College of Medicine, Shandong University, Jinan 250012, Shandong Province, China

Guang-Ping Liu, Ji-Gang Li, Department of Orthopedics, Zibo Central Hospital, Shandong University, Zibo 255000, Shandong Province, China

Xiao Gong, Department of Radiology, Zibo Central Hospital, Shandong University, Zibo 255000, Shandong Province, China

Corresponding author: Jian-Min Li, MD, Chief Doctor, Professor, Surgeon, Department of Orthopedics, Qilu Hospital, Cheeloo College of Medicine, Shandong University, No. 107 Culture Road, Jinan 250012, Shandong Province, China. gkljm@163.com

Abstract

BACKGROUND

Ankle syndesmosis injury is difficult to diagnose accurately at the initial visit. Missed diagnosis or improper treatment can lead to chronic complications. Complete syndesmosis injury with a concomitant rupture of the interosseous membrane (IOM) is more unstable and severe. The relationship between this type of injury and Maisonneuve injury, in which the syndesmosis is also injured, has not been discussed in the literature previously.

CASE SUMMARY

A 16-year-old patient sustained left medial malleolar fracture, and the associated inferior tibiofibular syndesmotom instability was overlooked. After open reduction and internal fixation of the medial malleolar fracture, inferior tibiofibular syndesmosis diastasis with IOM rupture was detected by auxiliary imaging. Secondary surgical intervention was performed to reduce anatomically and fix with two trans-syndesmosis screws. Twelve weeks later, the screws were removed. At the 6-mo follow-up, the patient gained full range of motion of the ankle.

CONCLUSION

Complete syndesmosis injury with IOM rupture should be considered Maisonneuve-type injury. Open reduction and internal fixation could obtain good outcomes.

Key Words: Maisonneuve; Syndesmosis injury; Interosseous membrane; Stress test; Classification; Case report

Commons Attribution
NonCommercial (CC BY-NC 4.0)
license, which permits others to
distribute, remix, adapt, build
upon this work non-commercially,
and license their derivative works
on different terms, provided the
original work is properly cited and
the use is non-commercial. See: <http://creativecommons.org/licenses/by-nc/4.0/>

Manuscript source: Unsolicited
manuscript

Specialty type: Medicine, research
and experimental

Country/Territory of origin: China

**Peer-review report's scientific
quality classification**

Grade A (Excellent): 0
Grade B (Very good): 0
Grade C (Good): 0
Grade D (Fair): 0
Grade E (Poor): 0

Received: January 6, 2021

Peer-review started: January 6,
2021

First decision: January 24, 2021

Revised: January 30, 2021

Accepted: March 3, 2021

Article in press: March 3, 2021

Published online: May 26, 2021

P-Reviewer: Santiago F

S-Editor: Gao CC

L-Editor: Wang TQ

P-Editor: Wu YXJ



©The Author(s) 2021. Published by Baishideng Publishing Group Inc. All rights reserved.

Core Tip: We present a case of medial malleolar fracture, and the associated complete syndesmosis injury with interosseous membrane rupture was overlooked, which teaches us to pay more attention to thorough physical examination and exact reading of auxiliary imaging and intraoperative stress fluoroscopy to avoid misdiagnosis. Furthermore, this is the first report describing this pattern of injury as a Maisonneuve-equivalent injury and further classifying Maisonneuve injury into three types.

Citation: Liu GP, Li JG, Gong X, Li JM. Maisonneuve injury with no fibula fracture: A case report. *World J Clin Cases* 2021; 9(15): 3733-3740

URL: <https://www.wjgnet.com/2307-8960/full/v9/i15/3733.htm>

DOI: <https://dx.doi.org/10.12998/wjcc.v9.i15.3733>

INTRODUCTION

Maisonneuve injury was first named after the French surgeon Maisonneuve[1] in 1840. The typical pattern of this injury is characterized by a fracture of the proximal fibula, a lesion of the inferior tibiofibular syndesmotic complex, and other possible injuries (rupture of the deltoid ligament, fracture of the medial malleolus, and avulsion fracture of the syndesmotic ligaments). Maisonneuve injury accounts for up to 7% of all ankle fractures, with approximately 5% of ankle fractures treated surgically[2,3].

Tibiofibular syndesmosis is essential for ankle stability. The incidence of syndesmosis injury accounts for 5% to 18% of ankle sprains[4]. Due to diagnostic difficulties, the injury is misidentified and, hence, poorly managed in 20% of cases[5]. Missed diagnosis or improper treatment can lead to chronic complications, especially in complete syndesmosis injury. We present a case of misdiagnosed complete syndesmosis injury involving interosseous membrane (IOM) rupture associated with medial malleolar fracture. This case report emphasizes the importance of thorough physical examination and exact reading of auxiliary imaging to detect latent syndesmosis instability. To our knowledge, this is the first time that this pattern injury was classified as a Maisonneuve-equivalent injury and further classification of Maisonneuve injury was made.

CASE PRESENTATION

Chief complaints

A healthy 16-year-old male student presented to the emergency department of our hospital due to left ankle trauma consequent to a car accident, complaining of severe pain and swelling on his left ankle.

History of past illness

The patient's past medical history was unremarkable.

Personal and family history

The patient's personal and family history contained nothing of note. There was no family history of related inherent diseases.

Physical examination

Physical examination revealed a closed ankle injury with swelling, ecchymoses over the medial aspect, and tenderness around the ankle. There was no tenderness or crack at the proximal fibula. There was no neurological deficit. Dorsalis pedis and tibialis posterior artery pulses were palpable.

Laboratory examinations

Laboratory evaluation, including complete blood count, blood biochemistry, and coagulation function, revealed no significant abnormalities.

Imaging examinations

The left ankle radiographs of anteroposterior (AP) and lateral views, which were performed at another hospital, showed only medial malleolar fracture (Figure 1), which was also revealed in a computed tomography (CT) scan. Postoperatively, radiograph of AP view showed syndesmosis injury (Figure 2), and calf magnetic resonance imaging (MRI) revealed an IOM rupture, surrounded by areas of high signal intensity representing hemorrhage and edema (Figure 3).

FINAL DIAGNOSIS

The final diagnosis was complete syndesmosis injury with IOM rupture and medial malleolar fracture of the left ankle.

TREATMENT

In the emergency department, radiographs of the proximal fibula were not performed because the patient reported no pain in the proximal fibula. In addition, physical examination also showed no tenderness or cracks at the proximal fibula. The injured limb was immobilized in a posterior short leg plaster, and then the patient was admitted to the orthopedic trauma ward and underwent CT scans to better identify the injury details. Except for a fractured medial malleolus, preoperative CT scans revealed no inferior tibiofibular diastasis according to Bartoníček *et al*[6]'s evaluation method (Figure 4A) and Gifford and Lutz[7] tibiofibular line (Figure 4B).

The patient underwent open reduction and internal fixation of the left medial malleolar fracture on the second day after injury. In the supine position, the surgical procedure was managed under epidural anesthesia and thigh tourniquet control. The fracture fragment was explored through an anteromedial approach. After hematoma drainage and interposed soft tissue removal, the fracture was reduced anatomically and fixed with two partially threaded cannulated screws. Intraoperative fluoroscopy indicated anatomic reduction of the medial malleolus with no widened tibiofibular clear space (TFCS) and medial clear space (MCS). However, the preoperative diagnosis was suspected and denied because postoperative radiograph of AP view showed enlarged TFCS and MCS (Figure 2). Immediately, radiographs of the proximal fibula were performed to rule out no fractures, but calf MRI revealed IOM rupture, surrounded by areas of high signal intensity representing hemorrhage and edema (Figure 3). As a windfall gain surprised us, a retrospective review of preoperative axial CT scans in the soft tissue window demonstrated that the IOM was torn from the fibular interosseous crest corresponding to the MRI findings (Figure 5A). The extent of IOM complete rupture was approximately 47.5 mm (1.25 mm/slice × 38 slices) above the talar dome. Furthermore, two minor bone fragments that could not be captured at all in the bone window were detected near the anterior tubercle and posterior tubercle of the distal tibia (a type of mini-Chaput fracture and mini-Volkman fracture) (Figure 5B and C), which indicated avulsion fracture of the anterior inferior tibiofibular ligament (AITFL) and posterior inferior tibiofibular ligament (PITFL), respectively. In short, the inferior tibiofibular syndesmosis was completely injured and reduced spontaneously after the accident (Figure 5).

After consent was obtained from the patient and his family, secondary surgical intervention was conducted in the supine position and under epidural anesthesia on the second day post operation. An anterior incision was made to explore the inferior tibiofibular syndesmosis under direct visualization. Complete syndesmotom diastasis with the AITFL interposition was confirmed. The diastasis was reduced anatomically and maintained using two 3.5-mm fully threaded cortical screws oriented 30° from posterior to anterior with the ankle dorsiflexed (Figure 6). Rupture of the AITFL was treated by means of figure-eight suture reconstruction. Intraoperative stress fluoroscopy was performed to verify the syndesmotom stability with an external rotation test and valgus test. Postoperatively, the ankle was immobilized in a U-shaped plaster for 2 wk, and then active and passive mobilization of the ankle was started.

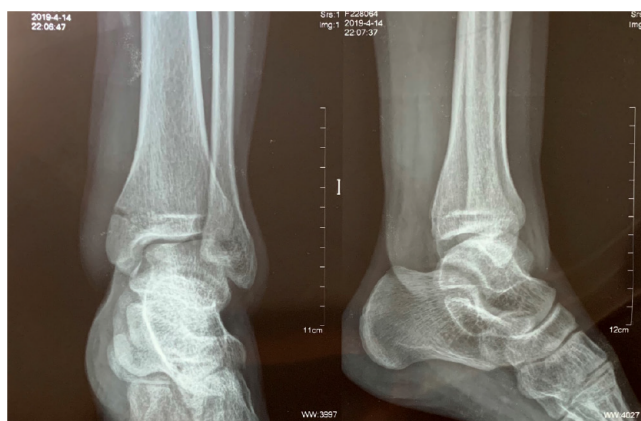

Figure 1 Left ankle radiographs (from another hospital) of anteroposterior and lateral views showing medial malleolar fracture.

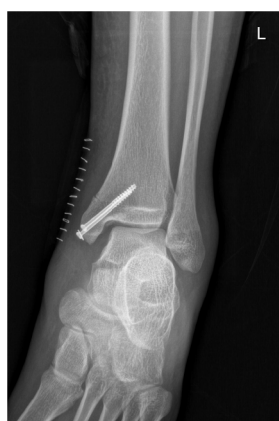

Figure 2 Postoperative radiograph showing the enlarged tibiofibular clear space and medial clear space.

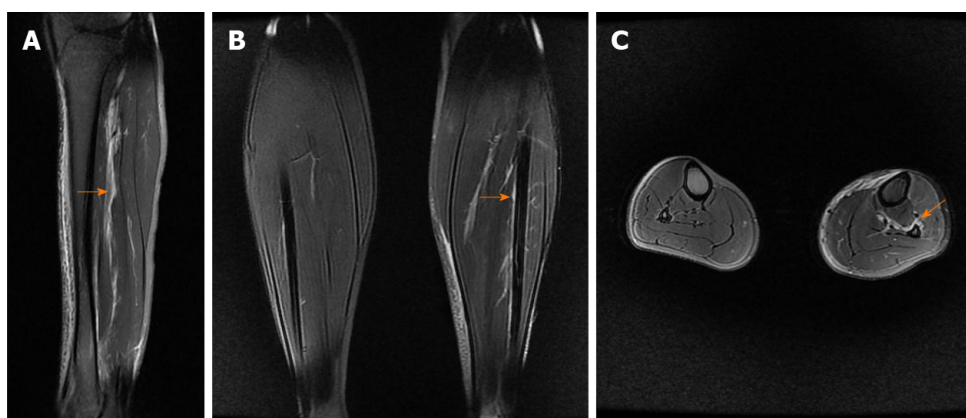


Figure 3 Calf magnetic resonance imaging. A: Sagittal magnetic resonance imaging (MRI) showing high-signal intensity (orange arrow) indicating injury of the interosseous membrane (IOM); B: Coronal MRI showing IOM injury (orange arrow) compared with the contralateral uninjured calf; C: Axial MRI showing IOM rupture (orange arrow) compared with the contralateral uninjured calf, torn from the fibular interosseous crest.

OUTCOME AND FOLLOW-UP

Before the syndesmotic screws were removed, the patient completed non-weight-bearing exercise for 10 wk, and then initiated weight bearing progressively. At the 6-mo postoperative visit, the patient gained full range of motion of the ankle and was restored to the preinjury activity level. The partially threaded cannulated screws were removed 12 mo postoperatively.

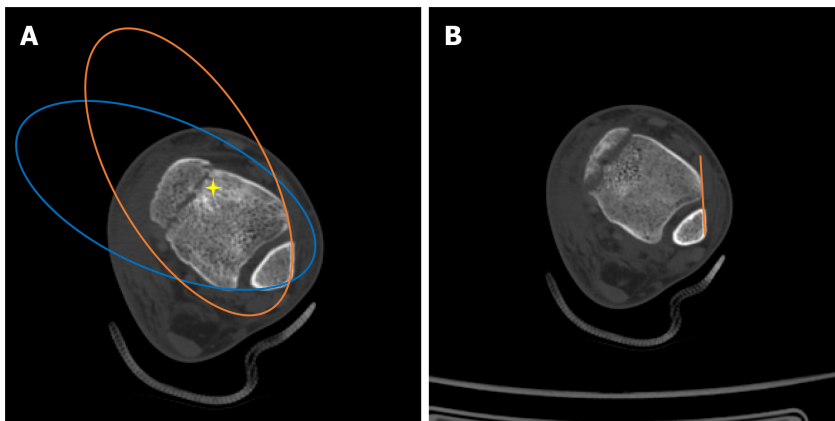


Figure 4 Assessment of inferior tibiofibular syndesmosis in computed tomography scans. A: Bartoniček *et al*[6]'s evaluation method: The anterior aspect of the distal fibula and tibia was continuous, similar to the posterior aspect, "star" area of higher density of the subchondral cancellous bone; B: The distance between the Tillaux-Chaput tubercle and Gifford and Lutz[7]'s tibiofibular line did not exceed 2 mm at the level of 10 mm superior to the tibial plafond.

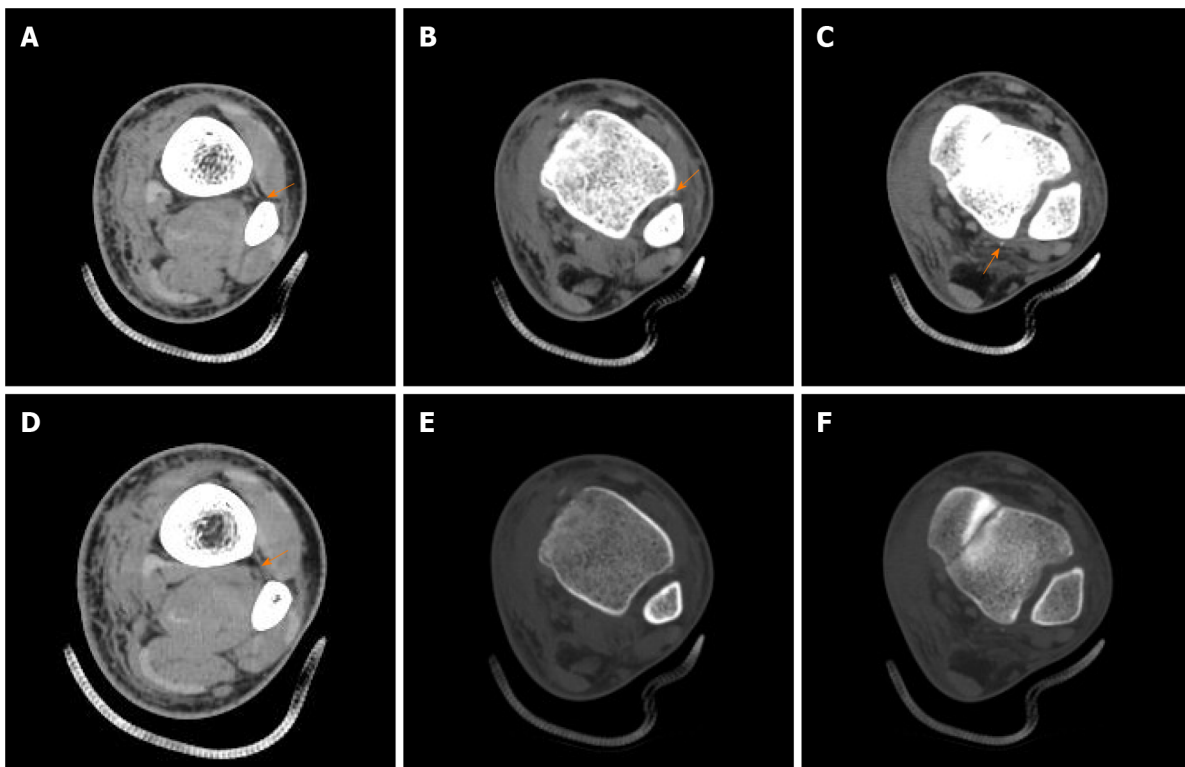


Figure 5 Computed tomography scans indicating complete injury of inferior tibiofibular syndesmosis. A: Rupture of the interosseous membrane (IOM) torn from fibular interosseous crest; B: Avulsion fracture of the anterior inferior tibiofibular ligament (AITFL) in the soft tissue window of computed tomography (CT) scan; C: Avulsion fracture of the posterior inferior tibiofibular ligament (PITFL) in the soft tissue window of CT scan; D: The intact IOM at the proximal part of the calf; E: Avulsion fracture of the AITFL was hardly caught in the bone window of the CT scan (the same B plane); F: Avulsion fracture of the PITFL was hardly caught in the bone window of the CT scan (the same C plane).

DISCUSSION

Syndesmosis injury may occur in isolation or be accompanied by other ankle injuries, accounting for 5% to 18% of ankle sprains[4]. It is difficult to diagnose accurately at the initial visit, with up to 20% overlooked in emergency[5]. Missed diagnosis or improper treatment can lead to chronic complications, such as instability, pain after activity, and osteoarthritis in the long term. Although auxiliary imaging assessment is essential to diagnosing this injury, clinical stress tests, including the valgus stress test, external rotation stress test, squeeze test, crossed-leg test, and Cotton test, also play an important role in the primary diagnosis. In the present case, we excessively assessed syndesmosis based on CT imaging and overfocused on matching the fibula and notch

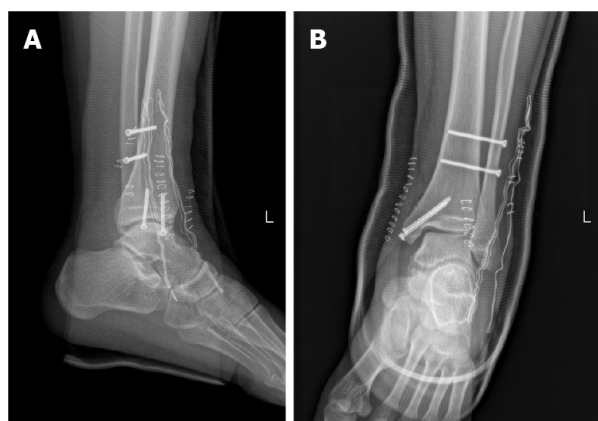


Figure 6 Ankle radiographs of anteroposterior and lateral views after secondary surgery. A: Anteroposterior; B: Lateral.

of the distal tibia in the bone window while ignoring syndesmotom soft tissue injury. If avulsion at the ventral and dorsal syndesmosis would have been caught in the soft tissue window before the primary surgery, the instability of the syndesmosis could potentially have raised suspicion. Stress tests could have been performed, and then secondary surgery would have been avoided. In addition, the well-known hook test is usually adopted to assess syndesmotom stability intraoperatively. If there is no lateral incision for the hook test, like the primary surgery in the present case, stress fluoroscopy of valgus or external rotation could also be performed to evaluate the syndesmotom stability.

Nonoperative treatment for patients with isolated syndesmosis injury has shown good results, even in high-level athletes[8]. Similarly, successful outcomes were obtained by surgical treatment with screws[9] or suture buttons[10]. Moreover, a minimum 2-year follow-up recommend that surgeons not only open reduction of the syndesmosis under direct visualization but perform postoperative CT scans with comparison to the contralateral extremity to reduce the rate of malreduction[11]. Reviewing the literature, nonoperative treatment is recommended for stable syndesmosis injury[12], whereas unstable syndesmosis injury (frank or latent) should be managed operatively[13]. The present case involved syndesmosis injury with a concomitant rupture of IOM, which is a fibrous connective tissue with a thickness of approximately 1 mm connecting the tibia and fibula. IOM plays an important role in maintaining the appropriate correlation between the tibia and fibula. Due to the strain of IOM, the distance between the tibia and fibula is not widened under external force to avoid lateral translation of the fibula, but it cannot prevent rotation or anterior-posterior translation of the fibula. When the IOM is injured, it unburdens the fibula in load transference by more than 30%[14]. Based on that, we believed that the present injury was caused by high energy (car accident), and the dynamic stability of syndesmosis was more difficult to maintain although the fractured medial malleolus was reduced and fixed firmly. Therefore, we chose open reduction and internal fixation for the syndesmosis injury to prevent spontaneous diastasis and eventually obtained good clinical outcomes in the follow-up.

IOM rupture was also found in all Maisonneuve injuries that previous studies reported[15,16]. The AITFL is not only the first involved structure when the talus rotates externally but also the weakest ligament of the tibiofibular syndesmotom complex, whereas the PITFL was confirmed to be intact in some Maisonneuve injuries. Therefore, except for upper third fibula fracture, one of the essential features of Maisonneuve injury may be rupture of the IOM, which continues distally and thickens into the interosseous ligament (IOL). Manyi *et al*[17] reported that the extent of IOM rupture was lower than the level of fibula fracture in all 12 patients with Maisonneuve fracture, ranging from 32-112 mm to the talar dome. He *et al*[18]'s study showed that the rupture of the IOM was not only limited to the distal one-third of the calf, on average 6.6 cm above the articular surface of the distal tibia, but also near the fibular fracture, while the IOM was intact between the two rupture sites in some patients. The wider the extent of the IOM rupture, the more severe the syndesmosis injury[17]. In our opinion, although the present case did not involve fracture of the upper third of the fibula, syndesmosis injury with IOM rupture could also be classified as Maisonneuve-equivalent injury according to the range of IOM rupture, the instability of the syndesmosis, and the similar management.

The injury mechanism of most Maisonneuve injuries is pronation-external rotation (PER)[19], in which the fibular fracture line extends from the anterior edge in a posteroinferior direction. Some studies have reported that the supination-external rotation mechanism could also lead to such injury, which is different from the former, being an intact medial structure (no fracture of the medial malleolus or rupture of the deltoid ligament)[6,20], and the fibular fracture line extended from the anterior edge in a posterosuperior direction[21]. Most authors have classified Maisonneuve injury as PER III or IV according to the Lauge-Hansen[22] classification. In a typical Maisonneuve injury, the involved structures caused by the PER IV mechanism include the fracture of the medial malleolus (or the rupture of the deltoid ligament), rupture of the AITFL (or avulsion fracture of the insertion), rupture of the IOL, rupture of the IOM, fracture of the proximal fibula, and rupture of the PITFL (or avulsion fracture of the insertion). On this basis, we concluded that the present case belongs to the PER IV mechanism, which was also one of the reasons that we classified it as Maisonneuve-equivalent injury.

In Maisonneuve injury, the force caused by talus external rotation runs from the medial aspect of the ankle, passing through the tibiotalar joint to the inferior tibiofibular syndesmosis. Rupture of the AITFL first occurs, followed by rupture of the IOL and IOM when the force persists. If the force is strong enough and continues to transmit up to the upper fibula, it may result in a stress concentration at the upper fibula due to the limitation of the upper tibiofibular syndesmosis; subsequently, upper fibula fracture occurs[23]. The fracture site of the fibula acts as a breakthrough point to release the force. When the transmitted force exceeds the limitation of upper tibiofibular syndesmosis, the superior tibiofibular joint is dislocated as a breakthrough point of the force, which is considered to be another kind of Maisonneuve-equivalent injury. Only five cases of that kind of Maisonneuve-equivalent injury have been reported in the literature[24]. According to the intensity of the transmitted force and the location of the breakthrough point, we further classified Maisonneuve injury as syndesmosis injury with IOM rupture (type I), syndesmosis injury with upper fibula fracture (type II), and syndesmosis injury with superior tibiofibular joint dislocation (type III).

CONCLUSION

The present injury pattern is different from simple syndesmosis injury and could be considered a Maisonneuve-equivalent injury. Comprehensive measures, including thorough physical examination and exact reading of auxiliary imaging and intraoperative stress fluoroscopy, should be performed to avoid misdiagnosis. The associated disruption of the IOM indicates the severity of syndesmosis injury. Good results could be achieved by open reduction and internal fixation.

REFERENCES

- 1 **Maisonneuve MJG.** Recherches sur la fracture du péroné. *Arch Gen Med* 1840; **7**: 165-187
- 2 **Stufkens SA,** van den Bekerom MP, Doornberg JN, van Dijk CN, Kloen P. Evidence-based treatment of maisonneuve fractures. *J Foot Ankle Surg* 2011; **50**: 62-67 [PMID: [21172642](#) DOI: [10.1053/j.jfas.2010.08.017](#)]
- 3 **Lock TR,** Schaffer JJ, Manoli A 2nd. Maisonneuve fracture: case report of a missed diagnosis. *Ann Emerg Med* 1987; **16**: 805-807 [PMID: [3592337](#) DOI: [10.1016/s0196-0644\(87\)80580-2](#)]
- 4 **McCollum GA,** van den Bekerom MP, Kerkhoffs GM, Calder JD, van Dijk CN. Syndesmosis and deltoid ligament injuries in the athlete. *Knee Surg Sports Traumatol Arthrosc* 2013; **21**: 1328-1337 [PMID: [23052109](#) DOI: [10.1007/s00167-012-2205-1](#)]
- 5 **Tourné Y,** Molinier F, Andrieu M, Porta J, Barbier G. Diagnosis and treatment of tibiofibular syndesmosis lesions. *Orthop Traumatol Surg Res* 2019; **105**: S275-S286 [PMID: [31594732](#) DOI: [10.1016/j.otsr.2019.09.014](#)]
- 6 **Bartoniček J,** Rammelt S, Kašper Š, Malík J, Tuček M. Pathoanatomy of Maisonneuve fracture based on radiologic and CT examination. *Arch Orthop Trauma Surg* 2019; **139**: 497-506 [PMID: [30552509](#) DOI: [10.1007/s00402-018-3099-2](#)]
- 7 **Gifford PB,** Lutz M. The tibiofibular line: an anatomical feature to diagnose syndesmosis malposition. *Foot Ankle Int* 2014; **35**: 1181-1186 [PMID: [25092879](#) DOI: [10.1177/1071100714546187](#)]
- 8 **Fort NM,** Aiyer AA, Kaplan JR, Smyth NA, Kadakia AR. Management of acute injuries of the tibiofibular syndesmosis. *Eur J Orthop Surg Traumatol* 2017; **27**: 449-459 [PMID: [28391516](#) DOI: [10.1007/s00590-017-1956-2](#)]

- 9 **van den Bekerom MP**, de Leeuw PA, van Dijk CN. Delayed operative treatment of syndesmotic instability. Current concepts review. *Injury* 2009; **40**: 1137-1142 [PMID: [19524232](#) DOI: [10.1016/j.injury.2009.03.011](#)]
- 10 **Förschner PF**, Beitzel K, Imhoff AB, Buchmann S, Feuerriegel G, Hofmann F, Karampinos DC, Jungmann P, Pogorzelski J. Five-Year Outcomes After Treatment for Acute Instability of the Tibiofibular Syndesmosis Using a Suture-Button Fixation System. *Orthop J Sports Med* 2017; **5**: 2325967117702854 [PMID: [28508007](#) DOI: [10.1177/2325967117702854](#)]
- 11 **Sagi HC**, Shah AR, Sanders RW. The functional consequence of syndesmotic joint malreduction at a minimum 2-year follow-up. *J Orthop Trauma* 2012; **26**: 439-443 [PMID: [22357084](#) DOI: [10.1097/BOT.0b013e31822a526a](#)]
- 12 **Amendola A**, Williams G, Foster D. Evidence-based approach to treatment of acute traumatic syndesmosis (high ankle) sprains. *Sports Med Arthrosc Rev* 2006; **14**: 232-236 [PMID: [17135973](#) DOI: [10.1097/01.jsa.0000212329.32969.b8](#)]
- 13 **van Dijk CN**, Longo UG, Loppini M, Florio P, Maltese L, Ciuffreda M, Denaro V. Conservative and surgical management of acute isolated syndesmotic injuries: ESSKA-AFAS consensus and guidelines. *Knee Surg Sports Traumatol Arthrosc* 2016; **24**: 1217-1227 [PMID: [26846658](#) DOI: [10.1007/s00167-016-4017-1](#)]
- 14 **Vukicević S**, Stern-Padovan R, Vukicević D, Keros P. Holographic investigations of the human tibiofibular interosseous membrane. *Clin Orthop Relat Res* 1980; 210-214 [PMID: [7418307](#)]
- 15 **Babis GC**, Papagelopoulos PJ, Tsarouchas J, Zoubos AB, Korres DS, Nikiforidis P. Operative treatment for Maisonneuve fracture of the proximal fibula. *Orthopedics* 2000; **23**: 687-690 [PMID: [10917243](#)]
- 16 **Yoshimura I**, Naito M, Kanazawa K, Takeyama A, Ida T. Arthroscopic findings in Maisonneuve fractures. *J Orthop Sci* 2008; **13**: 3-6 [PMID: [18274848](#) DOI: [10.1007/s00776-007-1192-4](#)]
- 17 **Manyi W**, Guowei R, Shengsong Y, Chunyan J. A sample of Chinese literature MRI diagnosis of interosseous membrane injury in Maisonneuve fractures of the fibula. *Injury* 2000; **31** Suppl 3: C107-C110 [PMID: [11052387](#) DOI: [10.1016/s0020-1383\(00\)80038-8](#)]
- 18 **He JQ**, Ma XL, Xin JY, Cao HB, Li N, Sun ZH, Wang GX, Fu X, Zhao B, Hu FK. Pathoanatomy and Injury Mechanism of Typical Maisonneuve Fracture. *Orthop Surg* 2020; **12**: 1644-1651 [PMID: [32896104](#) DOI: [10.1111/os.12733](#)]
- 19 **Porter DA**, Jagers RR, Barnes AF, Rund AM. Optimal management of ankle syndesmosis injuries. *Open Access J Sports Med* 2014; **5**: 173-182 [PMID: [25177153](#) DOI: [10.2147/OAJSM.S41564](#)]
- 20 **Charopoulos I**, Kokoroghiannis C, Karagiannis S, Lyritis GP, Papaioannou N. Maisonneuve fracture without deltoid ligament disruption: a rare pattern of injury. *J Foot Ankle Surg* 2010; **49**: 86.e11-86.e17 [PMID: [20123296](#) DOI: [10.1053/j.jfas.2009.10.001](#)]
- 21 **Pankovich AM**. Maisonneuve fracture of the fibula. *J Bone Joint Surg Am* 1976; **58**: 337-342 [PMID: [816799](#)]
- 22 **Lauge-Hansen N**. Fractures of the ankle. II. Combined experimental-surgical and experimental-roentgenologic investigations. *Arch Surg* 1950; **60**: 957-985 [PMID: [15411319](#)]
- 23 **Yu GS**, Lin YB, Xiong GS, Xu HB, Liu YY. Diagnosis and treatment of ankle syndesmosis injuries with associated interosseous membrane injury: a current concept review. *Int Orthop* 2019; **43**: 2539-2547 [PMID: [31440891](#) DOI: [10.1007/s00264-019-04396-w](#)]
- 24 **Alencar Neto JB**, Cavalcante MLC, Pinto Neto LH, Lucena IF, Garrido RJ, Rocha PHMD. Maisonneuve Variant Lesion with Proximal Tibiofibular Dislocation. *Rev Bras Ortop (Sao Paulo)* 2019; **54**: 339-342 [PMID: [31363291](#) DOI: [10.1055/s-0039-1692625](#)]



Published by **Baishideng Publishing Group Inc**
7041 Koll Center Parkway, Suite 160, Pleasanton, CA 94566, USA

Telephone: +1-925-3991568

E-mail: bpgoffice@wjgnet.com

Help Desk: <https://www.f6publishing.com/helpdesk>

<https://www.wjgnet.com>

