

**Name of Journal:** *World Journal of Clinical Cases*

**Manuscript NO:** 62169

**Manuscript Type:** CASE REPORT

**Diagnosis and treatment of <sup>2</sup>pediatric anaplastic lymphoma kinase-positive large B-cell lymphoma: A case report**

Diagnosis and treatment of pediatric ALK+ LBCL

## Abstract

### BACKGROUND

Anaplastic lymphoma kinase-positive large B-cell lymphoma (ALK+ LBCL) is a rare type of lymphoma with high invasiveness and rapid progression. It occurs in all age groups, however, it is extremely rare in children. The lesions mainly involve the lymph nodes and may present with extra-nodal involvement. Response to conventional chemotherapies and local radiotherapy is poor, with a 5-year overall survival (OS) of less than 40%. Recently, the use of ALK inhibitors for the treatment of this disease has

## Match Overview

1	Internet 69 words crawled on 15-Oct-2020 <a href="http://www.wjgnet.com">www.wjgnet.com</a>	2%
2	Internet 28 words crawled on 22-Dec-2019 <a href="http://tessera.spandidos-publications.com">tessera.spandidos-publications.com</a>	1%
3	Internet 18 words <a href="http://www.pubmedcentral.nih.gov">www.pubmedcentral.nih.gov</a>	1%
4	Crossref 18 words Zanelli, M., R. Valli, I. Capodanno, M. Ragazzi, and S. Ascani. "Anaplastic Lymphoma Kinase-Positive Large B-Cell Lymph ...	1%
5	Crossref 18 words Elizabeth A. Morgan, Alessandra F. Nascimento. "Anaplastic Lymphoma Kinase-Positive Large B-Cell Lymphoma: An Un ...	1%
6	Internet 14 words crawled on 27-Jun-2020 <a href="http://insights.ovid.com">insights.ovid.com</a>	<1%
7	Crossref 14 words Andrés E. Quesada, Yang O. Huh, Wei Wang, L. Jeffrey Medeiros, Beenu Thakral. "Anaplastic lymphoma kinase (ALK)-p ...	<1%





ALL

IMAGES

VIDEOS

TOOLS ▼

## Pediatric Anaplastic Lymphoma Kinase-Positive Large B-cell ...

<https://www.researchgate.net/publication/221681135...>

We **report** detailed clinical and pathologic features of four cases of **anaplastic lymphoma** kinase-positive diffuse **large** B-cell **lymphoma** (ALK-DLBCL), a rare entity with only 29 currently reported cases.

## (PDF) Pediatric Anaplastic Large Cell Lymphoma—A Review

<https://www.researchgate.net/publication/324958947...>

majority of **pediatric cases** demonstrate overexpression of **anaplastic lymphoma kinase (ALK)**. Despite a range of **treatment** strategies, event-free survival has remained stagnant at 65–75%. The role of...

### PEOPLE ALSO ASK

What is the prognosis for anaplastic large cell lymphoma? ▼

What are the types of pediatric lymphoma? ▼

What is the incidence of lymphoblastic lymphoma? ▼

Is positron emission tomography good for Hodgkin lymphoma? ▼

Feedback

## Promising response of anaplastic lymphoma kinase-positive ...

<https://pubmed.ncbi.nlm.nih.gov/26221234>

Abstract. **Anaplastic lymphoma kinase** (ALK)-positive diffuse **large B-cell lymphoma** (ALK + DLBCL) is a rare and poorly characterized subtype of lymphoma. Reports suggest that this type of **tumor** responds poorly to standard regimens for non-Hodgkin's lymphoma, with rituximab playing no therapeutic role due to the absence of CD20 expression.



[ALL](#)
[IMAGES](#)
[VIDEOS](#)
[MAPS](#)
[NEWS](#)
[SHOPPING](#)

304,000 Results Any time ▾

## Anaplastic lymphoma kinase-positive large B-cell lymphoma ...

<https://www.ncbi.nlm.nih.gov/pubmed/24868005>

**Anaplastic lymphoma kinase-positive (ALK-positive) large B-cell lymphoma** is a rare and aggressive variant of **large B-cell lymphoma (LBCL)**, first reported by Delsol et al in 1997, showing distinctive...

**Cited by:** 3 **Author:** Magda Zanelli, Riccardo Valli, Isabella Cap...

**Publish Year:** 2015

## Pediatric Anaplastic Lymphoma Kinase-Positive Large B-cell ...

<https://www.researchgate.net/publication/221681135...>

We **report** detailed clinical and pathologic features of four cases of **anaplastic lymphoma** kinase-positive diffuse **large B-cell lymphoma (ALK-DLBCL)**, a rare entity with only 29 currently reported cases.

## Anaplastic lymphoma kinase-positive diffuse large B-cell ...

<https://www.ncbi.nlm.nih.gov/pubmed/19636007>

Sep 01, 2009 · **PURPOSE:** **Anaplastic lymphoma** kinase (ALK) -positive diffuse **large B-cell lymphoma (DLBCL)** is a rare variant of DLBCL that has been described only in small **case** reports. To shed more ligh...

**Cited by:** 170 **Author:** Camille Laurent, Catherine Do, Randy D. Ga...

**Publish Year:** 2009

## Promising response of anaplastic lymphoma kinase-positive ...

<https://pubmed.ncbi.nlm.nih.gov/26221234>

**Anaplastic lymphoma** kinase (ALK)-positive **diffuse large B-cell lymphoma (ALK + DLBCL)** is a rare and poorly characterized subtype of **lymphoma**. **Reports** suggest that this type of **tumor** responds poorly to...

**Cited by:** 9 **Author:** Jian Li, Jian Ouyang, Rongfu Zhou, Bing Ch...

**Publish Year:** 2015

## Anaplastic Lymphoma Kinase-Positive Large B-Cell Lymphoma ...

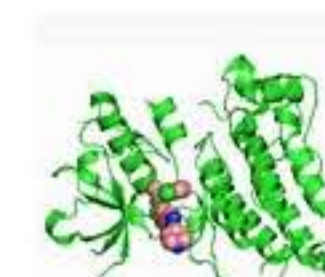
<https://www.hindawi.com/journals/ah/2012/529572> ▾

Abstract. **Anaplastic lymphoma** kinase-(ALK-) positive **large B-cell lymphoma (ALK+ LBCL)** is a rare, aggressive tumor characterized by an immunoblastic or plasmablastic morphologic appearance,...

**Cited by:** 22 **Author:** Elizabeth A. Morgan, Alessandra F. Nascim...

## Anaplastic Lymphoma Kinase

Enzyme

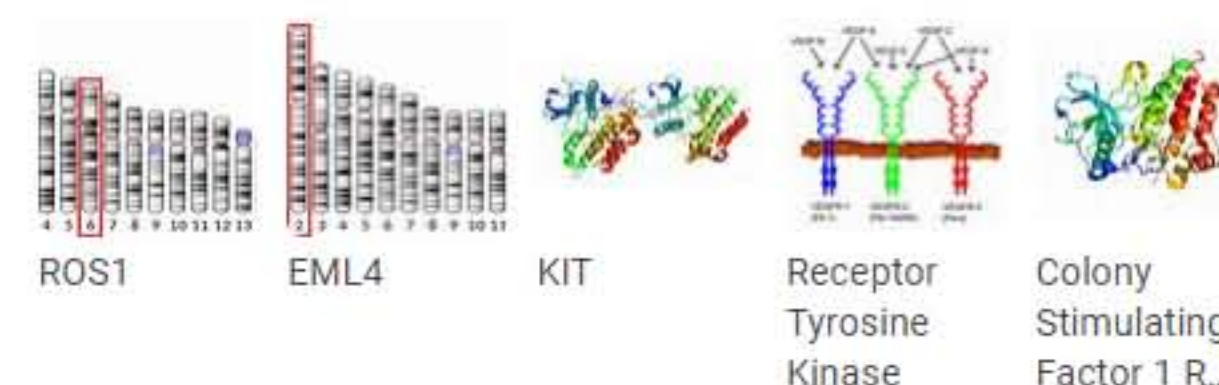


Anaplastic lymphoma kinase (ALK) also known as ALK tyrosine kinase receptor or CD246 (cluster of differentiation 246) is an enzyme that in humans is encoded by the ALK gene.

 [Wikipedia](#)

### People also search for

[See all \(15+\)](#)



Data from: Wikipedia

[Suggest an edit](#)