

国内版国际版

Microsoft Bing

Primary Malignant Vascular Tumors of the Liver in Children: Angiosarcoma

Chat with BingSign in

ALLIMAGESVIDEOS

80,800 ResultsAny time

Angiosarcoma - National Cancer Institute

<https://www.cancer.gov/.../rare-tumors/rare-vascular-tumors/angiosarcoma>

Angiosarcoma is a rare cancer that develops in the inner lining of blood vessels and lymph vessels. This cancer can occur anywhere in the body but most often is in the skin, breast, liver and spleen.

Primary hepatic malignant vascular tumors: a follow-up ...

<https://pubmed.ncbi.nlm.nih.gov/32795351>

Background: Owing to its low incidence, there is insufficient clinical awareness and diagnostic experience with primary hepatic malignant vascular tumors (PHMVTs). The aim of our study was to investigate the imaging and clinicopathological features of patients with ...

PEOPLE ALSO ASK

What are the symptoms of primary liver angiosarcoma?

Epithelioid hemangioendothelioma

Rare Tumor

Epithelioid hemangioendothelioma is a rare tumor, first characterized by Sharon Weiss and Franz Enzinger that both clinically and histologically is intermediate between angiosarcoma and hemangioma. However, a distinct, disease-defining genetic alteration recently described for EHE indicates that it is an entirely separate entity from both angiosarcoma and hemangioma.

117Wikipedia

国内版 国际版

Primary Malignant Vascular Tumors of the Liver in Children: Angiosa



ALL IMAGES VIDEOS

61,800 Results

Any time ▾

Open links in new tab ☒

Malignant vascular tumors of liver in neonates - ScienceDirect

<https://www.sciencedirect.com/science/article/pii/S0022346805008365>

Jan 01, 2006 · Vascular tumors of the liver reported in infants and young children are infantile **hemangioendothelioma**, **cavernous hemangioma**, malignant epithelioid **hemangioendothelioma**, and angiosarcoma. The most common is infantile **hemangioendothelioma**, a lesion most often congenital, usually multifocal, frequently symptomatic in infancy and may be complicated by hemodynamic and ...

Cited by: 22

Author: Zafar Nazir, Shahid Pervez

Publish Year: 2006

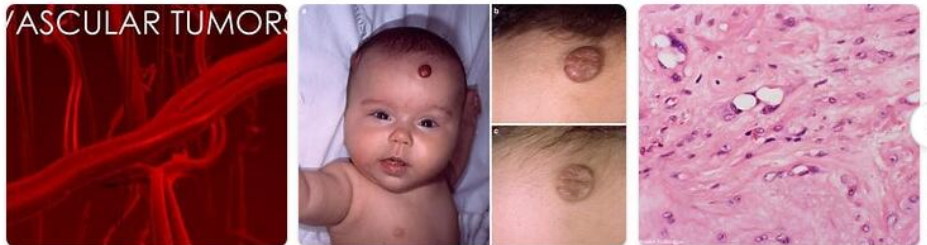Childhood Vascular Tumors Treatment (PDQ®)–Health ...

<https://www.cancer.gov/types/soft-tissue-sarcoma/...> ▾

In one child diagnosed with angiosarcoma secondary to malignant transformation from infantile hemangioma, response to treatment with **bevacizumab**, a monoclonal antibody against vascular endothelial growth factor, combined with systemic chemotherapy, has been reported.[17,27] A report of eight cases of liver angiosarcoma in children highlighted the misuse of the term ...

Images of Primary Malignant Vascular Tumors of the Liver in ...

<bing.com/images>



See all images >

Name of Journal: *World Journal of Gastrointestinal Oncology*

Manuscript NO: 62289

Manuscript Type: MINIREVIEWS

Primary Malignant Vascular Tumors of the Liver in Children: Angiosarcoma and Epithelioid Hemangioendothelioma

Malignant vascular tumors of the liver in children

Sami Bannoura, Juan Putra

Match Overview

1	Crossref 26 words Ely Gourmoyer, Aiyaa Al-Brateem, Elissa Engel, Gulraiz Chakraborty, Stacie Stapleton, Denise M. Adams. "Clinical of ...	1%
2	Crossref 21 words Hu-Zhi Zhang, Lei Dong, Su-Ying Wang, Xiao-Qian Yang. "TFE3 rearranged epithelioid hemangioendothelioma of bon	1%
3	Crossref 21 words Simone Helmer, Geoffrey Andrieux, Jochen Hochrein, Philipp Kurz et al. "Epithelioid hemangioendotheliomas of the ...	1%
4	Crossref 26 words Giovanni B. Chantrel, Ilam Siddiqui, Katriina M. Ingley, Abh ... A. Gupta. "Rare malignant liver tumors in children", <i>Pediatr</i>	1%
5	Crossref 18 words Anna McGuire, Israel Fernandez-Pineda, Steven J Fahm ... n, Belinda Hsi Dickie. "Pediatric Hepatic Vascular Tumors",	1%
6	Internet 16 words created on 23-Apr-2020 www.archivesofpathology.org	1%
7	Internet 15 words created on 19-Jun-2017 en.wikipedia.org	1%
8	Crossref 14 words Leigh A. Compton, Leona A. Doyle. "Advances in the Ge ... tic Characterization of Cutaneous Mesenchymal Neoplasms	1%
9	Crossref 14 words <i>Surgical Pathology of Liver Tumors</i> , 2015.	1%

国内版 国际版

Primary malignant vascular tumors of the liver in children: Angiosar



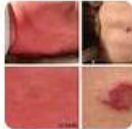ALL IMAGES VIDEOS

63,600 Results

Any time ▾

Childhood Vascular Tumors Treatment (PDQ®)—Health ...

<https://www.cancer.gov/types/soft-tissue-sarcoma/...> ▾



In one child diagnosed with angiosarcoma secondary to malignant transformation from infantile hemangioma, response to treatment with **bevacizumab**, a monoclonal antibody against vascular endothelial growth factor, combined with systemic chemotherapy, has ...

Malignant vascular tumors of liver in neonates - ScienceDirect

<https://www.sciencedirect.com/science/article/pii/S0022346805008365>

Jan 01, 2006 · Vascular tumors of the liver reported in infants and young children are infantile **hemangioendothelioma**, **cavernous hemangioma**, malignant epithelioid **hemangioendothelioma**, and **angiosarcoma**. The most common is infantile **hemangioendothelioma**, a lesion most often congenital, usually multifocal, frequently symptomatic in infancy and may be complicated by hemodynamic and ...

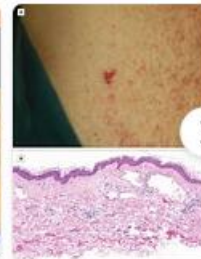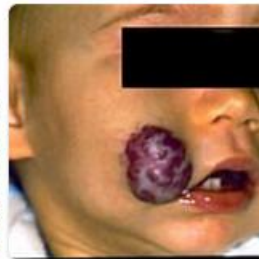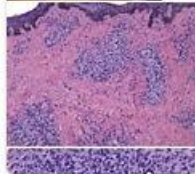
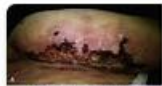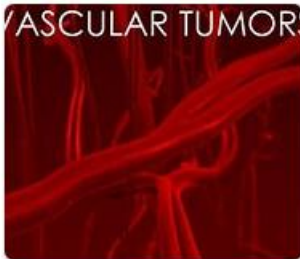Cited by: 23

Author: Zafar Nazir, Shahid Pervez

Publish Year: 2006

Images of Primary Malignant Vascular tumors of the Liver in ...

<bing.com/images>



See all images >

PEOPLE ALSO ASK