

World Journal of *Gastroenterology*

World J Gastroenterol 2021 July 28; 27(28): 4484-4745



EDITORIAL

- 4484** Asymptomatic small intestinal ulcerative lesions: Obesity and *Helicobacter pylori* are likely to be risk factors
Fujimori S

GUIDELINE INTERPRETATION

- 4493** Recent advances in gastrointestinal cancers
Bordry N, Astaras C, Ongaro M, Goossens N, Frossard JL, Koessler T

REVIEW

- 4504** Gastrointestinal and hepatic diseases during the COVID-19 pandemic: Manifestations, mechanism and management
Mohamed DZ, Ghoneim MES, Abu-Risha SES, Abdelsalam RA, Farag MA
- 4536** Management of cholelithiasis with choledocholithiasis: Endoscopic and surgical approaches
Cianci P, Restini E
- 4555** Cellular factors involved in the hepatitis C virus life cycle
Li HC, Yang CH, Lo SY
- 4582** Modulation of cell physiology under hypoxia in pancreatic cancer
Estaras M, Gonzalez A
- 4603** Viral hepatitis: Milestones, unresolved issues, and future goals
Torre P, Aglitti A, Masarone M, Persico M

MINIREVIEWS

- 4639** Addition of statins to the standard treatment in patients with cirrhosis: Safety and efficacy
Muñoz AE, Pollarsky FD, Marino M, Cartier M, Vázquez H, Salgado P, Romero G
- 4653** Genetic variant of cyclooxygenase-2 in gastric cancer: More inflammation and susceptibility
Ji XK, Madhurapantula SV, He G, Wang KY, Song CH, Zhang JY, Wang KJ

ORIGINAL ARTICLE

Basic Study

- 4667** Y-box binding protein 1 augments sorafenib resistance *via* the PI3K/Akt signaling pathway in hepatocellular carcinoma
Liu T, Xie XL, Zhou X, Chen SX, Wang YJ, Shi LP, Chen SJ, Wang YJ, Wang SL, Zhang JN, Dou SY, Jiang XY, Cui RL, Jiang HQ

Retrospective Study

- 4687** *Lens culinaris* agglutinin-reactive fraction of alpha-fetoprotein improves diagnostic accuracy for hepatocellular carcinoma

Lee HA, Lee YR, Lee YS, Jung YK, Kim JH, An H, Yim HJ, Jeon YT, Yeon JE, Byun KS, Seo YS

- 4697** New anti-reflux plastic stent to reduce the risk of stent-related cholangitis in the treatment of biliary strictures

Yuan XL, Ye LS, Zeng XH, Tan QH, Mou Y, Liu W, Wu CC, Yang H, Hu B

Clinical Trials Study

- 4710** Modified Xiaochaihu Decoction for gastroesophageal reflux disease: A randomized double-simulation controlled trial

Li Z, Tao L, Zhang SS, Sun XH, Chen SN, Wu J

Observational Study

- 4722** Relationship between clinical features and intestinal microbiota in Chinese patients with ulcerative colitis

He XX, Li YH, Yan PG, Meng XC, Chen CY, Li KM, Li JN

CASE REPORT

- 4738** HER2-positive adenocarcinoma arising from heterotopic pancreas tissue in the duodenum: A case report

Hirokawa YS, Iwata T, Okugawa Y, Tanaka K, Sakurai H, Watanabe M

ABOUT COVER

Editorial Board Member of *World Journal of Gastroenterology*, Kentaro Yoshioka, MD, PhD, Director, Center for Liver Diseases, Meijo Hospital, 1-3-1 Sannomaru, Naka-ku, Nagoya 460-0001, Japan. kyoshiok@fujita-hu.ac.jp

AIMS AND SCOPE

The primary aim of *World Journal of Gastroenterology* (WJG, *World J Gastroenterol*) is to provide scholars and readers from various fields of gastroenterology and hepatology with a platform to publish high-quality basic and clinical research articles and communicate their research findings online. WJG mainly publishes articles reporting research results and findings obtained in the field of gastroenterology and hepatology and covering a wide range of topics including gastroenterology, hepatology, gastrointestinal endoscopy, gastrointestinal surgery, gastrointestinal oncology, and pediatric gastroenterology.

INDEXING/ABSTRACTING

The WJG is now indexed in Current Contents®/Clinical Medicine, Science Citation Index Expanded (also known as SciSearch®), Journal Citation Reports®, Index Medicus, MEDLINE, PubMed, PubMed Central, and Scopus. The 2021 edition of Journal Citation Report® cites the 2020 impact factor (IF) for WJG as 5.742; Journal Citation Indicator: 0.79; IF without journal self cites: 5.590; 5-year IF: 5.044; Ranking: 28 among 92 journals in gastroenterology and hepatology; and Quartile category: Q2. The WJG's CiteScore for 2020 is 6.9 and Scopus CiteScore rank 2020: Gastroenterology is 19/136.

RESPONSIBLE EDITORS FOR THIS ISSUE

Production Editor: Li-Li Wang; Production Department Director: Yan-jie Ma; Editorial Office Director: Ze-Mao Gong.

NAME OF JOURNAL

World Journal of Gastroenterology

ISSN

ISSN 1007-9327 (print) ISSN 2219-2840 (online)

LAUNCH DATE

October 1, 1995

FREQUENCY

Weekly

EDITORS-IN-CHIEF

Andrzej S Tarnawski, Subrata Ghosh

EDITORIAL BOARD MEMBERS

<http://www.wjgnet.com/1007-9327/editorialboard.htm>

PUBLICATION DATE

July 28, 2021

COPYRIGHT

© 2021 Baishideng Publishing Group Inc

INSTRUCTIONS TO AUTHORS

<https://www.wjgnet.com/bpg/gerinfo/204>

GUIDELINES FOR ETHICS DOCUMENTS

<https://www.wjgnet.com/bpg/GerInfo/287>

GUIDELINES FOR NON-NATIVE SPEAKERS OF ENGLISH

<https://www.wjgnet.com/bpg/gerinfo/240>

PUBLICATION ETHICS

<https://www.wjgnet.com/bpg/GerInfo/288>

PUBLICATION MISCONDUCT

<https://www.wjgnet.com/bpg/gerinfo/208>

ARTICLE PROCESSING CHARGE

<https://www.wjgnet.com/bpg/gerinfo/242>

STEPS FOR SUBMITTING MANUSCRIPTS

<https://www.wjgnet.com/bpg/GerInfo/239>

ONLINE SUBMISSION

<https://www.f6publishing.com>



Asymptomatic small intestinal ulcerative lesions: Obesity and *Helicobacter pylori* are likely to be risk factors

Shunji Fujimori

ORCID number: Shunji Fujimori
0000-0002-6214-2595.

Author contributions: Fujimori S contributed to the writing this paper.

Conflict-of-interest statement: The author declares no conflict of interest.

Open-Access: This article is an open-access article that was selected by an in-house editor and fully peer-reviewed by external reviewers. It is distributed in accordance with the Creative Commons Attribution NonCommercial (CC BY-NC 4.0) license, which permits others to distribute, remix, adapt, build upon this work non-commercially, and license their derivative works on different terms, provided the original work is properly cited and the use is non-commercial. See: <http://creativecommons.org/licenses/by-nc/4.0/>

Manuscript source: Invited manuscript

Specialty type: Gastroenterology and hepatology

Country/Territory of origin: Japan

Peer-review report's scientific quality classification
Grade A (Excellent): A

Shunji Fujimori, Department of Gastroenterology, Chiba Hokusoh Hospital, Nippon Medical School, Chiba 270-1694, Japan

Corresponding author: Shunji Fujimori, AGAF, MD, PhD, Director, Department of Gastroenterology, Chiba Hokusoh Hospital, Nippon Medical School, 1715 Kamagari, Inzai-City, Chiba 270-1694, Japan. s-fujimori@nms.ac.jp

Abstract

It is often difficult to explain why ulcerative lesions are found in the small intestine because there are no obvious aggressors such as gastric acid. In particular, the treatment of small intestinal ulcerative lesions in asymptomatic patients with no symptoms, normal physical examinations, and normal blood test findings is not well documented. According to a summary of capsule endoscopy studies in healthy subjects, approximately 10% of subjects have small intestinal mucosal breaks. The number of mucosal breaks in these instances is approximately 1-3. We examined small intestinal mucosal breaks in healthy subjects recruited from our past two studies. Mucosal breaks were observed in approximately 10% of subjects, and the average number was 0.24 ± 1.21 . The number of mucosal breaks in the small intestine was correlated with body mass index and was significantly higher in *Helicobacter pylori*-infected subjects and higher in males. These results indicate that 1-2 small ulcerative lesions, such as erosions in the small intestine, can be considered to be in the normal range, and close examination is not required. It is assumed that a follow-up medical examination is required for such asymptomatic persons. The presence of many small ulcerative lesions or an unequivocal ulcer indicates an abnormality for which close examination is desired. However, in many cases, it is sufficient to scrutinize after detecting anemia, but it is difficult to make a judgment due to insufficient reports, and future studies are required.

Key Words: Small intestine; Mucosal break; Ulcer; Asymptomatic; Obesity; *Helicobacter pylori*

©The Author(s) 2021. Published by Baishideng Publishing Group Inc. All rights reserved.

Core Tip: Approximately 10% of asymptomatic subjects with normal blood tests have

Grade B (Very good): B
 Grade C (Good): 0
 Grade D (Fair): D
 Grade E (Poor): 0

Received: January 31, 2021

Peer-review started: January 31, 2021

First decision: March 29, 2021

Revised: April 9, 2021

Accepted: July 12, 2021

Article in press: July 12, 2021

Published online: July 28, 2021

P-Reviewer: Farhat S, Hu Y

S-Editor: Fan JR

L-Editor: A

P-Editor: Wang LL



small intestinal mucosal breaks. A reanalysis of our previous studies showed that small intestinal mucosal breaks were strongly correlated with body mass index, were significantly more prevalent in *Helicobacter pylori*-infected individuals and were more prevalent in men. These may be risk factors for small intestinal mucosal breaks. Overall, 1-2 small ulcerative lesions in asymptomatic patients are considered to be in the normal range and do not require close examination, and it is assumed that a follow-up medical examination is required.

Citation: Fujimori S. Asymptomatic small intestinal ulcerative lesions: Obesity and *Helicobacter pylori* are likely to be risk factors. *World J Gastroenterol* 2021; 27(28): 4484-4492

URL: <https://www.wjgnet.com/1007-9327/full/v27/i28/4484.htm>

DOI: <https://dx.doi.org/10.3748/wjg.v27.i28.4484>

INTRODUCTION

Ulcerative lesions are less common in the small intestine, except in the duodenum, than in the stomach. Even if some small ulcerative lesions such as erosions are found in the stomach, we do not care much because of the many accumulated reports and experiences. However, we are concerned with the cause of ulcerative lesions of the small intestine. This is because the small intestine lacks obvious aggressors such as gastric acid, making it difficult to explain the cause of ulcerative lesions. Moreover, there is insufficient knowledge about ulcerative lesions of the small intestine.

Screening colonoscopy occasionally detects a small number of small ulcerative lesions at the terminal ileum. Patients with small ulcerative lesions at the terminal ileum who do not take nonsteroidal anti-inflammatory drugs (NSAIDs) are often doubtful about Crohn's disease (CD) in endoscopic results reports. Some patients had small ulcerative lesions that could potentially progress to CD, and a case was reported [1]. Recently, a report described that CD was detected in 0.28% (13 out of 4640 cases) by colorectal cancer screening [2]. The report indicated that ileal ulcers were detected in 6 of 13 cases, suggesting that ileal ulcers were associated with CD. Four of the 6 patients had no lesions other than ileal ulcers, and the simple endoscopic score for CD was 2-6 points. In other words, some patients had a slightly larger ileal ulcer; however, all patients were scheduled only for a followed up without treatment. It is considered difficult to make an endoscopic diagnosis of the 4 patients with CD, and it is not stated whether granuloma was detected by histological examination. The diagnosis of CD is difficult in the early stages, but the patients in this study did not appear to meet the diagnostic criteria for CD [3]. The question remains as to the diagnosis of CD in these patients, and the follow-up results are considered important.

Subjects who were asymptomatic with no abnormalities in blood tests or physical tests and were not taking medication were defined as healthy subjects. This may include patients with asymptomatic diseases; however, these were subjects without any obvious disease. It is not easy to frequently follow-up with an endoscopy for asymptomatic small ulcerative lesions of the small intestine identified the screening test of healthy subjects because of the physical and financial burdens imposed on the subject. In addition, even if an asymptomatic small ulcerative lesion is found at the terminal ileum, it is considered to be rare and not enough reason to conduct close examination, such as capsule endoscopy. However, it is not clear whether this research policy is correct. This is because the treatment of small intestinal ulcerative lesions in asymptomatic patients is not reported. This is thought to be because reports on the proportion of ulcerative lesions in the small intestine found in healthy subjects and the cause of small intestinal ulcerative lesions are extremely few. In this paper, we summarize how many small intestinal ulcerative lesions are found in healthy subjects, analyze the degree of appearance of small intestinal ulcerative lesions, and investigate the causes of small intestinal ulcerative lesions where possible. Then, we would like to consider the research policy when small intestinal ulcerative lesions are found.

ANALYSIS OF SMALL INTESTINAL ULCERATIVE LESIONS IN HEALTHY SUBJECTS

Definition of small intestinal ulcerative lesions

Ulcerative lesions of the small intestine are often evaluated as mucosal breaks. A mucosal break is a lesion in which white slough is observed, and the degree varies from small ulcerative lesion erosion (Figure 1A) to ulcer (Figure 1B). It is difficult to clearly distinguish this lesion, and there are many cases in which it is not clear which category a specific lesion should be classified into, as shown in Figure 1C. This ulcerative lesion has white slough over 3 mm and approximately 5 mm. Since it is expected that the judgments by researchers will be different in categorizing this lesion, the frequency of appearance of mucosal breaks of healthy subjects was analyzed here.

Analysis of drug administration studies

In many studies, nonselective NSAIDs and cyclooxygenase 2-selective NSAIDs are administered to healthy subjects to compare the occurrence of small intestinal mucosal breaks. There are other studies in which mucosal protective drugs are administered at the same time as NSAIDs and aspirin to compare the effects of this combination. Capsule endoscopy has been performed in more than 1000 healthy subjects in various studies. In these studies, healthy subjects underwent capsule endoscopy before drug administration, and small intestinal evaluation of the healthy subjects was performed first. Table 1 summarizes the studies describing small intestinal mucosal breaks in healthy subjects before drug administration. Studies that do not describe these premedication small intestinal mucosal breaks and reports with a small number of subjects were not included in the Table 1.

According to the summarized results, approximately 10% of healthy subjects have small intestinal mucosal breaks. In addition, the number of mucosal breaks in subjects with mucosal breaks was approximately 1-3 in most examinations.

Analysis of small intestinal mucosal breaks in healthy subjects from our study

Our group has conducted several capsule endoscopy studies on healthy subjects. Two of these consisted of detailed tests and interviews, including tests for *Helicobacter pylori* (*H. pylori*) infection which bacterium is known to cause gastric ulcer, duodenal ulcer, atrophic gastritis, gastric cancer, etc., at the start of the study. Since the number of subjects in each study was insufficient for analysis, we combined these two studies to analyze the background of healthy subjects. In two studies we tested for *H. pylori* infection with a breath test[4] and with serum antibodies[5] prior to the NSAID dosing experiment. In particular, the latter study was investigated to block randomize *H. pylori*-infected individuals evenly when randomized.

Table 2 shows the cases that were analyzed. The total number of cases included in the two studies was slightly higher than that shown in Table 1. This is because the first capsule endoscopy was completed, but the subjects who dropped out of the study were added. The subjects enrolled in the study were those who were considered to be healthy subjects after screening, the results of basic blood tests and physical tests were normal, and were not taking any medication. The number of mucosal breaks in the small intestine determined by capsule endoscopy in these healthy subjects was 0.24 ± 1.21 (mean \pm SD). Based on these results, if the average \pm 2 SD of healthy subjects is considered to be the normal range, up to 2 mucosal breaks of the small intestine are in the normal range.

Next, since the number of mucosal breaks recognized in the subjects was 1-2 in most cases, subjects were divided into 21 cases with mucosal breaks and 201 cases without mucosal breaks. Then, sex, age, body mass index (BMI), smoking, alcohol consumption, and *H. pylori* infection were compared and analyzed. The results of the univariate analysis showed that the incidence of mucosal breaks was higher in men, in subjects that had a higher BMI, and in *H. pylori*-infected subjects. Therefore, when multivariate analysis was performed with these factors, mucosal breaks were strongly correlated with BMI and were significantly more common in *H. pylori*-infected subjects (Table 3).

MUCOSAL BREAKS ARE SIGNIFICANTLY ASSOCIATED WITH BMI AND *H. PYLORI* INFECTION

The results of this analysis revealed that small intestinal mucosal breaks were

Table 1 Reports of pretest small intestinal mucosal breaks in normal volunteers

Country	Year	No.	Subjects with mucosal breaks		Mean number of mucosal breaks		Ref.
			Number	%	Subjects with MB	All subjects	
United States	2005	413	57 ¹	13.8 ¹	N/A	N/A	Goldstein <i>et al</i> [10], 2005
United States	2007	472	56	11.9	N/A	N/A	Goldstein <i>et al</i> [11], 2007
Japan	2009	32	3	9.4	1.7	0.16	Fujimori <i>et al</i> [12], 2009
Canada	2009	20	0	0	0	0	Smecuol <i>et al</i> [13], 2009
Japan	2010	20	2	10.0	1-2	0.1-0.2	Shiotani <i>et al</i> [14], 2010
Japan	2011	72	4	5.6	1.0	0.56	Fujimori <i>et al</i> [4], 2011
Japan	2013	32	N/A	N/A	N/A	0.1-0.3	Kuramoto <i>et al</i> [15], 2013
China	2014	30	2	6.7	3.5	0.23	Huang <i>et al</i> [16], 2014
Japan	2014	30	N/A	N/A	N/A	0.14 ± 0.54	Umegaki <i>et al</i> [17], 2014
Japan	2016	141	14	9.9	3.5	0.35	Fujimori <i>et al</i> [5], 2016
Japan	2015	37	N/A	N/A	N/A	0.1-0.3	Kojima <i>et al</i> [18], 2015
Czech	2016	42	2	4.7	N/A	N/A	Tacheciet <i>et al</i> [19], 2016
Japan	2016	19	2	10.5	1.0	0.11	Arimoto <i>et al</i> [20], 2016
Japan	2016	45	N/A	N/A	N/A	0.13	Ota <i>et al</i> [21], 2016
Japan	2019	24	0	0	0	0	Ota <i>et al</i> [22], 2019

¹Lesion type unknown. Reports with 15 or more subjects and reports on premedication lesions were collected. MB: Mucosal break; N/A: Not available.

Table 2 Basic background of the two examinations whose background was examined in detail

Ref.	Number	Sex (M/F)	Age (mean ± SD)	Mean mucosal break
Fujimori <i>et al</i> [4], 2011	77	77/0	38.2 ± 8.1	0.12 ± 0.32
Fujimori <i>et al</i> [5], 2016	145	71/74	48.6 ± 6.4	0.30 ± 1.47
Total	222	148/74	45.0 ± 8.6	0.24 ± 1.21

Premedication capsule endoscopy was completed, and subjects who dropped out in subsequent studies were included.

correlated with BMI. In many reports, it has been reported that obese people have different intestinal flora compared to those with proper weight. Additionally, specific bacteria, which are predominantly present in obese people, cause tight junctions in the intestinal tract to malfunction allowing bacterial products to pass through the intestinal wall[6]. The results of the analysis are considered to support this idea. High-fat diet also affects gut flora[7]. In addition, blood flow disorders due to arteriosclerosis and lack of exercise may be involved.

In addition, small intestinal mucosal breaks was higher in *H. pylori*-infected subjects. We do not consider *H. pylori*-infected subjects to be completely healthy individuals, so *H. pylori* infection was investigated prior to the capsule endoscopy study to evenly distribute *H. pylori*-infected subjects between the two groups in our previous study[5]. The results of this study support the idea that *H. pylori* infection also affects the small intestine. Currently, it is easy to understand that the reason why *H. pylori*-infected individuals have many small intestinal mucosal breaks is that *H. pylori* infection causes atrophic gastritis, which is caused by changes in the intestinal flora due to a decrease in gastric acid concentration. Experimental reports of exacerbation of NSAID ulcers by administration of proton pump inhibitors (PPIs) are widely known[8]. Since the bacterial cell components and bacterial products of *H. pylori* flow in the lumen of the small intestine and their involvement is doubtful, such examination may be necessary in the future.

Table 3 Analysis of mucosal breaks and background factors

Valuable	Mucosal break + (n = 21)	Mucosal break – (n = 201)	P value ¹	P value ²
Sex	Male/female: 19/2	Male/female: 129/72	0.015	0.13
Age	44.0 ± 6.7	45.2 ± 8.8	0.54	
BMI	24.7 ± 3.6	22.5 ± 3.0	0.022	0.0074
Smoking	5 (23.8%)	56 (27.9%)	0.69	
Drinking	14 (66.7%)	140 (70.0%)	0.78	
<i>Helicobacter pylori</i>	8 (38.1%)	13 (6.4%)	0.054	0.035

¹Sex, smoking, alcohol consumption, and *Helicobacter pylori* were analyzed by the chi-square test, and age and body mass index were analyzed by the Mann-Whitney U test.

²P value by logistic multivariate analysis. BMI: Body mass index.

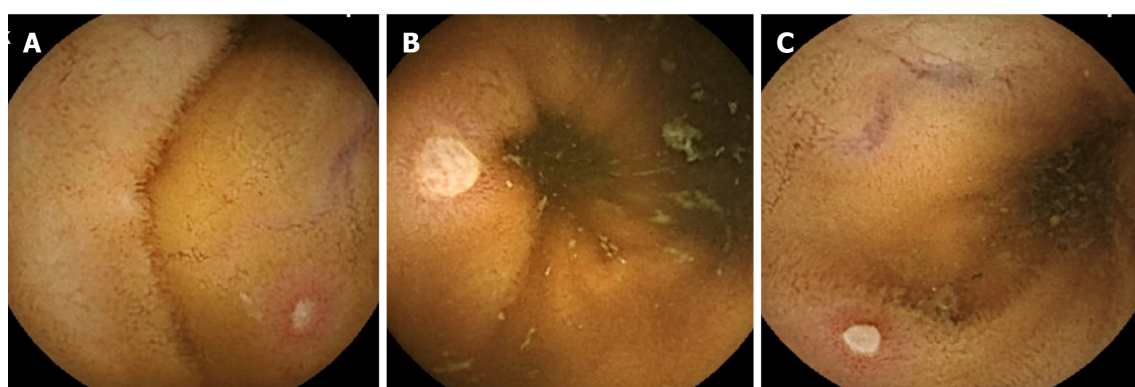


Figure 1 Endoscopic findings of small intestinal mucosal breaks. A: Erosion with white slough of approximately 3 mm; B: Ulcer with white slough of approximately 7 mm; C: The white slough is approximately 5 mm, and opinions of evaluation are divided by researchers.

In addition, small intestinal mucosal breaks tended to be higher in men. We were doubtful that smoking and alcohol consumption were related to mucosal breaks and no relationship was found between them in the analysis. CD is more common in men, and men may have some sex differences that are more likely to cause ulcerative lesions in the small intestine.

WHAT TO DO WITH SMALL INTESTINAL MUCOSAL BREAKS?

Any obvious ulcer should be considered abnormal. Table 4 summarizes the diseases and causes that cause small intestinal ulcers. Although it is not possible to mention the ulcer size here, it is natural to consider even one ulcer that is considered to be large or deep, such as white slough exceeding 1 cm, to be abnormal. However, what should we think of a small mucosal break with white slough up to approximately 5 mm?

As mentioned above, nearly 10% of healthy people have 1-2 small mucosal breaks. It would be physically and economically burdensome to follow-up with a capsule endoscopy for a person with a small number of asymptomatic mucosal breaks. Among the subjects examined in this study (Table 2), there were 3 male subjects with 5 or more mucosal breaks, but it was only confirmed at the end of the study that there were no abnormal symptoms or abnormal blood data. On the other hand, there is a case report in which a PPI was administered to a patient who had 6 mucosal breaks by capsule endoscopy before the study, and an increase in mucosal breaks was confirmed[9]. No abnormalities were found in this subject at a follow-up examination 2 years after the study.

If 3 or more small mucosal breaks are found in the small intestine, it is considered to exceed ± 2 SD on average and should be judged to be out of the normal range. There is a possibility that some of these asymptomatic lesions may develop into other diseases, such as CD, but there are few reports at this time, and there is not enough information

Table 4 Disease and/or cause of small intestinal ulcer with multiple reports

Category	Disease and/or cause	Ref.
Inflammatory disease	Crohn's disease	Gomollón <i>et al</i> [3], 2017
	Behçet's disease	Lee <i>et al</i> [23], 2012
	polyarteritis nodosa	Perlemuter <i>et al</i> [24], 1996
	Schönlein-Henoch purpura	Nishiyama <i>et al</i> [25], 2008
Vascular disease	Ischemic enteritis	Iwai <i>et al</i> [26], 2018
Systemic disease	Amyloidosis	Tada <i>et al</i> [27], 1994
Hereditary disease	Chronic enteropathy associated with <i>SLCO2A1</i> gene	Umeno <i>et al</i> [28], 2015
Bacterial infection	<i>Yersinia enterocolitica</i>	Matsumoto <i>et al</i> [29], 1990
	<i>Campylobacter jejuni</i>	Duffy <i>et al</i> [30], 1980
	<i>Salmonella typhi</i>	Goel <i>et al</i> [31], 2017
	<i>Salmonella typhimurium</i>	Boyd[32], 1985
	<i>Salmonella enteritidis</i>	Dworkin <i>et al</i> [33], 2001
	<i>Mycobacterium tuberculosis</i>	Lu <i>et al</i> [34], 2020
Viral infection	Epstein-Barr virus	Watanabe <i>et al</i> [35], 2020
	Cytomegalovirus	Matsumura <i>et al</i> [36], 2020
	COVID-19	Sahu <i>et al</i> [37], 2021
Drug induced	Various drugs included NSAIDs	Scarpignato and Bjarnason[38], 2019
Immunodeficiency	Acquired immunodeficiency syndrome	Zeitz <i>et al</i> [39], 1998
	Graft-versus-host disease	Peled <i>et al</i> [40], 2016

Reference searched as much as possible for new, review, and important ones. COVID-19: Coronavirus disease-2019; NSAID: Nonsteroidal anti-inflammatory drugs.

to consider follow-up guidelines. Considering the financial and physical burden of capsule endoscopy, it cannot be stated in detail how many mucosal breaks warrant followed-up, so presently the decision is left to each medical professional. Therefore, we think it is appropriate to perform a re-examination with a capsule endoscopy, *etc.*, when anemia or similar symptoms appear during follow-up at a normal health examination.

CONCLUSION

Based on this analysis, approximately 10% of healthy individuals have small intestinal mucosal breaks, and high BMI, *H. pylori*-infected individuals, and men are more likely to present with mucosal breaks. When up to 2 small mucosal breaks of 5 mm or less are found, this is considered to be within the normal range; therefore, asymptomatic persons with mucosal breaks could be followed up at a normal annual health examination. When a person has 3 or more small mucosal breaks, it is considered to be out of the normal range, but presently a follow-up schedule cannot be considered due to insufficient information. Nevertheless, when there is no significant number of mucosal breaks, follow-up should be carried out at a normal medical examination, and if anemia occurs, a close examination policy is sufficient. When a patient has an obvious ulcer, abnormality exists; therefore, close examination is desired. However, there is not enough information at this time to consider how to treat asymptomatic small intestinal ulcers.

We also hope that it should be clarified in future whether *H. pylori* and BMI really affect small intestinal ulcerative lesions in healthy subjects. 16s rRNA or metabolite sequencing of the intestinal flora between *H. pylori*-infected and uninfected as well as between high- and low-BMI assess whether small intestinal ulcerative lesions correlate with changes in the microbial flora. These researches such as comparing the intestinal

flora of objects is considered necessary. Future studies are required to address this issue.

ACKNOWLEDGEMENTS

I would like to thank the individuals who coauthored the manuscripts referenced in this paper with me and the research assistants who helped with those studies.

REFERENCES

- Sorrentino D**, Avellini C, Geraci M, Vadalà S. Pre-clinical Crohn's disease: diagnosis, treatment and six year follow-up. *J Crohns Colitis* 2014; **8**: 702-707 [PMID: [24411923](#) DOI: [10.1016/j.crohns.2013.12.008](#)]
- Bezzio C**, Manes G, Schettino M, Arena I, de Nucci G, Della Corte C, Devani M, Mandelli E, Morganti D, Omazzi B, Pellegrini L, Picascia D, Redaelli D, Reati R, Saibeni S. Inflammatory bowel disease in a colorectal cancer screening population: Diagnosis and follow-up. *Dig Liver Dis* 2021; **53**: 587-591 [PMID: [32863160](#) DOI: [10.1016/j.dld.2020.07.036](#)]
- Gomollón F**, Dignass A, Annese V, Tilg H, Van Assche G, Lindsay JO, Peyrin-Biroulet L, Cullen GJ, Daperno M, Kucharzik T, Rieder F, Almer S, Armuzzi A, Harbord M, Langhorst J, Sans M, Chowers Y, Fiorino G, Juillerat P, Mantzaris GJ, Rizzello F, Vavricka S, Gionchetti P; ECCO. 3rd European Evidence-based Consensus on the Diagnosis and Management of Crohn's Disease 2016: Part 1: Diagnosis and Medical Management. *J Crohns Colitis* 2017; **11**: 3-25 [PMID: [27660341](#) DOI: [10.1093/ecco-jcc/jjw168](#)]
- Fujimori S**, Takahashi Y, Gudis K, Seo T, Ehara A, Kobayashi T, Mitsui K, Yonezawa M, Tanaka S, Tatsuguchi A, Sakamoto C. Rebamipide has the potential to reduce the intensity of NSAID-induced small intestinal injury: a double-blind, randomized, controlled trial evaluated by capsule endoscopy. *J Gastroenterol* 2011; **46**: 57-64 [PMID: [20924615](#) DOI: [10.1007/s00535-010-0332-3](#)]
- Fujimori S**, Hanada R, Hayashida M, Sakurai T, Ikushima I, Sakamoto C. Celecoxib Monotherapy Maintained Small Intestinal Mucosa Better Compared With Loxoprofen Plus Lansoprazole Treatment: A Double-blind, Randomized, Controlled Trial. *J Clin Gastroenterol* 2016; **50**: 218-226 [PMID: [26166140](#) DOI: [10.1097/MCG.0000000000000372](#)]
- Dabke K**, Hendrick G, Devkota S. The gut microbiome and metabolic syndrome. *J Clin Invest* 2019; **129**: 4050-4057 [PMID: [31573550](#) DOI: [10.1172/JCI129194](#)]
- Zhang M**, Yang XJ. Effects of a high fat diet on intestinal microbiota and gastrointestinal diseases. *World J Gastroenterol* 2016; **22**: 8905-8909 [PMID: [27833381](#) DOI: [10.3748/wjg.v22.i40.8905](#)]
- Wallace JL**, Syer S, Denou E, de Palma G, Vong L, McKnight W, Jury J, Bolla M, Bercik P, Collins SM, Verdu E, Ongini E. Proton pump inhibitors exacerbate NSAID-induced small intestinal injury by inducing dysbiosis. *Gastroenterology* 2011; **141**: 1314-1322.e1-1322.e5 [PMID: [21745447](#) DOI: [10.1053/j.gastro.2011.06.075](#)]
- Fujimori S**, Takahashi Y, Tatsuguchi A, Sakamoto C. Omeprazole increased small intestinal mucosal injury in two of six disease-free cases evaluated by capsule endoscopy. *Dig Endosc* 2014; **26**: 676-679 [PMID: [25383403](#) DOI: [10.1111/den.12188](#)]
- Goldstein JL**, Eisen GM, Lewis B, Gralnek IM, Zlotnick S, Fort JG; Investigators. Video capsule endoscopy to prospectively assess small bowel injury with celecoxib, naproxen plus omeprazole, and placebo. *Clin Gastroenterol Hepatol* 2005; **3**: 133-141 [PMID: [15704047](#) DOI: [10.1016/s1542-3565\(04\)00619-6](#)]
- Goldstein JL**, Eisen GM, Lewis B, Gralnek IM, Aisenberg J, Bhadra P, Berger MF. Small bowel mucosal injury is reduced in healthy subjects treated with celecoxib compared with ibuprofen plus omeprazole, as assessed by video capsule endoscopy. *Aliment Pharmacol Ther* 2007; **25**: 1211-1222 [PMID: [17451567](#) DOI: [10.1111/j.1365-2036.2007.03312.x](#)]
- Fujimori S**, Seo T, Gudis K, Ehara A, Kobayashi T, Mitsui K, Yonezawa M, Tanaka S, Tatsuguchi A, Sakamoto C. Prevention of nonsteroidal anti-inflammatory drug-induced small-intestinal injury by prostaglandin: a pilot randomized controlled trial evaluated by capsule endoscopy. *Gastrointest Endosc* 2009; **69**: 1339-1346 [PMID: [19243767](#) DOI: [10.1016/j.gie.2008.08.017](#)]
- Smeciol E**, Pinto Sanchez ML, Suarez A, Argonz JE, Sugai E, Vazquez H, Litwin N, Piazzuelo E, Meddings JB, Bai JC, Lanas A. Low-dose aspirin affects the small bowel mucosa: results of a pilot study with a multidimensional assessment. *Clin Gastroenterol Hepatol* 2009; **7**: 524-529 [PMID: [19249402](#) DOI: [10.1016/j.cgh.2008.12.019](#)]
- Shiotani A**, Haruma K, Nishi R, Fujita M, Kamada T, Honda K, Kusunoki H, Hata J, Graham DY. Randomized, double-blind, pilot study of geranylgeranylacetone versus placebo in patients taking low-dose enteric-coated aspirin. Low-dose aspirin-induced small bowel damage. *Scand J Gastroenterol* 2010; **45**: 292-298 [PMID: [19968611](#) DOI: [10.3109/00365520903453182](#)]
- Kuramoto T**, Umegaki E, Nouda S, Narabayashi K, Kojima Y, Yoda Y, Ishida K, Kawakami K, Abe Y, Takeuchi T, Inoue T, Murano M, Tokioka S, Higuchi K. Preventive effect of irsogladine or omeprazole on non-steroidal anti-inflammatory drug-induced esophagitis, peptic ulcers, and small

- intestinal lesions in humans, a prospective randomized controlled study. *BMC Gastroenterol* 2013; **13**: 85 [PMID: [23672202](#) DOI: [10.1186/1471-230X-13-85](#)]
- 16 **Huang C**, Lu B, Fan YH, Zhang L, Jiang N, Zhang S, Meng LN. Muscovite is protective against non-steroidal anti-inflammatory drug-induced small bowel injury. *World J Gastroenterol* 2014; **20**: 11012-11018 [PMID: [25152605](#) DOI: [10.3748/wjg.v20.i31.11012](#)]
 - 17 **Umegaki E**, Kuramoto T, Kojima Y, Nouda S, Ishida K, Takeuchi T, Inoue T, Tokioka S, Higuchi K. Geranylgeranylacetone, a gastromucoprotective drug, protects against NSAID-induced esophageal, gastroduodenal and small intestinal mucosal injury in healthy subjects: A prospective randomized study involving a comparison with famotidine. *Intern Med* 2014; **53**: 283-290 [PMID: [24531083](#) DOI: [10.2169/internalmedicine.53.1572](#)]
 - 18 **Kojima Y**, Takeuchi T, Ota K, Harada S, Edogawa S, Narabayashi K, Nouda S, Okada T, Kakimoto K, Kuramoto T, Inoue T, Higuchi K. Effect of long-term proton pump inhibitor therapy and healing effect of irsogladine on nonsteroidal anti-inflammatory drug-induced small-intestinal lesions in healthy volunteers. *J Clin Biochem Nutr* 2015; **57**: 60-65 [PMID: [26236102](#) DOI: [10.3164/jcbs.15-32](#)]
 - 19 **Tacheci I**, Bradna P, Douda T, Baštecká D, Kopáčová M, Rejchrt S, Lutonský M, Soukup T, Bureš J. Wireless Capsule Enteroscopy in Healthy Volunteers. *Acta Medica (Hradec Kralove)* 2016; **59**: 79-83 [PMID: [27639097](#) DOI: [10.14712/18059694.2016.93](#)]
 - 20 **Arimoto J**, Endo H, Kato T, Umezawa S, Fuyuki A, Uchiyama S, Higurashi T, Ohkubo H, Nonaka T, Takeno M, Ishigatsubo Y, Sakai E, Matsuhashi N, Nakajima A. Clinical value of capsule endoscopy for detecting small bowel lesions in patients with intestinal Behçet's disease. *Dig Endosc* 2016; **28**: 179-185 [PMID: [26459917](#) DOI: [10.1111/den.12552](#)]
 - 21 **Ota K**, Takeuchi T, Nouda S, Ozaki H, Kawaguchi S, Takahashi Y, Harada S, Edogawa S, Kojima Y, Kuramoto T, Higuchi K. Determination of the adequate dosage of rebamipide, a gastric mucoprotective drug, to prevent low-dose aspirin-induced gastrointestinal mucosal injury. *J Clin Biochem Nutr* 2016; **59**: 231-237 [PMID: [27895392](#) DOI: [10.3164/jcbs.16-49](#)]
 - 22 **Ota K**, Takeuchi T, Kojima Y, Harada S, Hirata Y, Sugawara N, Nouda S, Kakimoto K, Kuramoto T, Higuchi K. Preventive effect of ecabet sodium on low-dose aspirin-induced small intestinal mucosal injury: a randomized, double-blind, pilot study. *BMC Gastroenterol* 2019; **19**: 4 [PMID: [30621622](#) DOI: [10.1186/s12876-018-0923-7](#)]
 - 23 **Lee HJ**, Kim YN, Jang HW, Jeon HH, Jung ES, Park SJ, Hong SP, Kim TI, Kim WH, Nam CM, Cheon JH. Correlations between endoscopic and clinical disease activity indices in intestinal Behçet's disease. *World J Gastroenterol* 2012; **18**: 5771-5778 [PMID: [23155319](#) DOI: [10.3748/wjg.v18.i40.5771](#)]
 - 24 **Perlemuter G**, Chaussade S, Soubrane O, Degoy A, Louvel A, Barbet P, Legman P, Kahan A, Weiss L, Couturier D. Multifocal stenosing ulcerations of the small intestine revealing vasculitis associated with C2 deficiency. *Gastroenterology* 1996; **110**: 1628-1632 [PMID: [8613071](#) DOI: [10.1053/gast.1996.v110.pm8613071](#)]
 - 25 **Nishiyama R**, Nakajima N, Ogihara A, Oota S, Kobayashi S, Yokoyama K, Oonishi M, Miyamoto S, Akai Y, Watanabe T, Uno A, Mizuno S, Ootani T, Tanaka N, Moriyama M. Endoscope images of Schönlein-Henoch purpura. *Digestion* 2008; **77**: 236-241 [PMID: [18688168](#) DOI: [10.1159/000150697](#)]
 - 26 **Iwai N**, Handa O, Naito Y, Dohi O, Okayama T, Yoshida N, Kamada K, Uchiyama K, Ishikawa T, Takagi T, Konishi H, Itoh Y. Stenotic Ischemic Enteritis with Concomitant Hepatic Portal Venous Gas and Pneumatosis Cystoides Intestinalis. *Intern Med* 2018; **57**: 1995-1999 [PMID: [29491303](#) DOI: [10.2169/internalmedicine.0367-17](#)]
 - 27 **Tada S**, Iida M, Yao T, Kawakubo K, Okada M, Fujishima M. Endoscopic features in amyloidosis of the small intestine: clinical and morphologic differences between chemical types of amyloid protein. *Gastrointest Endosc* 1994; **40**: 45-50 [PMID: [8163134](#) DOI: [10.1016/s0016-5107\(94\)70008-7](#)]
 - 28 **Umeno J**, Hisamatsu T, Esaki M, Hirano A, Kubokura N, Asano K, Kochi S, Yanai S, Fuyuno Y, Shimamura K, Hosoe N, Ogata H, Watanabe T, Aoyagi K, Ooi H, Watanabe K, Yasukawa S, Hirai F, Matsui T, Iida M, Yao T, Hibi T, Kosaki K, Kanai T, Kitazono T, Matsumoto T. A Hereditary Enteropathy Caused by Mutations in the SLCO2A1 Gene, Encoding a Prostaglandin Transporter. *PLoS Genet* 2015; **11**: e1005581 [PMID: [26539716](#) DOI: [10.1371/journal.pgen.1005581](#)]
 - 29 **Matsumoto T**, Iida M, Matsui T, Sakamoto K, Fuchigami T, Haraguchi Y, Fujishima M. Endoscopic findings in *Yersinia enterocolitica* enterocolitis. *Gastrointest Endosc* 1990; **36**: 583-587 [PMID: [2279647](#) DOI: [10.1016/s0016-5107\(90\)71169-8](#)]
 - 30 **Duffy MC**, Benson JB, Rubin SJ. Mucosal invasion in campylobacter enteritis. *Am J Clin Pathol* 1980; **73**: 706-708 [PMID: [7377140](#) DOI: [10.1093/ajcp/73.5.706](#)]
 - 31 **Goel A**, Bansal R. Massive Lower Gastrointestinal Bleed caused by Typhoid Ulcer: Conservative Management. *Euroasian J Hepatogastroenterol* 2017; **7**: 176-177 [PMID: [29201803](#) DOI: [10.5005/jp-journals-10018-1242](#)]
 - 32 **Boyd JF**. Pathology of the alimentary tract in *Salmonella typhimurium* food poisoning. *Gut* 1985; **26**: 935-944 [PMID: [3896961](#) DOI: [10.1136/gut.26.9.935](#)]
 - 33 **Dworkin MS**, Shoemaker PC, Goldoft MJ, Kobayashi JM. Reactive arthritis and Reiter's syndrome following an outbreak of gastroenteritis caused by *Salmonella enteritidis*. *Clin Infect Dis* 2001; **33**: 1010-1014 [PMID: [11528573](#) DOI: [10.1086/322644](#)]
 - 34 **Lu S**, Fu J, Guo Y, Huang J. Clinical diagnosis and endoscopic analysis of 10 cases of intestinal tuberculosis. *Medicine (Baltimore)* 2020; **99**: e21175 [PMID: [32664157](#) DOI: [10.1093/med/99.12.21175](#)]

- 10.1097/MD.00000000000021175]
- 35 **Watanabe H**, Yamazaki Y, Fujishima F, Ohashi Y, Imoto H, Sasano H. Epstein-Barr virus-associated enteritis with multiple ulcers: The first autopsy case. *Pathol Int* 2020; **70**: 899-905 [PMID: 32894806 DOI: 10.1111/pin.13013]
- 36 **Matsumura M**, Komeda Y, Watanabe T, Kudo M. Purpura-free small intestinal IgA vasculitis complicated by cytomegalovirus reactivation. *BMJ Case Rep* 2020; **13** [PMID: 32636227 DOI: 10.1136/bcr-2020-235042]
- 37 **Sahu T**, Mehta A, Ratre YK, Jaiswal A, Vishvakarma NK, Bhaskar LVKS, Verma HK. Current understanding of the impact of COVID-19 on gastrointestinal disease: Challenges and openings. *World J Gastroenterol* 2021; **27**: 449-469 [PMID: 33642821 DOI: 10.3748/wjg.v27.i6.449]
- 38 **Scarpignato C**, Bjarnason I. Drug-Induced Small Bowel Injury: a Challenging and Often Forgotten Clinical Condition. *Curr Gastroenterol Rep* 2019; **21**: 55 [PMID: 31720893 DOI: 10.1007/s11894-019-0726-1]
- 39 **Zeitz M**, Ullrich R, Schneider T, Kewenig S, Hohloch K, Riecken EO. HIV/SIV enteropathy. *Ann N Y Acad Sci* 1998; **859**: 139-148 [PMID: 9928377 DOI: 10.1111/j.1749-6632.1998.tb11118.x]
- 40 **Peled JU**, Hanash AM, Jenq RR. Role of the intestinal mucosa in acute gastrointestinal GVHD. *Blood* 2016; **128**: 2395-2402 [PMID: 27856471 DOI: 10.1182/blood-2016-06-716738]



Published by **Baishideng Publishing Group Inc**
7041 Koll Center Parkway, Suite 160, Pleasanton, CA 94566, USA

Telephone: +1-925-3991568

E-mail: bpgoffice@wjgnet.com

Help Desk: <https://www.f6publishing.com/helpdesk>

<https://www.wjgnet.com>

