

国内版国际版

Microsoft Bing

Is arthroscopic removal an effective treatment option for intra-artic

Chat with Bing

ALLIMAGESVIDEOS

37,000 ResultsAny time

Arthroscopic Excision of Juxta-articular Osteoid Osteoma ...

<https://www.ncbi.nlm.nih.gov/pmc/articles/PMC4810876>

Arthroscopic excision of intra-articular osteoid osteoma has been gaining popularity in recent times, with a greater number of cases being reported. A study published recently claimed to be the largest case series on arthroscopic treatment of osteoid osteoma of the ankle, comprising 9 cases, with 3 cases of osteoid osteoma in the distal tibia ...

Cited by: 3Author: Mohammed Tauheed, Ravi Jacob Korula,...

Publish Year: 2016

Arthroscopic removal of juxtaarticular osteoid osteoma of ...

<https://www.ncbi.nlm.nih.gov/pubmed/17628786>

Osteoid osteoma

Benign Bone Tumor

An osteoid osteoma is a benign bone tumor that arises from osteoblasts and some components of osteoclasts. It was originally thought to be a smaller version of an osteoblastoma. Osteoid osteomas tend to be less than 1.5 cm in size. The tumor can be in any bone in the body but are most common in long bones, such as the femur and tibia. They account for 10 to 12 percent of all bone tumors.

Arthroscopic removal of an intra-articular osteoid osteoma ...<https://www.ncbi.nlm.nih.gov/pubmed/22015076>

Arthroscopic removal of an intra-articular osteoid osteoma of the radial styloid. Nishio J(1), Ishiko T, Minamikawa T, Naito M. Author information: (1)Department of Orthopaedic Surgery, Faculty of Medicine, Fukuoka University, Fukuoka, Japan. jnishio@cis.fukuoka-u.ac.jp

Cited by: 3

Author: Jun Nishio, Toshiyuki Ishiko, Tomohiko Mi...

Publish Year: 2012

Arthroscopic removal of intra-articular osteoid osteoma in ...<https://www.ncbi.nlm.nih.gov/pubmed/21431904>

Arthroscopic removal of intra-articular osteoid osteoma in the knee: case report and review of the literature. Furukawa M(1), Anazawa U, Horiuchi K, Yabe H, Morioka H, Mukai M, Toyoda T, Chiba K, Mori T, Shiraishi T, Toyama Y.

Cited by: 7

Author: Mitsuru Furukawa, Ukei Anazawa, Keisu...

Publish Year: 2011

Clinical presentation of intra-articular osteoid osteoma ...<https://pubmed.ncbi.nlm.nih.gov/29423256>

Intra-articular osteoid osteoma (IAOO) of the hip is a relatively rare diagnosis, but one that can closely mimic symptomatic presentation of femoroacetabular impingement (FAI). Although there are multiple case reports of osteoid osteoma (OO) in the hip, we present the largest case series of hip IAOO ...

Cited by: 7

Author: Andrea M Spiker, Ben-Zion Rotter, Brend...

Publish Year: 2018

Arthroscopic removal of intra-articular osteoid osteoma in ...<https://www.researchgate.net/publication/50833227...>

... 4 Multiple articles report arthroscopic removal of intra-articular osteoid osteomas. Several methods have been described whereby osteoid osteomas may be treated percutaneously using CT...

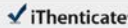
Arthroscopic removal of juxtaarticular osteoid osteoma of ...<https://www.researchgate.net/publication/6208997...>

In order to remove these lesions, we performed a CT-guided en block retrograde resection under

09 Jul 2021 11:43 AM

4726 words • 6 matches • 3 sources

ENG



64016_Auto_Edited.docx

Quotes Excluded
Bibliography Excluded

3%

Name of Journal: *World Journal of Orthopedics*

Manuscript NO: 64016

Manuscript Type: ORIGINAL ARTICLE

Observational Study

Arthroscopic removal as an effective treatment option for intra-articular osteoid osteoma of the knee

Plečko M *et al.* Arthroscopic removal of knee osteoid osteoma

Mihovil Plečko, Alan Mahnik, Damjan Dimnjaković, Ivan Bojanić

Abstract

BACKGROUND

Intra-articular osteoid osteoma (iaOO) can be found in 5.2% up to 10% of cases. They

Match Overview

1

Internet 31 words
created on 19-Jul-2020
[www.sjgnet.com](#)

1%

2

Internet 25 words
created on 19-Feb-2020
[kraljic.scribbr](#)

1%

3

Internet 21 words
created on 25-Sep-2014
[eLibrary.com](#)

1%

PDF 1 OF 28

Full

Text Copy Report

国内版

国际版

Arthroscopic removal as an effective treatment option for intra-art



ALL

IMAGES

VIDEOS

9,910 Results

Any time ▾

Arthroscopic removal of juxtaarticular osteoid osteoma of ...

<https://www.ncbi.nlm.nih.gov/pubmed/17628786>

Post-operatively, the patient reported prompt relief of pain that had not reoccurred during 1 year of follow up. To the authors' knowledge, this is the first report of the **arthroscopic removal** of juxtaarticular **osteoid osteoma** of the humeral capitulum which promises to be an **effective** and less invasive alternative to the existing **treatment options**.

Cited by: 19

Author: Oskar Zupanc, Nejc Šarabon, Klemen Str...

Publish Year: 2007

Arthroscopic removal of an osteoid osteoma of the ...

<https://www.ncbi.nlm.nih.gov/pmc/articles/PMC3159752>

Mar 29, 2011 · After identifying the **osteoid osteoma** close to the cartilage with MRI and CT investigations, we decided that in this case, **arthroscopic removal** was the **best treatment**. In the case of an **osteoid osteoma** in the acetabulum close to the cartilage, **arthroscopic removal** should be considered as one can treat the associated osteochondritic lesion ...

Cited by: 15

Author: Renske Barnhard, Eric E. J. Raven

Publish Year: 2011

Arthroscopic removal of intra-articular osteoid osteoma in ...

<https://link.springer.com/article/10.1007/s00776-011-0060-4> ▾

Mar 24, 2011 · The treatments for osteoid osteoma in the knee joint include open surgery [5, 7, 8], open surgery with cryoablation, CT-guided radio-frequency ablation (RFA), CT-guided curette [9, 11], and arthroscopic resection [12–14] (Table 1). Pain relief was immediate upon removal of the lesion in all cases in the literature, and there was no apparent difference in the clinical outcome irrespective of the ...

Cited by: 7

Author: Mitsuru Furukawa, Ukei Anazawa, Keisu...

Publish Year: 2011

Arthroscopic Excision of Intra-articular Osteoid Osteoma ...

<https://www.sciencedirect.com/science/article/pii/S0749806321003261>

Apr 16, 2021 · For revision cases, there are usually varying degrees of joint degeneration. **Arthroscopic resection** sometimes needs to start from the peripheral compartment. **Arthroscopic resection** is an effective treatment method for **hip OO**. **Options** for treatment of **hip OO** include open excision, CT-guided RFA or laser ablation, and **arthroscopic excision**.