

World Journal of *Clinical Oncology*

World J Clin Oncol 2021 October 24; 12(10): 833-965



Contents

Monthly Volume 12 Number 10 October 24, 2021

EVIDENCE REVIEW

- 833 Postoperative radiotherapy in resected non-small cell lung cancer: The never-ending story
Serrano J, Crespo PC, Taboada B, Gonzalez AA, García RG, Caamaño AG, Reyes JCT, Mielgo-Rubio X, Couñago F

REVIEW

- 845 Relationship between Th17 immune response and cancer
Marques HS, de Brito BB, da Silva FAF, Santos MLC, de Souza JCB, Correia TML, Lopes LW, Neres NSM, Dórea RSDM, Dantas ACS, Morbeck LLB, Lima IS, de Almeida AA, Dias MRJ, de Melo FF

MINIREVIEWS

- 868 Human epidermal growth factor receptor 2 targeted therapy in endometrial cancer: Clinical and pathological perspectives
Saito A, Yoshida H, Nishikawa T, Yonemori K
- 882 Role of lenalidomide in the treatment of peripheral T-cell non-Hodgkin lymphomas
Cencini E, Fabbri A, Mecacci B, Bocchia M
- 897 Current update on imaging for pancreatic neuroendocrine neoplasms
Segaran N, Devine C, Wang M, Ganeshan D
- 912 Recent advances and new insights in the management of early-stage epidermal growth factor receptor-mutated non-small-cell lung cancer
Sotelo MJ, Luis García J, Torres-Mattos C, Milián H, Carracedo C, González-Ruiz MÁ, Mielgo-Rubio X, Trujillo-Reyes JC, Couñago F

ORIGINAL ARTICLE

Retrospective Study

- 926 A biomarker study in Peruvian males with breast cancer
Castaneda CA, Castillo M, Bernabe LA, Sanchez J, Torres E, Suarez N, Tello K, Fuentes H, Dunstan J, De La Cruz M, Cotrina JM, Abugattas J, Guerra H, Gomez HL
- 935 Jejunostomy in the palliative treatment of gastric cancer: A clinical prognostic score
Ramos MFKP, Pereira MA, Dias AR, Sakamoto E, Ribeiro Jr U, Zilberstein B, Nahas SC

Observational Study

- 947 Novel molecular panel for evaluating systemic inflammation and survival in therapy naïve glioma patients
Gandhi P, Shrivastava R, Garg N, Sorte SK

CASE REPORT

- 960** Gastric myeloid sarcoma: A case report

Rioja P, Macetas J, Luna-Abanto J, Tirado-Hurtado I, Enriquez DJ

ABOUT COVER

Editorial Board Member of *World Journal of Clinical Oncology*, Elizabeth Ortiz-Sánchez, PhD, MD, Principal Investigator, Subdirección de Investigación Básica, Instituto Nacional de Cancerología, Av San Fernando 22, Sección XVI, Tlalpan 14080, Mexico City, Mexico. elinfkb@yahoo.com.mx

AIMS AND SCOPE

The primary aim of *World Journal of Clinical Oncology* (WJCO, *World J Clin Oncol*) is to provide scholars and readers from various fields of oncology with a platform to publish high-quality basic and clinical research articles and communicate their research findings online.

WJCO mainly publishes articles reporting research results and findings obtained in the field of oncology and covering a wide range of topics including art of oncology, biology of neoplasia, breast cancer, cancer prevention and control, cancer-related complications, diagnosis in oncology, gastrointestinal cancer, genetic testing for cancer, gynecologic cancer, head and neck cancer, hematologic malignancy, lung cancer, melanoma, molecular oncology, neurooncology, palliative and supportive care, pediatric oncology, surgical oncology, translational oncology, and urologic oncology.

INDEXING/ABSTRACTING

The WJCO is now abstracted and indexed in PubMed, PubMed Central, Emerging Sources Citation Index (Web of Science), China National Knowledge Infrastructure (CNKI), China Science and Technology Journal Database (CSTJ), and Superstar Journals Database. The 2021 edition of Journal Citation Reports® cites the 2020 Journal Citation Indicator (JCI) for WJCO as 0.48.

RESPONSIBLE EDITORS FOR THIS ISSUE

Production Editor: Ying-Yi Yuan; Production Department Director: Yu-Jie Ma; Editorial Office Director: Ze-Mao Gong.

NAME OF JOURNAL

World Journal of Clinical Oncology

ISSN

ISSN 2218-4333 (online)

LAUNCH DATE

November 10, 2010

FREQUENCY

Monthly

EDITORS-IN-CHIEF

Hiten RH Patel, Stephen Safe

EDITORIAL BOARD MEMBERS

<https://www.wjnet.com/2218-4333/editorialboard.htm>

PUBLICATION DATE

October 24, 2021

COPYRIGHT

© 2021 Baishideng Publishing Group Inc

INSTRUCTIONS TO AUTHORS

<https://www.wjnet.com/bpg/gerinfo/204>

GUIDELINES FOR ETHICS DOCUMENTS

<https://www.wjnet.com/bpg/GerInfo/287>

GUIDELINES FOR NON-NATIVE SPEAKERS OF ENGLISH

<https://www.wjnet.com/bpg/gerinfo/240>

PUBLICATION ETHICS

<https://www.wjnet.com/bpg/GerInfo/288>

PUBLICATION MISCONDUCT

<https://www.wjnet.com/bpg/gerinfo/208>

ARTICLE PROCESSING CHARGE

<https://www.wjnet.com/bpg/gerinfo/242>

STEPS FOR SUBMITTING MANUSCRIPTS

<https://www.wjnet.com/bpg/GerInfo/239>

ONLINE SUBMISSION

<https://www.f6publishing.com>



Role of lenalidomide in the treatment of peripheral T-cell non-Hodgkin lymphomas

Emanuele Cencini, Alberto Fabbri, Bianca Mecacci, Monica Bocchia

ORCID number: Emanuele Cencini 0000-0002-0432-9706; Alberto Fabbri 0000-0003-2603-9715; Bianca Mecacci 0000-0002-9762-8843; Monica Bocchia 0000-0003-3538-3913.

Author contributions: Cencini E prepared the first draft of the manuscript; Fabbri A and Mecacci B contributed to reviewing and revising the manuscript; Cencini E and Bocchia M coordinated the preparation of the manuscript.

Conflict-of-interest statement: The authors declare having no conflicts of interest.

Open-Access: This article is an open-access article that was selected by an in-house editor and fully peer-reviewed by external reviewers. It is distributed in accordance with the Creative Commons Attribution NonCommercial (CC BY-NC 4.0) license, which permits others to distribute, remix, adapt, build upon this work non-commercially, and license their derivative works on different terms, provided the original work is properly cited and the use is non-commercial. See: <http://creativecommons.org/licenses/by-nc/4.0/>

Manuscript source: Invited manuscript

Emanuele Cencini, Alberto Fabbri, Bianca Mecacci, Monica Bocchia, Unit of Hematology, Azienda Ospedaliera Universitaria Senese and University of Siena, Siena 53100, Italy

Corresponding author: Emanuele Cencini, MD, PhD, Doctor, Unit of Hematology, Azienda Ospedaliera Universitaria Senese and University of Siena, Policlinico Le Scotte, viale Bracci 16, Siena 53100, Italy. emanuele.cencini@ao-siena.toscana.it

Abstract

T-cell lymphomas (TCLs) represent a group of lymphoid neoplasms characterized by an aggressive clinical course, even after an anthracycline-containing regimen. Novel agents for patients with relapsed/refractory TCL are urgently needed. Lenalidomide is an oral drug with immunomodulatory, antiangiogenic and direct antineoplastic effects. These peculiar mechanisms of action make TCL an attractive target for lenalidomide. We have identified five clinical trials in which lenalidomide monotherapy was investigated to treat TCL, including cutaneous TCL (CTCL) and adult T-cell lymphoma/leukemia (ATLL). In the ATLL-002 study, the overall response rate (ORR) was 42% and median progression-free survival (PFS) and overall survival were 3.8 mo and 20.3 mo, respectively. In a phase II trial for CTCL, ORR was 28% and median PFS and overall survival were 8 mo and 43 mo, respectively. For nodal peripheral TCL, ORR was between 10% and 43% in three clinical trials, with a median PFS of about 4 mo, even if some patients had a durable response. Overall toxicity is manageable and grade 3-4 events are mainly hematological and reversible. Combination strategies did not improve PFS. In conclusion, lenalidomide could represent a suitable treatment option for relapsed/refractory TCL, especially for neoplasms with a T-follicular helper origin, such as angioimmunoblastic TCL.

Key Words: T-cell lymphomas; Lenalidomide; Therapy; Survival; Safety; T follicular helper

©The Author(s) 2021. Published by Baishideng Publishing Group Inc. All rights reserved.

Core Tip: T cell lymphoma (TCL) are rare. Lenalidomide is an oral drug with an immunomodulatory, antiangiogenic and direct antineoplastic effect. These peculiar mechanisms of action makes TCL an attractive target for lenalidomide. We have

Specialty type: Hematology**Country/Territory of origin:** Italy**Peer-review report's scientific quality classification**

Grade A (Excellent): A

Grade B (Very good): 0

Grade C (Good): 0

Grade D (Fair): 0

Grade E (Poor): 0

Received: March 3, 2021**Peer-review started:** March 3, 2021**First decision:** July 6, 2021**Revised:** July 7, 2021**Accepted:** September 2, 2021**Article in press:** September 2, 2021**Published online:** October 24, 2021**P-Reviewer:** Somasagara RR**S-Editor:** Ma YJ**L-Editor:** A**P-Editor:** Yuan YY

identified 5 clinical trials in which lenalidomide monotherapy was investigated to treat TCL, including cutaneous TCL and adult T-cell lymphoma/leukemia. Overall response rate was between 10 % and 43%, with prolonged response in a significant proportion of cases and manageable toxicity. Lenalidomide could represent a suitable treatment option for R/R TCL, especially for neoplasms with a T-follicular helper origin, such as angioimmunoblastic TCL.

Citation: Cencini E, Fabbri A, Mecacci B, Bocchia M. Role of lenalidomide in the treatment of peripheral T-cell non-Hodgkin lymphomas. *World J Clin Oncol* 2021; 12(10): 882-896

URL: <https://www.wjgnet.com/2218-4333/full/v12/i10/882.htm>

DOI: <https://dx.doi.org/10.5306/wjco.v12.i10.882>

INTRODUCTION

Peripheral T-cell lymphomas (TCLs), including primary nodal, extranodal, leukemic and cutaneous TCL (CTCL), are a heterogeneous group of lymphoid neoplasms characterized by aggressive clinical course and poor prognosis, representing about 10%-20% of non-Hodgkin lymphoma cases[1-3]. Due to its rarity, the treatment approach has historically been similar to that used for aggressive B-cell neoplasms, such as diffuse large B-cell lymphoma (DLBCL)[3,4]. However, except for anaplastic lymphoma kinase (ALK)-positive anaplastic lymphoma (ALCL), treatment efficacy is limited compared to DLBCL, disease relapse is frequent even after high-dose therapy and autologous stem-cell transplantation, and long-term responses are seldom observed[1,5-8]. Allogeneic stem-cell transplantation often remains the only curative option, but many elderly and/or relapsed/refractory (R/R) patients are not eligible, and treatment morbidity and mortality are not negligible[9]. Novel agents approved by the Food and Drug Administration and/or the European Medicines Agency for R/R TCL, as shown in Table 1, include pralatrexate, romidepsin, belinostat, brentuximab vedotin (only for ALCL and CD30-positive CTCL) and mogamulizumab [only for mycosis fungoides and Sézary syndrome (SS)][10-14]. Additional new drugs with different mechanisms of action are listed in the National Comprehensive Cancer Network guidelines, including bortezomib, alemtuzumab, crizotinib, cyclosporine, nivolumab and lenalidomide[15]. Interestingly, several drugs work very well on a few TCL subtypes, while their efficacy is limited for the others; this allows for speculation that disease biology could influence the therapeutic response[16].

Lenalidomide is an immunomodulatory drug initially approved as a treatment for patients with R/R multiple myeloma (MM)[17]. It was successfully used to treat myelodysplastic syndromes, chronic lymphocytic leukemia and R/R B-cell non-Hodgkin lymphoma, including DLBCL, mantle-cell lymphoma and follicular lymphoma[18-22]. Due to its peculiar mechanisms of action, TCL could represent an attractive target for lenalidomide; however, available data are limited[4,14]. According to this background, we would like to briefly summarize the pharmacological properties and to review the clinical efficacy and safety of lenalidomide monotherapy in previously treated TCL.

SEARCH CRITERIA FOR LITERATURE REVIEW

We performed a computerized search in MEDLINE to find full-text publications, in English, published to 2020, which focused on lenalidomide and TCL. We included nodal and extranodal peripheral TCL (PTCL), adult T-cell leukemia-lymphoma (ATLL) and CTCL. The key terms were "T-cell lymphoma OR TCL OR T-cell non-Hodgkin lymphoma OR mycosis fungoides (MF) OR Sézary syndrome (SS) OR cutaneous TCL OR peripheral TCL OR adult T-cell leukemia-lymphoma AND lenalidomide OR treatment OR immunotherapy OR combined modalities". We included prospective clinical trials, retrospective studies, letters to the editor and case reports. For each study, we extracted the following data, when available: number of patients, study design, patient population, treatment regimen, overall response rate (ORR), complete response (CR) rate, time to response (referred to as TTR), toxicity, and survival end-points, such as OS, PFS and duration of response (DOR). OS represents

Table 1 Clinical results of approved novel agents as monotherapy for relapsed/refractory T-cell lymphomas

Ref.	Patients, <i>n</i>	Study design	Treatment	Mechanism of action	Histology, (number of patients)	ORR	CR rate	Median PFS	Median DOR	Median OS
O'Connor <i>et al</i> [10], 2011	111	Multicenter phase II	Pralatrexate	Antifolate	Total evaluable (109) PTCL-NOS (59) ALCL (17) AITL (13) MF (12) Other (8)	29% 32% 35% 8% 25%	11% NA NA NA NA	3.5 mo	10.1 mo	14.5 mo
Coiffier <i>et al</i> [11], 2014	130	Multicenter phase II	Romidepsin	Histone deacetylase inhibitor	Total evaluable -130 PTCL-NOS (69) ALCL ALK- (21) AITL (27) Other (13)	25% 29% 24% 30% /	15% 14% 19% 19% /	4 mo	28 mo	11.3 mo
O'Connor <i>et al</i> [12], 2015	129	Multicenter phase II	Belinostat	Histone deacetylase inhibitor	Total evaluable -120 PTCL-NOS (77) ALCL ALK- (13) ALCL ALK+ (2) AITL (22) Other (6)	25.80% 23% 15% / 46% 16.60%	10.80% NA NA NA NA NA	1.6 mo	13.6 mo	7.9 mo
Pro <i>et al</i> [13], 2017	58	Multicenter phase II	Brentuximab vedotin	Monoclonal antibody anti-CD30	ALCL	86%	57%	20 mo	25.6 mo	NR (estimated 5-yr OS 60%)
Kim <i>et al</i> [14], 2018	186	Multicenter, randomized, phase III	Mogamulizumab	Monoclonal antibody anti C-C chemokine receptor 4	MF or Sézary syndrome	28%	2.70%	7.7 mo	14.1 mo	NR

AITL: Angioimmunoblastic T-cell lymphoma; ALCL: Anaplastic T-cell lymphoma; ALK: Anaplastic lymphoma kinase; CR: Complete response; DOR: Duration of response; MF: Mycosis fungoides; NA: Not available; NR: Not reached; ORR: Overall response rate; OS: Overall survival; PFS: Progression-free survival; PTCL-NOS: Peripheral T-cell lymphomas: not otherwise specified.

the most relevant outcome; PFS could be more accurate but the PFS definition has not been the same in different studies over the years. We included abstracts extracted from the last meetings of the European Hematology Association, American Society of Hematology, and International Conference on Malignant Lymphoma.

MECHANISMS OF ACTION AND PHARMACOLOGICAL CHARACTERISTICS OF LENALIDOMIDE

Lenalidomide is administered orally and rapidly adsorbed, without marked accumulation, even after multiple courses[23]. The drug is mainly excreted unchanged by renal elimination, thus a dose reduction is recommended in patients with reduced creatinine clearance due to renal impairment. Lenalidomide is characterized by an acceptable safety profile, and clinically relevant interactions with other drugs are unlikely[23].

The multiple mechanisms of action, as shown in **Figure 1**, include an immunomodulatory, antiangiogenic and direct antineoplastic effect[24]. Lenalidomide may be able to restore the function of the T-cell immune synapse and to suppress regulatory T-cells (*i.e.*, Tregs)[25,26]. Moreover, it could activate CD8-positive T-cells and favor a shift of T-helper (*i.e.*, T_H) response towards a T_H1 *vs* a T_H2 subtype[27,28]. Moreover, it could improve natural killer (NK)-mediated immune function and NK cell activation, leading to the induction of a primarily NK-mediated tumor cells apoptosis[28,29]. Moreover, lenalidomide could inhibit the production of cytokines with a pro-inflammatory activity, such as interleukin (IL)-1, IL-6, IL-12 and tumor necrosis factor- α , while the production of anti-inflammatory molecules, such as IL-10, is increased[30].

The antiangiogenic effect is achieved by blocking the migration and adhesion of endothelial cells and by inhibiting the formation of microvessels (reduced microvessels density)[28]. In mantle-cell lymphoma mouse models, the drug could cause a depletion of immune cells associated with lymphomagenesis, such as monocytes and macrophages[31]. Moreover, a direct inhibitory effect of lenalidomide on the vascular endothelial growth factor production was demonstrated and was associated with an increased SPARC expression[32,33].

The antiproliferative effect is carried out by directly inducing G1 growth arrest of the cell cycle and apoptosis[34]. A relevant discovery was represented by the identification of cereblon, a component of a cullin-RING E3 ubiquitin ligase enzyme complex, which includes the deoxyribonucleic acid damage binding protein 1, cullin 4 and the cullin regulator 1[35,36]. After the direct binding of lenalidomide, cereblon leads to the ubiquitination and subsequent degradation of the substrate proteins Aiolos (IKZF3) and Ikaros (IKZF1), which are lymphoid transcription factors, with consequent cytotoxic and immunomodulatory effects[37,38]. In DLBCL, especially nongerminal center B-cell-like DLBCL, a direct, cereblon-dependent capability of lenalidomide to kill neoplastic cells was observed, through deregulation of interferon regulatory factor 4[39]. Remarkably, the antiproliferative effect can occur in a p53-independent manner[40].

LENALIDOMIDE IN THE TREATMENT OF TCLS

ATLL

ATLL represents an uncommon neoplasm linked to the human T-lymphotropic virus type 1 infection and characterized by an aggressive course with poor prognosis[41]. Although rare in Western countries, it represents a common TCL in Japan, where human T-lymphotropic virus type 1 is endemic[41]. ATLL is subdivided into four subtypes: smoldering; chronic (often with an indolent course); lymphoma; and acute (with a very aggressive behavior)[2,41]. Anthracyclines-containing regimens, such as cyclophosphamide, doxorubicin, vincristine, prednisone (CHOP), showed limited efficacy, and most patients are refractory or relapse after an initial response[42]. R/R ATLL, due to the rarity of disease, has been frequently excluded from clinical trials investigating novel agents[42]. Ogura *et al*[43] investigated lenalidomide in relapsed ATLL or PTCL in a phase I study, in which 14 patients were enrolled. Maximum tolerated dose was 25 mg daily given continuously; out of 9 ATLL cases, 3/9 achieved a partial response (PR), leading to the design of a phase II study (ATLL-002), in which 26 relapsed or recurrent Japanese ATLL cases were enrolled[43,44]. The patients had received a median of two previous regimens (range: 1-4). Interestingly, 2 patients received lenalidomide for more than 1 year. As represented in **Table 2**, ORR was 42% (11/26 cases), with 4 CR and 1 unconfirmed CR; out of 11 responders, 2 were previously treated with mogamulizumab[44]. Median TTR, median PFS and OS were 1.9 mo, 3.8 mo and 20.3 mo, respectively, with manageable toxicity. According to disease subtype, ORR was 33% for acute ATLL and 57% for lymphoma ATLL[44]. Interestingly, in another Japanese experience, 2/4 relapsed ATLL cases after allo-stem-cell

Table 2 Clinical efficacy of lenalidomide single-agent in T-cell lymphomas

Ref.	Patient, n	Study design	Treatment	Histology (number of patients)	ORR	CR rate	Median PFS	Median DOR	Median OS
Ishida <i>et al</i> [44], 2016	26	Multicenter phase II	25 mg continuously until progression or unacceptable toxicity	ATLL (26)	42%	19%	3.8 mo	NR	20.3 mo
Querfeld <i>et al</i> [52], 2014	32	Multicenter phase II	25 mg for 21 d of a 28-d cycle; initial dose was reduced to 10 mg, with the possibility of increasing by 5 mg every cycle, until a maximum of 25 mg, until progression or up to 2 yr for SD or PR, while patients in CR received two additional cycles	Total evaluable (29) Mycosis fungoides (19) Sézary syndrome (13)	28% 36.8% 15.4%	/	8 mo	10 mo	43 mo
Zinzani <i>et al</i> [56], 2011	10	Phase II, bi-centric	25 mg for 21 d of a 28-d cycle for 4 cycles as induction phase; After the 4 th cycle, patients who achieved at least a SD continued for other eight cycles as maintenance	PTCL-NOS (10)	30%	30%	NA	13 mo	NA
Morschhauser <i>et al</i> [51], 2013	54	Multicenter phase II	25 mg on d 1-21 of a 28-d cycle, until progression or unacceptable toxicity, for a maximum of 2 yr	Total evaluable (54) AITL (26) PTCL-NOS (20) CTCL (3) ALCL (3) Cutaneous ALCL (1) Extranodal NK/T-cell, nasal type (1)	22% 31% 20% NA NA NA NA	11% 15% NA NA NA NA	2.5 mo (4.6 mo in AITL)	3.6 mo	NA
Toumshay <i>et al</i> [57], 2015	39	Multicenter phase II	25 mg daily on d 1-21 of a 28-d cycle, until progression or unacceptable toxicity	Total evaluable (39) ALCL (10) AITL (9) PTCL-NOS (14) Other (6)	26% 10% 33% 43% /	7.7% / 11.1% 14.3% /	4 mo	13 mo	12 mo

AITL: Angioimmunoblastic T-cell lymphoma; ALCL: Anaplastic T-cell lymphoma; ATLL: Adult T-cell lymphoma/leukemia; CTCL: Cutaneous T-cell lymphoma; CR: Complete response; DOR: Duration of response; NA: Not available; NK: Natural killer; NR: Not reached; OS: Overall survival; PR: Partial response; ORR: Overall response rate; PFS: Progression-free survival; PTCL-NOS: Peripheral T-cell lymphomas: Not otherwise specified; SD: Stable disease.

transplantation achieved a CR, and 1 of them showed a prolonged remission[45].

Even if these findings have not been confirmed outside Japan, lenalidomide could represent a promising option for R/R ATLL, as single-agent or in the context of combination strategies[46].

CTCLS

CTCLs are a heterogeneous group of TCL, and cell of origin is represented by skin-homing, mature, CD4-positive T_H lymphocytes[47]. MF and SS are the most common subtypes and frequently relapse after systemic therapy; R/R MF/SS are not curable and characterized by dismal prognosis[48]. Moreover, treatment toxicity is elevated after cytotoxic therapy, thus biological agents are needed to improve therapeutic efficacy with limited toxicity[47,48]. As there is a prevalent T_H2 response with a reduction of CD8-positive T-cells in MF/SS, especially in advanced-stage disease, the immunomodulatory characteristics of lenalidomide represent a strong rationale for its use in CTCL patients[49,50].

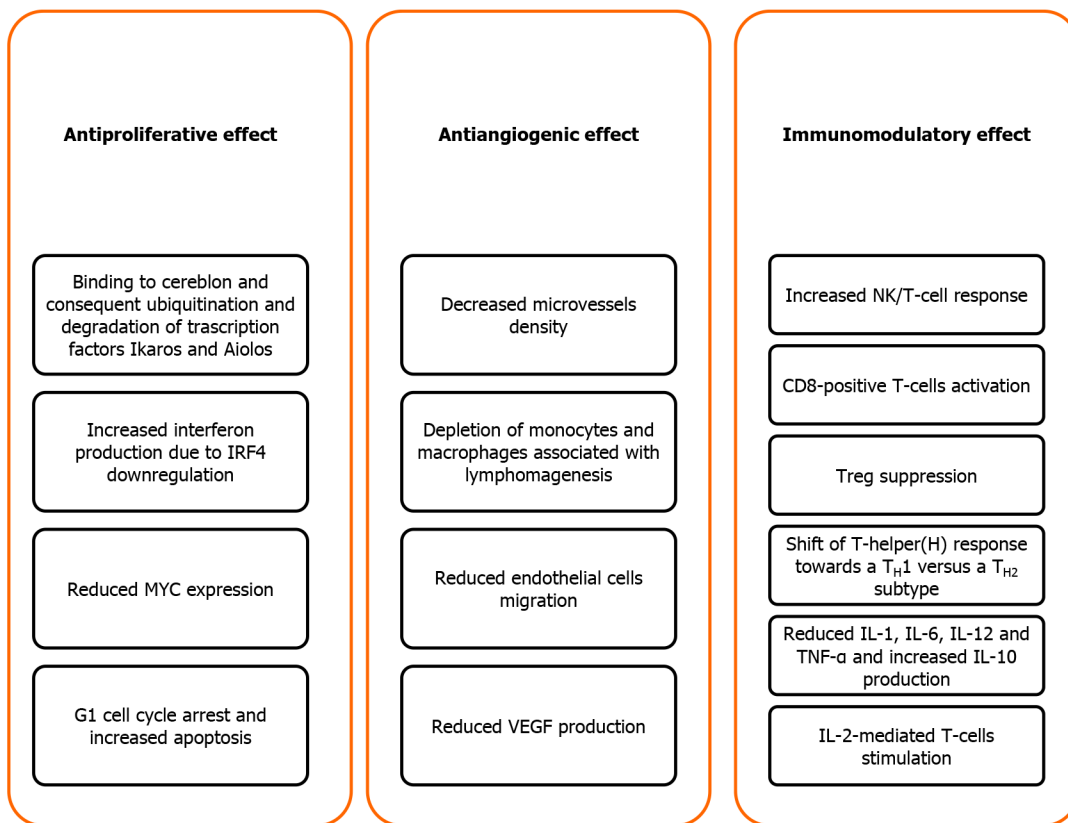


Figure 1 Lenalidomide mechanisms of action. IL: Interleukin; VEGF: Vascular endothelial growth factor.

Three MF patients were included in the phase II, single-arm EXPECT trial, in which lenalidomide dose was 25 mg once daily on days 1-21 of a 28-d cycle, given until progressive disease (PD) or unacceptable toxicity, for a maximum of 2 years. Unfortunately, treatment response for MF patients was not reported[51]. As illustrated in Table 2, Querfeld *et al*[52] enrolled in a phase II trial 32 patients with stage IB to IVB MF (18 cases), erythroidemic MF (3 cases) and SS (11 cases), who failed at least one prior therapy (skin-directed or systemic therapy). Lenalidomide was administered at a daily dose of 25 mg for 21 d of a 28-d cycle to the first 19 patients; the protocol was amended due to fatigue and tumor-flare reaction (referred to as TFR), and initial dose was reduced to 10 mg, with the possibility of daily dose increasing by 5 mg every cycle, based on treatment tolerance, up to a maximum of 25 mg[52]. Treatment was administered until PD or up to 2 years for patients who achieved a stable disease (SD) or PR, while patients in CR received two additional cycles before discontinuation. All patients received a median of six previous therapies (range: 1-14). In an intention-to-treat analysis, ORR was 28% (9/32 cases), all were PRs, with a median DOR of 10 mo [52]. The median TTR was 4 mo and 2 mo for an initial dose of 10 mg and 25 mg, respectively. Treatment response was achieved in a significant proportion of patients with blood or lymph node involvement and/or erythrodermic disease. Median PFS and OS were 8 mo and 43 mo, respectively; the main cause of death was PD (12/18 patients)[52]. Interestingly, immunophenotypic analysis showed lenalidomide effect could be associated with a reduction in circulating CD25-positive and CD4-positive T-cell count[52].

Nodal TCLS

The category of nodal PTCL includes angioimmunoblastic (AITL), anaplastic (ALCL) and PTCL not otherwise specified (NOS). PTCL-NOS represents the most common subtype, followed by AITL and ALCL (further divided in ALK-positive and ALK-negative ALCL)[1,2].

ALCL is characterized by a strong CD30 expression and large-cell anaplastic morphology; most ALK-positive cases occur in young adults and have a good prognosis, while ALK-negative cases are mainly reported in older population and display an aggressive behavior, with frequent disease relapse and/or chemorefractoriness[53]. AITL has peculiar pathophysiological features, such as the presence of an increased vascular proliferation and a reactive microenvironment (eosinophils, plasma

cells, epithelioid cells) in the lymph node, together with neoplastic T-cells[54]. Skin rash, B symptoms, hemolytic anemia and polyclonal hypergammaglobulinemia are frequently reported. Moreover, a deregulated T-cell response has been observed, with immune dysfunction[54]. A new category of neoplasms with derivation from CD4-positive T follicular helper (TFH) cells was defined in the last World Health Organization classification, which includes AITL, follicular TCL, and nodal lymphoma with a TFH phenotype[2]. PTCL-NOS is a heterogeneous subgroup of TCL cases, which do not fulfill the characteristics of more specific categories[1]. Due to this background, nodal PTCL, especially those with a TFH cell derivation, could represent an attractive target for lenalidomide.

To our knowledge, the first published study focused on lenalidomide for PTCL therapy is the interim report of a phase II trial by Dueck *et al*[55]. Both newly diagnosed (with contraindications to chemotherapy) and R/R TCL other than CTCL were enrolled from September 2006 to November 2008. The primary endpoint was ORR; patients received lenalidomide 25 mg daily on days 1-21 of a 28-d cycle, until PD or unacceptable side effects. Out of 24 patients, 20 were R/R; the diagnosis was PTCL-NOS (10 cases), AITL (7 cases), ALCL (5 cases), enteropathic-type and hepatosplenic $\gamma\delta$ TCL (1 case each). The median number of previous regimens was 1 (range: 0-4), and 5/24 cases were refractory to last previous line. Out of 23 evaluable patients, ORR was 30% (all achieved a PR), and median PFS and OS were 96 d and 241 d, respectively (for patients with at least a SD, median PFS was 168 d)[55]. Among different histologies, ORR was 40% 29% and 33% for ALCL, AITL and PTCL-NOS, respectively. Interestingly, 2 PR patients were refractory to their previous regimen, and the development of skin rash was associated with treatment response[55].

All final reports of clinical trials focused on lenalidomide treatment for nodal TCL are illustrated in Table 2. Between November 2008 and June 2009, Zinzani *et al*[56] enrolled 10 R/R PTCL-NOS patients with stage II-IV disease in a prospective, single-arm, phase II trial. Lenalidomide initial dose was 25 mg for 21 d of a 28-d cycle for four cycles as induction phase. At disease restaging after the 4th cycle, patients who achieved at least a SD continued lenalidomide administration for another eight cycles with the same schedule as maintenance phase. The results after induction phase, with an ORR of 30% (3/10 cases, all CRs) and 1 SD, were encouraging, considering that most of patients were heavily pretreated (median number of 4 Lines, range of 2-7)[56]. After maintenance phase, CR was confirmed for all 3 patients, with 2/3 cases relapsed after 3 and 5 mo, respectively, while the remaining case maintained a durable CR at last follow-up after 11 mo. The patient with SD received all 12 cycles but developed PD 1 mo upon completion of the last treatment administration[56].

On 2013, the results of the above mentioned phase II EXPECT trial were published. Even if the primary end-point was met, the study was terminated early after 54 patients were enrolled, because the efficacy was considered unsatisfactory when compared to the results obtained with other investigated compounds[51]. Patients were heavily pretreated (median number of 3 prior therapies, range of 1-11), histological subtypes included AITL (26/54 cases), PTCL-NOS (20/54 cases), ALCL (3/54 cases) and 5 cases with extranodal TCL (3 MF, 1 cutaneous ALCL and 1 TCL nasal-type). The median drug exposure time was 42 d, while the median treatment duration was 176 d for patients achieving at least a PR[51]. ORR was 22% and CR rate was 11%; among the different histologies, ORR was 20% and 31% for PTCL-NOS and AITL, respectively[51]. The median DOR was 3.6 mo (not reached for patients in CR) and the response rate was slightly higher for younger *vs* older cases (27% and 18%, respectively). Median PFS for the entire cohort was 2.5 mo, while it was 4.6 mo and 1.9 mo for AITL and non-AITL cases, respectively; OS data were not shown[51].

On 2015, the final report of the above mentioned interim analysis was published by Toumshy *et al*[57]. Out of 39 enrolled patients (8 treatment-naïve cases), diagnosis was PTCL-NOS (14 cases), ALCL (10 cases), AITL (9 cases), lymphoblastic TCL, enteropathic-type and hepatosplenic $\gamma\delta$ TCL (2 cases each). The median number of previous regimens was 1 (range: 0-5) and 11/39 cases were refractory to last previous line. ORR was 26% (10/39 cases), 3 patients achieved a CR. Among the different histologies, ORR was 10%, 33% and 43% for ALCL, AITL and PTCL-NOS, respectively [57]. The median PFS, DOR and OS were 4 mo, 13 mo and 12 mo, respectively. Interestingly, a trend between skin rash and treatment response was reported. When we analyzed newly diagnosed and R/R patients separately, ORR, median OS, PFS and DOR were 50% and 24%, 22 mo and 12 mo, 2 mo and 4 mo, 21 mo and 5 mo, respectively[57].

Due to the rarity of disease, we would like to mention several case reports about lenalidomide efficacy in R/R AITL. The peculiar pathophysiology of AITL makes the disease a suitable target for an immunomodulatory drug such as lenalidomide[58].

Our group administered lenalidomide to a patient with an unsatisfactory response despite three lines of chemotherapy. The patient received 12 treatment cycles (25 mg for four cycles and 15 mg for eight cycles) and maintained a durable CR after a follow-up of 30 mo[59]. In another report, a patient refractory to two previous lines received lenalidomide 15 mg continuously and achieved a CR, which was maintained after 2 years of follow-up[60]. Broccoli *et al*[61] administered reduced doses of lenalidomide (10 mg) to a refractory AITL patient with persistent disease and thrombocytopenia after autologous stem-cell transplantation. The patient achieved a long-lasting CR and continued therapy at an escalated dose of 15 mg for a total of 11 cycles. Finally, an 87-year-old woman with AITL and concurrent MM was refractory to multiple lines of chemotherapy and achieved a PR after four cycles of lenalidomide, with a dose escalation until 20 mg[62]. Interestingly, both AITL and MM improved after lenalidomide administration.

SAFETY

Lenalidomide is generally administered as an outpatient regimen and is well tolerated. As shown in Table 3, commonly observed side effects include neutropenia, thrombocytopenia, infections, skin rash and gastrointestinal disorders.

In the phase II study for R/R ATLL, the most common hematologic adverse event (AE) was thrombocytopenia (77%), while neutropenia and anemia occurred in 73% and 54% of total cases, respectively[44]. The incidence of grade 3-4 thrombocytopenia and neutropenia was 23% and 65%, respectively. The most frequent nonhematologic AEs were hypoalbuminemia (35%), constipation, hyponatremia and hypocalcemia (all with an incidence of 31%)[44]. Serious AEs were reported in 9 cases (35%), while AEs leading to treatment discontinuation were observed in 6 patients, including neutropenia and thrombocytopenia (2 cases each), toxic skin eruption (1 case), skin rash and hepatic failure (both in the same patient). Interestingly, no second primary malignancies (SPMs) were observed[44].

In the phase II trial focused on CTCL, the most common AEs were fatigue, lower leg edema and anemia, with an incidence of 59%, 47% and 41%, respectively[52]. Mild-to-moderate constipation or diarrhea was observed in 11 cases (35%), while peripheral neuropathy was uncommon (19%). Grade 3-4 toxicity included fatigue (22%), infections (9%) and leukopenia (3%). Nine cases experienced a TFR, while no SPMs were reported[52].

In the Italian study, the incidence of grade 3-4 neutropenia, thrombocytopenia and asthenia was 25%, 15% and 10%, respectively[56]. In the EXPECT trial, grade 3-4 thrombocytopenia and neutropenia occurred in 20% and 15% of total cases, respectively[51]. Grade 3-4 infections and febrile neutropenia were observed in 15% and 4% of total cases, respectively; these events did not lead to treatment discontinuation. Grade 3-4 gastrointestinal disorders and TFR were experienced by 17% and 4% of total cases, respectively; only 1 patient had a treatment discontinuation due to TFR[51]. The most common AEs leading to treatment interruption or dose reduction were neutropenia and thrombocytopenia (11% of total cases each). Serious AE were reported in 54% of patients, the most frequently observed were hematological events and infections (19% of total cases each). SPMs were experienced by 3 patients, in 1 case the neoplasm was considered as therapy-related[51].

Finally, in the phase II trial by Toumishey *et al*[57], the most common AEs were pain (mainly considered as lymphoma-related rather than therapy-related), fatigue, gastrointestinal and hematological events[57]. The incidence of grade 3-4 anemia, neutropenia, febrile neutropenia, dyspnea, muscle weakness and dehydration was 11%, 16%, 8%, 13%, and 10%, respectively. Neutropenia was the main cause for dose reduction, while no deaths were considered as lenalidomide-related and no SPMs were reported[57].

NEW PERSPECTIVES

Lenalidomide monotherapy can produce a durable CR with manageable toxicity in R/R TCL, with an overall efficacy comparable to other investigated novel agents. New perspectives could be represented by combination strategies with lenalidomide in association with conventional chemotherapy and/or other novel agents, with the aim to have a place for earlier lenalidomide administration, even in a front-line regimen, especially for TCL with a TFH cell origin, such as AITL[56,57].

Table 3 Toxicity profile of lenalidomide in clinical trials for T-cell lymphomas

Toxicity/Adverse event	Ishida <i>et al</i> [44]	Querfeld <i>et al</i> [52]	Morschhauser <i>et al</i> [51]	Toumishey <i>et al</i> [57]
Hematological toxicity				
Anemia total	54%	41%	NR	26%
Anemia grade 3-4	19.2%	/	4%	11%
Leukopenia total	50%	22%	NR	NR
Leukopenia grade 3-4	38.5%	3%	4%	NR
Neutropenia total	73%	NR	NR	18%
Neutropenia grade 3-4	65.4%	NR	15%	16%
Thrombocytopenia total	77%	NR	NR	26%
Thrombocytopenia grade 3-4	23.1%	NR	20%	5%
Hypoalbuminemia	35%	28%	NR	NR
Grade 3-4	/	/	NR	NR
Constipation	31%	34% ¹	17%	44%
Grade 3-4	/	/	NR	3%
Nausea	23.1%	13%	NR	28%
Grade 3-4	3.8%	/	NR	/
Vomiting	23.1%	NR	NR	10%
Grade 3-4	/	NR	NR	/
Skin rash	23.1%	25%	NR	38%
Grade 3-4	7.6%	/	9%	11%
Fatigue	15.4%	59%	NR	56%
Grade 3-4	3.8%	22%	NR	11%
Diarrhea	NR	NR	NR	31%
Grade 3-4	NR	NR	NR	8%
Pain	NR	34%	NR	64%
Grade 3-4	NR	/	NR	21%
Infection	19.2%	34%	NR	26%
Grade 3-4	10.4%	9%	15%	5%
Neuropathy	NR	19%	NR	NR
Grade 3-4	NR	/	NR	NR
Lower leg edema	NR	47%	NR	28%
Grade 3-4	NR	/	NR	3%
Anorexia	NR	16%	NR	28%
Grade 3-4	NR	/	NR	5%
Respiratory disorders	10.4%	NR	NR	26%
Grade 3-4	7.6%	NR	13%	13%
Pulmonary embolism	NR	NR	NR	10%
Grade 3-4	NR	NR	NR	8%
Tumor flare reaction	NR	28%	14%	NR
Grade 3-4	NR	NR	4%	NR

¹Considered together with diarrhea; Gastrointestinal disorders. NR: Not reported.

The genomic TCL landscape is being elucidated and a significant proportion of AT

The REVAIL study investigated lenalidomide in association with CHOP in newly diagnosed AITL patients. At the last International Conference on Malignant Lymphoma meeting, an ancillary study was presented in which bone marrow involvement (BMI), but no blood involvement, showed an association with reduced survival. Median PFS and OS for patients with or without BMI were 9 mo and 36 mo and 17 mo and 54 mo, respectively. The prognostic index for PTCL, including BMI, had the best power to divide the entire cohort between high-risk and low-risk cases, with a 2-year OS of 38% *vs* 79%. Moreover, BMI was associated with the presence of IDH-2 mutations[64].

An integrative analysis of this trial has been recently published, lenalidomide was given in association with CHOP every 21 d for eight total cycles[65]. CHOP was administered on day 1, and lenalidomide was added at a daily dose of 25 mg for 14 d every 21 d. Out of 78 patients included in the efficacy analysis, ORR was 56%, with a CR rate of 41%. The median dose intensity for lenalidomide was 81%, and 55% of total cases completed the study; the most common reasons for early treatment discontinuation were PD and toxicity[65]. After a median follow-up of 45 mo, 2-year PFS and OS were 42.1% and 59.2%, respectively; the presence of DNMT3A mutation appeared related with shorter PFS. Unfortunately, the primary end-point to improve a positron emission tomography-based CR rate from 45% to 60% was not reached, and the authors suggest the lack of benefit from adding lenalidomide to CHOP as AITL first-line therapy[65]. In 2 refractory AITL cases, lenalidomide was investigated in association with bortezomib and dexamethasone, achieving a CR and a PR with a manageable safety profile[66]. The rationale could be represented by a potential synergism between the immunomodulatory and antiangiogenic action of lenalidomide and the proteasome inhibitor activity of bortezomib.

In another phase I/II study, a combination of lenalidomide, vorinostat and dexamethasone was explored. Out of 8 enrolled R/R nodal TCL patients, 2 experienced a dose-limiting toxicity with a daily dose of 10 mg; thus, the maximum tolerated dose of lenalidomide was 5 mg/d[67]. ORR was 25% (1 CR and 1 PR), with a median PFS and OS of 2.2 and 6.7 mo, respectively. Due to these disappointing results, the authors did not find any additional benefit for this combination regimen compared to lenalidomide alone and discouraged further investigations[67].

The histone deacetylase inhibitor romidepsin showed a potential synergism with lenalidomide and could enhance tumor cell death in a TCL preclinical model[68]. This combination demonstrated a synergistic effect in the Hut-78 human TCL cell line and an additive effect in the Karpas-299 human TCL cell line; it was mainly related to the activation of a caspase-dependent pro-apoptotic pathway[68]. A phase Ib/IIa study, in which both PTCL and MM will be enrolled, is currently ongoing (NCT01755975).

Another promising strategy is represented by the use of lenalidomide as maintenance after debulking therapy, as previously published for R/R DLBCL cases[69]. Lenalidomide maintenance *vs* observation for advanced CTCL was investigated in a phase III, randomized trial at a daily dose of 25 mg for 21 d every 28 d[70]. Unfortunately, the trial was terminated early, following withdrawal of funding; out of 21 patients, 9/21 and 12/21 cases had been randomized to lenalidomide and observation. Median PFS was 5.3 mo and 2 mo, respectively, further suggesting a potential benefit for maintenance therapy, even if the reduced sample size did not permit a statistical comparison[70].

CONCLUSION

R/R TCL cases are characterized by poor prognosis and current guidelines showed a lack of satisfactory treatment options. Lenalidomide has been successfully used in several hematologic malignancies, such as mantle-cell lymphoma, MM, DLBCL and myelodysplastic syndromes. The multiple mechanisms of action, with immunomodulatory, antiangiogenic and direct antineoplastic properties, represent a strong rationale to investigate the drug, alone or in association, for the treatment of R/R TCL patients. Lenalidomide demonstrated a promising efficacy with manageable toxicity in the treatment of ATLL, CTCL and nodal TCL, at least comparable to licensed drugs such as mogamulizumab, pralatrexate or romidepsin, even in heavily pretreated patients. Identification of the TFH cell as the cell of origin of several TCLs, including AITL, could explain the high efficacy of lenalidomide in the treatment of R/R AITL cases. To our knowledge, combination strategies did not show an additional benefit compared to monotherapy, even if further investigations are warranted.

In conclusion, lenalidomide as a single-agent prolongs PFS in R/R TCL with an acceptable toxicity and could represent a suitable treatment option for this patient population, especially for neoplasm cases with a TFH origin.

REFERENCES

- 1 **d'Amore F**, Gaulard P, Trümper L, Corradini P, Kim WS, Specht L, Bjerregaard Pedersen M, Ladetto M; ESMO Guidelines Committee. Peripheral T-cell lymphomas: ESMO Clinical Practice Guidelines for diagnosis, treatment and follow-up. *Ann Oncol* 2015; **26** Suppl 5: v108-v115 [PMID: 26314772 DOI: 10.1093/annonc/mdv201]
- 2 **Swerdlow SH**, Campo E, Pileri SA, Harris NL, Stein H, Siebert R, Advani R, Ghielmini M, Salles GA, Zelenetz AD, Jaffe ES. The 2016 revision of the World Health Organization classification of lymphoid neoplasms. *Blood* 2016; **127**: 2375-2390 [PMID: 26980727 DOI: 10.1182/blood-2016-01-643569]
- 3 **Bachy E**, Broccoli A, Dearden C, de Leval L, Gaulard P, Koch R, Morschhauser F, Trümper L, Zinzani PL. Controversies in the Treatment of Peripheral T-cell Lymphoma. *Hemasphere* 2020; **4**: e461 [PMID: 33062943 DOI: 10.1097/HS9.0000000000000461]
- 4 **Laribi K**, Alani M, Truong C, Baugier de Materre A. Recent Advances in the Treatment of Peripheral T-Cell Lymphoma. *Oncologist* 2018; **23**: 1039-1053 [PMID: 29674443 DOI: 10.1634/theoncologist.2017-0524]
- 5 **Shustov A**, Cabrera ME, Civallero M, Bellei M, Ko YH, Manni M, Skrypets T, Horwitz SM, De Souza CA, Radford JA, Bobillo S, Prates MV, Ferreri AJM, Chiattone C, Spina M, Vose JM, Chiappella A, Laszlo D, Marino D, Stelitano C, Federico M. ALK-negative anaplastic large cell lymphoma: features and outcomes of 235 patients from the International T-Cell Project. *Blood Adv* 2021; **5**: 640-648 [PMID: 33560375 DOI: 10.1182/bloodadvances.2020001581]
- 6 **Vose J**, Armitage J, Weisenburger D; International T-Cell Lymphoma Project. International peripheral T-cell and natural killer/T-cell lymphoma study: pathology findings and clinical outcomes. *J Clin Oncol* 2008; **26**: 4124-4130 [PMID: 18626005 DOI: 10.1200/JCO.2008.16.4558]
- 7 **Cencini E**, Fabbri A, Sicuranza A, Bocchia M. Prognostic significance of lymphocyte/monocyte count and neutrophil/lymphocyte count in peripheral T cell lymphoma. *Leuk Res* 2019; **77**: 5-7 [PMID: 30594867 DOI: 10.1016/j.leukres.2018.12.008]
- 8 **Bellei M**, Foss FM, Shustov AR, Horwitz SM, Marcheselli L, Kim WS, Cabrera ME, Dlouhy I, Nagler A, Advani RH, Pesce EA, Ko YH, Martinez V, Montoto S, Chiattone C, Moskowitz A, Spina M, Biasoli I, Manni M, Federico M; International T-cell Project Network. The outcome of peripheral T-cell lymphoma patients failing first-line therapy: a report from the prospective, International T-Cell Project. *Haematologica* 2018; **103**: 1191-1197 [PMID: 29599200 DOI: 10.3324/haematol.2017.186577]
- 9 **Abeyakoon C**, van der Weyden C, Harrop S, Khot A, Dickinson M, Yannakou CK, Prince HM. Role of Haematopoietic Stem Cell Transplantation in Peripheral T-Cell Lymphoma. *Cancers (Basel)* 2020; **12** [PMID: 33114606 DOI: 10.3390/cancers12113125]
- 10 **O'Connor OA**, Pro B, Pinter-Brown L, Bartlett N, Popplewell L, Coiffier B, Lechowicz MJ, Savage KJ, Shustov AR, Gisselbrecht C, Jacobsen E, Zinzani PL, Furman R, Goy A, Haioun C, Crump M, Zain JM, Hsi E, Boyd A, Horwitz S. Pralatrexate in patients with relapsed or refractory peripheral T-cell lymphoma: results from the pivotal PROPEL study. *J Clin Oncol* 2011; **29**: 1182-1189 [PMID: 21245435 DOI: 10.1200/JCO.2010.29.9024]
- 11 **Coiffier B**, Pro B, Prince HM, Foss F, Sokol L, Greenwood M, Caballero D, Morschhauser F, Wilhelm M, Pinter-Brown L, Padmanabhan Iyer S, Shustov A, Nielsen T, Nichols J, Wolfson J, Balser B, Horwitz S. Romidepsin for the treatment of relapsed/refractory peripheral T-cell lymphoma: pivotal study update demonstrates durable responses. *J Hematol Oncol* 2014; **7**: 11 [PMID: 24456586 DOI: 10.1186/1756-8722-7-11]
- 12 **O'Connor OA**, Horwitz S, Masszi T, Van Hoof A, Brown P, Doorduijn J, Hess G, Jurczak W, Knoblauch P, Chawla S, Bhat G, Choi MR, Walewski J, Savage K, Foss F, Allen LF, Shustov A. Belinostat in Patients With Relapsed or Refractory Peripheral T-Cell Lymphoma: Results of the Pivotal Phase II BELIEF (CLN-19) Study. *J Clin Oncol* 2015; **33**: 2492-2499 [PMID: 26101246 DOI: 10.1200/JCO.2014.59.2782]
- 13 **Pro B**, Advani R, Brice P, Bartlett NL, Rosenblatt JD, Illidge T, Matous J, Ramchandren R, Fanale M, Connors JM, Fenton K, Huebner D, Pinelli JM, Kennedy DA, Shustov A. Five-year results of brentuximab vedotin in patients with relapsed or refractory systemic anaplastic large cell lymphoma. *Blood* 2017; **130**: 2709-2717 [PMID: 28974506 DOI: 10.1182/blood-2017-05-780049]
- 14 **Kim YH**, Bagot M, Pinter-Brown L, Rook AH, Porcu P, Horwitz SM, Whittaker S, Tokura Y, Vermeer M, Zinzani PL, Sokol L, Morris S, Kim EJ, Ortiz-Romero PL, Eradat H, Scarisbrick J, Tsianakas A, Elmets C, Dalle S, Fisher DC, Halwani A, Poligone B, Greer J, Fierro MT, Khot A, Moskowitz AJ, Musiek A, Shustov A, Pro B, Geskin LJ, Dwyer K, Moriya J, Leoni M, Humphrey JS, Hudgens S, Grebennik DO, Tobinai K, Duvic M; MAVORIC Investigators. Mogamulizumab versus vorinostat in previously treated cutaneous T-cell lymphoma (MAVORIC): an international, open-label, randomised, controlled phase 3 trial. *Lancet Oncol* 2018; **19**: 1192-1204 [PMID: 30100375 DOI: 10.1016/S1470-2045(18)30379-6]

- 15 **Horwitz SM**, Ansell S, Ai WZ, Barnes J, Barta SK, Clemens MW, Dogan A, Goodman AM, Goyal G, Guitart J, Halwani A, Haverkos BM, Hoppe RT, Jacobsen E, Jagadeesh D, Jones A, Kim YH, Mehta-Shah N, Olsen EA, Pro B, Rajguru SA, Rozati S, Said J, Shaver A, Shustov A, Sokol L, Torka P, Torres-Cabala C, Wilcox R, William BM, Zain J, Dwyer MA, Sundar H. NCCN Guidelines Insights: T-Cell Lymphomas, Version 1. 2021. *J Natl Compr Canc Netw* 2020; **18**: 1460-1467 [PMID: [33152703](#) DOI: [10.6004/jncn.2020.0053](#)]
- 16 **Broccoli A**, Argnani L, Zinzani PL. Peripheral T-cell lymphomas: Focusing on novel agents in relapsed and refractory disease. *Cancer Treat Rev* 2017; **60**: 120-129 [PMID: [28946015](#) DOI: [10.1016/j.ctrv.2017.09.002](#)]
- 17 **Palumbo A**, Hakej R, Delforge M, Kropff M, Petrucci MT, Catalano J, Gisslinger H, Wiktor-Jędrzejczak W, Zodelava M, Weisel K, Cascavilla N, Iosava G, Cavo M, Kloczko J, Bladé J, Beksac M, Spicka I, Plesner T, Radke J, Langer C, Ben Yehuda D, Corso A, Herbein L, Yu Z, Mei J, Jacques C, Dimopoulos MA; MM-015 Investigators. Continuous lenalidomide treatment for newly diagnosed multiple myeloma. *N Engl J Med* 2012; **366**: 1759-1769 [PMID: [22571200](#) DOI: [10.1056/NEJMoa1112704](#)]
- 18 **Strati P**, Keating MJ, Wierda WG, Badoux XC, Calin S, Reuben JM, O'Brien S, Kornblau SM, Kantarjian HM, Gao H, Ferrajoli A. Lenalidomide induces long-lasting responses in elderly patients with chronic lymphocytic leukemia. *Blood* 2013; **122**: 734-737 [PMID: [23801633](#) DOI: [10.1182/blood-2013-04-495341](#)]
- 19 **Defina M**, Rondoni M, Gozzetti A, Aprile L, Chitarrelli I, Fabbri A, Lauria F, Bocchia M. Lenalidomide on alternative days is effective in myelodysplastic syndrome with 5q- deletion. *Br J Haematol* 2010; **148**: 483-484 [PMID: [19874309](#) DOI: [10.1111/j.1365-2141.2009.07971.x](#)]
- 20 **Czuczman MS**, Trněný M, Davies A, Rule S, Linton KM, Wagner-Johnston N, Gascoyne RD, Slack GW, Brousset P, Eberhard DA, Hernandez-Ilizaliturri FJ, Salles G, Witzig TE, Zinzani PL, Wright GW, Staudt LM, Yang Y, Williams PM, Lih CJ, Russo J, Thakurta A, Hagner P, Fustier P, Song D, Lewis ID. A Phase 2/3 Multicenter, Randomized, Open-Label Study to Compare the Efficacy and Safety of Lenalidomide Versus Investigator's Choice in Patients with Relapsed or Refractory Diffuse Large B-Cell Lymphoma. *Clin Cancer Res* 2017; **23**: 4127-4137 [PMID: [28381416](#) DOI: [10.1158/1078-0432.CCR-16-2818](#)]
- 21 **Strati P**, Jain P, Johnson RJ, Forbes S, Feng L, Samaniego F, Rodriguez MA, Fayad LE, Hagemester F, Westin J, Wang M, Neelapu SS, Nastoupil LJ, Fowler NH. Long-term follow-up of lenalidomide and rituximab as initial treatment of follicular lymphoma. *Blood* 2021; **137**: 1124-1129 [PMID: [32932518](#) DOI: [10.1182/blood.2020007994](#)]
- 22 **Stefoni V**, Pellegrini C, Broccoli A, Baldini L, Tani M, Cencini E, Figuera A, Ansuinelli M, Bernocco E, Cantonetti M, Cox MC, Ballerini F, Rusconi C, Visco C, Arcaini L, Fama A, Marasca R, Volpetti S, Castellino A, Califano C, Cavaliere M, Gini G, Liberati AM, Musuraca G, Lucania A, Ricciuti G, Argnani L, Zinzani PL. Lenalidomide in Pretreated Mantle Cell Lymphoma Patients: An Italian Observational Multicenter Retrospective Study in Daily Clinical Practice (the Lenamant Study). *Oncologist* 2018; **23**: 1033-1038 [PMID: [29674440](#) DOI: [10.1634/theoncologist.2017-0597](#)]
- 23 **Chen N**, Zhou S, Palmisano M. Clinical Pharmacokinetics and Pharmacodynamics of Lenalidomide. *Clin Pharmacokinet* 2017; **56**: 139-152 [PMID: [27351179](#) DOI: [10.1007/s40262-016-0432-1](#)]
- 24 **Kritharis A**, Coyle M, Sharma J, Evens AM. Lenalidomide in non-Hodgkin lymphoma: biological perspectives and therapeutic opportunities. *Blood* 2015; **125**: 2471-2476 [PMID: [25736312](#) DOI: [10.1182/blood-2014-11-567792](#)]
- 25 **Ramsay AG**, Clear AJ, Kelly G, Fatah R, Matthews J, Macdougall F, Lister TA, Lee AM, Calaminici M, Gribben JG. Follicular lymphoma cells induce T-cell immunologic synapse dysfunction that can be repaired with lenalidomide: implications for the tumor microenvironment and immunotherapy. *Blood* 2009; **114**: 4713-4720 [PMID: [19786615](#) DOI: [10.1182/blood-2009-04-217687](#)]
- 26 **Ramsay AG**, Clear AJ, Fatah R, Gribben JG. Multiple inhibitory ligands induce impaired T-cell immunologic synapse function in chronic lymphocytic leukemia that can be blocked with lenalidomide: establishing a reversible immune evasion mechanism in human cancer. *Blood* 2012; **120**: 1412-1421 [PMID: [22547582](#) DOI: [10.1182/blood-2012-02-411678](#)]
- 27 **Kater AP**, Tonino SH, Egle A, Ramsay AG. How does lenalidomide target the chronic lymphocytic leukemia microenvironment? *Blood* 2014; **124**: 2184-2189 [PMID: [25161268](#) DOI: [10.1182/blood-2014-05-578286](#)]
- 28 **Reddy N**, Hernandez-Ilizaliturri FJ, Deeb G, Roth M, Vaughn M, Knight J, Wallace P, Czuczman MS. Immunomodulatory drugs stimulate natural killer-cell function, alter cytokine production by dendritic cells, and inhibit angiogenesis enhancing the anti-tumour activity of rituximab in vivo. *Br J Haematol* 2008; **140**: 36-45 [PMID: [17995965](#) DOI: [10.1111/j.1365-2141.2007.06841.x](#)]
- 29 **Wu L**, Adams M, Carter T, Chen R, Muller G, Stirling D, Schafer P, Bartlett JB. lenalidomide enhances natural killer cell and monocyte-mediated antibody-dependent cellular cytotoxicity of rituximab-treated CD20+ tumor cells. *Clin Cancer Res* 2008; **14**: 4650-4657 [PMID: [18628480](#) DOI: [10.1158/1078-0432.CCR-07-4405](#)]
- 30 **Gribben JG**, Fowler N, Morschhauser F. Mechanisms of Action of Lenalidomide in B-Cell Non-Hodgkin Lymphoma. *J Clin Oncol* 2015; **33**: 2803-2811 [PMID: [26195701](#) DOI: [10.1200/JCO.2014.59.5363](#)]
- 31 **Song K**, Herzog BH, Sheng M, Fu J, McDaniel JM, Chen H, Ruan J, Xia L. Lenalidomide inhibits lymphangiogenesis in preclinical models of mantle cell lymphoma. *Cancer Res* 2013; **73**: 7254-7264 [PMID: [24158094](#) DOI: [10.1158/0008-5472.CAN-13-0750](#)]

- 32 **Pellagatti A**, Jädersten M, Forsblom AM, Cattani H, Christensson B, Emanuelsson EK, Merup M, Nilsson L, Samuelsson J, Sander B, Wainscoat JS, Boulton J, Hellström-Lindberg E. Lenalidomide inhibits the malignant clone and up-regulates the SPARC gene mapping to the commonly deleted region in 5q- syndrome patients. *Proc Natl Acad Sci U S A* 2007; **104**: 11406-11411 [PMID: 17576924 DOI: 10.1073/pnas.0610477104]
- 33 **Lu L**, Payvandi F, Wu L, Zhang LH, Hariri RJ, Man HW, Chen RS, Muller GW, Hughes CC, Stirling DI, Schafer PH, Bartlett JB. The anti-cancer drug lenalidomide inhibits angiogenesis and metastasis via multiple inhibitory effects on endothelial cell function in normoxic and hypoxic conditions. *Microvasc Res* 2009; **77**: 78-86 [PMID: 18805433 DOI: 10.1016/j.mvr.2008.08.003]
- 34 **Jin Z**, Qing K, Ouyang Y, Liu Z, Wang W, Li X, Xu Z, Li J. Low dose of lenalidomide and PI3K/mTOR inhibitor trigger synergistic cytotoxicity in activated B cell-like subtype of diffuse large B cell lymphoma. *J Exp Clin Cancer Res* 2016; **35**: 52 [PMID: 27009084 DOI: 10.1186/s13046-016-0327-x]
- 35 **Lopez-Girona A**, Mendy D, Ito T, Miller K, Gandhi AK, Kang J, Karasawa S, Carmel G, Jackson P, Abbasian M, Mahmoudi A, Cathers B, Rychak E, Gaidarova S, Chen R, Schafer PH, Handa H, Daniel TO, Evans JF, Chopra R. Cereblon is a direct protein target for immunomodulatory and antiproliferative activities of lenalidomide and pomalidomide. *Leukemia* 2012; **26**: 2326-2335 [PMID: 22552008 DOI: 10.1038/leu.2012.119]
- 36 **Zhu YX**, Braggio E, Shi CX, Bruins LA, Schmidt JE, Van Wier S, Chang XB, Bjorklund CC, Fonseca R, Bergsagel PL, Orlowski RZ, Stewart AK. Cereblon expression is required for the antimyeloma activity of lenalidomide and pomalidomide. *Blood* 2011; **118**: 4771-4779 [PMID: 21860026 DOI: 10.1182/blood-2011-05-356063]
- 37 **Gandhi AK**, Kang J, Havens CG, Conklin T, Ning Y, Wu L, Ito T, Ando H, Waldman MF, Thakurta A, Klippel A, Handa H, Daniel TO, Schafer PH, Chopra R. Immunomodulatory agents lenalidomide and pomalidomide co-stimulate T cells by inducing degradation of T cell repressors Ikaros and Aiolos via modulation of the E3 ubiquitin ligase complex CRL4 (CRBN). *Br J Haematol* 2014; **164**: 811-821 [PMID: 24328678 DOI: 10.1111/bjh.12708]
- 38 **Krönke J**, Udeshi ND, Narla A, Grauman P, Hurst SN, McConkey M, Svinkina T, Heckl D, Comer E, Li X, Ciarlo C, Hartman E, Munshi N, Schenone M, Schreiber SL, Carr SA, Ebert BL. Lenalidomide causes selective degradation of IKZF1 and IKZF3 in multiple myeloma cells. *Science* 2014; **343**: 301-305 [PMID: 24292625 DOI: 10.1126/science.1244851]
- 39 **Zhang LH**, Kosek J, Wang M, Heise C, Schafer PH, Chopra R. Lenalidomide efficacy in activated B-cell-like subtype diffuse large B-cell lymphoma is dependent upon IRF4 and cereblon expression. *Br J Haematol* 2013; **160**: 487-502 [PMID: 23252516 DOI: 10.1111/bjh.12172]
- 40 **Fecteau JF**, Corral LG, Ghia EM, Gaidarova S, Futalan D, Bharati IS, Cathers B, Schwaederlé M, Cui B, Lopez-Girona A, Messmer D, Kipps TJ. Lenalidomide inhibits the proliferation of CLL cells via a cereblon/p21(WAF1/Cip1)-dependent mechanism independent of functional p53. *Blood* 2014; **124**: 1637-1644 [PMID: 24990888 DOI: 10.1182/blood-2014-03-559591]
- 41 **Tsukasaki K**, Marçais A, Nasr R, Kato K, Fukuda T, Hermine O, Bazarbachi A. Diagnostic Approaches and Established Treatments for Adult T Cell Leukemia Lymphoma. *Front Microbiol* 2020; **11**: 1207 [PMID: 32636814 DOI: 10.3389/fmicb.2020.01207]
- 42 **Cook LB**, Fuji S, Hermine O, Bazarbachi A, Ramos JC, Ratner L, Horwitz S, Fields P, Tanase A, Bumbea H, Cwynarski K, Taylor G, Waldmann TA, Bittencourt A, Marçais A, Suarez F, Sibon D, Phillips A, Lunning M, Farid R, Imaizumi Y, Choi I, Ishida T, Ishitsuka K, Fukushima T, Uchimaru K, Takaori-Kondo A, Tokura Y, Utsunomiya A, Matsuoka M, Tsukasaki K, Watanabe T. Revised Adult T-Cell Leukemia-Lymphoma International Consensus Meeting Report. *J Clin Oncol* 2019; **37**: 677-687 [PMID: 30657736 DOI: 10.1200/JCO.18.00501]
- 43 **Ogura M**, Imaizumi Y, Uike N, Asou N, Utsunomiya A, Uchida T, Aoki T, Tsukasaki K, Taguchi J, Choi I, Maruyama D, Nosaka K, Chen N, Midorikawa S, Ohtsu T, Tobinai K. Lenalidomide in relapsed adult T-cell leukaemia-lymphoma or peripheral T-cell lymphoma (ATLL-001): a phase 1, multicentre, dose-escalation study. *Lancet Haematol* 2016; **3**: e107-e118 [PMID: 26947199 DOI: 10.1016/S2352-3026(15)00284-7]
- 44 **Ishida T**, Fujiwara H, Nosaka K, Taira N, Abe Y, Imaizumi Y, Moriuchi Y, Jo T, Ishizawa K, Tobinai K, Tsukasaki K, Ito S, Yoshimitsu M, Otsuka M, Ogura M, Midorikawa S, Ruiz W, Ohtsu T. Multicenter Phase II Study of Lenalidomide in Relapsed or Recurrent Adult T-Cell Leukemia/Lymphoma: ATLL-002. *J Clin Oncol* 2016; **34**: 4086-4093 [PMID: 27621400 DOI: 10.1200/JCO.2016.67.7732]
- 45 **Sakamoto H**, Itonaga H, Sawayama Y, Furumoto T, Fujioka M, Chiwata M, Toriyama E, Kasai S, Nakashima J, Horai M, Kato T, Sato S, Ando K, Taguchi J, Imaizumi Y, Yoshida S, Hata T, Moriuchi Y, Miyazaki Y. Treatment with mogamulizumab or lenalidomide for relapsed adult T-cell leukemia/lymphoma after allogeneic hematopoietic stem cell transplantation: The Nagasaki transplant group experience. *Hematol Oncol* 2020; **38**: 162-170 [PMID: 31922287 DOI: 10.1002/hon.2712]
- 46 **Mehra-Shah N**, Horwitz SM. Lenalidomide in Adult T-Cell Leukemia/Lymphoma. *J Clin Oncol* 2016; **34**: 4066-4067 [PMID: 27863193 DOI: 10.1200/JCO.2016.69.4505]
- 47 **Willemze R**, Hodak E, Zinzani PL, Specht L, Ladetto M; ESMO Guidelines Committee. Primary cutaneous lymphomas: ESMO Clinical Practice Guidelines for diagnosis, treatment and follow-up. *Ann Oncol* 2018; **29**: iv30-iv40 [PMID: 29878045 DOI: 10.1093/annonc/mdy133]
- 48 **Agar NS**, Wedgeworth E, Crichton S, Mitchell TJ, Cox M, Ferreira S, Robson A, Calonje E, Stefanato CM, Wain EM, Wilkins B, Fields PA, Dean A, Webb K, Scarisbrick J, Morris S, Whittaker

- SJ. Survival outcomes and prognostic factors in mycosis fungoides/Sézary syndrome: validation of the revised International Society for Cutaneous Lymphomas/European Organisation for Research and Treatment of Cancer staging proposal. *J Clin Oncol* 2010; **28**: 4730-4739 [PMID: [20855822](#) DOI: [10.1200/JCO.2009.27.7665](#)]
- 49 **Chong BF**, Wilson AJ, Gibson HM, Hafner MS, Luo Y, Hedgecock CJ, Wong HK. Immune function abnormalities in peripheral blood mononuclear cell cytokine expression differentiates stages of cutaneous T-cell lymphoma/mycosis fungoides. *Clin Cancer Res* 2008; **14**: 646-653 [PMID: [18245523](#) DOI: [10.1158/1078-0432.CCR-07-0610](#)]
- 50 **Tiemessen MM**, Mitchell TJ, Hendry L, Whittaker SJ, Taams LS, John S. Lack of suppressive CD4+CD25+FOXP3+ T cells in advanced stages of primary cutaneous T-cell lymphoma. *J Invest Dermatol* 2006; **126**: 2217-2223 [PMID: [16741512](#) DOI: [10.1038/sj.jid.5700371](#)]
- 51 **Morschhauser F**, Fitoussi O, Haioun C, Thieblemont C, Quach H, Delarue R, Glaisner S, Gabarre J, Bosly A, Lister J, Li J, Coiffier B. A phase 2, multicentre, single-arm, open-label study to evaluate the safety and efficacy of single-agent lenalidomide (Revlimid) in subjects with relapsed or refractory peripheral T-cell non-Hodgkin lymphoma: the EXPECT trial. *Eur J Cancer* 2013; **49**: 2869-2876 [PMID: [23731832](#) DOI: [10.1016/j.ejca.2013.04.029](#)]
- 52 **Querfeld C**, Rosen ST, Guitart J, Duvic M, Kim YH, Duszka SW, Kuzel TM. Results of an open-label multicenter phase 2 trial of lenalidomide monotherapy in refractory mycosis fungoides and Sézary syndrome. *Blood* 2014; **123**: 1159-1166 [PMID: [24335103](#) DOI: [10.1182/blood-2013-09-525915](#)]
- 53 **Tsuyama N**, Sakamoto K, Sakata S, Dobashi A, Takeuchi K. Anaplastic large cell lymphoma: pathology, genetics, and clinical aspects. *J Clin Exp Hematop* 2017; **57**: 120-142 [PMID: [29279550](#) DOI: [10.3960/jslrt.17023](#)]
- 54 **Broccoli A**, Zinzani PL. Angioimmunoblastic T-Cell Lymphoma. *Hematol Oncol Clin North Am* 2017; **31**: 223-238 [PMID: [28340875](#) DOI: [10.1016/j.hoc.2016.12.001](#)]
- 55 **Dueck G**, Chua N, Prasad A, Finch D, Stewart D, White D, van der Jagt R, Johnston J, Belch A, Reiman T. Interim report of a phase 2 clinical trial of lenalidomide for T-cell non-Hodgkin lymphoma. *Cancer* 2010; **116**: 4541-4548 [PMID: [20572046](#) DOI: [10.1002/encr.25377](#)]
- 56 **Zinzani PL**, Pellegrini C, Broccoli A, Stefoni V, Gandolfi L, Quirini F, Argnani L, Berti E, Derenzini E, Pileri S, Baccarani M. Lenalidomide monotherapy for relapsed/refractory peripheral T-cell lymphoma not otherwise specified. *Leuk Lymphoma* 2011; **52**: 1585-1588 [PMID: [21504290](#) DOI: [10.3109/10428194.2011.573031](#)]
- 57 **Toumishey E**, Prasad A, Dueck G, Chua N, Finch D, Johnston J, van der Jagt R, Stewart D, White D, Belch A, Reiman T. Final report of a phase 2 clinical trial of lenalidomide monotherapy for patients with T-cell lymphoma. *Cancer* 2015; **121**: 716-723 [PMID: [25355245](#) DOI: [10.1002/encr.29103](#)]
- 58 **de Leval L**, Rickman DS, Thielen C, Reynies Ad, Huang YL, Delsol G, Lamant L, Leroy K, Brière J, Molina T, Berger F, Gisselbrecht C, Xerri L, Gaulard P. The gene expression profile of nodal peripheral T-cell lymphoma demonstrates a molecular link between angioimmunoblastic T-cell lymphoma (AITL) and follicular helper T (TFH) cells. *Blood* 2007; **109**: 4952-4963 [PMID: [17284527](#) DOI: [10.1182/blood-2006-10-055145](#)]
- 59 **Fabbri A**, Cencini E, Pietrini A, Gozzetti A, Defina M, Fontanelli G, Mazzei MA, Volterrani L, Bocchia M. Impressive activity of lenalidomide monotherapy in refractory angioimmunoblastic T-cell lymphoma: report of a case with long-term follow-up. *Hematol Oncol* 2013; **31**: 213-217 [PMID: [23161606](#) DOI: [10.1002/hon.2038](#)]
- 60 **Beckers MM**, Huls G. Therapy refractory angioimmunoblastic T-cell lymphoma in complete remission with lenalidomide. *Eur J Haematol* 2013; **90**: 162-163 [PMID: [23227803](#) DOI: [10.1111/ejh.12053](#)]
- 61 **Broccoli A**, Pellegrini C, Celli M, Argnani L, Agostinelli C, Pileri S, Zinzani PL. Single-agent lenalidomide is effective in the treatment of a heavily pretreated and refractory angioimmunoblastic T-cell lymphoma patient. *Clin Lymphoma Myeloma Leuk* 2014; **14**: e119-e122 [PMID: [24629851](#) DOI: [10.1016/j.clml.2014.01.011](#)]
- 62 **Kishimoto W**, Takiuchi Y, Nakae Y, Tabata S, Fukunaga A, Matsuzaki N, Yuba Y, Kitano T, Arima N. A case of AITL complicated by EBV-positive B cell and monoclonal plasma cell proliferation and effectively treated with lenalidomide. *Int J Hematol* 2019; **109**: 499-504 [PMID: [30604313](#) DOI: [10.1007/s12185-018-02587-6](#)]
- 63 **Nagata Y**, Kontani K, Enami T, Kataoka K, Ishii R, Totoki Y, Kataoka TR, Hirata M, Aoki K, Nakano K, Kitanaka A, Sakata-Yanagimoto M, Egami S, Shiraishi Y, Chiba K, Tanaka H, Shiozawa Y, Yoshizato T, Suzuki H, Kon A, Yoshida K, Sato Y, Sato-Otsubo A, Sanada M, Munakata W, Nakamura H, Hama N, Miyano S, Nureki O, Shibata T, Haga H, Shimoda K, Katada T, Chiba S, Watanabe T, Ogawa S. Variegated RHOA mutations in adult T-cell leukemia/lymphoma. *Blood* 2016; **127**: 596-604 [PMID: [26574607](#) DOI: [10.1182/blood-2015-06-644948](#)]
- 64 **Lemonnier F**, Safar V, A. Ferchiou A, A. Cottreau A, E. Bachy E, G. Cartron G, Moles-Moreau M, Delmer A, Bouabdallah R, Voillat L, Parrens M, Casasnovas O, Cacheux V, Réguy C, Tilly H, Meignan M, Gaulard P, de Leval L, Delfau-Larrue M, Haioun C. Bone marrow involvement, but no blood involvement, impairs survival in angioimmunoblastic T cell lymphoma: an ancillary study of the REVAIL trial. Proceedings of the 15th International Conference on Malignant Lymphoma. Lugano, Switzerland-June 18-22, 2019. *Hematol Oncol* 2019; **37** [DOI: [10.1002/hon.89_2630](#)]
- 65 **Lemonnier F**, Safar V, Beldi-Ferchiou A, Cottreau AS, Bachy E, Cartron G, Fataccioli V, Pelletier L, Robe C, Letourneau A, Missiaglia E, Fourati S, Moles-Moreau MP, Delmer A, Bouabdallah R, Voillat L, Becker S, Bossard C, Parrens M, Casasnovas O, Cacheux V, Régny C, Camus V, Delfau-

- Larue MH, Meignan M, de Leval L, Gaulard P, Haioun C. Integrative analysis of a phase 2 trial combining lenalidomide with CHOP in angioimmunoblastic T-cell lymphoma. *Blood Adv* 2021; **5**: 539-548 [PMID: 33496747 DOI: 10.1182/bloodadvances.2020003081]
- 66 **Chaoui D**, Bouallegue S, Arakelyan N, Genet P, Aljijakli A, Sutton L. Bortezomib, lenalidomide and dexamethasone (VRD) combination as salvage therapy in refractory angioimmunoblastic T cell lymphoma. *Br J Haematol* 2014; **164**: 750-752 [PMID: 25136706 DOI: 10.1111/bjh.12678]
- 67 **Hopfinger G**, Nösslinger T, Lang A, Linkesch W, Melchardt T, Weiss L, Egle A, Greil R. Lenalidomide in combination with vorinostat and dexamethasone for the treatment of relapsed/refractory peripheral T cell lymphoma (PTCL): report of a phase I/II trial. *Ann Hematol* 2014; **93**: 459-462 [PMID: 24441915 DOI: 10.1007/s00277-014-2009-0]
- 68 **Cosenza M**, Civallero M, Fiorcari S, Pozzi S, Marcheselli L, Bari A, Ferri P, Sacchi S. The histone deacetylase inhibitor romidepsin synergizes with lenalidomide and enhances tumor cell death in T-cell lymphoma cell lines. *Cancer Biol Ther* 2016; **17**: 1094-1106 [PMID: 27657380 DOI: 10.1080/15384047.2016.1219820]
- 69 **Ferreri AJ**, Sassone M, Zaja F, Re A, Spina M, Rocco AD, Fabbri A, Stelitano C, Frezzato M, Rusconi C, Zambello R, Couto S, Ren Y, Arcari A, Bertoldero G, Nonis A, Scarfò L, Calimeri T, Cecchetti C, Chiozzotto M, Govi S, Ponzoni M. Lenalidomide maintenance in patients with relapsed diffuse large B-cell lymphoma who are not eligible for autologous stem cell transplantation: an open label, single-arm, multicentre phase 2 trial. *Lancet Haematol* 2017; **4**: e137-e146 [PMID: 28219694 DOI: 10.1016/S2352-3026(17)30016-9]
- 70 **Bagot M**, Hasan B, Whittaker S, Beylot-Barry M, Knobler R, Shah E, Marreaud S, Morris S, Dalle S, Servitje O, Cowan R, Väkevä L, Chaby G, Jonak C, Fox CP, Ritchie D, Vermeer MH, Stadler R, Romero PLO, Scarisbrick J, Quaglino P. A phase III study of lenalidomide maintenance after debulking therapy in patients with advanced cutaneous T-cell lymphoma - EORTC 21081 (NCT01098656): results and lessons learned for future trial designs. *Eur J Dermatol* 2017; **27**: 286-294 [PMID: 28468739 DOI: 10.1684/ejd.2017.3008]



Published by **Baishideng Publishing Group Inc**
7041 Koll Center Parkway, Suite 160, Pleasanton, CA 94566, USA

Telephone: +1-925-3991568

E-mail: bpgoffice@wjgnet.com

Help Desk: <https://www.f6publishing.com/helpdesk>

<https://www.wjgnet.com>

