

World Journal of *Clinical Cases*

World J Clin Cases 2021 October 26; 9(30): 8953-9319



Contents

Thrice Monthly Volume 9 Number 30 October 26, 2021

REVIEW

- 8953 Endothelial progenitor cells and coronary artery disease: Current concepts and future research directions
Xiao ST, Kuang CY

MINIREVIEWS

- 8967 Regulation of bone metabolism mediated by β -adrenergic receptor and its clinical application
Zhong XP, Xia WF
- 8974 Tricuspid valve endocarditis: Cardiovascular imaging evaluation and management
Fava AM, Xu B

ORIGINAL ARTICLE

Case Control Study

- 8985 Novel application of multispectral refraction topography in the observation of myopic control effect by orthokeratology lens in adolescents
Ni NJ, Ma FY, Wu XM, Liu X, Zhang HY, Yu YF, Guo MC, Zhu SY

Retrospective Cohort Study

- 8999 Uncertainty in illness and coping styles: Moderating and mediating effects of resilience in stroke patients
Han ZT, Zhang HM, Wang YM, Zhu SS, Wang DY

Retrospective Study

- 9011 Development and validation of a prognostic nomogram model for Chinese patients with primary small cell carcinoma of the esophagus
Zhang DY, Huang GR, Ku JW, Zhao XK, Song X, Xu RH, Han WL, Zhou FY, Wang R, Wei MX, Wang LD
- 9023 Preliminary establishment of a spinal stability scoring system for multiple myeloma
Yao XC, Shi XJ, Xu ZY, Tan J, Wei YZ, Qi L, Zhou ZH, Du XR
- 9038 Effect of intrauterine perfusion of granular leukocyte-colony stimulating factor on the outcome of frozen embryo transfer
Zhu YC, Sun YX, Shen XY, Jiang Y, Liu JY
- 9050 "An integrated system, three separated responsibilities", a new fever clinic management model, in prevention and control of novel coronavirus pneumonia
Shen J, He Q, Shen T, Wu ZQ, Tan MM, Chen YL, Weng Q, Nie LM, Zhang HF, Zheng B, Zhang J

Clinical Trials Study

- 9059** Single dose dexamethasone prophylaxis of postembolisation syndrome after chemoembolisation in hepatocellular carcinoma patient: A randomised, double-blind, placebo-controlled study

Sainamthip P, Kongphanich C, Prasongsook N, Chirapongsathorn S

Observational Study

- 9070** Serum calcium, albumin, globulin and matrix metalloproteinase-9 levels in acute cerebral infarction patients

Zhong TT, Wang G, Wang XQ, Kong WD, Li XY, Xue Q, Zou YA

SYSTEMATIC REVIEWS

- 9077** Neoadjuvant radiotherapy dose escalation for locally advanced rectal cancers in the new era of radiotherapy: A review of literature

Delishaj D, Fumagalli IC, Ursino S, Cristaudo A, Colangelo F, Stefanelli A, Alghisi A, De Nobili G, D'Amico R, Cocchi A, Ardizzoia A, Soatti CP

META-ANALYSIS

- 9090** Clinical significance of breast cancer susceptibility gene 1 expression in resected non-small cell lung cancer: A meta-analysis

Gao Y, Luo XD, Yang XL, Tu D

CASE REPORT

- 9101** Particular tumor of the pancreas: A case report

Zhu MH, Nie CF

- 9108** Dynamic changes in the radiologic manifestation of a recurrent checkpoint inhibitor related pneumonitis in a non-small cell lung cancer patient: A case report

Tan PX, Huang W, Liu PP, Pan Y, Cui YH

- 9114** Spontaneous rupture of a mucinous cystic neoplasm of the liver resulting in a huge biloma in a pregnant woman: A case report

Kośnik A, Stadnik A, Szczepankiewicz B, Patkowski W, Wójcicki M

- 9122** Diagnosis and laparoscopic excision of accessory cavitated uterine mass in a young woman: A case report

Hu YL, Wang A, Chen J

- 9129** Unusual cervical foreign body - a neglected thermometer for 5 years: A case report

Yang L, Li W

- 9134** Long-term survival of a patient with pancreatic cancer and lung metastasis: A case report and review of literature

Yang WW, Yang L, Lu HZ, Sun YK

- 9144** Synchronous diagnosis and treatment of acute myeloid leukemia and chronic lymphocytic leukemia: Two case reports

Chen RR, Zhu LX, Wang LL, Li XY, Sun JN, Xie MX, Zhu JJ, Zhou D, Li JH, Huang X, Xie WZ, Ye XJ

- 9151** Conversion therapy of hepatic artery ligation combined with transcatheter arterial chemoembolization for treating liver cancer: A case report
Feng GY, Cheng Y, Xiong X, Shi ZR
- 9159** Hemophagocytic lymphohistiocytosis secondary to composite lymphoma: Two case reports
Shen J, Wang JS, Xie JL, Nong L, Chen JN, Wang Z
- 9168** Fatal visceral disseminated varicella-zoster virus infection in a renal transplant recipient: A case report
Wang D, Wang JQ, Tao XG
- 9174** Choriocarcinoma misdiagnosed as cerebral hemangioma: A case report
Huang HQ, Gong FM, Yin RT, Lin XJ
- 9182** Rapid progression of colonic mucinous adenocarcinoma with immunosuppressive condition: A case report and review of literature
Koseki Y, Kamimura K, Tanaka Y, Ohkoshi-Yamada M, Zhou Q, Matsumoto Y, Mizusawa T, Sato H, Sakamaki A, Umezu H, Yokoyama J, Terai S
- 9192** Temporary pacemaker protected transjugular intrahepatic portosystemic shunt in a patient with acute variceal bleeding and bradyarrhythmia: A case report
Yao X, Li SH, Fu LR, Tang SH, Qin JP
- 9198** Recurrent pyogenic liver abscess after pancreatoduodenectomy caused by common hepatic artery injury: A case report
Xie F, Wang J, Yang Q
- 9205** Transient ventricular arrhythmia as a rare cause of dizziness during exercise: A case report
Gao LL, Wu CH
- 9211** Successful management of infected right iliac pseudoaneurysm caused by penetration of migrated inferior vena cava filter: A case report
Weng CX, Wang SM, Wang TH, Zhao JC, Yuan D
- 9218** Anterior abdominal abscess - a rare manifestation of severe acute pancreatitis: A case report
Jia YC, Ding YX, Mei WT, Xue ZG, Zheng Z, Qu YX, Li J, Cao F, Li F
- 9228** Monteggia type-I equivalent fracture in a fourteen-month-old child: A case report
Li ML, Zhou WZ, Li LY, Li QW
- 9236** Diagnosis and treatment of primary pulmonary enteric adenocarcinoma: Report of Six cases
Tu LF, Sheng LY, Zhou JY, Wang XF, Wang YH, Shen Q, Shen YH
- 9244** Choroidal metastatic mucinous abscess caused by *Pseudomonas aeruginosa*: A case report
Li Z, Gao W, Tian YM, Xiao Y
- 9255** Diagnosis and treatment of acute graft-versus-host disease after liver transplantation: Report of six cases
Tian M, Lyu Y, Wang B, Liu C, Yu L, Shi JH, Liu XM, Zhang XG, Guo K, Li Y, Hu LS

- 9269** Hepatic portal venous gas without definite clinical manifestations of necrotizing enterocolitis in a 3-day-old full-term neonate: A case report
Yuan K, Chen QQ, Zhu YL, Luo F
- 9276** Emergence of lesions outside of the basal ganglia and irreversible damage to the basal ganglia with severe β -ketothiolase deficiency: A case report
Guo J, Ren D, Guo ZJ, Yu J, Liu F, Zhao RX, Wang Y
- 9285** Skeletal muscle metastasis with bone metaplasia from colon cancer: A case report and review of the literature
Guo Y, Wang S, Zhao ZY, Li JN, Shang A, Li DL, Wang M
- 9295** Biopsy-confirmed fenofibrate-induced severe jaundice: A case report
Lee HY, Lee AR, Yoo JJ, Chin S, Kim SG, Kim YS
- 9302** Missense mutation in *DYNC1H1* gene caused psychomotor developmental delay and muscle weakness: A case report
Ding FJ, Lyu GZ, Zhang VW, Jin H
- 9310** Isolated hepatic tuberculosis associated with portal vein thrombosis and hepatitis B virus coinfection: A case report and review of the literature
Zheng SM, Lin N, Tang SH, Yang JY, Wang HQ, Luo SL, Zhang Y, Mu D

ABOUT COVER

Editorial Board Member of *World Journal of Clinical Cases*, Rahul Gupta, MBBS, MCh, MD, Assistant Professor, Chief Doctor, Consultant Physician-Scientist, Surgeon, Department of Gastrointestinal Surgery, Synergy Institute of Medical Sciences, Dehradun 248001, Uttarakhand, India. rahul.g.85@gmail.com

AIMS AND SCOPE

The primary aim of *World Journal of Clinical Cases* (WJCC, *World J Clin Cases*) is to provide scholars and readers from various fields of clinical medicine with a platform to publish high-quality clinical research articles and communicate their research findings online.

WJCC mainly publishes articles reporting research results and findings obtained in the field of clinical medicine and covering a wide range of topics, including case control studies, retrospective cohort studies, retrospective studies, clinical trials studies, observational studies, prospective studies, randomized controlled trials, randomized clinical trials, systematic reviews, meta-analysis, and case reports.

INDEXING/ABSTRACTING

The WJCC is now indexed in Science Citation Index Expanded (also known as SciSearch®), Journal Citation Reports/Science Edition, Scopus, PubMed, and PubMed Central. The 2021 Edition of Journal Citation Reports® cites the 2020 impact factor (IF) for WJCC as 1.337; IF without journal self cites: 1.301; 5-year IF: 1.742; Journal Citation Indicator: 0.33; Ranking: 119 among 169 journals in medicine, general and internal; and Quartile category: Q3. The WJCC's CiteScore for 2020 is 0.8 and Scopus CiteScore rank 2020: General Medicine is 493/793.

RESPONSIBLE EDITORS FOR THIS ISSUE

Production Editor: Ji-Hong Lin; Production Department Director: Yun-Jie Ma; Editorial Office Director: Jin-Lei Wang.

NAME OF JOURNAL

World Journal of Clinical Cases

ISSN

ISSN 2307-8960 (online)

LAUNCH DATE

April 16, 2013

FREQUENCY

Thrice Monthly

EDITORS-IN-CHIEF

Dennis A Bloomfield, Sandro Vento, Bao-Gan Peng

EDITORIAL BOARD MEMBERS

<https://www.wjgnet.com/2307-8960/editorialboard.htm>

PUBLICATION DATE

October 26, 2021

COPYRIGHT

© 2021 Baishideng Publishing Group Inc

INSTRUCTIONS TO AUTHORS

<https://www.wjgnet.com/bpg/gerinfo/204>

GUIDELINES FOR ETHICS DOCUMENTS

<https://www.wjgnet.com/bpg/GerInfo/287>

GUIDELINES FOR NON-NATIVE SPEAKERS OF ENGLISH

<https://www.wjgnet.com/bpg/gerinfo/240>

PUBLICATION ETHICS

<https://www.wjgnet.com/bpg/GerInfo/288>

PUBLICATION MISCONDUCT

<https://www.wjgnet.com/bpg/gerinfo/208>

ARTICLE PROCESSING CHARGE

<https://www.wjgnet.com/bpg/gerinfo/242>

STEPS FOR SUBMITTING MANUSCRIPTS

<https://www.wjgnet.com/bpg/GerInfo/239>

ONLINE SUBMISSION

<https://www.f6publishing.com>



Synchronous diagnosis and treatment of acute myeloid leukemia and chronic lymphocytic leukemia: Two case reports

Rong-Rong Chen, Li-Xia Zhu, Lu-Lu Wang, Xue-Ying Li, Jia-Nai Sun, Mi-Xue Xie, Jing-Jing Zhu, De Zhou, Jian-Hu Li, Xin Huang, Wan-Zhuo Xie, Xiu-Jin Ye

ORCID number: Rong-Rong Chen 0000-0002-6729-7545; Li-Xia Zhu 0000-0002-8762-278X; Lu-Lu Wang 0000-0001-5408-8018; Xue-Ying Li 0000-0001-6388-3988; Jia-Nai Sun 0000-0002-5148-9489; Mi-Xue Xie 0000-0001-5388-3945; Jing-Jing Zhu 0000-0002-5129-7523; De Zhou 0000-0001-3498-3912; Jian-Hu Li 0000-0001-5179-5701; Xin Huang 0000-0002-5103-1223; Wan-Zhuo Xie 0000-0001-3179-2397; Xiu-Jin Ye 0000-0002-4553-2751.

Author contributions: Chen RR collected the patient's clinical data, reviewed the literature, and drafted the manuscript; Zhu LX was the patients' physician; Wang LL were involved in case analysis and treatment discussion; Ye XJ contributed to the drafting and revision of the manuscript; all authors issued final approval of the version to be submitted.

Informed consent statement:

Consent was obtained from relatives of the patient for publication of this report and any accompanying images.

Conflict-of-interest statement: The authors declare that they have no conflict of interest.

CARE Checklist (2016) statement:

The authors have read the CARE Checklist (2016), and the

Rong-Rong Chen, Li-Xia Zhu, Lu-Lu Wang, Xue-Ying Li, Jia-Nai Sun, Mi-Xue Xie, Jing-Jing Zhu, De Zhou, Jian-Hu Li, Xin Huang, Wan-Zhuo Xie, Xiu-Jin Ye, Department of Hematology, The First Affiliated Hospital, College of Medicine, Zhejiang University, Hangzhou 310003, Zhejiang Province, China

Corresponding author: Xiu-Jin Ye, PhD, Chief Doctor, Department of Hematology, The First Affiliated Hospital, College of Medicine, Zhejiang University, No. 79 Qingchun Road, Hangzhou 310003, Zhejiang Province, China. yxsunny@zju.edu.cn

Abstract

BACKGROUND

The concurrence of acute myeloid leukemia (AML) and chronic lymphocytic leukemia (CLL) is rare. Previous reports of such cases have focused mainly on clinical diagnosis and characteristics, so the mechanism remains unclear, and therapy options have been poorly explored.

CASE SUMMARY

Here, we report two cases of synchronous AML and CLL. Flow cytometry revealed two distinct abnormal cell populations (myeloblasts and lymphoid cells) according to scatter characteristics. CD5-positive B cell lymphoma with myeloid leukemia invasion was observed on lymph node biopsy. Chemotherapy regimens indicated for both AML and CLL were used in our patients, and our patients achieved complete response after chemotherapy. Next-generation sequencing of 88 genes was performed.

CONCLUSION

We conclude that early mutation and dysregulation at the hematopoietic stem cell stage and the accumulation of multiple rearrangements may cause the concurrence of CLL and AML. The treatment of infection and combination therapy aimed at the CLL component are significant in the management of patients with concurrent CLL and AML.

Key Words: Acute myeloid leukemia; Chronic lymphocytic leukemia; B-cell lymphoma-2 inhibitors; Therapy; Ten-eleven translocation-2; Case report

©The Author(s) 2021. Published by Baishideng Publishing Group Inc. All rights reserved.

manuscript was prepared and revised according to the CARE Checklist (2016).

Open-Access: This article is an open-access article that was selected by an in-house editor and fully peer-reviewed by external reviewers. It is distributed in accordance with the Creative Commons Attribution NonCommercial (CC BY-NC 4.0) license, which permits others to distribute, remix, adapt, build upon this work non-commercially, and license their derivative works on different terms, provided the original work is properly cited and the use is non-commercial. See: <http://creativecommons.org/licenses/by-nc/4.0/>

Manuscript source: Unsolicited manuscript

Specialty type: Hematology

Country/Territory of origin: China

Peer-review report's scientific quality classification

Grade A (Excellent): 0
Grade B (Very good): 0
Grade C (Good): 0
Grade D (Fair): 0
Grade E (Poor): 0

Received: March 28, 2021

Peer-review started: March 28, 2021

First decision: July 8, 2021

Revised: July 13, 2021

Accepted: September 3, 2021

Article in press: September 3, 2021

Published online: October 26, 2021

P-Reviewer: Giordano A

S-Editor: Ma YJ

L-Editor: A

P-Editor: Li JH



Core Tip: The concurrence of acute myeloid leukemia (AML) and chronic lymphocytic leukemia is rare, and patients with both diseases have a poor prognosis. The clinical features, include male predominance and a predilection for older patients, and the AML-M2 subtype is the most frequent subtype. Infection and rapid progression are the most common causes of death in these patients.

Citation: Chen RR, Zhu LX, Wang LL, Li XY, Sun JN, Xie MX, Zhu JJ, Zhou D, Li JH, Huang X, Xie WZ, Ye XJ. Synchronous diagnosis and treatment of acute myeloid leukemia and chronic lymphocytic leukemia: Two case reports. *World J Clin Cases* 2021; 9(30): 9144-9150

URL: <https://www.wjgnet.com/2307-8960/full/v9/i30/9144.htm>

DOI: <https://dx.doi.org/10.12998/wjcc.v9.i30.9144>

INTRODUCTION

With the application of flow cytometry and next-generation sequencing (NGS), the number of patients diagnosed with concurrent acute myeloid leukemia (AML) and B cell chronic lymphocytic leukemia (CLL) has dramatically increased recently. Patients with CLL have an increased risk of secondary neoplasms, especially cancers of the skin and lung[1]. Generally, the cases reported to date can be categorized into three types: (1) AML cases with treated CLL, in which alkylating agents and purine analogs such as fludarabine can cause treatment-related AML or MDS[2]; (2) AML cases with untreated CLL that remains undetected for a period of time[3]; and (3) Cases with synchronous diagnosis of AML and CLL (of which 21 have been reported since 1973) [4]. Infection and rapid progression are the most common causes of death in patients with both AML and CLL, which may be associated with the immune dysfunction induced by CLL.

The balance of antileukemia and anti-infection therapy remains challenging. Only one patient who received allogeneic hematopoietic stem cell (HSC) transplantation (allo-HSCT) after achieving complete remission after chemotherapy has been reported [5], and only two patients with concurrent de novo AML with inv(16) and CLL had a relatively good prognosis[4,6]. However, few of the reported cases have involved simultaneous treatment of both types of tumors or demethylation therapy. We report two cases with synchronous diagnosis of AML and CLL that were treated with chemotherapy directed at both the CLL and AML components.

CASE PRESENTATION

Chief complaints

Case 1: A 66-year-old man presented to our hospital in July 2020 with progressive enlargement of the right parotid gland and pancytopenia for over five months.

Case 2: A 62-year-old woman was hospitalized with fatigue and abnormal blood counts for one week in April 2020.

History of present illness

Case 1: The patient developed a mass on his left neck accompanied by fever five months ago. Then progressive enlargement of the right parotid gland followed. The patient went to a local hospital, and ultrasound indicated substantial mass in the right parotid gland and bilateral cervical lymph node enlargement. The mass shrank slightly after hormone and anti-infective therapy. The patient was later transferred to our hospital for further treatment. Right neck lymph node biopsy was performed, and the lymph node biopsy results returned a pathologic diagnosis of CD5-positive B cell lymphoma (small lymphocytic lymphoma (SLL)/CLL was considered first) with myeloid leukemia invasion (Figure 1A). Bone marrow examination indicated that the number of nucleated cells was increased, and myeloblasts accounted for 52% of cells. The FAB classification was M2a.

Case 2: The patient felt fatigue one week ago, and then went to the hospital for blood routine examination which indicated that the three blood lines were reduced. Bone

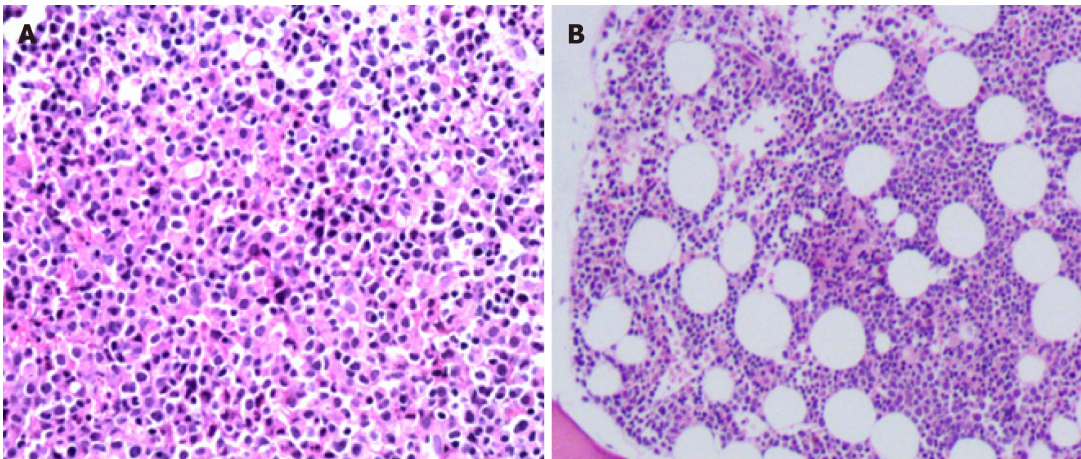


Figure 1 Pathological microscopic image with hematoxylin-eosin staining of lymph node biopsy in case once (A) and of marrow biopsy in case two (B).

marrow and immunophenotyping were performed. Bone marrow assessment showed that the number of nucleated cells was increased, and type I+II immature granulocytes accounted for 38% of these cells. The pathology results of the bone marrow biopsy showed diffuse distribution of immature cells and lamellar proliferation of lymphoid cells (Figure 1B).

History of past illness

Case 1: The patient had a history of hypertension for 20 years.

Case 2: The patient had no prior history of a hematolymphoid neoplasm or exposure to toxins or radiation.

Personal and family history

Case 1: There is nothing special about personal history. His parents died of "cancer". His sister suffered from bowel cancer.

Case 2: The patient had undergone cholecystectomy for gallbladder polyps and hysterectomy for hysteromyoma. There is nothing special about family history.

Physical examination

Case 1: Progressive enlargement of the right parotid gland.

Laboratory examinations

Case 1: Routine blood examination showed the following: white blood cells (WBCs) $3.04 \times 10^9/L$, lymphocyte ratio 58.9%, proportion of monocytes 10.9%, hemoglobin (HB) 93 g/L and platelets (PLTs) $68 \times 10^9/L$. His peripheral blood smear showed a few primitive naive cells (6%). Flow cytometric analysis showed a population of cells with moderately low side scatter (red, Figure 2A) and a separate population with high side scatter (green, Figure 2A): one population was positive for myeloblast markers (CD117, CD34, CD33, CD13, HLADR, CD38, and MPO), and the other population was positive for B lymphoid markers (CD19, CD5, CD22, CD20, CD23 (dim), CD200, and kappa light chain-restricted expression) and did not express CD103, FMC7, CD10, CD25, or sIgM. Thus, the patient's flow cytometry results clearly showed the concurrence of CLL and AML.

Immunohistochemical analysis of lymph node tissue showed the following: lymphocyte CD3 (-), CD20 (+), Ki-67 (+20%), Bcl-2 (+), CD5 (+), CD10 (-), CD23 (dim), cyclin D1 (-), CD21 (-), kappa (κ) (dim), lambda (λ) (dim), SOX11 (-), and TDT (-). The analysis of myeloid cells yielded the following results: MPO (+), Ki67 (+70%), CD34 (-), and CD117 (dim). Chromosome analysis revealed an abnormal karyotype: 45, XY, -7 [10]/46, XY[5]. NGS showed the following mutation frequencies in cells: ASXL1 34.3%, TET2 40.5%, STAG2 81.8%, CEBPA 38.9%, and ETV6 1.7%. The WHO classification was AML with CEBPA mutation. Bone marrow cells showed IgHV gene mutation, and the IgH rearrangement-positive mutation rate was 9.8%, suggesting a good prognosis.

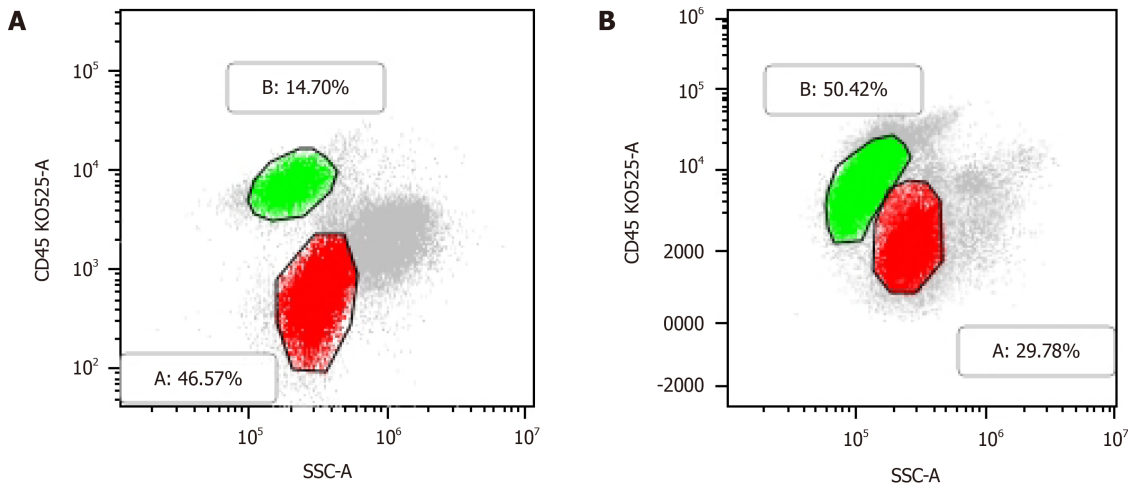


Figure 2 Flow cytometric analysis showed two separate populations of cells the red one positive for myeloblast markers (CD117, CD34, CD33, CD13, HLADR, CD38, MPO) and the green one for B lymphoid markers [CD19, CD5, CD22, CD20, CD23(weak), CD200, kappa light chain] in case one (A), and two separate populations of cells the red one positive for myeloblast markers (CD117, CD34, CD33, CD13, HLA-DR, CD38) and the green one for B lymphoid markers [CD19, CD5, CD22 (weak), CD20 (weak), CD23, CD200, Kappa light chain] in case two (B).

Case 2: Peripheral blood analysis showed WBCs $24.4 \times 10^9/L$, HB 113 g/L, PLTs $17 \times 10^9/L$ and abnormal cells 5%. Immunotyping of the leukemia cells showed the following: A primitive myeloid cell population (red, **Figure 2B**) (expressing CD117, CD34, CD 33, CD13, HLA-DR, and CD38) accounted for 29.78% of cells, and an abnormal B lymphocyte population (green, **Figure 2B**) (expressing CD19, CD5, CD22 (dim), CD20 (dim), CD23, CD200, and kappa light chain) accounted for approximately 50.42% of cells. NGS showed the following mutation frequencies in cells: CEBPA mutation 7.23%, GATA2 6.5%, NOTCH1 28.47%, and SF3B1 1.14%.

FINAL DIAGNOSIS

Case 1

(1) Synchronous CLL and AML; and (2) Pulmonary infection.

Case 2

The results of the bone marrow morphology and flow cytometric analyses indicated a diagnosis of AML-M1 and CLL.

TREATMENT

Case 1

The pulmonary infection, which was diagnosed at admission, partially responded to therapy with dexamethasone 10 mg/d, which was administered before leukemia treatment. Considering the poor physical condition of the patient and the desire for combination therapy, a low dose of combination cytarabine and azacytidine (azacytidine 130 mg d1-7 + cytarabine 20 mg Q12H d1-10) was used initially. Partial hematological remission after the first induction therapy was achieved by administration of the same chemotherapy regimen a second time. However, routine bone marrow monitoring after two cycles of this regimen indicated that immature granulocytes accounted for 38% of bone marrow cells. Minimum residual disease (MRD) monitoring showed a residual cancer cell proportion of 36.149%, suggesting that the patient was not in remission. Therefore, the treatment regimen was changed. Two courses of the Bcl-2 inhibitor Venclexta (100 mg d1-28) combined with azacytidine (130 mg d1-7) were administered; surprisingly, both bone marrow and molecular remission were obtained. Pulmonary fungal infection occurred during the patient's hospital stay, and the dose of Bcl-2 inhibitor was adjusted for concomitant

use with the antifungal drug posaconazole.

Case 2

The HA regimen (homoharringtonine (HHT) 4 mg d1–5 and cytarabine 150 mg d1–5) combined with a low dose of hormonal therapy (30 mg/d) was used as induction chemotherapy. Complete remission of the AML component was obtained after the first course of chemotherapy (with bone marrow immature granulocytes accounting for 2% of cells). Then, cytarabine and VP-16 (cytarabine 4 g d1/3/5 and VP-16 100 mg d1–5) treatment was administered once as consolidation chemotherapy. Next, HA+VP (HHT 4 mg d1–5, cytarabine 150 mg d1–7, vincristine 4 mg d1/8 and dexamethasone 10 mg d1–8) was administered as maintenance therapy, and MRD negativity (abnormal B lymphocytes < 0.01%) occurred after three cycles of HA+VP.

OUTCOME AND FOLLOW-UP

Case 1

The patient had low PLTs although bone marrow remission was achieved, and he is currently waiting for a bone marrow transplant.

Case 2

The patient achieved remission but refused a bone marrow transplant.

DISCUSSION

With flow cytometry becoming a reliable detection method to diagnose the coexistence of CLL and AML, understanding the mechanisms underlying such cases and exploring treatments have become urgent. Patients with CLL and AML always have poor prognoses. The clinical features, as Rui Zhang *et al* summarized, include a male predominance and predilection for older patients, and AML-M2 is the most frequent subtype[7]. The unique aspects of our cases include the following: (1) The NGS results of our cases provide insight into the underlying mechanisms; and (2) The complete chemotherapy regimens were administered in the process of treatment.

The majority of recent studies support the idea that CLL and AML originate from two separate cell types[6,8,9]. However, some researchers maintain that AML and CLL cells share the same origin[7]. The myeloid and lymphoid lineages evolve from common progenitor cells called primitive HSCs. The occurrence of simultaneous hematologic tumors may be triggered by an early defect at the level of pluripotent stem cells, resulting in the simultaneous development of two tumorigenic processes [10–12]. To date, no specific genetic or chromosomal mutations that are clearly associated with the synchronous development of CLL and AML have been identified. However, complex chromosomal rearrangements occur in most cases, as do cytogenetic abnormalities[4]. Mutations affecting epigenetic modulators (TET2 40.5% and ASXL1 34.3%), cohesion proteins (STAG2 81.8%), and the cell cycle and differentiation (CEBPA 38.9%) have been discovered by previous NGS studies. TET2, a member of the ten-eleven translocation (TET) family, largely participates in regulating lymphoid and myeloid differentiation and function and may contribute to the development of multiple hematological malignancies[13,14]. Viny *et al*[15] proposed that STAG2 mutation may represent a transformative event in a primed premalignant clone. The other genetic mutations observed in the NGS results of the second case (CEBPA 7.23%, GATA2 6.5%, and NOTCH1 28.47%) occur primarily in AML. Our study supports the view that early mutation and dysregulation at the HSC stage and the accumulation of multiple rearrangements cause the concurrence of CLL and AML.

Timely treatment of AML is necessary due to the nature of the disease. However, CLL is associated with profound immunosuppression, which results in both impaired antitumor responses and increased susceptibility to infection[16]. To date, few successful chemotherapy attempts have been made. The difficulty in finding effective therapy may be related to the fact that patients with both AML and CML often have concurrent opportunistic infections and older age. Therefore, anti-infection and combination treatment for the CLL component are equally important in the management of these patients.

Two effective therapeutic options were used in our cases (Venclexta combined with azacytidine and HA+VP). DiNardo *et al*[17] concluded that azacitidine-venetoclax

significantly improved the response and prolonged overall survival (OS) compared with azacitidine alone in previously untreated AML patients. BCL-2 inhibitors have been proven to provide good therapeutic responses in CLL patients[18,19]. TET-2 mutation was detected by NGS in the first case, and epigenetic silencing is known to play an important role in the pathogenesis of CLL[20]. Therefore, BCL-2 inhibitors plus azacitidine might be a good treatment option for CLL patients. Because patients similar to the one in case 2 generally have advanced age and susceptibility to infection, a simple, modified combination regimen for first-line treatment of AML and CLL (HA+VP) was chosen as intensive chemotherapy in the second case. However, for this rare high-risk subtype of hematologic tumor, allo-HSCT is still the ultimate goal of therapy.

CONCLUSION

Our data support the view that early mutation and dysregulation at the HSC stage and the accumulation of multiple rearrangements may cause the concurrence of CLL and AML. The treatment of infection and combination therapy aimed at CLL are significant in the management of patients with concurrent CLL and AML.

REFERENCES

- 1 Schöllkopf C, Rosendahl D, Rostgaard K, Pipper C, Hjalgrim H. Risk of second cancer after chronic lymphocytic leukemia. *Int J Cancer* 2007; **121**: 151-156 [PMID: 17351903 DOI: 10.1002/ijc.22672]
- 2 Robertson LE, Estey E, Kantarjian H, Koller C, O'Brien S, Brown B, Keating MJ. Therapy-related leukemia and myelodysplastic syndrome in chronic lymphocytic leukemia. *Leukemia* 1994; **8**: 2047-2051 [PMID: 7807993]
- 3 Lai R, Arber DA, Brynes RK, Chan O, Chang KL. Untreated chronic lymphocytic leukemia concurrent with or followed by acute myelogenous leukemia or myelodysplastic syndrome. A report of five cases and review of the literature. *Am J Clin Pathol* 1999; **111**: 373-378 [PMID: 10078113 DOI: 10.1093/ajcp/111.3.373]
- 4 Shoyele O, Gupta G. Synchronous Diagnosis of *De Novo* Acute Myeloid Leukemia with inv(16)(p13q22) and Chronic Lymphocytic Leukemia: A Case Report and Review of the Literature. *Ann Clin Lab Sci* 2018; **48**: 790-796 [PMID: 30610052]
- 5 DeFilipp Z, Huynh DV, Fazal S, Sahovic E. Allogeneic stem cell transplantation for acute myeloid leukemia with del(7q) following untreated chronic lymphocytic leukemia. *Hematol Oncol Stem Cell Ther* 2012; **5**: 165-168 [PMID: 23095794 DOI: 10.5144/1658-3876.2012.165]
- 6 Lu CM, Murata-Collins JL, Wang E, Siddiqi I, Lawrence H. Concurrent acute myeloid leukemia with inv(16)(p13.1q22) and chronic lymphocytic leukemia: molecular evidence of two separate diseases. *Am J Hematol* 2006; **81**: 963-968 [PMID: 16917916 DOI: 10.1002/ajh.20716]
- 7 Zhang R, Kim YM, Lu X, Wang X, Pang H, Li Y, Li S, Lee JY. Characterization of a novel t(2;5;11) in a patient with concurrent AML and CLL: a case report and literature review. *Cancer Genet* 2011; **204**: 328-333 [PMID: 21763630 DOI: 10.1016/j.cancergen.2011.04.006]
- 8 Ornellas De Souza MH, de Souza Fernandez T, Diamond HR, Maioli MC, Pitanga Bacha PC, De Lucena SB. Cytogenetic and immunophenotypic evidence of independent clonal origins of concomitant chronic lymphocytic leukaemia and acute myeloid leukaemia. *Eur J Haematol* 2001; **66**: 281-283 [PMID: 11380608 DOI: 10.1034/j.1600-0609.2001.066004281.x]
- 9 Gottardi M, Gattei V, Degan M, Bomben R, Zucchetto A, Tecchio C, Laurino L, Zanatta L, Dei Tos AP, Mordacchini M, Canal F, Gherlinzoni F. Concomitant chronic lymphocytic leukemia and acute myeloid leukemia: evidence of simultaneous expansion of two independent clones. *Leuk Lymphoma* 2006; **47**: 885-889 [PMID: 16753874 DOI: 10.1080/10428190500404761]
- 10 Lima M, Porto B, Rodrigues M, Teixeira MA, Coutinho J, Ribeiro AC, Malheiro MI, Justiça B. Cytogenetic findings in a patient presenting simultaneously with chronic lymphocytic leukemia and acute myeloid leukemia. *Cancer Genet Cytogenet* 1996; **87**: 38-40 [PMID: 8646738 DOI: 10.1016/0165-4608(95)00262-6]
- 11 Kikushige Y, Miyamoto T. Hematopoietic stem cell aging and chronic lymphocytic leukemia pathogenesis. *Int J Hematol* 2014; **100**: 335-340 [PMID: 25100497 DOI: 10.1007/s12185-014-1651-6]
- 12 Kikushige Y, Miyamoto T. Pre-malignant lymphoid cells arise from hematopoietic stem/progenitor cells in chronic lymphocytic leukemia. *Int J Hematol* 2015; **102**: 528-535 [PMID: 25644149 DOI: 10.1007/s12185-015-1740-1]
- 13 Cong B, Zhang Q, Cao X. The function and regulation of TET2 in innate immunity and inflammation. *Protein Cell* 2021; **12**: 165-173 [PMID: 33085059 DOI: 10.1007/s13238-020-00796-6]
- 14 Lio CJ, Rao A. TET Enzymes and 5hmC in Adaptive and Innate Immune Systems. *Front Immunol* 2019; **10**: 210 [PMID: 30809228 DOI: 10.3389/fimmu.2019.00210]
- 15 Viny AD, Levine RL. Cohesin mutations in myeloid malignancies made simple. *Curr Opin Hematol*

- 2018; **25**: 61-66 [PMID: [29278534](#) DOI: [10.1097/MOH.0000000000000405](#)]
- 16 **Forconi F**, Moss P. Perturbation of the normal immune system in patients with CLL. *Blood* 2015; **126**: 573-581 [PMID: [26084672](#) DOI: [10.1182/blood-2015-03-567388](#)]
- 17 **DiNardo CD**, Jonas BA, Pullarkat V, Thirman MJ, Garcia JS, Wei AH, Konopleva M, Döhner H, Letai A, Fenaux P, Koller E, Havelange V, Leber B, Esteve J, Wang J, Pejsa V, Hájek R, Porkka K, Illés Á, Lavie D, Lemoli RM, Yamamoto K, Yoon SS, Jang JH, Yeh SP, Turgut M, Hong WJ, Zhou Y, Potluri J, Pratz KW. Azacitidine and Venetoclax in Previously Untreated Acute Myeloid Leukemia. *N Engl J Med* 2020; **383**: 617-629 [PMID: [32786187](#) DOI: [10.1056/NEJMoa2012971](#)]
- 18 **Cang S**, Iragavarapu C, Savooji J, Song Y, Liu D. ABT-199 (venetoclax) and BCL-2 inhibitors in clinical development. *J Hematol Oncol* 2015; **8**: 129 [PMID: [26589495](#) DOI: [10.1186/s13045-015-0224-3](#)]
- 19 **Roberts AW**, Davids MS, Pagel JM, Kahl BS, Puvvada SD, Gerecitano JF, Kipps TJ, Anderson MA, Brown JR, Gressick L, Wong S, Dunbar M, Zhu M, Desai MB, Cerri E, Heitner Enschede S, Humerickhouse RA, Wierda WG, Seymour JF. Targeting BCL2 with Venetoclax in Relapsed Chronic Lymphocytic Leukemia. *N Engl J Med* 2016; **374**: 311-322 [PMID: [26639348](#) DOI: [10.1056/NEJMoa1513257](#)]
- 20 **Tong WG**, Wierda WG, Lin E, Kuang SQ, Bekele BN, Estrov Z, Wei Y, Yang H, Keating MJ, Garcia-Manero G. Genome-wide DNA methylation profiling of chronic lymphocytic leukemia allows identification of epigenetically repressed molecular pathways with clinical impact. *Epigenetics* 2010; **5**: 499-508 [PMID: [20484983](#) DOI: [10.4161/epi.5.6.12179](#)]



Published by **Baishideng Publishing Group Inc**
7041 Koll Center Parkway, Suite 160, Pleasanton, CA 94566, USA

Telephone: +1-925-3991568

E-mail: bpgoffice@wjgnet.com

Help Desk: <https://www.f6publishing.com/helpdesk>

<https://www.wjgnet.com>

