

Replies to Reviewers

Reviewer #1:

Scientific Quality: Grade C (Good)

Language Quality: Grade B (Minor language polishing)

Conclusion: Accept (General priority)

Specific Comments to Authors: The authors of the paper have in their paper "Transcanal endoscopic type III tympanoplasty" have attempted to report long-term outcomes of simultaneous bilateral stapedotomy/stapedectomy. Though the attempt is laudable, I have several issues with the paper.

1- Why authors performed CTA/V, 4D flow MR and DSA together?

Reply: Thanks for your comment.

In the past ten years, thousands of patients with pulsatile tinnitus (PT) have come to our hospital. CTA/V has been used as a screening tool for PT outpatients with normal otoscopic findings. After CTA/V examination, multiple abnormal morphologic signs at different locations associated with PT are often observed [1], but it is still not clear which sign is mostly responsible for PT. Therefore, for hospitalized patients who want to undergo surgical treatment, 4D flow MRI examination will be performed to further evaluate the hemodynamic characteristics such as blood flow, velocity, blood flow pattern to narrow the diagnostic scope [2]. Then, DSA will be performed to exclude arteriovenous malformations and arteriovenous fistulas before the surgery.

For this patient, possible associated signs including a dilated-vine diploic vein (DV), transverse sinus stenosis, ipsilateral outflow dominance, multiple small dehiscence of sigmoid sinus sulcus wall and high jugular bulb were found on CTA/V. 4D flow MR showed that the blood flow in the DV ran toward the transverse-sigmoid sinus in all phases of the cardiac cycle, and the velocity in the transverse sinus obviously increased after the inflow of the DV, while the

flow pattern in the sigmoid sinus was regular. Thus, the DV was thought of as the mostly responsible sign for this patient. DSA was further performed to evaluate the characteristics of DV and to exclude minor vascular malformations and fistulas.

2- what means: "The pre//postoperative maximum through-plane velocity and average through-plane velocity of the transverse sinus were 59.1 cm/s/107.3 cm/s and 26.1 cm/s/23.3 cm/s, respectively."

Reply: Thanks for your comment.

The meaning of this sentence is not clear here. We have revised it as follows:

The pre-operative maximum through-plane velocity and average through-plane velocity of the transverse sinus were 59.1 cm/s/ and 26.1 cm/s, while the post-operative maximum through-plane velocity and average through-plane velocity of the transverse sinus were 107.3 cm/s and 23.3 cm/s, respectively. The maximum and average through-plane velocity were measured according to the article of li Y et al's (figure 1) [3].

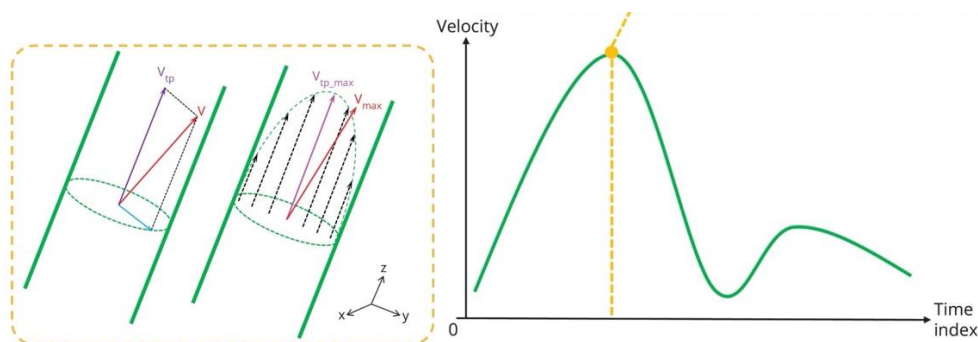


Figure 1 The definition of flow measures For a certain voxel inside the contour, the magnitude of velocity (cm/s) is denoted as V , and through-plane velocity is denoted as V_{tp} . By evaluating all voxels inside the contour, we define maximum velocity (V_{max} , cm/s) and maximum through-plane velocity (V_{tp_max} , cm/s) at the time index when peak velocity appears.

3- Are authors received informed consent and the ethical board approval?

Reply: Thanks for your comment.

Reply: Informed consent was obtained from the patient. This study was approved by the ethics committee in our institution.

References

- [1] Dong C, Zhao PF, Yang JG, Liu ZH, Wang ZC. Incidence of Vascular Anomalies and Variants Associated with Unilateral Venous Pulsatile Tinnitus in 242 Patients Based on Dual-phase Contrast-enhanced Computed Tomography. *Chinese Med J-Peking*, 2015, 128(5):581-585.
- [2] Li X, Qiu X, Ding H, Lv H, Zhao P, Yang Z, Gong S, Wang Z. Effects of different morphologic abnormalities on hemodynamics in patients with venous pulsatile tinnitus: A four-dimensional flow magnetic resonance imaging study. *J Magn Reson Imaging*, 2021, 53(6):1744-1751.
- [3] Li Y, Chen H, He L, Cao X, Wang X, Chen S, Li R, Yuan C. Hemodynamic assessments of venous pulsatile tinnitus using 4D-flow MRI. *Neurology*, 2018, 91(6):e586-e593.

Reviewer #2:

Scientific Quality: Grade B (Very good)

Language Quality: Grade A (Priority publishing)

Conclusion: Accept (General priority)

Specific Comments to Authors: It would be better if you explain in details the final diagnosis.

Reply: Thanks for your suggestion.

The final diagnosis has been revised as follows: PT caused by a dilated-vine DV connecting with mastoid air cavities.