

ALL IMAGES VIDEOS

30,200 Results

Any time ▾

Open links in new tab **[PDF] Primary malignant pericardial tumour in Lynch ... - BMC ...**<https://bmccancer.biomedcentral.com/track/pdf/10.1186/s12885-020-6677-y>

Background: This case represents the first report of malignant primary cardiac tumour in a patient with Lynch Syndrome associated with MSH2 pathogenic variant. Case presentation: A 57-year-old woman...

Neoplastic Pericardial Effusion | Request PDF<https://www.researchgate.net/publication/51652628...>

Patients with neoplastic pericardial effusion face a grave prognosis, as their malignancy is usually more advanced. ... Herein we report the first case, to our knowledge, of a patient with DLBCL ...

Primary malignant pericardial tumour in Lynch ... - BMC Cancer<https://bmccancer.biomedcentral.com/articles/10.1186/s12885-020-6677-y>

Mar 06, 2020 - This case represents the first report of malignant primary cardiac tumour in a patient with Lynch Syndrome associated with MSH2 pathogenic variant. A 57-year-old woman with previous...

Cited by: 1

Author: Pasquale Paolisso, Giulia Satri, Alberto ...

Publish Year: 2020

Management of pericardial effusion | Request PDF<https://www.researchgate.net/publication/232813825...>

Commonly found in cancer patients, pericardial effusion (PE) has been reported in up to 21% of patients with underlying malignancy [8] and has been shown to affect patient survival [7,9].

(PDF) Enterobacter cloacae pericardial effusion in a frail ...<https://www.researchgate.net/publication/272517806...>

Enterobacter cloacae pericardial effusion in a frail elderly patient. February 2015; BMJ Case Reports 2015(feb19 1) 2015(feb19 1)

Severe Pericardial Effusion in Patients with Concurrent ...<https://www.researchgate.net/publication/51422545...>

Between January 1999 and August 2004, 55 eligible patients were admitted in the ICU for pericardial effusion, including 30 with lung cancer, 9 with breast cancer, 5 with hematological malignancies ...

ALL IMAGES VIDEOS

30,900 Results

Any time

Neoplastic Pericardial Effusion | Request PDF<https://www.researchgate.net/publication/51652628...>

Patients with neoplastic pericardial effusion face a grave prognosis, as their malignancy is usually more advanced. ... we report a case of a previously healthy 11-year-old male who presented to ...

Estimated Reading Time: 7 mins

Severe Pericardial Effusion in Patients with Concurrent ...<https://www.researchgate.net/publication/51422545...>

Between January 1999 and August 2004, 55 eligible patients were admitted in the ICU for pericardial effusion, including 30 with lung cancer, 9 with breast cancer, 5 with hematological malignancies ...

(PDF) Enterobacter cloacae pericardial effusion in a frail ...<https://www.researchgate.net/publication/272517806...>

Enterobacter cloacae pericardial effusion in a frail elderly patient. February 2015; BMJ Case Reports

Primary malignant pericardial tumour in Lynch ... - BMC Cancer<https://bmccancer.biomedcentral.com/articles/10.1186/s12885-020-6677-y>

Mar 06, 2020 · This case represents the first report of malignant primary cardiac tumour in a patient with Lynch Syndrome associated with MSH2 pathogenic variant. A 57-year-old woman with previous ovarian cystadenocarcinoma was admitted to the emergency room for hematic pericardial effusion. Multimodal diagnostic imaging revealed two solid pericardial vascularized masses.

Cited by: 1

Author: Pasquale Paolitto, Giulia Satri, Alberto Fo...

Publish Year: 2020 Estimated Reading Time: 10 mins

(PDF) Characteristics of neoplastic cardiac tamponade and ...<https://www.researchgate.net/publication/272078796...>

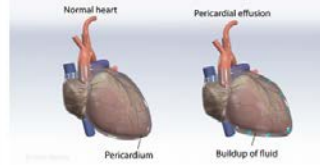
This case highlights the extreme severity of pericardial effusion, a sign of progressive disease, secondary to pancreatic cancer. In the case of neoplastic pericardial effusion, an extremely poor ...

Diagnostic issues in the clinical management of ...<https://onlinelibrary.wiley.com/doi/full/10.1111/j.1742-1241.2009.02178.x>

Aug 16, 2010 · In a report of 450 consecutive patients, neoplastic aetiology was found in 33 of 450 patients with acute pericardial disease (7.3%). Acute pericardial disease (acute pericarditis and cardiac tamponade) was the first manifestation of previously unknown malignancies in 18 of 450 patients (4.0%), and lung cancer was the most common malignancy (72.2%).

Fluid Around the Lung or Malignant Pleural Effusion**Pericardial Effusion**

Medical Condition

Abnormal accumulation of fluid in the pericardium

A condition with the accumulation of too much fluid in the pericardium, a sac surrounding the heart. Mild cases are not harmful, but sometimes it may affect the functioning of the heart.

Rare (Fewer than 200,000 cases per year in US)

Requires lab test or imaging

Treatable by a medical professional

Can last several days or weeks

It caused by the injury or disease which leads to the accumulation of fluid in the pericardium. Shortness of breath, orthopnea - difficulty breathing while lying, chest pain and chest fullness are the commonly observed symptoms. Treatment depends on the amount of fluid that has accumulated, the cause of the effusion and probability of developing cardiac tamponade.

Symptoms

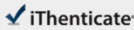
Commonly noted symptoms are as follows:

- Shortness of breath
- Orthopnea - difficulty in breathing while lying down
- Chest pain
- Chest fullness
- Light-headedness

18 May 2021 02:03:14

3040 words • 7 matches • 5 sources

PAG 2

iThenticate®

66487-check.docx

Quotes Excluded
Bibliography Excluded

5%
5000 / 100

Name of Journal: *World Journal of Clinical Cases*

Manuscript NO: 66487

Manuscript Type: CASE REPORT

Fruquintinib beneficial in elderly patient with neoplastic pericardial effusion from rectal cancer: A case report

Fruquintinib beneficial in elderly patient

Ying Zhang, Jia-Yun Zou, Yan-Yan Xu, Jing-Ni He

Abstract

BACKGROUND

Neoplastic pericardial effusion (NPE) is a rare consequence of rectal cancer and carries a poor prognosis. Optimal management has yet to be determined. Fruquintinib is an oral anti-vascular endothelial growth factor receptor tyrosine kinase inhibitor approved by the China Food and Drug Administration in September 2018 as third-line treatment of metastatic colorectal cancer.

Match Overview

1

Internet 52 words
crawled on 03-Oct-2020
www.dovepress.com

2%

2

Internet 17 words
crawled on 07-Aug-2018
onlinelibrary.wiley.com

1%

3

Internet 16 words
crawled on 15-Oct-2019
www.internationaljournal.com

1%

4

Crossref 12 words
Matt Shirley, "Fruquintinib: First Global Approval", *Drugs*, 2018

1%

5

Internet 12 words
crawled on 17-Jun-2019
pancreas.imedpub.com

1%

激活 Windows

转到"设置"以激活 Windows。

PAGE: 1 OF 12

Test Only Report

国内版 国际版

Fruquintinib beneficial in elderly patient with neoplastic pericardial effusion



ALL

IMAGES

VIDEOS

31,100 Results

Any time ▾

Neoplastic Pericardial Effusion | Request PDF

<https://www.researchgate.net/publication/51652628...>

Neoplastic pericardial effusion is a serious and common clinical disorder encountered by cardiologists, cardiothoracic surgeons, oncologists, and radiation oncologists. It may develop from dire...

Estimated Reading Time: 7 mins

[PDF] Primary malignant pericardial tumour in Lynch ... - BMC ...

<https://bmccancer.biomedcentral.com/track/pdf/10.1186/s12885-020-6677-y>

Background: This case represents the first report of malignant primary cardiac tumour in a patient with Lynch Syndrome associated with MSH2 pathogenic variant. Case presentation: A 57-year-old woman...

(PDF) Enterobacter cloacae pericardial effusion in a frail ...

<https://www.researchgate.net/publication/272517806...>

We report a case of a frail 82-year-old man with seronegative rheumatoid arthritis and a recent pacemaker insertion, admitted with pulmonary oedema and a symptomatic pericardial effusion. He...

Severe Pericardial Effusion in Patients with Concurrent ...

<https://www.researchgate.net/publication/51422545...>

Between January 1999 and August 2004, 55 eligible patients were admitted in the ICU for pericardial effusion, including 30 with lung cancer, 9 with breast cancer, 5 with hematological malignancies ...

Primary malignant pericardial tumour in Lynch ... - BMC Cancer

<https://bmccancer.biomedcentral.com/articles/10.1186/s12885-020-6677-y>

Mar 06, 2020 · This case represents the first report of malignant primary cardiac tumour in a patient with Lynch Syndrome associated with MSH2 pathogenic variant. A 57-year-old woman with previous...

Cited by: 1

Author: Pasquale Paolisso, Giulia Satri, Alberto ...

Publish Year: 2020

Estimated Reading Time: 10 mins

(PDF) Characteristics of neoplastic cardiac tamponade and ...

<https://www.researchgate.net/publication/272078796...>

This case highlights the extreme severity of pericardial effusion, a sign of progressive disease, secondary to pancreatic cancer. In the case of neoplastic pericardial effusion, an extremely poor ...