

ALL

IMAGES

VIDEOS

44,400 Results

Any time ▾

### Intrahepatic biliary cystadenoma: A case report

<https://pubmed.ncbi.nlm.nih.gov/33344559>

Background: Biliary cystadenoma (BCA) is a rare benign tumor, accounting for only 5% of reported cystic lesions of the liver. Given its potential for malignancy and high rate of recurrence, surgical resection is the preferred treatment. Therefore, early and accurate preoperative diagnosis is critical to the choice of treatment. We here **report** the first male **case** of BCA in our hospital, ...

**Author:** Ruo-Mei Xu, Xiao-Ru Li, Lin-Han L... **Publish Year:** 2020

### Intrahepatic biliary cystadenoma: A case report

<https://www.researchgate.net/publication/347161590...>

Download Citation | **Intrahepatic biliary cystadenoma: A case report** | Background: Biliary cystadenoma (BCA) is a **rare** benign tumor, accounting ...

### Giant biliary cystadenoma: a case report.

<https://www.ncbi.nlm.nih.gov/pubmed/21780527>

**Biliary cystadenoma** is a very **rare** benign cystic tumour of the liver. Fewer than 150 **cases** have been described in the literature so far. The authors present a **case** of a 29-year-old female with a giant **intrahepatic biliary cystadenoma** who presented ...

**Cited by:** 1

**Author:** F. Čečka, A. Ferko, Z. Šubrt, B. Jon

**Publish Year:** 2011

### (PDF) Episodic biliary obstruction due to an intrahepatic ...

<https://www.researchgate.net/publication/38094105...>

Sep 08, 2009 · **Biliary cystadenoma** (BCA) is a **rare neoplasm** of the bile duct with malignant potential. We report a **case** of **intrahepatic BCA** with an ...

**Estimated Reading Time:** 5 mins

### [PDF] Case report Episodic biliary obstruction due to an ...

<https://jmedicalcasereports.biomedcentral.com/track/pdf/10.4076/1752-1947-3-9032>

enhanced computed tomography findings and histology revealed an **intrahepatic** mucinous

### Intrahepatic biliary cystadenoma: A case report

<https://pubmed.ncbi.nlm.nih.gov/33344559>

**Background:** Biliary cystadenoma (BCA) is a rare benign tumor, accounting for only 5% of reported cystic lesions of the liver. Given its potential for malignancy and high rate of recurrence, surgical resection is the preferred treatment. Therefore, early and accurate preoperative diagnosis is ...

Author: Ruo-Mei Xu, Xiao-Fu Li, Lin-Han Liu, We... Publish Year: 2020

### Giant biliary cystadenoma: a case report.

<https://www.ncbi.nlm.nih.gov/pubmed/21780527>

**Biliary cystadenoma** is a very rare benign cystic tumour of the liver. Fewer than 150 cases have been described in the literature so far. The authors present a case of a 29-year-old female with a giant intrahepatic biliary cystadenoma who presented with abdominal pain and obstructive jaundice.

Cited by: 1      Author: F. Čečka, A. Ferko, Z. Šubrt, B. Jon

Publish Year: 2011

**IPD® A case of biliary cystadenoma with obstructive jaundice**

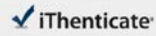
<https://www.spandidos-publications.com/10.3892/or.5.4.833/download>

It is rare that intrahepatic biliary cystadenoma will be the chief presenting complaint due to a biliary obstruction [3,7], although some extrahepatic cases have been reported [5]. Cappelli reported that tumor size above 12 cm was the dominant factor for biliary obstruction in ...

[PDF] Case Report: Biliary cystadenoma and choledochal polyp: a ...

## Search Tools

Turn off Hover Translation (关闭取词)



66742-Crosscheck.docx

Quotes Excluded  
Bibliography Excluded2%  
(selected)**Name of Journal:** *World Journal of Clinical Cases***Manuscript NO:** 66742**Manuscript Type:** CASE REPORT**Rare monolocular intrahepatic biliary cystadenoma: A case report**Che CH *et al.* IBC that lacks internal septations.

Chen-Hao Che, Zhen-Hua Zhao, Hui-Ming Song, Yuan-Yuan Zheng

**Received:** April 19, 2021**Revised:** May 27, 2021**Accepted:****Published online:**

## Match Overview

1 Internet: 59 words  
created on 04-Mar-2021  
[www.ejnet.com](http://www.ejnet.com)2%  
(selected)

PAGE: 1 OF 10

Text Only Report

国内版

国际版

Rare monolocular intrahepatic biliary cystadenoma: A case report



ALL

IMAGES

VIDEOS

9,030 Results

Any time ▾

### [Intrahepatic biliary cystadenoma: A case report](https://pubmed.ncbi.nlm.nih.gov/33344559)

<https://pubmed.ncbi.nlm.nih.gov/33344559>

Background: Biliary cystadenoma (BCA) is a rare benign tumor, accounting for only 5% of reported cystic lesions of the liver. Given its potential for malignancy and high rate of recurrence, surgical resection is the preferred treatment. Therefore, early and accurate preoperative diagnosis is ...

Author: Ruo-Mei Xu, Xiao-Ru Li, Lin-Han Liu, ... Publish Year: 2020

### [Misdiagnosis of Intrahepatic Biliary Cystadenoma Located ...](https://pubmed.ncbi.nlm.nih.gov/30947661)

<https://pubmed.ncbi.nlm.nih.gov/30947661>

Background: Intrahepatic Biliary Cystadenoma (IBC) is rare but has a high incidence of misdiagnosis, especially for experienceless surgeons. Case: We report a case of IBC located in the caudate lobe and described a typical procedure of misdiagnosing this disease. Finally, the patient was successfully cured, but the procedure of misdiagnosis should attract attention.

### [Giant biliary cystadenoma: a case report.](https://www.ncbi.nlm.nih.gov/pubmed/21780527)

<https://www.ncbi.nlm.nih.gov/pubmed/21780527>

Biliary cystadenoma is a very rare benign cystic tumour of the liver. Fewer than 150 cases have been described in the literature so far. The authors present a case of a 29-year-old female with a giant intrahepatic biliary cystadenoma who presented with abdominal pain and obstructive jaundice.

Cited by: 1 Author: F. Čečka, A. Ferko, Z. Šubr, B. Jon

Publish Year: 2011

### [\[PDF\] A case of biliary cystadenoma with obstructive jaundice](https://www.spandidos-publications.com/10.3892/or.5.4.833/download)

<https://www.spandidos-publications.com/10.3892/or.5.4.833/download>

It is rare that intrahepatic biliary cystadenoma will be the chief presenting complaint due to a biliary obstruction (3,7), although some extrahepatic cases have been reported (5). Cappell reported that tumor size above 12 cm was the dominant factor for biliary obstruction in ...

### [Unilocular Extrahepatic Biliary Cystadenoma Mimicking ...](https://www.ncbi.nlm.nih.gov/pmc/articles/PMC2698174)

<https://www.ncbi.nlm.nih.gov/pmc/articles/PMC2698174>

Dec 31, 2004 · DISCUSSION. Biliary cystadenoma is a rare benign cystic neoplasm that usually occurs in middle-aged women (1, 3, 4). The majority of biliary cystadenomas are entirely intrahepatic,