

Microsoft Bing

国内版 国际版

Rare hepatocellular carcinoma with inferior vena cava and right atri

ALL

IMAGES

VIDEOS

60,100 Results Any time

Hepatocellular carcinoma with inferior vena cava and right ...

<https://pubmed.ncbi.nlm.nih.gov/31661575>

This is a case report of a 45-year-old patient admitted with the symptom of bilateral leg swelling. Ultrasonography revealed a hyperechoic mass in the right lobe of the liver, which invaded the right hepatic vein (RHV) and extended into the inferior vena cava (IVC) and right atrium (RA).

Cited by: 1

Author: Meihua Chen, Xuning Huang, Qianyu Yang

Publish Year: 2019

Hepatocellular carcinoma with inferior vena cava and right ...

<https://onlinelibrary.wiley.com/doi/abs/10.1111/echo.14520>

Oct 29, 2019 · Abstract This is a case report of a 45-year-old patient admitted with the symptom of bilateral leg swelling. Ultrasonography revealed a hyperechoic mass in the right lobe of the liver, which invaded the right hepatic vein (RHV) and extended into the inferior vena cava (IVC) and right atrium

...

Chat with Bing

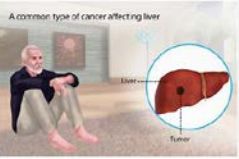
Sign in

Add the Give with Bing extension

Hepatocellular Carcinoma

Medical Condition

A common type of cancer affecting liver



The most common form of liver cancer often seen in people with chronic liver diseases

Hepatocellular carcinoma (HCC) patients with tumor **thrombus** extended through the major hepatic veins and **inferior vena cava** into the **right atrium** (RA) are rare, and most **cases** are considered as the advanced stage with a poor prognosis. We **report a case** of HCC with a tumor **thrombus** extending into the RA and a tumor **thrombus** in the portal vein.

Author: Xin Luo, Binhao Zhang, Shuilin Dong, Bixiang Zhang, Xiaoping Chen

Cited by: 14

Publish Year: 2015

[Hepatocellular Carcinoma With Tumor Thrombus Occupying the ...](#)

 pubmed.ncbi.nlm.nih.gov/26313767/

Was this helpful?  

[Hepatocellular carcinoma with inferior vena cava and right ...](#)

<https://pubmed.ncbi.nlm.nih.gov/31661575>

This is a case report of a 45-year-old patient admitted with the symptom of bilateral leg swelling. Ultrasonography revealed a hyperechoic mass in the right lobe of the liver, which invaded the right **hepatic vein** (RHV) and extended into the **inferior vena cava** (IVC) and **right atrium** (RA).

Cited by: 2

Author: Meihua Chen, Xuning Huang, Qianyu Yang

Publish Year: 2019

[Hepatocellular carcinoma with inferior vena cava and right ...](#)

<https://www.ncbi.nlm.nih.gov/pubmed/31661575>

Oct 29, 2019 · Ultrasonography revealed a hyperechoic mass in the right lobe of the liver, which invaded the **right hepatic vein** (RHV) and extended into the **inferior vena cava** (IVC) and **right atrium** (RA). Based on the high alpha-fetoprotein (AFP) level and the ultrasonography findings, the patient was diagnosed as having **hepatocellular carcinoma** (HCC) with a RHV, IVC, and RA **tumor thrombus** and secondary Budd ...

Cited by: 2

Author: Meihua Chen, Xuning Huang, Qianyu Yang

Publish Year: 2019

[Hepatocellular carcinoma with inferior vena cava and right ...](#)

14-Mar-2021 17:08PM7392 words • 5 matches • 4 sources00866_Auto_Edited -IT check.docx

iThenticate

Quoted Excluded
Bibliography Excluded4%
Source: JCR

Name of Journal: *World Journal of Clinical Cases*

Manuscript NO: 66866

Manuscript Type: CASE REPORT

Hepatocellular carcinoma with inferior vena cava and right atrium thrombus: A case report

Hepatocellular carcinoma with right atrium thrombus

Jin Liu, Rixin Zhang, Bing Dong, Kun Guo, Zhenming Gao, Liming Wang

Match Overview

1Crossref29 words
Shintaro Kurahashi, Tetsuichi Sano, Seiji Natsume, Yoshiaki Senoo, Hiroyuki Yamada, Yoshitaka Kato, Yasuhiro Shima1%

2Crossref24 words
Kazunori Sakamoto, Hiroaki Nagano "Outcomes of Surgery for hepatocellular carcinoma with tumor thrombus in the inferior vena cava: A case report"1%

3Crossref24 words
Xiao-Qing Tian, Xiang Chen, Sheng-Liang Chen "Clinical outcomes of transcatheter arterial chemoembolization for hepatocellular carcinoma with portal vein thrombosis: A case report"1%

4Crossref15 words
Tsung-Tai Lin, Hsuan-He Hsu, Shih-Chun Lee, Yi-Jen Peng, Kuo-Huang Ko "Dynamic magnetic resonance imaging for hepatocellular carcinoma with portal vein thrombosis: A case report"1%

PAGE 1 OF 9

Test Only Report

国内版

国际版

Hepatocellular carcinoma with inferior vena cava and right atrium t



ALL

IMAGES

VIDEOS

17,600 Results

Any time ▾

Hepatocellular carcinoma (HCC) patients with tumor **thrombus** extended through the major hepatic veins and **inferior vena cava** into the **right atrium (RA)** are rare, and most **cases** are considered as the advanced stage with a poor prognosis. We **report a case** of HCC with a tumor **thrombus** extending into the RA and a tumor **thrombus** in the portal vein.

Author: Xin Luo, Binhao Zhang, Shuilin Dong, Bixiang Zhang, Xiaoping Chen

Cited by: 14

Publish Year: 2015

[Hepatocellular Carcinoma With Tumor Thrombus Occupyin...](#)

► pubmed.ncbi.nlm.nih.gov/26313767/

Was this helpful?



[Hepatocellular carcinoma with inferior vena cava and right ...](#)

<https://pubmed.ncbi.nlm.nih.gov/31661575>

This is a case report of a 45-year-old patient admitted with the symptom of bilateral leg swelling. Ultrasonography revealed a hyperechoic mass in the right lobe of the liver, which invaded the right hepatic vein (RHV) and extended into the inferior vena cava (IVC) and right atrium (RA).

Cited by: 2

Author: Meihua Chen, Xuning Huang, Qianyu Yang

Publish Year: 2019

[Hepatocellular carcinoma with inferior vena cava and right ...](#)

<https://www.ncbi.nlm.nih.gov/pubmed/31661575>

Oct 29, 2019 · Ultrasonography revealed a hyperechoic mass in the right lobe of the liver, which invaded the right hepatic vein (RHV) and extended into the inferior vena cava (IVC) and right atrium (RA). Based on the high alpha-fetoprotein (AFP) level and the ultrasonography findings, the patient was diagnosed as having hepatocellular carcinoma (HCC) with a RHV, IVC, and RA tumor thrombus and

...

Cited by: 2

Author: Meihua Chen, Xuning Huang, Qianyu Yang

Publish Year: 2019