

# World Journal of *Clinical Cases*

*World J Clin Cases* 2021 September 26; 9(27): 7963-8279



## Contents

Thrice Monthly Volume 9 Number 27 September 26, 2021

## EDITORIAL

7963 *Exophiala dermatitidis**Usuda D, Higashikawa T, Hotchi Y, Usami K, Shimozaawa S, Tokunaga S, Osugi I, Katou R, Ito S, Yoshizawa T, Asako S, Mishima K, Kondo A, Mizuno K, Takami H, Komatsu T, Oba J, Nomura T, Sugita M*

## REVIEW

7973 Gastric neuroendocrine neoplasms: A review

*Köseoglu H, Duzenli T, Sezikli M*

## MINIREVIEWS

7986 Coronavirus disease 2019 and renal transplantation

*Nassar M, Nso N, Ariyaratnam J, Sandhu J, Mohamed M, Baraka B, Ibrahim A, Alfshawy M, Zheng D, Bhangoo H, Soliman KM, Li M, Rizzo V, Daoud A*

7998 Impact of COVID-19 on liver

*Su YJ, Chang CW, Chen MJ, Lai YC*

## ORIGINAL ARTICLE

## Case Control Study

8008 Association of gestational anemia with pregnancy conditions and outcomes: A nested case-control study

*Sun Y, Shen ZZ, Huang FL, Jiang Y, Wang YW, Zhang SH, Ma S, Liu JT, Zhan YL, Lin H, Chen YL, Shi YJ, Ma LK*

## Retrospective Cohort Study

8020 Clinical stages of recurrent hepatocellular carcinoma: A retrospective cohort study

*Yao SY, Liang B, Chen YY, Tang YT, Dong XF, Liu TQ*

## Retrospective Study

8027 Accuracy of ultrasonography in diagnosis of fetal central nervous system malformation

*Pang B, Pan JJ, Li Q, Zhang X*

8035 Analysis of ocular structural parameters and higher-order aberrations in Chinese children with myopia

*Li X, Hu Q, Wang QR, Feng ZQ, Yang F, Du CY*

8044 Radial nerve recovery following closed nailing of humeral shaft fractures without radial nerve exploration: A retrospective study

*Yeh KL, Liaw CK, Wu TY, Chen CP*

8051 Bridging therapy and direct mechanical thrombectomy in the treatment of cardiogenic cerebral infarction with anterior circulation macrovascular occlusion

*Ding HJ, Ma C, Ye FP, Zhang JF*

- 8061** Endu combined with concurrent chemotherapy and radiotherapy for stage IIB-IVA cervical squamous cell carcinoma patients

*Zhao FJ, Su Q, Zhang W, Yang WC, Zhao L, Gao LY*

### CASE REPORT

- 8071** Primary pancreatic paraganglioma harboring lymph node metastasis: A case report

*Jiang CN, Cheng X, Shan J, Yang M, Xiao YQ*

- 8082** Retraction of lumbar disc herniation achieved by noninvasive techniques: A case report

*Wang P, Chen C, Zhang QH, Sun GD, Wang CA, Li W*

- 8090** Mixed neuroendocrine carcinoma of the gastric stump: A case report

*Zhu H, Zhang MY, Sun WL, Chen G*

- 8097** Diploic vein as a newly treatable cause of pulsatile tinnitus: A case report

*Zhao PF, Zeng R, Qiu XY, Ding HY, Lv H, Li XS, Wang GP, Li D, Gong SS, Wang ZC*

- 8104** Acute myocardial infarction and extensive systemic thrombosis in thrombotic thrombocytopenic purpura: A case report and review of literature

*Şalaru DL, Adam CA, Marcu DTM, Şimon IV, Macovei L, Ambrosie L, Chirita E, Sascau RA, Statescu C*

- 8114** Limited thoracoplasty and free musculocutaneous flap transposition for postpneumonectomy empyema: A case report

*Huang QQ, He ZL, Wu YY, Liu ZJ*

- 8120** Paraneoplastic focal segmental glomerulosclerosis associated with gastrointestinal stromal tumor with cutaneous metastasis: A case report

*Zhou J, Yang Z, Yang CS, Lin H*

- 8127** Acute coronary syndrome with severe atherosclerotic and hyperthyroidism: A case report

*Zhu HM, Zhang Y, Tang Y, Yuan H, Li ZX, Long Y*

- 8135** Gastric cancer with calcifications: A case report

*Lin YH, Yao W, Fei Q, Wang Y*

- 8142** Value of eosinophil count in bronchoalveolar lavage fluid for diagnosis of allergic bronchopulmonary aspergillosis: A case report

*Wang WY, Wan SH, Zheng YL, Zhou LM, Zhang H, Jiang LB*

- 8147** Asymptomatic gastric adenomyoma and heterotopic pancreas in a patient with pancreatic cancer: A case report and review of the literature

*Li K, Xu Y, Liu NB, Shi BM*

- 8157** Successful treatment of gastrointestinal infection-induced septic shock using the oXiris® hemofilter: A case report

*Li Y, Ji XJ, Jing DY, Huang ZH, Duan ML*

- 8164** Streptococcal pneumonia-associated hemolytic uremic syndrome treated by T-antibody-negative plasma exchange in children: Two case reports  
*Wang XL, Du Y, Zhao CG, Wu YB, Yang N, Pei L, Wang LJ, Wang QS*
- 8171** Subclavian steal syndrome associated with Sjogren's syndrome: A case report  
*Hao LJ, Zhang J, Naveed M, Chen KY, Xiao PX*
- 8177** Metachronous mixed cellularity classical Hodgkin's lymphoma and T-cell leukemia/lymphoma: A case report  
*Dong Y, Deng LJ, Li MM*
- 8186** Duodenal perforation after organophosphorus poisoning: A case report  
*Lu YL, Hu J, Zhang LY, Cen XY, Yang DH, Yu AY*
- 8192** Surgical treatment of abnormal systemic artery to the left lower lobe: A case report  
*Zhang YY, Gu XY, Li JL, Liu Z, Lv GY*
- 8199** Madelung's disease with alcoholic liver disease and acute kidney injury: A case report  
*Wu L, Jiang T, Zhang Y, Tang AQ, Wu LH, Liu Y, Li MQ, Zhao LB*
- 8207** Anesthetic technique for awake artery malformation clipping with motor evoked potential and somatosensory evoked potential: A case report  
*Zhou HY, Chen HY, Li Y*
- 8214** Multiple hidden vessels in walled-off necrosis with high-risk bleeding: Report of two cases  
*Xu N, Zhai YQ, Li LS, Chai NL*
- 8220** Non-small-cell lung cancer with epidermal growth factor receptor L861Q-L833F compound mutation benefits from both afatinib and osimertinib: A case report  
*Zhang Y, Shen JQ, Shao L, Chen Y, Lei L, Wang JL*
- 8226** Successful removal of two magnets in the small intestine by laparoscopy and colonoscopy: A case report  
*Oh RG, Lee CG, Park YN, Lee YM*
- 8232** Acute lower extremity arterial thrombosis after intraocular foreign body removal under general anesthesia: A case report and review of literature  
*Jeon S, Hong JM, Lee HJ, Kim E, Lee H, Kim Y, Ri HS, Lee JJ*
- 8242** Low-intensity extracorporeal shock wave therapy for midshaft clavicular delayed union: A case report and review of literature  
*Yue L, Chen H, Feng TH, Wang R, Sun HL*
- 8249** Treatment of bilateral granulomatous lobular mastitis during lactation with traditional Chinese medicine: A case report  
*Li ZY, Sun XM, Li JW, Liu XF, Sun ZY, Chen HH, Dong YL, Sun XH*
- 8260** Early acute fat embolism syndrome caused by femoral fracture: A case report  
*Yang J, Cui ZN, Dong JN, Lin WB, Jin JT, Tang XJ, Guo XB, Cui SB, Sun M, Ji CC*

- 8268** Combined fascia iliaca compartment block and monitored anesthesia care for geriatric patients with hip fracture: Two case reports  
*Zhan L, Zhang YJ, Wang JX*
- 8274** Bell's palsy after inactivated COVID-19 vaccination in a patient with history of recurrent Bell's palsy: A case report  
*Yu BY, Cen LS, Chen T, Yang TH*

**ABOUT COVER**

Editorial Board Member of *World Journal of Clinical Cases*, Sunil Kumar Gupta, MBBS, MD, Reader (Associate Professor), Department of Dermatology, Venereology and Leprology, All India Institute of Medical Sciences, Gorakhpur, Gorakhpur 273008, Uttar Pradesh, India. dr.sunil\_30@yahoo.co.in

**AIMS AND SCOPE**

The primary aim of *World Journal of Clinical Cases* (WJCC, *World J Clin Cases*) is to provide scholars and readers from various fields of clinical medicine with a platform to publish high-quality clinical research articles and communicate their research findings online.

WJCC mainly publishes articles reporting research results and findings obtained in the field of clinical medicine and covering a wide range of topics, including case control studies, retrospective cohort studies, retrospective studies, clinical trials studies, observational studies, prospective studies, randomized controlled trials, randomized clinical trials, systematic reviews, meta-analysis, and case reports.

**INDEXING/ABSTRACTING**

The WJCC is now indexed in Science Citation Index Expanded (also known as SciSearch®), Journal Citation Reports/Science Edition, Scopus, PubMed, and PubMed Central. The 2021 Edition of Journal Citation Reports® cites the 2020 impact factor (IF) for WJCC as 1.337; IF without journal self cites: 1.301; 5-year IF: 1.742; Journal Citation Indicator: 0.33; Ranking: 119 among 169 journals in medicine, general and internal; and Quartile category: Q3. The WJCC's CiteScore for 2020 is 0.8 and Scopus CiteScore rank 2020: General Medicine is 493/793.

**RESPONSIBLE EDITORS FOR THIS ISSUE**

Production Editor: Ji-Hong Lin; Production Department Director: Xiang Li; Editorial Office Director: Jin-Lai Wang.

**NAME OF JOURNAL**

*World Journal of Clinical Cases*

**ISSN**

ISSN 2307-8960 (online)

**LAUNCH DATE**

April 16, 2013

**FREQUENCY**

Thrice Monthly

**EDITORS-IN-CHIEF**

Dennis A Bloomfield, Sandro Vento, Bao-Gan Peng

**EDITORIAL BOARD MEMBERS**

<https://www.wjnet.com/2307-8960/editorialboard.htm>

**PUBLICATION DATE**

September 26, 2021

**COPYRIGHT**

© 2021 Baishideng Publishing Group Inc

**INSTRUCTIONS TO AUTHORS**

<https://www.wjnet.com/bpg/gerinfo/204>

**GUIDELINES FOR ETHICS DOCUMENTS**

<https://www.wjnet.com/bpg/GerInfo/287>

**GUIDELINES FOR NON-NATIVE SPEAKERS OF ENGLISH**

<https://www.wjnet.com/bpg/gerinfo/240>

**PUBLICATION ETHICS**

<https://www.wjnet.com/bpg/GerInfo/288>

**PUBLICATION MISCONDUCT**

<https://www.wjnet.com/bpg/gerinfo/208>

**ARTICLE PROCESSING CHARGE**

<https://www.wjnet.com/bpg/gerinfo/242>

**STEPS FOR SUBMITTING MANUSCRIPTS**

<https://www.wjnet.com/bpg/GerInfo/239>

**ONLINE SUBMISSION**

<https://www.f6publishing.com>



## Duodenal perforation after organophosphorus poisoning: A case report

Yuan-Lan Lu, Jie Hu, Lu-Ying Zhang, Xiang-Yin Cen, Deng-Hui Yang, An-Yong Yu

**ORCID number:** Yuan-Lan Lu 0000-0001-6285-2709; Jie Hu 0000-0001-9934-488X; Lu-Ying Zhang 0000-0002-7184-8899; Xiang-Yin Cen 0000-0002-1835-9471; Deng-Hui Yang 0000-0003-4572-7564; An-Yong Yu 0000-0003-2605-6881.

**Author contributions:** Lu YL and Hu J reviewed the literature and contributed to manuscript drafting; Zhang LY, Cen XY, and Yang DH analyzed and interpreted the imaging findings and contributed to manuscript drafting; Yu AY revised the manuscript for important intellectual content; all authors issued final approval for the version to be submitted.

**Supported by** the National Natural Science Foundation of China, No. 81560217; and the Zunyi Science and Technology Project, No. ZunshiKeheHZ(2019)95.

**Informed consent statement:** Informed written consent was obtained from the patient for publication of this report and any accompanying images.

**Conflict-of-interest statement:** The authors declare that they have no conflict of interest to report.

**CARE Checklist (2016) statement:** The authors have read the CARE Checklist (2016), and the manuscript was prepared and

Yuan-Lan Lu, Lu-Ying Zhang, Xiang-Yin Cen, Deng-Hui Yang, An-Yong Yu, Department of Emergency Medicine, Affiliated Hospital of Zunyi Medical University, Zunyi 563003, Guizhou Province, China

Jie Hu, Department of Critical Care Medicine, Affiliated Hospital of Zunyi Medical University, Zunyi 563003, Guizhou Province, China

**Corresponding author:** An-Yong Yu, MD, Chief physician, Professor, Department of Emergency Medicine, Affiliated Hospital of Zunyi Medical University, No. 149 Dalian Road, Zunyi 563003, Guizhou Province, China. [anyongyu750811@126.com](mailto:anyongyu750811@126.com)

### Abstract

#### BACKGROUND

Organophosphorus poisoning (OP) is one of the common critical conditions in emergency departments in China, which is usually caused by suicide by taking oral drugs. Patients with severe OP have disturbance of consciousness, respiratory failure, toxic shock, gastrointestinal dysfunction, and so on. As far as we know, the perforation of the duodenum caused by OP has not been reported yet.

#### CASE SUMMARY

A 33-year-old male patient suffered from acute severe OP, associated with abdominal pain. Multiple computed tomography scans of the upper abdomen showed no evidence of intestinal perforation. However, retrograde digital subtraction angiography, performed *via* an abdominal drainage tube, revealed duodenal perforation. After conservative treatment, the symptoms eased and the patient was discharged from hospital.

#### CONCLUSION

Clinicians should pay close attention to gastrointestinal dysfunction and abdominal signs in patients with severe OP. If clinical manifestation and vital signs cannot be explained by common complications, stress duodenal ulcer or perforation should be highly suspected.

**Key Words:** Organophosphate poisoning; Duodenal perforation; Gastrointestinal dysfunction; Abdominal signs; Case report

©The Author(s) 2021. Published by Baishideng Publishing Group Inc. All rights reserved.

revised according to the CARE Checklist (2016).

**Open-Access:** This article is an open-access article that was selected by an in-house editor and fully peer-reviewed by external reviewers. It is distributed in accordance with the Creative Commons Attribution NonCommercial (CC BY-NC 4.0) license, which permits others to distribute, remix, adapt, build upon this work non-commercially, and license their derivative works on different terms, provided the original work is properly cited and the use is non-commercial. See: <http://creativecommons.org/licenses/by-nc/4.0/>

**Manuscript source:** Unsolicited manuscript

**Specialty type:** Medicine, research and experimental

**Country/Territory of origin:** China

**Peer-review report's scientific quality classification**

Grade A (Excellent): 0  
Grade B (Very good): B, B  
Grade C (Good): 0  
Grade D (Fair): 0  
Grade E (Poor): 0

**Received:** May 7, 2021

**Peer-review started:** May 7, 2021

**First decision:** June 6, 2021

**Revised:** June 18, 2021

**Accepted:** July 19, 2021

**Article in press:** July 19, 2021

**Published online:** September 26, 2021

**P-Reviewer:** Abubakar MS, Ravikanth R

**S-Editor:** Wang LL

**L-Editor:** Wang TQ

**P-Editor:** Wu RR



**Core Tip:** Organophosphorus poisoning is one of the common critical conditions in emergency departments in China and is usually caused by suicide. However, duodenal perforation caused by organophosphorus poisoning has not yet been reported. In this case, organophosphorus poisoning induced duodenal perforation, and the potential mechanism involves drug toxicity, physical injury caused by gastric lavage, or a stress response to acute poisoning, and severe shock.

**Citation:** Lu YL, Hu J, Zhang LY, Cen XY, Yang DH, Yu AY. Duodenal perforation after organophosphorus poisoning: A case report. *World J Clin Cases* 2021; 9(27): 8186-8191

**URL:** <https://www.wjgnet.com/2307-8960/full/v9/i27/8186.htm>

**DOI:** <https://dx.doi.org/10.12998/wjcc.v9.i27.8186>

## INTRODUCTION

Organophosphorus poisoning (OP) is one of the common critical conditions in emergency departments in China, accounting for 49.1% of acute poisonings and 83.6% of poisoning-related deaths. In the vast southwestern regions of China, pesticide use and storage are poorly managed, and thus, people sometimes commit suicide by oral administration of pesticides. Patients with severe OP usually have disturbance of consciousness, respiratory failure, toxic shock, and gastrointestinal dysfunction[1]. However, concurrent duodenal perforation has not been reported in the literature. We treated one case of duodenal perforation secondary to severe acute OP.

## CASE PRESENTATION

### Chief complaints

A 33-year-old man attempted suicide 4 h ago because of taking an unknown dose of dichlorvos, and was admitted to the emergency department of our hospital.

### History of present illness

The patient was hospitalized due to acute severe phosphorus poisoning. He drank before oral dose of unknown dichlorvos and was found foaming at the mouth and sweating, with cyanotic lips and no response to calls. Gastric lavage and atropine treatment were administered at a local hospital. He was later transferred to our hospital.

### History of past illness

The patient had a free previous medical history.

### Personal and family history

The patient had no personal and family history.

### Physical examination

On examination, the vital signs showed an unmeasurable body temperature, heart rate of 127/min, blood pressure of 61/39 mmHg, and SPO<sub>2</sub> of 82%, invasive ventilator assisted ventilation, slight coma, moist skin and mucous membrane, no light reflection, a garlic smell in the mouth, a thick breathing sound of both lungs, a little damp rale in the left lower lung, a soft and flat abdomen, and normal bowel sounds.

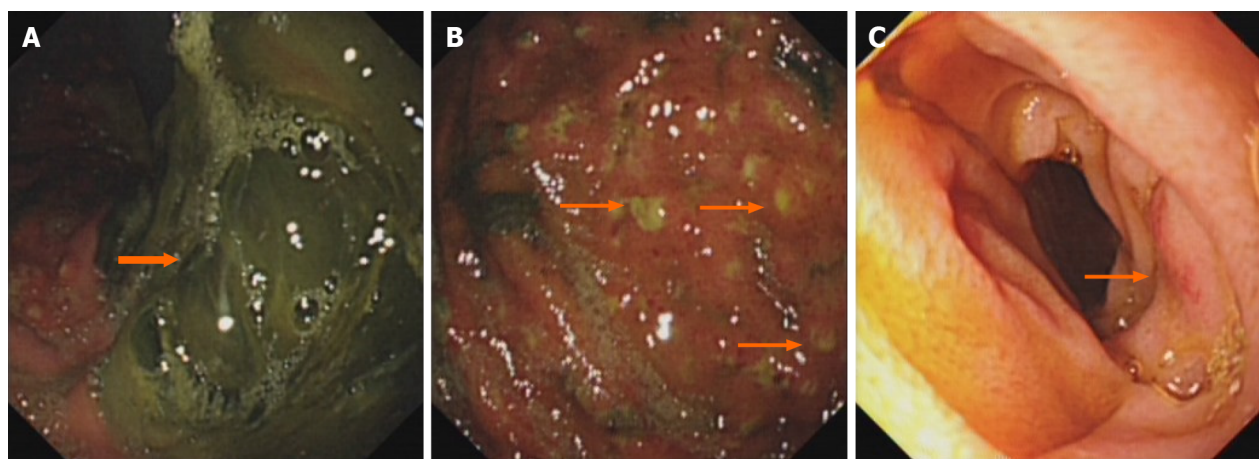
### Laboratory examinations

Auxiliary examination showed a cholinesterase level of 0.26 kU/L.

### Imaging examinations

Gastroscopy performed on September 3, 2018 showed that there were a large number of dark green secretions and membranous substances in the stomach cavity (Figure 1A), and there were many bulges in the mucosa of the stomach cavity, purulent secretions at the top, and obvious congestion in the surrounding mucosa





**Figure 1 Gastroscopic images of the stomach and descending duodenum.** A: Gastroscopy showing that there are a large number of dark green secretions and membranous substances in the stomach cavity, which are mainly in the corner of the stomach and could not be washed and scraped off; B: Gastroscopy showing there are many bulges in the mucosa of the stomach cavity, purulent secretions at the top, and obvious congestion in the surrounding mucosa; C: Gastroscopy showing congestion and edema in part of the descending duodenum.

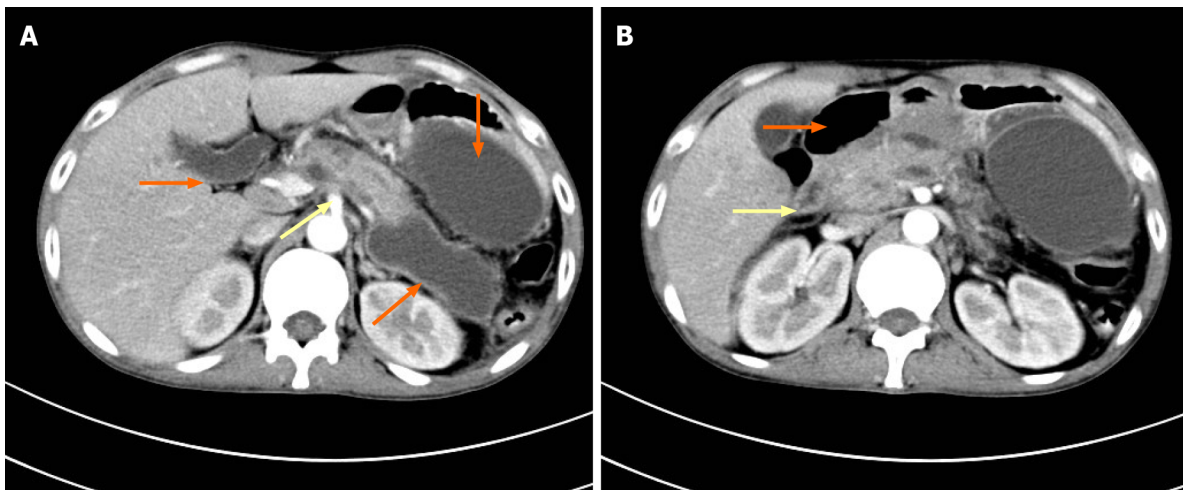
(Figure 1B). It also showed congestion and edema in part of the descending duodenum (Figure 1C). Computed tomography (CT) of the upper abdomen performed on September 18, 2018 showed acute pancreatitis and multiple pancreatic pseudocysts (Figure 2A), as well as descending duodenal edema and pneumatosis (Figure 2B). From September 3, 2018 to October 3, 2018, repeated CT of the upper abdomen showed no sign of intestinal perforation. However, digital subtraction angiography (DSA) performed on October 2, 2018 revealed that iohexol, a contrast agent, had been distributed around pancreatic pseudocyst through a drainage tube (Figure 3A) and the descending duodenum (Figure 3B), which confirmed duodenal perforation.

## FINAL DIAGNOSIS

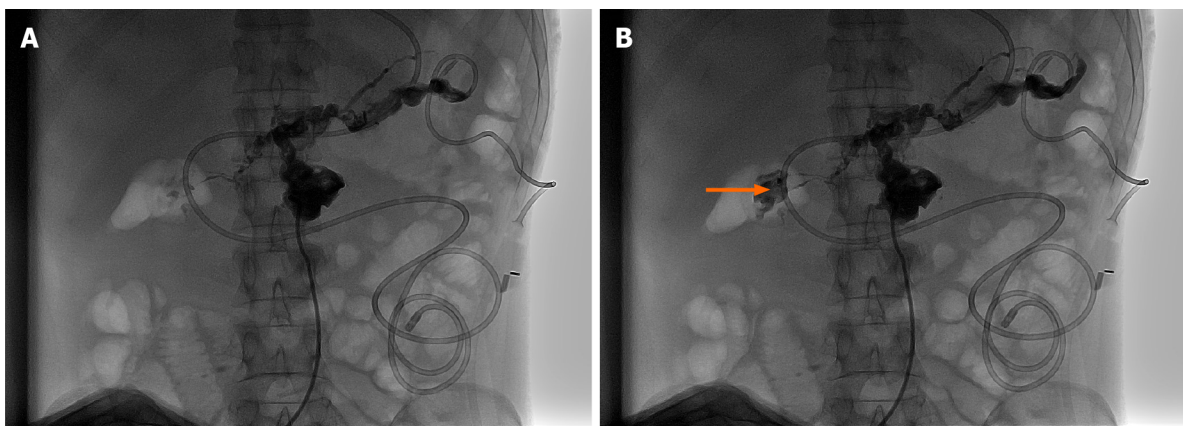
Duodenal fistula was finally diagnosed by retrograde DSA through a drainage tube in the median abdomen.

## TREATMENT

The patient received gastric lavage, catharsis, a special antidote, blood purification, ventilator-assisted respiration, and vasoactive drugs for boosting blood pressure. The patient was seriously ill, and the above-mentioned rescue measures significantly improved his symptoms. He still presented remarkable abdominal bulging and tenderness in the upper abdomen, accompanied by local muscular tension and weakened bowel sounds. Abdominal CT scanning indicated the possibility of acute pancreatitis. He underwent fasting, enzyme therapy, and acid suppression, as well as jejunal nutrition. Additionally, the traditional Chinese medical prescription Qingyi II was administered to restore normal bowel movement. All symptoms were alleviated, and thus, the tracheal intubation was removed, and vital signs became stable. Four weeks after admission, multiple pseudocysts were observed, peripheral to the pancreas (Figure 2A). CT-guided puncture and drainage were performed, and 300 mL of a light-yellow fluid was drawn from the left upper and median abdomen. Abdominal CT demonstrated that the peripancreatic cysts shrank and their number was reduced. The concentration of amylase was lowered, and abdominal pain was significantly relieved. At 40 d after admission, the patient experienced intensified abdominal pain after oral ingestion of a small amount of a fluid diet, and the volume of the drainage fluid from the median abdomen increased to 500 mL. Retrograde DSA was performed through a drainage tube in the median abdomen (Figure 3), which confirmed duodenal perforation. According to the surgical consultation, since the patient was in a poor general condition and the perforated duodenum was enveloped, there was no indication for surgery. The patient underwent fasting and conservative treatment and then was discharged with a drainage tube.



**Figure 2 Computed tomography of the upper abdomen.** A: Computed tomography (CT) showing acute pancreatitis (yellow arrow) and multiple pancreatic pseudocysts (orange arrows); B: CT showing descending duodenal edema (yellow arrow) and pneumatosis (orange arrow).



**Figure 3 Retrograde digital subtraction angiography through a pancreatic pseudocyst drainage tube.** Comparing A with B, digital subtraction angiography showed that the contrast agent iohexol has been distributed in the surrounding areas of the pancreatic pseudocyst through the drainage tube in A, as well as in the descending section of the duodenum in B (orange arrow).

## OUTCOME AND FOLLOW-UP

The patient was discharged with a drainage tube and had a normal diet 5 wk after the jejunal nutrition tube was removed. Angiography of the upper digestive tract showed no abnormalities in the duodenum.

## DISCUSSION

Organophosphorus pesticides are widely used in agriculture in China and are regarded as one of the main sources of poisoning. The poisoning mechanism in humans and animals involves the inhibition of the acetylcholine enzyme and causes the accumulation of acetylcholine, leading to muscarinic and nicotine toxicity and central nervous system dysfunction[2]. Patients with severe OP usually have clinical manifestations including disturbance of consciousness, respiratory failure, toxic shock, and gastrointestinal dysfunction.

Gastrointestinal dysfunction is closely related to the development and aggravation of OP. The mechanism involves the direct damage of the poison to the gastrointestinal mucosa, mucosal atrophy, shortening of villi, and increased vascular permeability. There are few cases of OP complicated with acute pancreatitis in the literature, and there are fewer cases of severe pancreatitis after operation[3], but there are no case of duodenal perforation. Previous research reported yellow phosphorus poisoning, which is one of the raw materials for synthesizing organophosphorus pesticides and

could lead to explosive liver failure and duodenal perforation[4]. Duodenal perforation is mainly caused by a duodenal ulcer and diverticulum, traumatic injury, iatrogenic endoscopic injury, a foreign body[5,6], and corrosive drug poisoning[4]. In this case, the difficult and eventful diagnosis and treatment of duodenal perforation after severe, acute OP may be attributed to the following facts: (1) The physical injury, caused by the pesticide and gastric lavage, or a stress reaction, caused by acute poisoning and severe shock, resulted in mucosal injury and gastrointestinal bleeding [7], *e.g.*, an acute gastric lesion shown in [Figure 1](#). Gastroscopy showed that there were many bulges in the mucosa of the stomach cavity, purulent secretions at the top, and obvious congestion in the surrounding mucosa ([Figure 1B](#)), and edema in part of the descending duodenum ([Figure 1C](#)); (2) Atropine, which was administered against poisoning, inhibited intestinal peristalsis and promoted the absorption of intestinal edema and toxins, further leading to an increased abdominal pressure (maximum: 27 cm H<sub>2</sub>O) and weakened bowel sounds[8]; (3) Severe poisoning caused serious hemodynamic changes and hypoxia. The concentration of lactic acid was 13.0 mmol/L, and therefore, a high dose of norepinephrine was administered to maintain blood pressure. Key organs were in ischemia and hypoxia[9], and the gastrointestinal tract might have also been impaired. Mahajan *et al*[7] reported that one patient with severe OP developed multiple perforations in the small intestine after the patient fell in shock; (4) The organs in the abdominal cavity were damaged, and pseudocysts were formed because of pancreatic secretion. The pancreatic fluid corroded the surrounding intestinal wall. Retrograde DSA *via* a drainage tube on a pseudocyst of the pancreatic head showed that a peripancreatic pseudocyst was connected to the duodenum ([Figure 3B](#)); and (5) The patient was in sedation and analgesia for critical care. The perforated part was enveloped, and therefore, no diffuse peritonitis developed. The abdominal symptoms were not thoroughly observed, and gastroscopy and abdominal CT showed no free gas below the diaphragm, leading to the missed diagnosis of duodenal perforation. Due to the aggravated abdominal pain and a sudden increase in abdominal drainage, retrograde angiography was performed *via* a drainage tube to confirm duodenal perforation. CT of the upper abdomen and gastroscopy are effective for the diagnosis of duodenal perforation. However, abdominal CT is superior to X-ray, with a higher sensitivity and specificity in detecting free gas outside the abdominal cavity and with a better view of the perforated section. In this case, the missed diagnosis of duodenal perforation at an early stage was due to severe toxic symptoms, repeated abdominal pain, and a small perforation and package. No typical signs of peritonitis were observed, which made it difficult to reach a definitive diagnosis. Finally, retrograde angiography confirmed duodenal perforation. Because the patient was in a poor general condition and had low immunity, conservative treatment was provided. Upper gastrointestinal angiography at 4 weeks after discharge showed no duodenal abnormalities. Compared with those undergoing surgical treatment, patients who undergo conservative treatment have fewer complications and a lower mortality.

## CONCLUSION

Duodenal perforation caused by OP has not yet been reported. In the clinic, many factors such as duodenal ulcer and diverticulum, traumatic injury, iatrogenic endoscopic injury, a foreign body, and corrosive drug poisoning can induce duodenal perforation. In patients with severe OP, clinicians should pay close attention to the damage to gastrointestinal function and to abdominal signs. If clinical manifestations and signs go beyond common complications, stress-induced duodenal ulcer and perforation should be highly suspected.

## REFERENCES

- 1 **Haliga RE**, Morarasu BC, Ursaru M, Irimioaia V, Sorodoc L. New insights into the organophosphate-induced intermediate syndrome. *Arh Hig Rada Toksikol* 2018; **69**: 191-195 [PMID: [29990296](#) DOI: [10.2478/aiht-2018-69-3121](#)]
- 2 **Malinak D**, Nepovimova E, Jun D, Musilek K, Kuca K. Novel Group of AChE Reactivators-Synthesis, In Vitro Reactivation and Molecular Docking Study. *Molecules* 2018; **23** [PMID: [30205495](#) DOI: [10.3390/molecules23092291](#)]
- 3 **Hou R**, Zhang H, Chen H, Zhou Y, Long Y, Liu D. Total pancreatic necrosis after organophosphate intoxication. *Front Med* 2019; **13**: 285-288 [PMID: [29777518](#) DOI: [10.1007/s11684-018-0626-z](#)]

- 4 **Ravikanth R**, Sandeep S, Philip B. Acute Yellow Phosphorus Poisoning Causing Fulminant Hepatic Failure with Parenchymal Hemorrhages and Contained Duodenal Perforation. *Indian J Crit Care Med* 2017; **21**: 238-242 [PMID: [28515612](#) DOI: [10.4103/ijccm.IJCCM\\_410\\_16](#)]
- 5 **Yang Z**, Wu D, Xiong D, Li Y. Gastrointestinal perforation secondary to accidental ingestion of toothpicks: A series case report. *Medicine (Baltimore)* 2017; **96**: e9066 [PMID: [29390302](#) DOI: [10.1097/MD.0000000000009066](#)]
- 6 **Donald KJ**, Doherty SR, Shun A. Duodenal perforation: an interesting case report. *Emerg Med Australas* 2005; **17**: 46-48 [PMID: [15675904](#) DOI: [10.1111/j.1742-6723.2005.00695.x](#)]
- 7 **Mahajan RK**, Rajan SJ, Peter JV, Suryawanshi MK. Multiple Small Intestine Perforations after Organophosphorous Poisoning: A Case Report. *J Clin Diagn Res* 2016; **10**: GD06-GD07 [PMID: [27134898](#) DOI: [10.7860/JCDR/2016/17103.7454](#)]
- 8 **Mostafazadeh B**, Farzaneh E, Paezi M, Nikkiah F. Toxic megacolon as a rare complication following atropine therapy due to organophosphate poisoning: A case report. *Med Leg J* 2017; **85**: 221-223 [PMID: [28403672](#) DOI: [10.1177/0025817217703520](#)]
- 9 **Yuan S**, Gao Y, Ji W, Song J, Mei X. The evaluation of acute physiology and chronic health evaluation II score, poisoning severity score, sequential organ failure assessment score combine with lactate to assess the prognosis of the patients with acute organophosphate pesticide poisoning. *Medicine (Baltimore)* 2018; **97**: e10862 [PMID: [29794787](#) DOI: [10.1097/MD.0000000000010862](#)]



Published by **Baishideng Publishing Group Inc**  
7041 Koll Center Parkway, Suite 160, Pleasanton, CA 94566, USA

**Telephone:** +1-925-3991568

**E-mail:** [bpgoffice@wjgnet.com](mailto:bpgoffice@wjgnet.com)

**Help Desk:** <https://www.f6publishing.com/helpdesk>

<https://www.wjgnet.com>

