

# World Journal of *Gastrointestinal Surgery*

*World J Gastrointest Surg* 2021 October 27; 13(10): 1110-1292



## Contents

Monthly Volume 13 Number 10 October 27, 2021

### FRONTIER

- 1110** Long-term survival outcome of laparoscopic liver resection for hepatocellular carcinoma  
*Lam S, Cheng KC*

### OPINION REVIEW

- 1122** Review of minimally invasive pancreas surgery and opinion on its incorporation into low volume and resource poor centres  
*Cawich SO, Kluger MD, Francis W, Deshpande RR, Mohammed F, Bonadie KO, Thomas DA, Pearce NW, Schrope BA*

### MINIREVIEWS

- 1136** Research progress regarding programmed cell death 1/programmed cell death ligand 1 inhibitors combined with targeted therapy for treating hepatocellular carcinoma  
*Zheng LL, Tao CC, Tao ZG, Zhang K, Wu AK, Wu JX, Rong WQ*
- 1149** Transanal minimally invasive surgery using laparoscopic instruments of the rectum: A review  
*Kim MJ, Lee TG*
- 1166** Current surgical management of duodenal gastrointestinal stromal tumors  
*Lim KT*
- 1180** Gastric endoscopic submucosal dissection in Western countries: Indications, applications, efficacy and training perspective  
*De Luca L, Di Berardino M, Mangiavillano B, Repici A*

### ORIGINAL ARTICLE

#### Case Control Study

- 1190** Laparoscopy for Crohn's disease: A comprehensive exploration of minimally invasive surgical techniques  
*Wan J, Liu C, Yuan XQ, Yang MQ, Wu XC, Gao RY, Yin L, Chen CQ*

#### Retrospective Study

- 1202** Onodera's Prognostic Nutritional Index is a novel and useful prognostic marker for gastrointestinal stromal tumors  
*Wang H, Xu YY, You J, Hu WQ, Wang SF, Chen P, Yang F, Shi L, Zhao W, Zong L*
- 1216** Utility of preoperative systemic inflammatory biomarkers in predicting postoperative complications after pancreaticoduodenectomy: Literature review and single center experience  
*Coppola A, La Vaccara V, Caggiati L, Carbone L, Spoto S, Ciccozzi M, Angeletti S, Coppola R, Caputo D*

- 1226** Low serum albumin may predict poor efficacy in patients with perforated peptic ulcer treated nonoperatively  
*Liang TS, Zhang BL, Zhao BB, Yang DG*
- 1235** Oesophageal adenocarcinoma: In the era of extended lymphadenectomy, is the value of neoadjuvant therapy being attenuated?  
*Park JS, Van der Wall H, Kennedy C, Falk GL*
- 1245** Outcomes of reduction hepatectomy combined with postoperative multidisciplinary therapy for advanced hepatocellular carcinoma  
*Asahi Y, Kamiyama T, Kakisaka T, Orimo T, Shimada S, Nagatsu A, Aiyama T, Sakamoto Y, Kamachi H, Taketomi A*
- 1258** Development and validation of a prediction model for deep vein thrombosis in older non-mild acute pancreatitis patients  
*Yang DJ, Li M, Yue C, Hu WM, Lu HM*

**SCIENTOMETRICS**

- 1267** Immunotherapy after liver transplantation: Where are we now?  
*Au KP, Chok KSH*

**CASE REPORT**

- 1279** Hodgkin lymphoma masquerading as perforated gallbladder adenocarcinoma: A case report  
*Manesh M, Henry R, Gallagher S, Greas M, Sheikh MR, Zielsdorf S*
- 1285** Whole circumferential endoscopic submucosal dissection of superficial adenocarcinoma in long-segment Barrett's esophagus: A case report  
*Abe K, Goda K, Kanamori A, Suzuki T, Yamamiya A, Takimoto Y, Arisaka T, Hoshi K, Sugaya T, Majima Y, Tominaga K, Iijima M, Hirooka S, Yamagishi H, Irisawa A*

**ABOUT COVER**

Editorial Board Member of World Journal of *Gastrointestinal Surgery*, Ramón Cantero, MD, PhD, Associate Professor, Surgeon, Department of Surgery, La Paz University Hospital, Pozuelo de Alarcón 28223, Madrid, Spain. [ramon.cantero@salud.madrid.org](mailto:ramon.cantero@salud.madrid.org)

**AIMS AND SCOPE**

The primary aim of *World Journal of Gastrointestinal Surgery* (WJGS, *World J Gastrointest Surg*) is to provide scholars and readers from various fields of gastrointestinal surgery with a platform to publish high-quality basic and clinical research articles and communicate their research findings online.

WJGS mainly publishes articles reporting research results and findings obtained in the field of gastrointestinal surgery and covering a wide range of topics including biliary tract surgical procedures, biliopancreatic diversion, colectomy, esophagectomy, esophagostomy, pancreas transplantation, and pancreatectomy, etc.

**INDEXING/ABSTRACTING**

The WJGS is now abstracted and indexed in Science Citation Index Expanded (SCIE, also known as SciSearch®), Current Contents/Clinical Medicine, Journal Citation Reports/Science Edition, PubMed, and PubMed Central. The 2021 edition of Journal Citation Reports® cites the 2020 impact factor (IF) for WJGS as 2.582; IF without journal self cites: 2.564; 5-year IF: 3.378; Journal Citation Indicator: 0.53; Ranking: 97 among 212 journals in surgery; Quartile category: Q2; Ranking: 73 among 92 journals in gastroenterology and hepatology; and Quartile category: Q4.

**RESPONSIBLE EDITORS FOR THIS ISSUE**

Production Editor: Rui-Rui Wu, Production Department Director: Xiang Li, Editorial Office Director: Ya-Juan Ma.

**NAME OF JOURNAL**

*World Journal of Gastrointestinal Surgery*

**ISSN**

ISSN 1948-9366 (online)

**LAUNCH DATE**

November 30, 2009

**FREQUENCY**

Monthly

**EDITORS-IN-CHIEF**

Shu-You Peng, Varut Lohsiriwat, Jin Gu

**EDITORIAL BOARD MEMBERS**

<https://www.wjgnet.com/1948-9366/editorialboard.htm>

**PUBLICATION DATE**

October 27, 2021

**COPYRIGHT**

© 2021 Baishideng Publishing Group Inc

**INSTRUCTIONS TO AUTHORS**

<https://www.wjgnet.com/bpg/gerinfo/204>

**GUIDELINES FOR ETHICS DOCUMENTS**

<https://www.wjgnet.com/bpg/gerinfo/287>

**GUIDELINES FOR NON-NATIVE SPEAKERS OF ENGLISH**

<https://www.wjgnet.com/bpg/gerinfo/240>

**PUBLICATION ETHICS**

<https://www.wjgnet.com/bpg/gerinfo/288>

**PUBLICATION MISCONDUCT**

<https://www.wjgnet.com/bpg/gerinfo/208>

**ARTICLE PROCESSING CHARGE**

<https://www.wjgnet.com/bpg/gerinfo/242>

**STEPS FOR SUBMITTING MANUSCRIPTS**

<https://www.wjgnet.com/bpg/gerinfo/239>

**ONLINE SUBMISSION**

<https://www.f6publishing.com>



## Hodgkin lymphoma masquerading as perforated gallbladder adenocarcinoma: A case report

Michelle Manesh, Reynold Henry, Shea Gallagher, Michael Greas, Mohd Raashid Sheikh, Shannon Zielsdorf

**ORCID number:** Michelle Manesh 0000-0002-8175-2364; Reynold Henry 0000-0002-2662-5485; Shea Gallagher 0000-0002-5796-3866; Michael Greas 0000-0001-8213-4122; Mohd Raashid Sheikh 0000-0001-7890-6337; Shannon Zielsdorf 0000-0003-4593-781X.

**Author contributions:** Manesh M, Henry R, Gallagher S and Zielsdorf S were the patient's surgeons, reviewed the literature and contributed to manuscript drafting; Greas M performed the pathologic analyses and interpretation and contributed to manuscript drafting; Sheikh MR was responsible for the revision of the manuscript for important intellectual content; all authors issued final approval for the version to be submitted.

**Informed consent statement:**

Informed written consent was obtained from the patient for publication of this report and any accompanying images.

**Conflict-of-interest statement:** The authors declare that they have no conflict of interest.

**CARE Checklist (2016) statement:**

The authors have read the CARE Checklist (2016), and the manuscript was prepared and revised according to the CARE Checklist (2016).

**Michelle Manesh, Reynold Henry, Shea Gallagher, Mohd Raashid Sheikh, Shannon Zielsdorf,** Department of Surgery, University of Southern California, Los Angeles, CA 90033, United States

**Michael Greas,** Department of Pathology, University of Southern California, Los Angeles, CA 90033, United States

**Corresponding author:** Reynold Henry, MD, Surgeon, Department of Surgery, University of Southern California, 2051 Marengo Street IPT, C5L100, Los Angeles, CA 90033, United States. [reyshehry@gmail.com](mailto:reyshehry@gmail.com)

### Abstract

#### BACKGROUND

There are several case reports of acute cholecystitis as the initial presentation of lymphoma of the gallbladder; all reports describe non-Hodgkin lymphoma or its subtypes on histopathology of the gallbladder tissue itself. Interestingly, there is no description in the literature of Hodgkin lymphoma causing hilar lymphadenopathy, inevitably presenting as ruptured cholecystitis with imaging mimicking gallbladder adenocarcinoma.

#### CASE SUMMARY

A 48-year-old man with a past medical history of diabetes mellitus presented with progressive abdominal pain, jaundice, night sweats, weakness, and unintended weight loss for one month. Work-up revealed a mass in the region of the porta hepatis causing obstructions of the cystic and common hepatic ducts, gallbladder rupture, as well as retroperitoneal lymphadenopathy. The clinical picture and imaging findings were suspicious for locally advanced gallbladder adenocarcinoma causing ruptured cholecystitis and cholangitis, with metastases to retroperitoneal lymph nodes. Minimally invasive techniques, including endoscopic duct brushings and percutaneous lymph node biopsy, were inadequate for tissue diagnosis. Therefore, this case required exploratory laparotomy, open cholecystectomy, and periaortic lymph node dissection for histopathological assessment and definitive diagnosis. Hodgkin lymphoma was present in the lymph nodes while the gallbladder specimen had no evidence of malignancy.

#### CONCLUSION

This clinical scenario highlights the importance of histopathological assessment in diagnosing gallbladder malignancy in a patient with gallbladder perforation and



**Open-Access:** This article is an open-access article that was selected by an in-house editor and fully peer-reviewed by external reviewers. It is distributed in accordance with the Creative Commons Attribution NonCommercial (CC BY-NC 4.0) license, which permits others to distribute, remix, adapt, build upon this work non-commercially, and license their derivative works on different terms, provided the original work is properly cited and the use is non-commercial. See: <http://creativecommons.org/licenses/by-nc/4.0/>

**Manuscript source:** Unsolicited manuscript

**Specialty type:** Surgery

**Country/Territory of origin:** United States

**Peer-review report's scientific quality classification**

Grade A (Excellent): 0  
Grade B (Very good): B  
Grade C (Good): 0  
Grade D (Fair): 0  
Grade E (Poor): 0

**Received:** April 20, 2021

**Peer-review started:** April 20, 2021

**First decision:** June 24, 2021

**Revised:** June 24, 2021

**Accepted:** August 30, 2021

**Article in press:** August 30, 2021

**Published online:** October 27, 2021

**P-Reviewer:** Renzo ND

**S-Editor:** Zhang H

**L-Editor:** A

**P-Editor:** Li JH



a grossly positive positron emission tomography/computed tomography scan. For both gallbladder adenocarcinoma and Hodgkin lymphoma, medical and surgical therapies must be tailored to the specific disease entity in order to achieve optimal long-term survival rates.

**Key Words:** Hodgkin lymphoma; Gallbladder perforation; Acute cholecystitis; Gallbladder adenocarcinoma; Case report

©The Author(s) 2021. Published by Baishideng Publishing Group Inc. All rights reserved.

**Core Tip:** Here we present a case of Hodgkin lymphoma masquerading as gallbladder adenocarcinoma. In our patient, Hodgkin lymphadenopathy in the region of the porta hepatitis led to obstructions of the cystic and common hepatic ducts, causing acute cholecystitis and subsequent gallbladder perforation with associated cholangitis. Our case highlights the importance of histopathological assessment in diagnosing gallbladder malignancy when a patient presents with gallbladder perforation and a grossly positive positron emission tomography/computed tomography scan. For either gallbladder adenocarcinoma or Hodgkin lymphoma, chemotherapy tailored to the disease (and appropriate surgical intervention) are essential to achieve the best chance of cure and long-term survival.

**Citation:** Manesh M, Henry R, Gallagher S, Greas M, Sheikh MR, Zielsdorf S. Hodgkin lymphoma masquerading as perforated gallbladder adenocarcinoma: A case report. *World J Gastrointest Surg* 2021; 13(10): 1279-1284

**URL:** <https://www.wjgnet.com/1948-9366/full/v13/i10/1279.htm>

**DOI:** <https://dx.doi.org/10.4240/wjgs.v13.i10.1279>

## INTRODUCTION

Primary lymphoma of the gallbladder is rare but likely fits on the spectrum of lymphomas occurring in the gastrointestinal tract[1]. There are several case reports of acute cholecystitis as the initial presentation of lymphoma of the gallbladder, all of which describe non-Hodgkin lymphoma or its subtypes on histopathology of the gallbladder specimen[2-7]. Interestingly, there is no description in the literature of Hodgkin lymphoma causing hilar lymphadenopathy, inevitably presenting as ruptured cholecystitis and mimicking metastatic gallbladder adenocarcinoma on imaging. Here we present a case of Hodgkin lymphadenopathy in the region of the porta hepatitis which led to obstructions of the cystic and common hepatic ducts, causing an acute cholecystitis, gallbladder perforation, and cholangitis.

## CASE PRESENTATION

### Chief complaints

A 48-year-old man presented to the Emergency Department with acute nausea and vomiting for one day but did also endorse vague symptoms of nausea for the preceding two weeks. He also described having subjective fevers at home with rare right upper quadrant pain and without evidence of jaundice.

### History of present illness

Patient described progressive right upper quadrant pain, jaundice, night sweats, weakness, and unintended weight loss for one month. His symptoms had worsened on the week prior to arrival, at which time he began to experience decreased oral intake with nausea. His acute onset of non-bloody, nonbilious vomiting on day prior to arrival is what led him to seek care. He initially presented to an urgent care center where computed tomography (CT) scan was done and showed acute cholecystitis. He was then sent to the emergency room.

**History of past illness**

The patient had a past medical history of diabetes mellitus and hypertension. His only home medication was a prostate medication of unknown name. He also had a remote history of laparoscopic appendectomy.

**Personal and family history**

Family history was noncontributory. Patient denied any alcohol, tobacco or illicit drug use.

**Physical examination**

His vital signs on arrival were temperature 36.4 °C, heart rate 110 beats per minute, respiratory rate 16 breaths per minute, blood pressure of 125/82 mmHg. Physical exam was notable for right upper quadrant tenderness without peritoneal signs. His skin was jaundiced.

**Laboratory examinations**

Laboratory findings were significant for leukocytosis (white blood cell count 18.3 K/mm<sup>3</sup>) and hyperbilirubinemia (total bilirubin 14.5 mg/dL). The remainder of the complete blood count and blood chemistries, as well as liver function panel were normal. Tumor markers included CEA level of 1.2 µg/L and CA19-9 level of 21 U/L. Electrocardiogram and chest X-ray were also normal.

**Imaging examinations**

An abdominal ultrasound demonstrated a distended gallbladder with a thickened, edematous wall, gallstones, and an apparent defect in the wall, as well as intrahepatic and extrahepatic ductal dilation. A magnetic resonance cholangiopancreatography identified a T2 hypointense right hepatic lobe lesion that involved the right hepatic artery and narrowing of the common bile duct (CBD). CT again demonstrated a contained perforation of the gallbladder, moderate intrahepatic ductal dilation, possible mass within the porta hepatis, and long narrowing of the CBD (Figure 1). Additional findings consisted of multiple large retroperitoneal and pelvic lymph nodes measuring up to 2.6 cm, located in proximity to the aortic bifurcation. Given the possibility of malignancy, a chest CT was performed to evaluate for metastatic disease, which demonstrated abnormally enlarged right hilar lymph nodes.

---

**FINAL DIAGNOSIS**

---

Pathologic examination of the para-aortic lymph nodes provided a definitive diagnosis of mixed-cellularity classic Hodgkin lymphoma (Figure 2). The gallbladder demonstrated chronic cholecystitis without evidence of dysplasia, adenocarcinoma, or lymphoma.

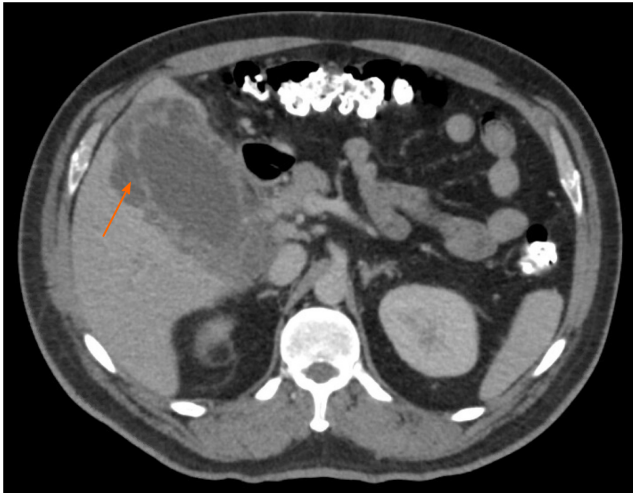
---

**TREATMENT**

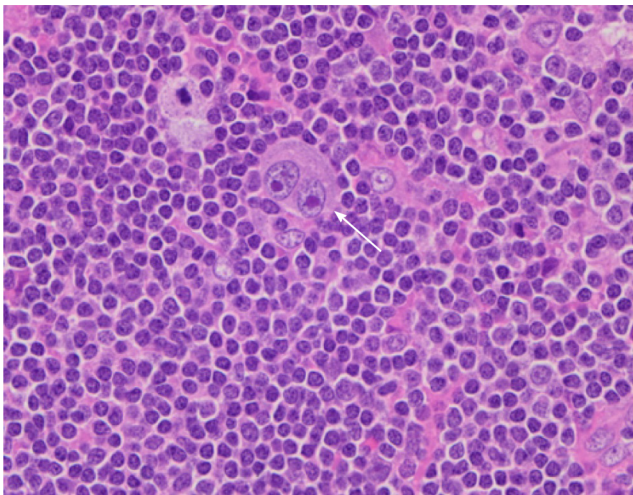
---

The patient received intravenous antibiotics for presumed cholangitis and underwent endoscopic retrograde cholangiopancreatography for sphincterotomy and stent placement in the common hepatic duct. Bile duct brushings were negative for malignant cells. The patient then underwent percutaneous cholecystostomy tube placement. A specimen of the bilious drainage was cytologically negative for malignancy, but fluid culture grew extended spectrum beta-lactamase *Escherichia coli*. The patient was transitioned to the appropriate oral antibiotics and was discharged with the cholecystostomy tube in place.

The differential diagnosis included locally advanced (and metastatic) gallbladder adenocarcinoma, hilar cholangiocarcinoma, lymphoma, or severe cholecystitis and cholangitis causing intra-abdominal lymphadenopathy. One month after his initial presentation, the patient underwent positron emission tomography with 2-deoxy-2-(fluorine-18) fluoro-D-glucose integrated with CT (<sup>18</sup>F-FDG PET-CT) and ultrasound-guided biopsy of the largest iliac lymph node. The <sup>18</sup>F-FDG PET-CT demonstrated a soft tissue density associated with intense hypermetabolic activity in the region of the gallbladder fossa at the junction of the cystic duct and proximal CBD. It also demonstrated hypermetabolic activity in the gallbladder wall and in several lymph nodes in the para-aortic region extending to the iliac vessels (Figure 3). The lymph



**Figure 1** Abdominal computed tomography demonstrating discontinuity of the gallbladder wall consistent with perforation (orange arrow), as well as a soft tissue density in the area of the porta hepatis.



**Figure 2** Micrograph of a para-aortic lymph node showing classic Hodgkin lymphoma. A typical binucleated Reed-Sternberg cell (arrow) is surrounded by small lymphocytes, macrophages and occasional plasma cells.

node biopsy showed the presence of lymphoid tissue but was otherwise inadequate for diagnosis.

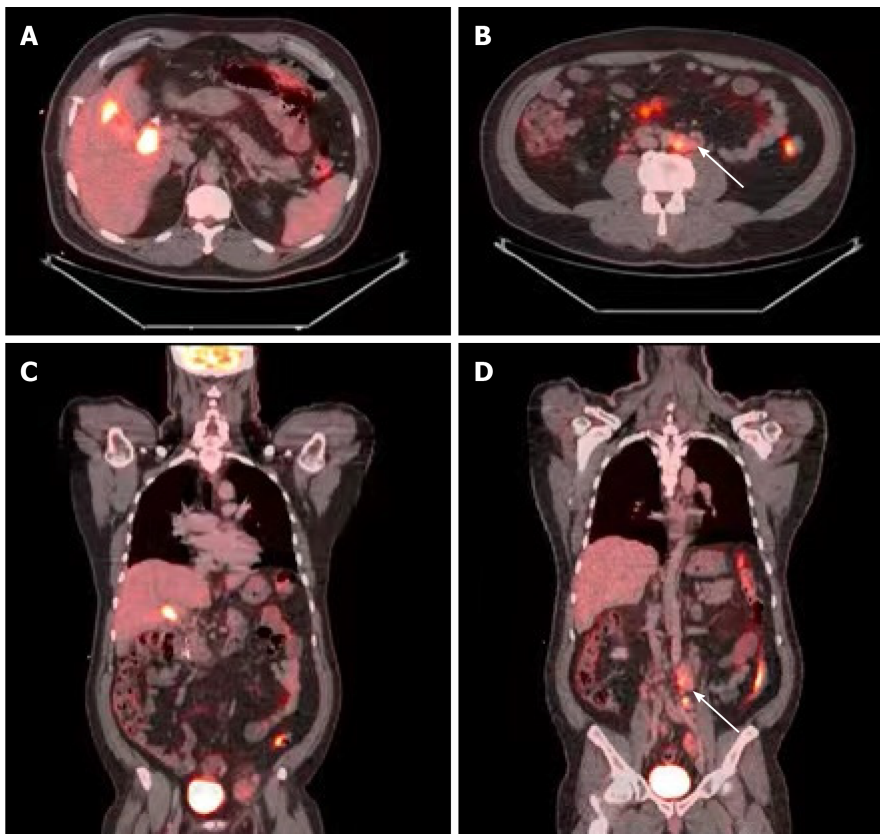
The patient subsequently underwent surgical intervention for both diagnostic and therapeutic purposes. A para-aortic lymphadenectomy was performed first in order to obtain a diagnosis. If this was positive for gallbladder adenocarcinoma or cholangiocarcinoma, any further operative intervention would be aborted in favor of chemotherapy for metastatic disease. However, intra-operative pathology showed no evidence of adenocarcinoma, but rather cellular atypia suggesting lymphoma. An open cholecystectomy, without liver resection or portal lymphadenectomy was then performed.

---

## OUTCOME AND FOLLOW-UP

The patient recovered well post-operatively and was discharged on post-operative day eight. Upon follow up to the surgery clinic, he was pleased with his care and thankful that a diagnosis had been made. He is scheduled to receive adriamycin, bleomycin, vinblastine, and dacarbazine chemotherapy as treatment for Hodgkin lymphoma.





**Figure 3** Positron emission tomography with 2-deoxy-2-(fluorine-18) fluoro-D-glucose integrated with computed tomography demonstrating the following findings. A and C: Axial and coronal views, respectively, displaying intense metabolic activity associated with the gallbladder, and a soft tissue density at the level of the proximal common bile duct and cystic duct; B and D: Axial and coronal views, respectively, displaying several enlarged and hypermetabolic peri-aortic lymph nodes proximal to the aortic bifurcation (white arrows).

## DISCUSSION

Primary lymphoma of the gallbladder is rare but likely fits on the spectrum of lymphomas occurring in the gastrointestinal tract[5,7]. There are several case reports of acute cholecystitis as the initial presentation of lymphoma of the gallbladder and all describe non-Hodgkin's lymphoma or its subtypes on histopathology[2-5]. On the contrary, our case report describes Hodgkin's lymphoma of the portal lymph nodes, and benign pathology of the gallbladder itself, presenting as ruptured cholecystitis and mimicking gallbladder adenocarcinoma on imaging. Other authors have written about clinical situations where there is a mass in the region of the gallbladder or biliary ducts causing acute acalculous cholecystitis. In these settings, the distinction between lymphoma and gallbladder adenocarcinoma relies on histopathological assessment[2].

Given our patient's initial presentation with an inflamed, thickened and perforated gallbladder, along with  $^{18}\text{F}$ -FDG PET avidity in a mass-like structure within the region of the gallbladder fossa and CBD, our differential diagnosis was highly concerning for primary gallbladder malignancy. Still, confirmation by tissue diagnosis was essential. Regarding surgical planning: With the mass-like structure involving the gallbladder, CBD, and right hepatic artery – surgical intervention would necessitate a right hepatic lobectomy. However, with distant lymphadenopathy concerning for metastatic disease, aggressive hepatobiliary resection(s) such as right hepatic lobectomy would be contraindicated. Conversely, if the mass-like structure was not a primary gallbladder or bile duct malignancy, the ruptured cholecystitis required surgical intervention, albeit less aggressive than liver resection. Unfortunately, minimally invasive techniques, including endoscopic duct brushings and percutaneous lymph node biopsy, were inadequate for pre-operative tissue diagnosis. Hence, exploratory laparotomy and para-aortic lymphadenectomy were required for histopathological assessment and definitive diagnosis. Once intra-operative pathology returned as likely Hodgkin lymphoma, open cholecystectomy was performed.

Classic Hodgkin lymphoma typically presents as an asymptomatic supradiaphragmatic lymphadenopathy. Constitutional “B” symptoms such as high fevers, night sweats and unintended weight loss occur in 33% of cases. In retrospect, our patient had constitutional “B” symptoms for at least one month leading up to his presentation to the hospital. Interestingly, peripheral and abdominal lymphadenopathy are prominent in the mixed-cellularity type, which was the subtype diagnosed in this case report. The pathologic hallmark of classical Hodgkin lymphoma is large multinucleated Reed-Sternberg cells with a characteristic reactive cellular background [8]. Hodgkin lymphoma is unique in that malignant cells (Reed-Sternberg cells) only constitute a small portion of the cell population within each tumor (Figure 2). As such, fine-needle aspiration and core-needle biopsies are often inadequate to make a definitive diagnosis[9]. In our case as well, several biopsies were non-diagnostic prior to our operative intervention and excisional lymph node biopsy.

To our knowledge, there are no cases documented of Hodgkin lymphoma presenting with gallbladder and biliary obstruction, leading to gallbladder perforation and cholangitis, respectively. Moreover, this unique case revealed benign pathology of the gallbladder. This further supports a pathophysiology that is distinct from the current literature review of acute cholecystitis due to primary lymphoma of the gallbladder.

## CONCLUSION

This case highlights the importance of histopathological assessment in diagnosing gallbladder malignancy in a patient with gallbladder perforation and a grossly positive PET-CT scan. For either gallbladder adenocarcinoma or Hodgkin lymphoma, chemotherapy tailored to the disease (and appropriate surgical intervention) are essential to achieve the best chance of cure and long-term survival[4]. Therefore, in patients like ours, lymphoma must be ruled out definitively by pathology, which in this case required exploratory laparotomy and excisional lymph node biopsy.

## ACKNOWLEDGEMENTS

We thank Drs Maria Stapfer and Hector Ramos for their comments in consultation.

## REFERENCES

- 1 **Pezzuto R**, Di Mauro D, Bonomo L, Patel A, Ricciardi E, Attanasio A, Manzelli A. An Unusual Case of Primary Extranodal Lymphoma of the Gallbladder. *Hematol Rep* 2017; **9**: 6972 [PMID: 28435654 DOI: 10.4081/hr.2017.6972]
- 2 **Doherty B**, Palmer W, Cvinar J, Sadek N. A Rare Case of Systemic Adult Burkitt Lymphoma Presenting as Acute Acalculous Cholecystitis. *ACG Case Rep J* 2019; **6**: e00048 [PMID: 31616732 DOI: 10.14309/crj.0000000000000048]
- 3 **Katiyar R**, Patne SC, Agrawal A. Primary B-cell Non-Hodgkin Lymphoma of Gallbladder Presenting as Cholecystitis. *J Lab Physicians* 2015; **7**: 67-68 [PMID: 25949065 DOI: 10.4103/0974-2727.154803]
- 4 **Lakananurak N**, Laichuthai N, Treeprasertsuk S. Acalculous Cholecystitis as the Initial Presentation of Systemic Diffuse Large B-Cell Lymphoma. *ACG Case Rep J* 2015; **2**: 110-112 [PMID: 26157930 DOI: 10.14309/crj.2015.21]
- 5 **Shah KS**, Shelat VG, Jogai S, Trompetas V. Primary gallbladder lymphoma presenting with perforated cholecystitis and hyperamylasaemia. *Ann R Coll Surg Engl* 2016; **98**: e13-e15 [PMID: 26673049 DOI: 10.1308/rcsann.2016.0001]
- 6 **Tishler M**, Rahmani R, Shilo R, Armon S, Abramov AL. Large-cell lymphoma presenting as acute cholecystitis. *Acta Haematol* 1987; **77**: 51-52 [PMID: 3107323 DOI: 10.1159/000205950]
- 7 **Yadav S**, Chisti MM, Rosenbaum L, Barnes MA. Intravascular large B cell lymphoma presenting as cholecystitis: diagnostic challenges persist. *Ann Hematol* 2014; **93**: 1259-1260 [PMID: 24288109 DOI: 10.1007/s00277-013-1963-2]
- 8 **Ansell SM**. Hodgkin Lymphoma: Diagnosis and Treatment. *Mayo Clin Proc* 2015; **90**: 1574-1583 [PMID: 26541251 DOI: 10.1016/j.mayocp.2015.07.005]
- 9 **Townsend W**, Linch D. Hodgkin's lymphoma in adults. *Lancet* 2012; **380**: 836-847 [PMID: 22835602 DOI: 10.1016/S0140-6736(12)60035-X]



Published by **Baishideng Publishing Group Inc**  
7041 Koll Center Parkway, Suite 160, Pleasanton, CA 94566, USA

**Telephone:** +1-925-3991568

**E-mail:** [bpgoffice@wjgnet.com](mailto:bpgoffice@wjgnet.com)

**Help Desk:** <https://www.f6publishing.com/helpdesk>

<https://www.wjgnet.com>

