




Microsoft Bing

国内版 国际版

A Case Report of Complete Withdrawal of Glucocorticoids after Dup



ALL IMAGES VIDEOS

30,600 Results Any time

Successful Treatment of Mepolizumab- and Prednisolone ...
https://www.jstage.jst.go.jp/article/internal...
Recurrence of mucus plugs in allergic bronchopulmonary aspergillosis (ABPA) can cause bronchiectasis and lung fi-brosis, which may lead to lung destruction. Approximately...

Super-response to dupilumab therapy in a patient with ...
https://erj.ersjournals.com/content/56/suppl_64/2228
Sep 07, 2020 · Allergic bronchopulmonary aspergillosis (ABPA) is a severe hypersensitivity reaction to aspergillus species colonizing the airways of patients with asthma or cystic fibrosis. Biologicals includin...
Author: Carlo Mümmeler, Bernd Kemmerich, Katr... Publish Year: 2020

and Allergic Bronchopulmonary Aspergillosis Double the ...
https://www.atsjournals.org/doi/pdf/10.1164/ajrccm...
Here we report a case of a patient with severe asthma complicated by allergic bronchopulmonary aspergillosis (ABPA) treated with dupilumab, with improvement in clinical symptoms and radiographic...

Differential response to biologics in a patient with ...
https://aacijournal.biomedcentral.com/articles/10.1186/s13223-020-00454-w
Jun 26, 2020 · Background Allergic bronchopulmonary aspergillosis (ABPA) is a severe hypersensitivity reaction to aspergillus species colonizing the airways of patients with asthma or cystic fibrosis. Biologic...
Cited by: 3 Author: Carlo Mümmeler, Bernd Kemmerich, Jürgen ...

Allergic bronchopulmonary aspergillosis

Symptoms Diagnosis

Allergic bronchopulmonary aspergillosis is a condition characterised by an exaggerated response of the immune system to the fungus Aspergillus. It occurs most often in people with asthma or cystic fibrosis. Aspergillus spores are ubiquitous in soil and are commonly found in the sputum of healthy individuals. A. fumigatus is responsible for a spectrum of lung diseases known as aspergilloses.

Wikipedia

People also search for

Bronchiectasis

Aspergillosis

Aspergilloma

Cystic Fibrosis

Heart Failure



ALL IMAGES VIDEOS

35,500 Results

Any time ▾

Open links in new tab



[PDF] Successful Treatment of Mepolizumab- and Prednisolone ...

https://www.jstage.jst.go.jp/article/internalmedicine/advpub/0/advpub_6679-20/_pdf/...

Recurrence of mucus plugs in allergic bronchopulmonary aspergillosis (ABPA) can cause bronchiectasis and lung fibrosis, which may lead to lung destruction. Approximately...

Super-response to dupilumab therapy in a patient with ...

https://erj.ersjournals.com/content/56/suppl_64/2228 ▼

Sep 07, 2020 · Allergic bronchopulmonary aspergillosis (ABPA) is a severe hypersensitivity reaction to aspergillus species colonizing the airways of patients with asthma or cystic fibrosis. Biologicals...

Author: Carlo Mümmeler, Bernd Kemmerich, K... Publish Year: 2020

Differential response to biologics in a patient with ...

<https://aacijournal.biomedcentral.com/articles/10.1186/s13223-020-00454-w> ▼

Jun 26, 2020 · Background Allergic bronchopulmonary aspergillosis (ABPA) is a severe hypersensitivity reaction to aspergillus species colonizing the airways of patients with asthma or cystic...

Cited by: 3

Author: Carlo Mümmeler, Bernd Kemmerich, Jürge...

Publish Year: 2020 **Estimated Reading Time:** 9 mins

[\[PDF\] and Allergic Bronchopulmonary Aspergillosis Double the ...](#)

https://www.atsjournals.org/doi/pdf/10.1164/ajrccm-conference.2020.201.1_Meeting...

Here we report a case of a patient with severe asthma complicated by allergic bronchopulmonary aspergillosis (ABPA) treated with dupilumab, with improvement in clinical symptoms and radiographi...

(PDF) Differential response to biologics in a patient with ...

<https://www.researchgate.net/publication/342479086...>

Background: Allergic bronchopulmonary aspergillosis (ABPA) is a severe hypersensitivity reaction to aspergillus species colonizing the airways of patients with asthma or cystic fibrosis.

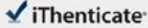
Estimated Reading Time: 5 mins

(PDF) Allergic bronchopulmonary aspergillosis successfully ...

22-Jun-2021 01:58PM

1647 words • 3 matches • 2 sources

FAQ

 iThenticate®

67402_Auto_Edited-IT 查重.docx

Quotes Excluded
Bibliography Excluded

3%
Similarity

Match Overview

1

Crossref 30 words
Taro Yasuma, Yoko Okano, Soichiro Tanaka, Kota Nishihara
a et al. "Sodium-glucose co-transporter-2 inhibitor-associated

2%

2

Internet 14 words
crawled on 09-Nov-2020
jmedicallibraryreport.biomedcentral.com

1%

Name of Journal: *World Journal of Clinical Cases*

Manuscript NO: 67402

Manuscript Type: CASE REPORT

A Case Report of Complete Withdrawal of Glucocorticoids after Dupilumab Therapy in Allergic Bronchopulmonary Aspergillosis

Dupilumab in allergic bronchopulmonary aspergillosis

Tadashi Nishimura, Tomohito Okano, Masahiro Naito, Chikashi Tsuji, Soichi Iwanaka, Yasumasa Sakakura, Taro Yasuma, Hajime Fujimoto, Corina N D'Alessandro-Gabazza, Yasuhiro Oomoto, Tetsu Kobayashi, Esteban C. Gabazza, Hidenori Iibata

PAGE: 1 OF 8

Test-Only Report

国内版 国际版

Complete withdrawal of glucocorticoids after dupilumab therapy in



网页 图片 视频 学术 词典 地图

检测到您输入了英文，试试切换到国际版？搜英文结果更丰富更准确 >

14,700 条结果

时间不限 ▾

自适应缩放



Dupilumab: a new contestant to corticosteroid in ... 翻译此页

<https://academic.oup.com/omcr/article/2021/4/omaa029/6255675> ▾

2021-4-28 · We present a case of **dupilumab** as add-on **therapy** in a patient with ABPA, which allowed us to reduce daily steroid dosage. INTRODUCTION **Allergic bronchopulmonary** aspergillosis (ABPA) is...

Author: Muhammad Ali, O'Neil Green Publish Year: 2021

Successful Treatment of Mepolizumab- and ... 翻译此页

<https://pubmed.ncbi.nlm.nih.gov/33642487>

A 45-year-old man with **allergic bronchopulmonary** aspergillosis (ABPA) was treated with oral prednisolone (PSL) (30 mg/day), inhaled corticosteroids, and long-acting beta2-agonists. **After...**

Author: Sunao Mikura, Takeshi Saraya, Yuki Y... Publish Year: 2021

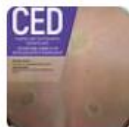Successful Treatment of Mepolizumab- and Prednisolone ...

https://www.jstage.jst.go.jp/article/internalmedicine/advpub/0/advpub_6679-20/_pdf/...

monary aspergillosis and steroid **therapy**. Eur Respir J 25: 324, 2005. 2. Rabe KF, Nair P, Brusselle G, et al. Efficacy and safety of **dupi-lumab** in glucocorticoid-dependent severe asthma. N Engl J Med...

Successful treatment of trichothiodystrophy with ... 翻译此页

<https://onlinelibrary.wiley.com/doi/full/10.1111/ced.14642>



2021-5-6 · Quality of life improved, with the patient a score of 11 of 30 in the Children's Dermatology Life Quality Index, compared with 28 of 30 prior to treatment with **dupilumab**. **After** 1 year of **dupilumab therapy**, the patient's skin appeared almost normal (Fig. ...

Successful Treatment of Mepolizumab- and ... 翻译此页

<https://europepmc.org/article/MED/33642487> ▾

2021-3-1 · Successful Treatment of Mepolizumab- and Prednisolone-resistant **Allergic Bronchopulmonary** Aspergillosis with **Dupilumab**. 1 Please help EMBL-EBI keep the data flowing to the...

Author: Sunao Mikura, Takeshi Saraya, Yuki Y... Publish Year: 2021