

Dear Professor. Bloomfield

Department Clinical Research, Richmond University Medical Center, United States

Editorial office of World Journal of Clinical Cases

We thank you very much for giving us an opportunity to resubmit our manuscript, and we appreciate editor and reviewer very much for their positive and constructive comments and suggestions on our manuscript 'A girl of malignant solitary fibrous tumor in central nervous system after gross total resections shortly recurrence and with good prognosis combination radiotherapy and anlotinib: a case report and literature review' (Manuscript ID: 67815).

We have studied editor and reviewer' comments and suggestions carefully and have made revisions accordingly in the paper. The following is a point-to-point response to the editor and the reviewer' comments. All the authors have been and approved of the submission of this revised manuscript which we wish to be considered for publication in World Journal of Clinical Cases.

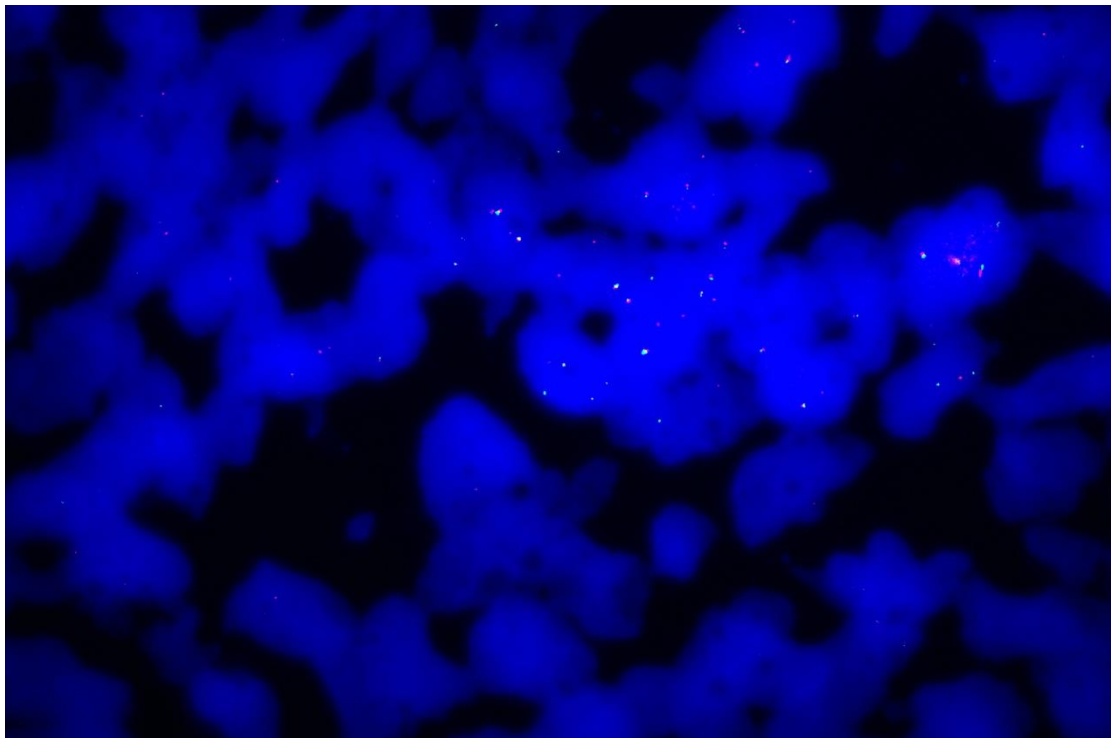
Responses to the comments of Reviewer #1:

1. As the authors mentioned, nuclear expression of STAT6 is specific and essential for SFT. In the tumor of the patient, STAT6 staining was negative and STAT6 fusion was not detected. Some readers might consider that the diagnosis of SFT is questionable. The authors should show some differential diagnosis and the reason they exclude them.

Answer: Thank you very much for your recommendation. Some readers might consider that the diagnosis of SFT is questionable. In the discussion section, the 2nd paragraph 18 line, we add the differential diagnosis.

"The differential diagnosis of SFT in the CNS includes meningioma. MRI initially showed that the mass was broadly attached to the dura matter in our patient. However, the dural tail sign which is the most important characteristic of meningioma on MRI was absent. Secondly, EMA, and SSTR2 were negative in our case by immunohistochemistry, as opposed to meningioma in which EMA and SSTR2 are both positive^[13]. Thirdly, meningioma is usually a benign tumor

and SFT tends to be aggressive. In our case, Ki-67 proliferation index was 80%, and showed that the tumor was very malignant. These features can be used to differentiate SFT from meningioma. As our patient was young, a diagnosis of synovial sarcoma was considered. The diagnosis of synovial sarcoma depends on the cytogenetic change t(X;18) (p11;q11), which is detected by fluorescence in situ hybridization (FISH) assay^[14]. In our case, FISH assay showed that the t(X;18) was negative. Thus, the diagnosis in our patient was not synovial sarcoma. Another differential diagnosis we considered was schwannoma. However, the tumor was located in the frontal-parietal lobe, not the area where the cranial nerves are located. Therefore, a schwannoma was ruled out.”



FISH assay showed the t(X;18) was negative in our case.

2. Adverse events of anlotinib for this patient should be described.

Answer: Thank you very much for your suggestion. Case presentation, treatment part, line 15: we added “During anlotinib treatment, the patient occasionally suffered from loss of appetite, and her laboratory results were within the normal range.”

3. The biological significance of FGFR4 (c.1463G>A, p.Gly488Asp) and TP53 (c.751A>T,

p.Ile251Phe) should be discussed citing descriptions in public databases and previous reports.

Answer: Thank you very much for your recommendation.

In the 5th paragraph, line 12, in discussion part, we have added the discussion of the biological significance of FGFR4. "Oncogene alternations are present in all FGFR family members in human cancers. FGFR are receptor tyrosine kinases (RTKs) consisting of an intracellular tyrosine-kinase domain and an extracellular ligand-binding domain. FGFR 1-3 often occur in amplifications or fusions in some cancers. However, FGFR4 is infrequently mutated in cancers^[28]. FGFR4 mutations are present in 6% of melanomas^[29]. One recent report found that 7% of cancers had FGFR aberrations, and FGFR4 mutation was found in 0.5% of 4853 tumors^[30]. Y367C mutation of the FGFR4 gene in the breast cancer cell line MDA-MB453 promoted tumor growth^[31]. Futami et al identified FGFR4 mutation in one of 83 gastric tumor specimens, and cells expressing this mutation showed a malignant phenotype^[32]. Multi-targeted tyrosine kinase inhibitors (TKIs) can be used to inactivate FGFR4 by disrupting ATP binding in its TK domains^[33]. Potential mechanisms of FGFR4 activation include FGFR4 overexpression and somatic mutations^[34]. Therefore, we speculated that FGFR4 mutation was likely to be the "driver" mutation and resulted in increased FGFR signaling in this patient. FGFR4 mutation might be a key anticancer target for anlotinib in the treatment of malignant intracranial SFT."

In the 6th paragraph, line 4, in discussion part, we have added the discussion of the biological significance of TP53. "Recent research found that anlotinib induced apoptosis in TP53 D259Y and R248G mutants, which were able to induce apoptosis through their its transcription-independent function^[37]. Fang et al identified three cases with TP53 mutations (p.S183X on exon 5, p.S241F on exon 7, p.R175H on exon 5, K320fs on exon 9) which might represent biomarkers for predicting the effects of anlotinib in non-small-cell lung cancer^[38]. Wu et al reported a patient with pulmonary artery sarcoma harboring a TP53 mutation (p.R110P in exon 4) who had a favorable response to anlotinib^[39]. Kurisaki-Arakawa et al found dedifferentiated solitary fibrous tumors in the pelvis with a TP53 mutation (p.A158H in exon 5)^[40]. Morimitsu et al found the TP53 mutation p.A116T in one of 17 cases with solitary extrapleural fibrous

tumors^[41]. These findings suggest that various mutations of TP53 in SFTs are common, and tumors with TP53 mutations are more likely to respond to anlotinib.”

4. In the Discussion, reference should be noted for “Wu et al reported a case harboring TP53 mutation was favorable responses to anlotinib with the diagnosis of pulmonary artery sarcoma.”

Answer: Thank you very much for your valuable suggestions. Due to our negligence in writing, we forgot to insert references. We have inserted references (Wu Y, Huang J, Wang Q, Zhang M, Luo Y, Wang X, Zhu X, Liu H. Whole-exome sequencing insights into pulmonary artery sarcoma mimicking pulmonary embolism: A case report and review. *Onco Targets Ther* 2019; 12: 6227-6235 [PMID: 31496726 DOI: 10.2147/OTT.S212416]).

5. Grammatical errors and incomprehensible expressions should be corrected by a native English speaker.

Answer: Thank you very much for your recommendation. We have edited and corrected English grammar used MedE Editing Group.

MedE Editing Service 麦迪文编辑
<http://meditoxpert.com>

EDITORIAL CERTIFICATE
(Ref. OCJLME-MS2021102717R)

We herein certify that the following document has been edited for English language by a native English speaking medical editor at MedE Medical Editing Group. The edited paper has reached grade A in language evaluation for SCI journals.

Manuscript title
Malignant solitary fibrous tumor in the central nervous system treated with surgery, radiotherapy and anlotinib: A case report

First author and affiliations
Dong-Yong Zhang, the First Affiliated Hospital of China Medical University, Shenyang, China

Date issued
October 31, 2021

*We are NOT responsible for any error in the added content to our revised version after this date.

MedE Medical Editing Group Inc.
+86-10-82082089
<http://meditoxpert.com>
Email: info@meditoxpert.com
File-code:MS2021102717R-OCJLME



MedE provides services of translation and English language editing in medical sciences, and training and guidance of medical writing, editing and publishing. Our team consists of senior native-English-speaking medical editors with M.D./Ph.D, bilingual medical editors with over 20 years of experience, and translators with medical background and a good command of English.

Responses to the comments of Reviewer #2:

1. Page 5, “Pathology” section. The first, the authors should show the definition of

“malignant” SFT. The next, following the criteria, the description of the histopathology should be done.

Answer: Thank you very much for your valuable suggestions. We added the definition of malignant SFT and description of the histopathology how to diagnose malignant SFT.

“Further diagnostic work-up” section, we added “hypercellularity and increased mitotic activity were observed in the tumor [>4 mitosis/10 high-power fields (HPF)]” in the line 4.

In the discussion part, at the end of 2nd paragraph, we added the definition of malignant SFT. “A malignant SFT has been shown to be hypercellular, mitotically active (> 4 mitosis/10 HPF), with cytological atypia, tumor necrosis and /or infiltrative margins^[15]. Although our case did not show NAB2-STAT6 fusion following high-throughput sequencing and STAT6 expression on immunohistochemistry, CT scanning, MRI imaging, morphologic examination, conventional immunohistochemistry (positive for CD99, Bcl-2 and Vimentin), high Ki-67 proliferation index and the exclusion of other tumors resulted in the diagnosis of malignant SFT.”

2. Line 3, page6, showed a solid mass lesion, suggesting quickly progressive tumor (Fig.1 C).

→The recurrent MRI image looks like local recurrence. The recurrent tumor is recognized on the cut margin. Is primary surgery R0 resection? Do the authors have the proof of the complete resection with tumor free margin? The rapid progression of the malignant SFT should be clarified from the simple local recurrence due to the incisional resection.

Answer: thank you for your suggestion. Because of the tumor was in the rolandic area, if we resected the tumor with R0 resection, the complication was high, such as bleeding, embolization and motor decline. Therefore, our surgery is not R0 resection, and we have not the proof of the complete resection with tumor free margin. Our resection is not gross total resection, and we changed the expression of gross total resection.

In the discussion of 3rd paragraph line 3, we added the reason of the rapid progression of local recurrence by incisional resection. “Although gross total resection offers a potential cure, improvement or preservation of motor function is crucial for patients. During surgery, we found that the tumor invaded the arachnoid, and gross total resection could cause the damage to

the underlying cortex. Thus, gross total resection was not performed in our patient. Her muscle strength after surgery was better than that before surgery, and she could walk unaided. However, the disadvantage of this surgical method is that the tumor can recur. MRI (1.5 mo after surgery) showed a solid mass on the cut margin.”

Our article previous title was “A girl of malignant solitary fibrous tumor in central nervous system after gross total resections shortly recurrence and with good prognosis combination radiotherapy and anlotinib: a case report and literature review”. Now, we have changed the title to “ Malignant solitary fibrous tumor in the central nervous system treated with surgery, radiotherapy and anlotinib: A case report.”

In the summary, introduction, treatment and discussion parts, we used “resection” instead of “total resection”.

3. “Treatment” section, Line 4, page 6: The patient did not walk by herself and physical examination showed muscle strength grade 3 in the right limbs. The patient received 60 Gy and 30 fractions of radiation by intensity modulated radiotherapy. After 19 days of radiotherapy, the patient could walk by herself.

→These expressions of the clinical course are confusing. Please explain the academical reasons for very rapid improvement after the radiotherapy.

Answer: Thank for your suggestions.

In the 3rd paragraph line 25 of discussion, we added the reasons for very rapid improvement after the radiotherapy. “We speculated that there were three main reasons for rapid alleviation of the patient's symptoms. The first is that the time for the tumor to press against the motor zone of the cortex was relatively short, and did not cause necrosis of cortical cells.

Radiotherapy induces tumor cell necrosis, and the functions of these cells are then restored.

The second is that we administered mannitol to relieve symptoms by reducing intracranial pressure. The third is that the tumor was more sensitive to radiotherapy, and it was effectively controlled.”

4. “Conclusion” section, Line 20, page9; Our case is the first report in the word in

which a patient was treated by surgery, radiotherapy and anlotinib monotherapy.

→If this is the first regimen for the malignant SFT, "ethics approval and consent to participate" should be needed at the end of the text.

Answer: thank you for your suggestion, we added "Informed consent for treatment was obtained from the patient's parents " in the informed consent statement.

5. "Figure" section: Do the authors have the PET-CT data in order to evaluate the distant metastasis?

Please disclose the images.

Answer: Thank you for your suggestion. Malignant SFT showed rapid local recurrence and distant metastasis. The most frequent location of distant metastasis was the lung followed by bone (Hassani M, Jung S, Garzia L, Ghodsi E, Alcindor T, Turcotte RE. Aggressive behavior predictors in solitary fibrous tumor: Demographic, clinical, and histopathologic characteristics of 81 cases. Ann Surg Oncol 2021; 28: 6861-6867 [PMID: 33512676 DOI: 10.1245/s10434-021-09592-w]). Unenhanced chest CT scan before surgery (2019-5-21, showed in below picture) and 1.5 yr after surgery (2021-3-9, showed in below picture) revealed no nodules in the chest. The patient had no symptoms of discomfort in the bone. Considering that the patient was young and the PET-CT radiation was larger, we did not perform PET-CT for the patient.

"An unenhanced chest CT scan revealed no nodules in the chest" had added the end of "Imaging examinations" and "OUTCOME AND FOLLOW-UP" section.

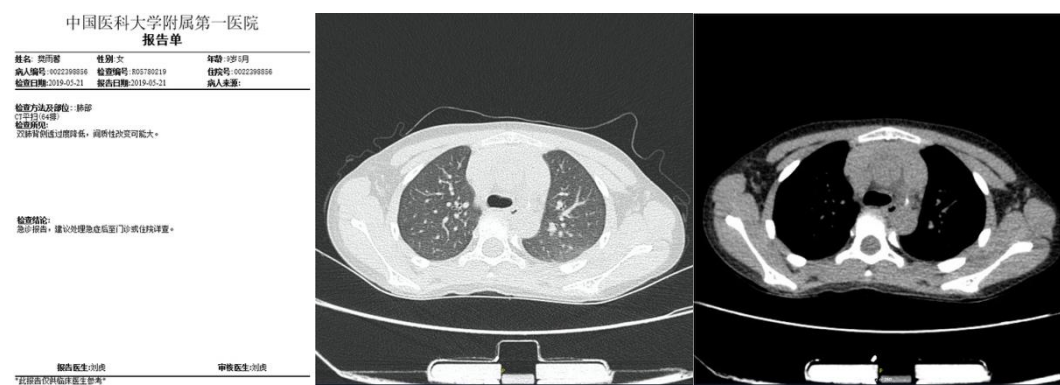


Figure. Chest CT report and representative pictures suggest no nodules in chest (2019-5-21)

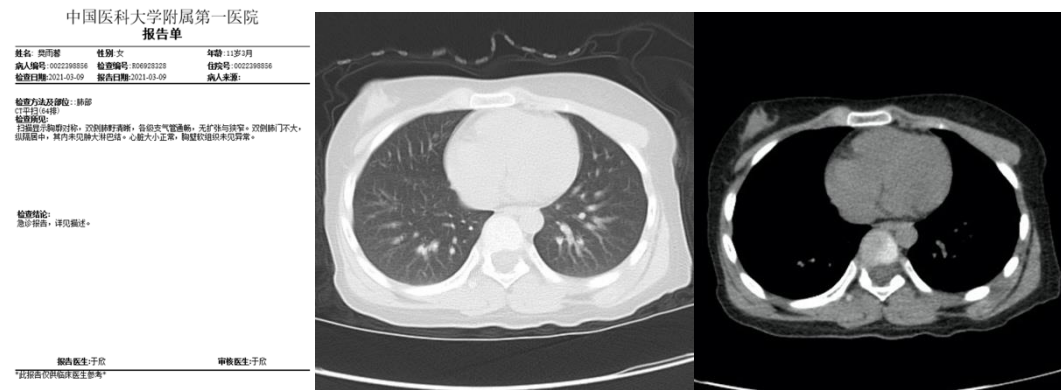


Figure. Chest CT report and representative pictures suggest no nodules in chest (2021-3-9)

Responses to the comments of Science editor.

1. The language classification is Grade C. Please visit the following website for the professional English language editing companies we recommend:

<https://www.wjgnet.com/bpg/gerinfo/240>

Answer: Thank you very much for your recommendation. We have edited and corrected English grammar used MedE Editing Group.

MedE Editing Service 麦迪文编辑
<http://meditoxpert.com>

EDITORIAL CERTIFICATE
(Ref. OCJLME-MS2021102717R)

We herein certify that the following document has been edited for English language by a native English speaking medical editor at MedE Medical Editing Group. The edited paper has reached grade A in language evaluation for SCI journals.

Manuscript title
Malignant solitary fibrous tumor in the central nervous system treated with surgery, radiotherapy and anlotinib: A case report

First author and affiliations
Dong-Yong Zhang, the First Affiliated Hospital of China Medical University, Shenyang, China

Date issued
October 31, 2021

*We are NOT responsible for any error in the added content to our revised version after this date.

MedE Medical Editing Group Inc.
+86-10-82082089
<http://meditoxpert.com>
Email: info@meditoxpert.com
File-code: MS2021102717R-OCJLME

Editing Service
MedE
CERTIFIED

MedE provides services of translation and English language editing in medical sciences, and training and guidance of medical writing, editing and publishing. Our team consists of senior native-English-speaking medical editors with M.D./Ph.D, bilingual medical editors with over 20 years of experience, and translators with medical background and a good command of English.

2. The title is too long, and it should be no more than 18 words

Answer: Thank you very much for your recommendation. We have changed the title for

“Malignant solitary fibrous tumor in the central nervous system treated with surgery, radiotherapy and anlotinib: A case report.” The words of the title were 18 words.

3. The authors did not provide original pictures. Please provide the original figure documents. Please prepare and arrange the figures using PowerPoint to ensure that all graphs or arrows or text portions can be reprocessed by the editor.

Answer: Thank you very much for your recommendation. We provided the original figure documents in a single PowerPoint file.

4. The authors didn't provide the written informed consent of treatment.

Answer: thank you for your suggestion, we added “we added “Informed consent for treatment was obtained from the patient's parents ” in the informed consent statement. We uploaded the informed consent of the treatment.

5. One of the references has not the DOI name.

We found the DOI name at <http://www.crossref.org/SimpleTextQuery/> and other web site, this references has not DOI name (Reference 12. Han Y, Zhang Q, Yu X, Han X, Wang H, Xu Y, Qiu X, Jin F. Immunohistochemical detection of stat6, cd34, cd99 and bcl-2 for diagnosing solitary fibrous tumors/hemangiopericytomas. Int J Clin Exp Pathol 2015; 8: 13166-13175 [PMID: 26722515 DOI: not found])

Responses to the comments of editor-in-chief

Answer: Thank you very much for your recommendation. The legend of the figures has been changed for “ A: ...; B: ...; C: ...; D: ...; E: ...; F: ...; G: ...”. We provided the original figure documents in a single PowerPoint file. We have changed the title for “Malignant solitary fibrous tumor in the central nervous system treated with surgery, radiotherapy and anlotinib: A case report.” The words of the title were 18 words.

Special thanks to you for your good comments.

We tried our best to improve the manuscript and made some changes in the manuscript. These

changes will not influence the content and framework of the paper.

We appreciate for Editors/Reviewers' warm work earnestly, and hope that the correction will meet with approval. Once again, thank you very much for your comments and suggestions 。

Your sincerely,

Dongyong Zhang

Assistant Professor

Department of Neurosurgery, The First Affiliated Hospital of China Medical University

Email: zhangdongyong@cmu.edu.cn