

# World Journal of *Clinical Cases*

*World J Clin Cases* 2022 January 7; 10(1): 1-396



## Contents

Weekly Volume 10 Number 1 January 7, 2022

## MINIREVIEWS

- 1      Omicron variant (B.1.1.529) of SARS-CoV-2: Mutation, infectivity, transmission, and vaccine resistance  
*Ren SY, Wang WB, Gao RD, Zhou AM*
- 12     Hepatitis B virus reactivation in rheumatoid arthritis  
*Wu YL, Ke J, Zhang BY, Zhao D*
- 23     Paradoxical role of interleukin-33/suppressor of tumorigenicity 2 in colorectal carcinogenesis: Progress and therapeutic potential  
*Huang F, Chen WY, Ma J, He XL, Wang JW*

## ORIGINAL ARTICLE

## Case Control Study

- 35      Changes in rheumatoid arthritis under ultrasound before and after sinomenine injection  
*Huang YM, Zhuang Y, Tan ZM*
- 43      Benefits of multidisciplinary collaborative care team-based nursing services in treating pressure injury wounds in cerebral infarction patients  
*Gu YH, Wang X, Sun SS*

## Retrospective Study

- 51      Outcomes and complications of open, laparoscopic, and hybrid giant ventral hernia repair  
*Yang S, Wang MG, Nie YS, Zhao XF, Liu J*
- 62      Surgical resection of intradural extramedullary tumors in the atlantoaxial spine *via* a posterior approach  
*Meng DH, Wang JQ, Yang KX, Chen WY, Pan C, Jiang H*
- 71      Vancomycin lavage for the incidence of acute surgical site infection following primary total hip arthroplasty and total knee arthroplasty  
*Duan MY, Zhang HZ*
- 79      Distribution of transient receptor potential vanilloid-1 channels in gastrointestinal tract of patients with morbid obesity  
*Atas U, Erin N, Tazegul G, Elpek GO, Yıldırım B*
- 91      Value of neutrophil-lymphocyte ratio in evaluating response to percutaneous catheter drainage in patients with acute pancreatitis  
*Gupta P, Das GC, Bansal A, Samanta J, Mandavdhare HS, Sharma V, Naseem S, Gupta V, Yadav TD, Dutta U, Varma N, Sandhu MS, Kochhar R*

- 104** Influence of overweight and obesity on the mortality of hospitalized patients with community-acquired pneumonia  
*Wang N, Liu BW, Ma CM, Yan Y, Su QW, Yin FZ*
- 117** Minimally invasive open reduction of greater tuberosity fractures by a modified suture bridge procedure  
*Kong LP, Yang JJ, Wang F, Liu FX, Yang YL*
- 128** Increased levels of lactate dehydrogenase and hypertension are associated with severe illness of COVID-19  
*Jin ZM, Shi JC, Zheng M, Chen QL, Zhou YY, Cheng F, Cai J, Jiang XG*
- 136** Age, alcohol, sex, and metabolic factors as risk factors for colonic diverticulosis  
*Yan Y, Wu JS, Pan S*
- 143** Evaluation of right-to-left shunt on contrast-enhanced transcranial Doppler in patent foramen ovale-related cryptogenic stroke: Research based on imaging  
*Xiao L, Yan YH, Ding YF, Liu M, Kong LJ, Hu CH, Hui PJ*
- 155** Characterization of focal hypermetabolic thyroid incidentaloma: An analysis with F-18 fluorodeoxyglucose positron emission tomography/computed tomography parameters  
*Lee H, Chung YS, Lee JH, Lee KY, Hwang KH*

### Clinical Trials Study

- 166** Low-dose intralesional injection of 5-fluorouracil and triamcinolone reduces tissue resident memory T cells in chronic eczema  
*Wu Y, Wang GJ, He HQ, Qin HH, Shen WT, Yu Y, Zhang X, Zhou ML, Fei JB*

### Observational Study

- 177** Alterations in blink and masseter reflex latencies in older adults with neurocognitive disorder and/or diabetes mellitus  
*Bricio-Barrios JA, Rios-Bracamontes E, Rios-Silva M, Huerta M, Serrano-Moreno W, Barrios-Navarro JE, Ortiz GG, Huerta-Trujillo M, Guzmán-Esquivel J, Trujillo X*
- 189** Predicting adolescent perfectionism: The role of socio-demographic traits, personal relationships, and media  
*Livazović G, Kuzmanović K*
- 205** Novel m.4268T>C mutation in the mitochondrial tRNA<sup>Leu</sup> gene is associated with hearing loss in two Chinese families  
*Zhao LJ, Zhang ZL, Fu Y*
- 217** Superior mesenteric venous thrombosis: Endovascular management and outcomes  
*Alnahhal K, Toskich BB, Nussbaum S, Li Z, Erben Y, Hakaim AG, Farres H*

### Randomized Controlled Trial

- 227** Zinc carnosine-based modified bismuth quadruple therapy *vs* standard triple therapy for *Helicobacter pylori* eradication: A randomized controlled study  
*Ibrahim N, El Said H, Choukair A*

## CASE REPORT

- 236 Acquired coagulation dysfunction resulting from vitamin K-dependent coagulation factor deficiency associated with rheumatoid arthritis: A case report  
*Huang YJ, Han L, Li J, Chen C*
- 242 Intraoperative thromboelastography-guided transfusion in a patient with factor XI deficiency: A case report  
*Guo WJ, Chen WY, Yu XR, Shen L, Huang YG*
- 249 Positron emission tomography and magnetic resonance imaging combined with computed tomography in tumor volume delineation: A case report  
*Zhou QP, Zhao YH, Gao L*
- 254 Successful response to camrelizumab in metastatic bladder cancer: A case report  
*Xie C, Yuan X, Chen SH, Liu ZY, Lu DL, Xu F, Chen ZQ, Zhong XM*
- 260 HER2 changes to positive after neoadjuvant chemotherapy in breast cancer: A case report and literature review  
*Wang L, Jiang Q, He MY, Shen P*
- 268 Hyper-accuracy three-dimensional reconstruction as a tool for better planning of retroperitoneal liposarcoma resection: A case report  
*Ye MS, Wu HK, Qin XZ, Luo F, Li Z*
- 275 Recurrent postmenopausal bleeding - just endometrial disease or ovarian sex cord-stromal tumor? A case report  
*Wang J, Yang Q, Zhang NN, Wang DD*
- 283 Complex proximal femoral fracture in a young patient followed up for 3 years: A case report  
*Li ZY, Cheng WD, Qi L, Yu SS, Jing JH*
- 289 Bilateral Hypertrophic Olivary Degeneration after Pontine Hemorrhage: A Case Report  
*Zheng B, Wang J, Huang XQ, Chen Z, Gu GF, Luo XJ*
- 296 Clinical characteristics and outcomes of primary intracranial alveolar soft-part sarcoma: A case report  
*Chen JY, Cen B, Hu F, Qiu Y, Xiao GM, Zhou JG, Zhang FC*
- 304 Removal of laparoscopic cerclage stitches *via* laparotomy and rivanol-induced labour: A case report and literature review  
*Na XN, Cai BS*
- 309 Cerebral venous sinus thrombosis in pregnancy: A case report  
*Zhou B, Huang SS, Huang C, Liu SY*
- 316 Eustachian tube teratoma: A case report  
*Li JY, Sun LX, Hu N, Song GS, Dou WQ, Gong RZ, Li CT*

- 323** Protein-losing enteropathy caused by a jejunal ulcer after an internal hernia in Petersen's space: A case report  
*Yasuda T, Sakurazawa N, Kuge K, Omori J, Arai H, Kakinuma D, Watanabe M, Suzuki H, Iwakiri K, Yoshida H*
- 331** Lunate dislocation with avulsed triquetral fracture: A case report  
*Li LY, Lin CJ, Ko CY*
- 338** Clinical manifestations and prenatal diagnosis of Ullrich congenital muscular dystrophy: A case report  
*Hu J, Chen YH, Fang X, Zhou Y, Chen F*
- 345** Diagnosis and guidance of treatment of breast cancer cutaneous metastases by multiple needle biopsy: A case report  
*Li ZH, Wang F, Zhang P, Xue P, Zhu SJ*
- 353** Test of incremental respiratory endurance as home-based, stand-alone therapy in chronic obstructive pulmonary disease: A case report  
*Dosbaba F, Hartman M, Batalik L, Brat K, Plutinsky M, Hnatiak J, Formiga MF, Cahalin LP*
- 361** Diagnostic and surgical challenges of progressive neck and upper back painless masses in Madelung's disease: A case report and review of literature  
*Yan YJ, Zhou SQ, Li CQ, Ruan Y*
- 371** Suspected cerebrovascular air embolism during endoscopic esophageal varices ligation under sedation with fatal outcome: A case report  
*Zhang CMJ, Wang X*
- 381** An atypical primary malignant melanoma arising from the cervical nerve root: A case report and review of literature  
*Shi YF, Chen YQ, Chen HF, Hu X*
- 388** Epidural blood patch for spontaneous intracranial hypotension with subdural hematoma: A case report and review of literature  
*Choi SH, Lee YY, Kim WJ*

**ABOUT COVER**

Editorial Board Member of *World Journal of Clinical Cases*, Ravi Kant, MD, Associate Professor, Division of Endocrinology, Diabetes and Metabolism, Medical University of South Carolina/Anmed Campus, Anderson, SC 29621, United States. rkant82@hotmail.com

**AIMS AND SCOPE**

The primary aim of *World Journal of Clinical Cases* (WJCC, *World J Clin Cases*) is to provide scholars and readers from various fields of clinical medicine with a platform to publish high-quality clinical research articles and communicate their research findings online.

WJCC mainly publishes articles reporting research results and findings obtained in the field of clinical medicine and covering a wide range of topics, including case control studies, retrospective cohort studies, retrospective studies, clinical trials studies, observational studies, prospective studies, randomized controlled trials, randomized clinical trials, systematic reviews, meta-analysis, and case reports.

**INDEXING/ABSTRACTING**

The WJCC is now indexed in Science Citation Index Expanded (also known as SciSearch®), Journal Citation Reports/Science Edition, Scopus, PubMed, and PubMed Central. The 2021 Edition of Journal Citation Reports® cites the 2020 impact factor (IF) for WJCC as 1.337; IF without journal self cites: 1.301; 5-year IF: 1.742; Journal Citation Indicator: 0.33; Ranking: 119 among 169 journals in medicine, general and internal; and Quartile category: Q3. The WJCC's CiteScore for 2020 is 0.8 and Scopus CiteScore rank 2020: General Medicine is 493/793.

**RESPONSIBLE EDITORS FOR THIS ISSUE**

Production Editor: Lin-YuTong Wang; Production Department Director: Xiang Li; Editorial Office Director: Jin-Lei Wang.

**NAME OF JOURNAL**

*World Journal of Clinical Cases*

**ISSN**

ISSN 2307-8960 (online)

**LAUNCH DATE**

April 16, 2013

**FREQUENCY**

Weekly

**EDITORS-IN-CHIEF**

Bao-Gan Peng

**EDITORIAL BOARD MEMBERS**

<https://www.wjgnet.com/2307-8960/editorialboard.htm>

**PUBLICATION DATE**

January 7, 2022

**COPYRIGHT**

© 2022 Baishideng Publishing Group Inc

**INSTRUCTIONS TO AUTHORS**

<https://www.wjgnet.com/bpg/gerinfo/204>

**GUIDELINES FOR ETHICS DOCUMENTS**

<https://www.wjgnet.com/bpg/GerInfo/287>

**GUIDELINES FOR NON-NATIVE SPEAKERS OF ENGLISH**

<https://www.wjgnet.com/bpg/gerinfo/240>

**PUBLICATION ETHICS**

<https://www.wjgnet.com/bpg/GerInfo/288>

**PUBLICATION MISCONDUCT**

<https://www.wjgnet.com/bpg/gerinfo/208>

**ARTICLE PROCESSING CHARGE**

<https://www.wjgnet.com/bpg/gerinfo/242>

**STEPS FOR SUBMITTING MANUSCRIPTS**

<https://www.wjgnet.com/bpg/GerInfo/239>

**ONLINE SUBMISSION**

<https://www.f6publishing.com>



## Clinical characteristics and outcomes of primary intracranial alveolar soft-part sarcoma: A case report

Jun-Yu Chen, Bo Cen, Fei Hu, Yong Qiu, Guo-Min Xiao, Jun-Ge Zhou, Fang-Cheng Zhang

**ORCID number:** Jun-Yu Chen 0000-0003-2839-2198; Bo Cen 0000-0002-1721-3762; Fei Hu 0000-0003-2713-9291; Yong Qiu 0000-0002-0781-2939; Guo-Min Xiao 0000-0002-3816-8373; Jun-Ge Zhou 0000-0001-8558-0742; Fang-Cheng Zhang 0000-0003-1775-2797.

**Author contributions:** Chen JY contributed to data curation, formal analysis, and original draft; Chen JY and Zhang FC contributed to conceptualization and methodology; Chen JY, Cen B, Qiu Y, and Zhou JG provided resources; Chen JY, Qiu Y, Xiao GM, and Zhang FC wrote the paper; Cen B and Zhou JG generated the figures/table for data visualization; Cen B and Hu F supervised the study; Fei Hu and Xiao GM validated the findings; Qiu Y, Xiao GM, and Zhang FC reviewed and edited paper.

**Informed consent statement:** Informed consent was obtained from all individual participants included in the study.

**Conflict-of-interest statement:** Authors have nothing to disclose.

**CARE Checklist (2016) statement:** The authors have read the CARE Checklist (2016), and the manuscript was prepared and revised according to the CARE Checklist (2016).

**Jun-Yu Chen, Bo Cen, Fei Hu, Yong Qiu, Guo-Min Xiao, Jun-Ge Zhou,** Department of Neurosurgery, General Hospital of the Yangtze River Shipping, Wuhan 430010, Hubei Province, China

**Fang-Cheng Zhang,** Department of Neurosurgery, Wuhan Union Hospital, Wuhan 430010, Hubei Province, China

**Corresponding author:** Fang-Cheng Zhang, MD, Professor, Department of Neurosurgery, Wuhan Union Hospital, No. 1277 Jiefang Avenue, Wuhan 430010, Hubei Province, China. [zfcwhuh@gmail.com](mailto:zfcwhuh@gmail.com)

### Abstract

#### BACKGROUND

Primary intracranial alveolar soft-part sarcoma (PIASPS) is a rare malignancy. We aimed to investigate the clinical profiles and outcomes for PIASPS.

#### CASE SUMMARY

We firstly reported five consecutive cases from our institute. Then, the cases from previous studies were pooled and analyzed to delineate the characteristics of this disease. Our cohort included two males and three females. The median age was 21-years-old (range: 8-54-years-old). All the patients received surgical treatment. Gross total resection (GTR), radiotherapy, and chemotherapy were administered in 3 patients, 4 patients, and 1 patient, respectively. After a median follow-up of 36 mo, tumor progression was noticed in 4 patients; and 3 patients died of the disease. Pooled data ( $n = 14$ ) contained 5 males and 9 females with a median age of 19 years. The log-rank tests showed that GTR ( $P = 0.011$ ) could prolong progression-free survival, and radiotherapy ( $P < 0.001$ ) resulted in longer overall survival.

#### CONCLUSION

Patients with PIASPS suffer from poor outcomes. Surgical treatment is the first choice, and GTR should be achieved when the tumor is feasible. Patients with PIASPS benefit from radiotherapy, which should be considered as a part of treatment therapies.

**Key Words:** Primary intracranial alveolar soft-part sarcoma; Surgery; Radiotherapy; Progression-free survival; Overall survival; Case report



**Country/Territory of origin:** China**Specialty type:** Oncology**Provenance and peer review:**

Unsolicited article; Externally peer reviewed.

**Peer-review model:** Single blind**Peer-review report's scientific quality classification**

Grade A (Excellent): 0

Grade B (Very good): 0

Grade C (Good): C

Grade D (Fair): 0

Grade E (Poor): 0

**Open-Access:** This article is an open-access article that was selected by an in-house editor and fully peer-reviewed by external reviewers. It is distributed in accordance with the Creative Commons Attribution NonCommercial (CC BY-NC 4.0) license, which permits others to distribute, remix, adapt, build upon this work non-commercially, and license their derivative works on different terms, provided the original work is properly cited and the use is non-commercial. See: <http://creativecommons.org/licenses/by-nc/4.0/>

**Received:** May 18, 2021**Peer-review started:** May 18, 2021**First decision:** July 5, 2021**Revised:** July 15, 2021**Accepted:** November 30, 2021**Article in press:** November 30, 2021**Published online:** January 7, 2022**P-Reviewer:** Ottaviano M**S-Editor:** Liu M**L-Editor:** Filipodia**P-Editor:** Liu M

©The Author(s) 2022. Published by Baishideng Publishing Group Inc. All rights reserved.

**Core Tip:** Alveolar soft part sarcoma, or alveolar soft-part sarcoma (ASPS), is reportedly a rare tumor with a high recurrent rate. Current understanding of primary intracranial ASPS, or primary intracranial ASPS (PIASPS), is limited to case reports or small case series that preclude statistical analysis of outcomes (e.g., progression-free survival or overall survival). In this article, we first reported 5 consecutive cases from our institute. Then, the 9 cases from previous studies were pooled and analyzed to delineate the characteristics of this disease. We found PIASPS was a rare malignancy and predominately affected young females. Patients with PIASPS suffer from poor outcomes, characterized by a high tendency of recurrence. Surgical treatment is the first choice and gross total resection should be achieved when the tumor is feasible. Besides, PIASPS benefit from radiotherapy, which should be considered as a part of treatment therapies.

**Citation:** Chen JY, Cen B, Hu F, Qiu Y, Xiao GM, Zhou JG, Zhang FC. Clinical characteristics and outcomes of primary intracranial alveolar soft-part sarcoma: A case report. *World J Clin Cases* 2022; 10(1): 296-303

**URL:** <https://www.wjgnet.com/2307-8960/full/v10/i1/296.htm>

**DOI:** <https://dx.doi.org/10.12998/wjcc.v10.i1.296>

## INTRODUCTION

Alveolar soft part sarcoma (ASPS) accounts for less than 1% of soft-tissue sarcoma[1]. Christopherson *et al*[2] first described ASPS as a unique variant from general soft-tissue sarcoma in 1952. ASPSs are characterized by pseudoalveolar architecture and various cytoplasmic inclusion bodies with diastase-resistant periodic acid-Schiff crystalline[3]. *ASPSCR1-TFE3* (or *ASPL-TFE3*), a fusion gene, has been shown to contribute to tumor genesis and be particularly informative in diagnosing ASPS[4,5]. While the exact cell (myogenic or neurogenic) origin of ASPS is disputable, the sarcoma entity is mainly found in the lower extremities and, to a lesser extent, in the upper extremity or trunk, head and neck, and abdomen[6]. ASPSs tend to metastasize, and brain is one of the most common targets[7,8]. Accordingly, intracranial ASPS presents as primary and metastatic ASPS, with the former being less common. The current understanding of primary intracranial ASPS (PIASPS) was based on 8 case reports (9 cases)[3,9-15]. In this study, we firstly reported 5 consecutive cases from our institute to delineate the clinical characteristics of this disease. Then, the cases from previous studies were pooled to evaluate the efficacy of treatment options in patients' outcomes with PIASPS.

## CASE PRESENTATION

### Chief complaints

There were 5 patients with PIASPS between 2005 and 2019, including 2 males and 3 females (Table 1). The median age of the 5 cases was 21 years (range: 8-54-years-old). One patient was asymptomatic, and the intracranial lesion was found because of routine computed tomography (CT) for a minor cranial injury. The other 4 patients suffered from various symptoms, including headache in 3 cases, aphasia, muscle weakness, each in 1 case.

### History of present illness

For the 4 symptomatic patients, the median duration from the onset of symptoms to the diagnosis was 7.5 mo (range: 2-24 mo). Worsened headache (2/3) and muscle weakness (1/1) were reported after the onset of symptoms.

### History of past illness

One patient had an injury in the spinal column in his childhood, which was well



**Table 1** Fourteen cases from previous literature and our institute

Ref.	Sex/age	Location/diameter	Treatment strategies	Salvage treatments and outcomes
Bots <i>et al</i> [9], 1988	M/9 yr	Pituitary gland	NGTR + RT (45 Gy)	Metastases (12.3 mo, GTR); alive (40 mo)
Bodi <i>et al</i> [3], 2009	F/39 yr	L temporal/6 cm	GTR	Tumor free; NED (10 mo)
Das <i>et al</i> [10], 2012	F/17 yr	Bifrontal	GTR + RT	Tumor free; NED (4 mo)
Mandal <i>et al</i> [11], 2013	F/32 yr	R parietal	GTR	
Ahn <i>et al</i> [12], 2014	F/9 yr	R CPA/4.5 cm	NGTR + RT (54 Gy)	LR (14 mo, NGTR + GKS + CMT <sup>1</sup> ); alive (56 mo)
Emmez <i>et al</i> [13], 2015	F/11 yr	L frontal	GTR + RT (54 Gy) + CMT <sup>2</sup>	LR (45 mo, GTR + chemotherapy); alive (54 mo)
Tao <i>et al</i> [15], 2016	F/28 yr	L frontal/4.1 cm	GTR + RT	Tumor free; alive (27 mo)
Tao <i>et al</i> [19], 2017	M/13 yr	R temporal/3.7 cm	NGTR + RT	LR (14 mo); DOD (24 mo)
Kumar <i>et al</i> [14], 2019	M/21 yr	L post. fossa	GTR	Tumor free; NED (8 mo)
Present	M/24 yr	R frontal/3.5 cm	GTR + RT (52 Gy)	Tumor free; NED (25 mo)
Present	F/53 yr	Ant. skull base/5.0 cm	NGTR + RT (46 Gy) + CMT <sup>3</sup>	LR (10 mo, surg.); AWD (36 mo)
Present	M/21 yr	R parietooccipital/4.0 cm	GTR	Metastases (15 mo); DOD (26 mo)
Present	F/8 yr	R temporal/2.8 cm	NGTR + RT	LR (8 mo, surg.); DOD (50 mo)
Present	F/16 yr	L parietal/3.0 cm	GTR + RT (42 Gy)	LR (32 mo, surg. + CMT <sup>1</sup> + RT); DOD (61 mo)

<sup>1</sup>CMT, ifosfamide, carboplatin, and etoposide.<sup>2</sup>CMT, ifosfamide, vincristine, and actinomycin.<sup>3</sup>CMT, doxorubicin and ifosfamide.

M: Male; F: Female; R: Right; L: Left; GTR: Gross total resection; NGTR: Non-gross total resection; RT: Radiotherapy; GKS: Gamma knife surgery; CMT: Chemotherapy; NED: No evidence of disease; DOD: Dead of disease; LR: Local recurrence.

treated by surgery. No medical history was reported for the other 4 patients.

### Physical examination

Critical and general signs were within the normal range for 5 patients. The neurological examination showed that papilledema was found in 2 patients, diplopia in 1 patient, and myasthenia of the upper right limb in 1 patient.

### Laboratory examinations

Routine blood and urine tests of the 5 patients were normal.

### Imaging examinations

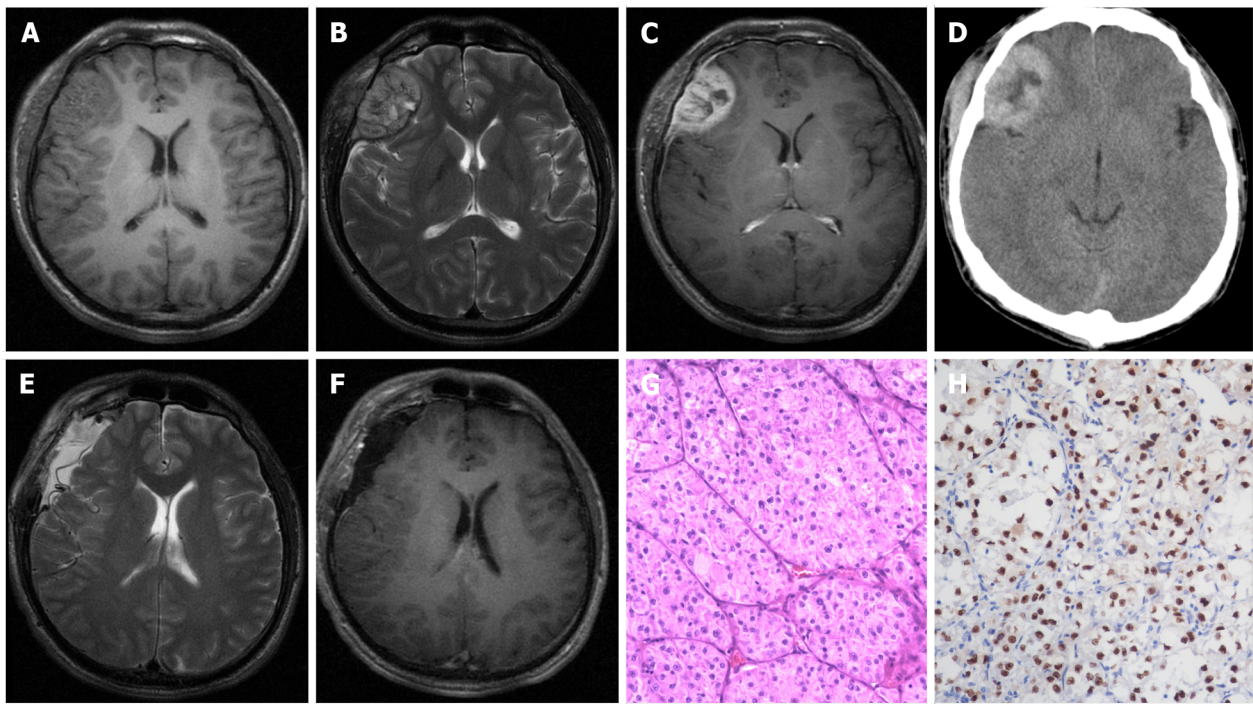
Pre-operative chest X-ray scans were normal in all patients. CT and/or magnetic resonance imaging were performed in all patients. The majority of lesions (4/5) presented as isointense/hypointense on T1 images, isointense/hyperintense on T2 images, and heterogeneous enhancement after the administration of gadolinium, with a heterogeneously high-density appearance on CT scan (Figure 1A-D). The median tumor size was 3.0 cm (range: 2.8-5.0 cm). Anterior skull-base ASPS was found in 1 case; the other 4 ASPSs were frontal, parietal, parieto-occipital, and temporal.

## MULTIDISCIPLINARY EXPERT CONSULTATION

Multidisciplinary expert consultations were recorded for all patients, and one of them (the 10<sup>th</sup> case in Table 1) was presented in this part.

### Jia Wang, MD, Professor and Chief Doctor of Radiologist, Department of Radiology, General Hospital of the Yangtze River Shipping

The radiological appearance of this patient was not typical. Meningioma could be one potential diagnosis.



**Figure 1 Radiological and histopathological findings.** A-D: Pre-operative magnetic resonance imaging and computed tomography revealed a right frontal lesion with an isointense signal on T1 images (axial), hyperintense signal on T2 images (axial), and heterogeneous enhancement after the administration of gadolinium (axial) with a heterogeneously high-density appearance (axial). The presence of a "dural tail sign" was highly suggestive of meningioma; E and F: Postoperative magnetic resonance imaging proved that this lesion had completely resolved; G: Pathological morphology informed the diagnosis of intracranial alveolar soft-part sarcoma (hematoxylin-eosin,  $\times 200$ ); H: Showing that the tumor stained positively for TEF-3, immunohistochemical examination ( $\times 200$ ) further confirmed the diagnosis.

**Jun-Yu Chen, MD, Attending Doctor of Neurosurgeon, Department of Neurosurgery, General Hospital of the Yangtze River Shipping**

Based on symptoms, signs, physical examinations, and radiological scans, a presumed diagnosis was right frontal meningioma. Surgical treatment should be planned to remove the brain tumor and obtain a pathological diagnosis.

**Fei Hu, MD, Professor and Chief Doctor of Neurosurgeon, Department of Neurosurgery, General Hospital of the Yangtze River Shipping**

Craniotomy should be performed *via* the right frontal approach.

**Jing Lv, MD, Professor and Chief Doctor of Pathologist, Department of Pathology, General Hospital of the Yangtze River Shipping**

Under the microscope, the specimens from hematoxylin-eosin staining showed a characteristic appearance of nests of cells loosely arranged along fibrous septa. Immunohistochemistry staining revealed tumor cells were positive for TEF-3. Pathological findings were consistent with the diagnosis of ASPS.

**Fang-Cheng Zhang, Department of Neurosurgery, Wuhan Union Hospital, Tongji Medical College, Huazhong University of Science and Technology, Wuhan, Hubei, China**

Positron emission tomography or combinations of x-ray chest film, abdominal ultrasound scan, and/or CT should be performed to evaluate extracranial lesions. The diagnosis of PIASPS was only made when there was no evidence of extracranial ASPS.

## FINAL DIAGNOSIS

After a pathological diagnosis was established, further diagnostic work-up was conducted when necessary. The final diagnoses of the 5 patients were PIASPS.

## TREATMENT

None of these patients was treated outside regarding the intracranial lesion. All of these patients accepted surgical treatments. In addition to routine hematoxylin and eosin staining (Figure 1G), immunohistochemical examination for TFE-3 was also employed (Figure 1H). Before establishing the diagnosis of PIASPS, extensive screenings were performed to exclude potential extracranial lesions, which included but were not limited to CT chest, abdomen and pelvis, and positron emission tomography.

Postoperatively, gross total resection (GTR) and NGTR were achieved in 3 and 2 patients, respectively. Among the patients who received GTR, 1 patient received no adjuvant therapies and another 2 patients accepted local radiation therapy because of a high Ki-67 index ( $> 10\%$ ). Both NGTR patients received radiotherapy. Consequently, 4 patients received adjuvant radiotherapy postoperatively. The radiation doses available in three patients were 42 Grays, 46 Grays, and 52 Grays. Only 1 patient received chemotherapy (doxorubicin and ifosfamide), which followed NGTR plus radiotherapy.

## OUTCOME AND FOLLOW-UP

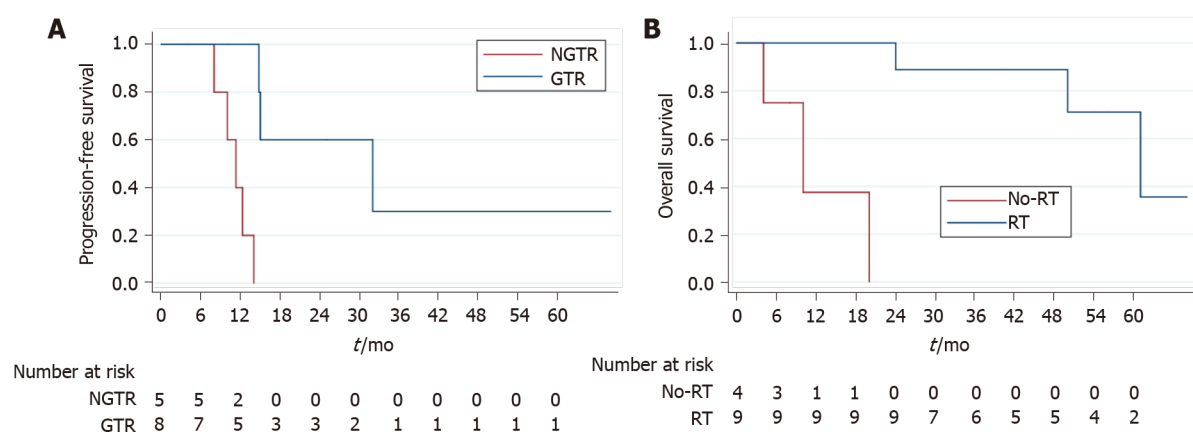
After a median follow-up of 36 mo (range: 25-61 mo), 1 patient remained tumor-free, but tumor progression was noticed in 4 patients. Local recurrence (LR) was observed in 3 patients, and the durations for LR were 8 mo, 10 mo, and 15 mo. All three patients with LR received surgical treatment, with one receiving radiotherapy and chemotherapy after surgery. Another patient suffered from leptomeningeal metastases, and the patient declined further treatments. When this study ended, 3 patients died of the disease (20 mo, 50 mo, and 61 mo after surgery).

## DISCUSSION

An extensive search using the medical subject heading term "alveolar soft-part sarcoma" was conducted in OVID MEDLINE, EMBASE, Cochrane Database, and PubMed. Published cases were included as long as candidates were pathologically diagnosed with PIASPS and reported in the English literature. Cases with the concurrent presence of IASPS and other malignant tumors were excluded. Chen JY and Zhang FC scrutinized the resources of each patient to rule out duplicate cases. The clinical data of interest included the following: Age at diagnosis, sex, tumor location, the extent of surgery, radiotherapy, chemotherapy, progression-free survival (PFS), and overall survival (OS). Statistical analyses of the role of treatment options in prognoses (PFS and OS) were assessed by the Log-rank test using STATA 15.0 (Stata Corp, Lakeway Drive College Station, TX, United States). When  $P$ -value  $< 0.05$ , the difference is considered significant statistically.

To investigate this disease comprehensively, the cases from our center and previous studies were pooled to conduct survival analyses. In brief, the female predominance was confirmed, as the integrated data ( $n = 14$ ) 5 males and 9 females (Table 1). The median age of 14 patients was 19 years, ranging from 8 to 53 years. One patient's follow-up detail was not reported[11]; the other 13 patients were available regarding follow-up data, with a median follow-up being 36 mo (range: 4-68 mo). Tumor progression was found in 8 (61.5%) cases and death due to disease was observed in 4 (30.4%) cases. The 3-year PFS and OS were 15.5% and 67.1%, respectively. According to log-rank tests, GTR (3-year PFS of GTR *vs* NGTR was 36.0% *vs* 0;  $P = 0.011$ ) (Figure 2A) could prolong PFS but not the use of radiotherapy ( $P = 0.128$ ) or chemotherapy ( $P = 0.090$ ). Only radiotherapy (3-year OS of radiotherapy *vs* no radiotherapy was 87.5% *vs* 0;  $P < 0.001$ ) (Figure 2B) resulted in longer OS, and neither GTR ( $P = 0.071$ ) nor chemotherapy ( $P = 0.064$ ) did.

ASPS is a rare tumor with a slow high metastatic rate. Prior research has shown that GPNMB (glycoprotein nmb), a transcriptional target of ASPSCR1-TFE3, might exert a critical role during its systemic metastasis[16]. The brain is one of the most vulnerable sites of metastases[7]. Accounting for the terminal event and primary reason for death among patients with ASPS[8,12], brain metastasis reportedly features an incidence of 11%-21%[1,6,17,18]. However, the incidence of PIASPS is less common. In addition to the 5 cases treated at our institute, only 9 cases with PIASPA were reported[3,9-15]. Our findings based on pooled cases revealed that PIASPS affected young adults with



**Figure 2 Kaplan-Meier survival curves.** A: Gross total resection can prolong progression-free survival (PFS); B: Radiotherapy can improve overall survival (OS). ASPS: Alveolar soft part sarcoma; IASPS: Intracranial alveolar soft part sarcoma.

female predominance; GTR (PFS) and the use of radiotherapy (OS) contributed to better prognoses.

Surgical resection remains the mainstay of the treatment for IASPS[19-21]. Indeed, we found that GTR subgroup achieved a higher 3-year PFS rate when compared with the NGTR in this study. Meanwhile, there was a report[22] stating that surgery was not only associated with improved survival but also with better neurological outcomes. All accessible lesions should be completely removed to achieve better outcomes[19], and staged surgeries have been performed to accomplish this goal[21]. However, statistical analyses failed to prove that GTR could improve the OS in this study, which could be attributed to the relatively small cohort size.

ASPS reportedly responded to radiotherapy, and several authors insisted that on the postoperative administration of radiotherapy to patients with insufficient surgical margins or even as a routine schedule[9,12,15]. Interestingly, when GTR was achieved, some centers still recommended adjuvant radiotherapy[13,15], while other centers did not[3,11,14]. Based on our experience, those patients with a high Ki-67 index or incomplete tumor resection were suitable for radiotherapy. While it was seemingly impossible to evaluate the role of radiotherapy in PIASPS based on previous case reports, pooling cases together indicated that radiotherapy could significantly improve OS. Only 6 cases reported radiation doses in the pooled cohort, which precluded further evaluation of increasing radiation doses' efficacy and safety in treating PFS. Unfortunately, our analyses failed to demonstrate that radiotherapy enabled significantly to prolong PFS. Future studies on optimal radiation modalities, radiation doses, and the optimal radiotherapy administration time are warranted to improve the efficacy of radiotherapy.

Anthracycline- or ifosfamide-based regimens, which were considered effective in treating other soft tissue sarcomas, lacked efficacy in resolving ASPS[7]. Only 3 patients were administrated with chemotherapy in the pooled cohort (Table 1)[10,13]. Consequently, our results failed to find evidence for the efficacy of chemotherapy, in prolonging either PFS or OS. Novel agents, including vascular endothelial growth factor-predominant tyrosine kinase inhibitors (*e.g.*, pazopanib[5]) and the mesenchymal epithelial transition factor receptor[1] (a protein encoded by the ASPSCR1-TFE3 fusion gene), seem to provide more therapeutic options to patients with ASPS. Emerging data showed that ASPS patients benefited from immune checkpoint inhibitors[23,24]. Recently, Su *et al*[25] reported an advanced lung ASPS with multiple metastases, including brain. With combined tyrosine kinase inhibitor and immune checkpoint inhibitor therapy, partial remission in brain metastases was achieved. Benefits from these novel treatments based on limited cases addressed the necessities to verify the response of ASPS in large-scale clinical trials. Therefore, in clinical practice, PIASPS patients should be encouraged to be involved in clinical trials, just similar to primary glioblastoma[26].

The results based on the pooled data should be carefully interpreted, as they were from various centers and distributed among the past 3 decades. However, we tried our best to minimize the bias by retrieving the objective parameters. Finally, this study, to the best of our knowledge, firstly assessed the PFS and OS of patients with PIASPS and the role of treatment options in improving patients' prognoses with PIASPS.



## CONCLUSION

PIASPS is a rare malignancy and predominately affects young females. Patients with PIASPS suffer from poor outcomes, characterized by a high tendency of recurrence. Surgical treatment is the first choice, and GTR should be achieved when the tumor is feasible. Patients with PIASPS benefit from radiotherapy, which should be considered as a part of treatment therapies. Future studies are needed to investigate effective radiation modalities and novel agents.

## ACKNOWLEDGEMENTS

We appreciated Prof. Jia Wang (Department of Neurosurgery, General Hospital of the Yangtze River Shipping) and Jing Lv (Department of Pathology, General Hospital of the Yangtze River Shipping) for their contributions in multidisciplinary expert consultation.

## REFERENCES

- 1 **Paoluzzi L**, Maki RG. Diagnosis, Prognosis, and Treatment of Alveolar Soft-Part Sarcoma: A Review. *JAMA Oncol* 2019; **5**: 254-260 [PMID: [30347044](#) DOI: [10.1001/jamaoncol.2018.4490](#)]
- 2 **Christopherson WM**, Foote FW Jr, Stewart FW. Alveolar soft-part sarcomas; structurally characteristic tumors of uncertain histogenesis. *Cancer* 1952; **5**: 100-111 [PMID: [14886902](#) DOI: [10.1002/1097-0142\(195201\)5:1<100::aid-cnrcr2820050112>3.0.co;2-k](#)]
- 3 **Bodi I**, Gonzalez D, Epaliyange P, Gullan R, Fisher C. Meningeal alveolar soft part sarcoma confirmed by characteristic ASPCR1-TFE3 fusion. *Neuropathology* 2009; **29**: 460-465 [PMID: [18713311](#) DOI: [10.1111/j.1440-1789.2008.00965.x](#)]
- 4 **Heimann P**, Devalck C, Debusscher C, Sariban E, Vamos E. Alveolar soft-part sarcoma: further evidence by FISH for the involvement of chromosome band 17q25. *Genes Chromosomes Cancer* 1998; **23**: 194-197 [PMID: [9739024](#)]
- 5 **Schöffski P**, Wozniak A, Kasper B, Aamdal S, Leahy MG, Rutkowski P, Bauer S, Gelderblom H, Italiano A, Lindner LH, Hennig I, Strauss S, Zakotnik B, Anthoney A, Albiges L, Blay JY, Reichardt P, Sufliarsky J, van der Graaf WTA, Debiec-Rychter M, Sciort R, Van Cann T, Marréaud S, Raveloarivahy T, Collette S, Stacchiotti S. Activity and safety of crizotinib in patients with alveolar soft part sarcoma with rearrangement of TFE3: European Organization for Research and Treatment of Cancer (EORTC) phase II trial 90101 'CREATE'. *Ann Oncol* 2018; **29**: 758-765 [PMID: [29216400](#) DOI: [10.1093/annonc/mdx774](#)]
- 6 **Portera CA Jr**, Ho V, Patel SR, Hunt KK, Feig BW, Respondek PM, Yasko AW, Benjamin RS, Pollock RE, Pisters PW. Alveolar soft part sarcoma: clinical course and patterns of metastasis in 70 patients treated at a single institution. *Cancer* 2001; **91**: 585-591 [PMID: [11169942](#) DOI: [10.1002/1097-0142\(20010201\)91:3<585::aid-cnrcr1038>3.0.co;2-0](#)]
- 7 **Reichardt P**, Lindner T, Pink D, Thuss-Patience PC, Kretzschmar A, Dörken B. Chemotherapy in alveolar soft part sarcomas. What do we know? *Eur J Cancer* 2003; **39**: 1511-1516 [PMID: [12855256](#) DOI: [10.1016/s0959-8049\(03\)00264-8](#)]
- 8 **Lieberman PH**, Foote FW Jr, Stewart FW, Berg JW. Alveolar soft-part sarcoma. *JAMA* 1966; **198**: 1047-1051 [PMID: [5953380](#)]
- 9 **Bots GT**, Tijssen CC, Wijnalda D, Teepeen JL. Alveolar soft part sarcoma of the pituitary gland with secondary involvement of the right cerebral ventricle. *Br J Neurosurg* 1988; **2**: 101-107 [PMID: [3268152](#) DOI: [10.3109/02688698808999666](#)]
- 10 **Das KK**, Singh RK, Jaiswal S, Agrawal V, Jaiswal AK, Behari S. Alveolar soft part sarcoma of the frontal calvarium and adjacent frontal lobe. *J Pediatr Neurosci* 2012; **7**: 36-39 [PMID: [22837776](#) DOI: [10.4103/1817-1745.97621](#)]
- 11 **Mandal S**, Majumdar K, Kumar Saran R, Jagetia A. Meningeal alveolar soft part sarcoma masquerading as a meningioma: a case report. *ANZ J Surg* 2013; **83**: 693-694 [PMID: [23998475](#) DOI: [10.1111/ans.12261](#)]
- 12 **Ahn SH**, Lee JY, Wang KC, Park SH, Cheon JE, Phi JH, Kim SK. Primary alveolar soft part sarcoma arising from the cerebellopontine angle. *Childs Nerv Syst* 2014; **30**: 345-350 [PMID: [23793948](#) DOI: [10.1007/s00381-013-2193-6](#)]
- 13 **Emmez H**, Kale A, Sevinç Ç, Börcek AÖ, Yilmaz G, Kaymaz M, Uluoğlu Ö, Paşaoğlu A. Primary Intracerebral Alveolar Soft Part Sarcoma in an 11-Year-Old Girl: Case Report and Review of the Literature. *NMC Case Rep J* 2015; **2**: 31-35 [PMID: [28663959](#) DOI: [10.2176/nmcrcj.2014-0009](#)]
- 14 **Kumar A**, Alrohman B, Taylor W, Bhattathiri P. Alveolar soft part sarcoma: the new primary intracranial malignancy : A case report and review of the literature. *Neurosurg Rev* 2019; **42**: 23-29 [PMID: [28744773](#) DOI: [10.1007/s10143-017-0874-4](#)]
- 15 **Tao X**, Tian R, Hao S, Li H, Gao Z, Liu B. Primary Intracranial Alveolar Soft-Part Sarcoma: Report of Two Cases and a Review of the Literature. *World Neurosurg* 2016; **90**: 699.e1-699.e6 [PMID: [27111111](#) DOI: [10.1016/j.wneu.2016.05.038](#)]

26862023 DOI: [10.1016/j.wneu.2016.02.005](https://doi.org/10.1016/j.wneu.2016.02.005)]

- 16 **Tanaka M**, Homme M, Yamazaki Y, Shimizu R, Takazawa Y, Nakamura T. Modeling Alveolar Soft Part Sarcoma Unveils Novel Mechanisms of Metastasis. *Cancer Res* 2017; **77**: 897-907 [PMID: [27979841](https://pubmed.ncbi.nlm.nih.gov/27979841/) DOI: [10.1158/0008-5472.CAN-16-2486](https://doi.org/10.1158/0008-5472.CAN-16-2486)]
- 17 **Wang CH**, Lee N, Lee LS. Successful treatment for solitary brain metastasis from alveolar soft part sarcoma. *J Neurooncol* 1995; **25**: 161-166 [PMID: [8543972](https://pubmed.ncbi.nlm.nih.gov/8543972/) DOI: [10.1007/Bf01057760](https://doi.org/10.1007/Bf01057760)]
- 18 **Flores RJ**, Harrison DJ, Federman NC, Furman WL, Huh WW, Broaddus EG, Okcu MF, Venkatramani R. Alveolar soft part sarcoma in children and young adults: A report of 69 cases. *Pediatr Blood Cancer* 2018; **65**: e26953 [PMID: [29350467](https://pubmed.ncbi.nlm.nih.gov/29350467/) DOI: [10.1002/pbc.26953](https://doi.org/10.1002/pbc.26953)]
- 19 **Tao X**, Hou Z, Wu Z, Hao S, Liu B. Brain metastatic alveolar soft-part sarcoma: Clinicopathological profiles, management and outcomes. *Oncol Lett* 2017; **14**: 5779-5784 [PMID: [29113207](https://pubmed.ncbi.nlm.nih.gov/29113207/) DOI: [10.3892/ol.2017.6941](https://doi.org/10.3892/ol.2017.6941)]
- 20 **Perry JR**, Bilbao JM. Metastatic alveolar soft part sarcoma presenting as a dural-based cerebral mass. *Neurosurgery* 1994; **34**: 168-170 [PMID: [8121554](https://pubmed.ncbi.nlm.nih.gov/8121554/)]
- 21 **Bindal RK**, Sawaya RE, Leavens ME, Taylor SH, Guinee VF. Sarcoma metastatic to the brain: results of surgical treatment. *Neurosurgery* 1994; **35**: 185-90; discussion 190 [PMID: [7969824](https://pubmed.ncbi.nlm.nih.gov/7969824/) DOI: [10.1227/00006123-199408000-00002](https://doi.org/10.1227/00006123-199408000-00002)]
- 22 **Fox BD**, Patel A, Suki D, Rao G. Surgical management of metastatic sarcoma to the brain. *J Neurosurg* 2009; **110**: 181-186 [PMID: [18834268](https://pubmed.ncbi.nlm.nih.gov/18834268/) DOI: [10.3171/2008.4.17505](https://doi.org/10.3171/2008.4.17505)]
- 23 **Lewin J**, Davidson S, Anderson ND, Lau BY, Kelly J, Tabori U, Salah S, Butler MO, Aung KL, Shlien A, Dickson BC, Abdul Razak AR. Response to Immune Checkpoint Inhibition in Two Patients with Alveolar Soft-Part Sarcoma. *Cancer Immunol Res* 2018; **6**: 1001-1007 [PMID: [30018044](https://pubmed.ncbi.nlm.nih.gov/30018044/) DOI: [10.1158/2326-6066.CIR-18-0037](https://doi.org/10.1158/2326-6066.CIR-18-0037)]
- 24 **Conley AP**, Trinh VA, Zobniw CM, Posey K, Martinez JD, Arrieta OG, Wang WL, Lazar AJ, Somaiah N, Roszik J, Patel SR. Positive Tumor Response to Combined Checkpoint Inhibitors in a Patient With Refractory Alveolar Soft Part Sarcoma: A Case Report. *J Glob Oncol* 2018; **4**: 1-6 [PMID: [30241159](https://pubmed.ncbi.nlm.nih.gov/30241159/) DOI: [10.1200/JGO.2017.009993](https://doi.org/10.1200/JGO.2017.009993)]
- 25 **Su H**, Yu C, Ma X, Song Q. Combined immunotherapy and targeted treatment for primary alveolar soft part sarcoma of the lung: case report and literature review. *Invest New Drugs* 2021; **39**: 1411-1418 [PMID: [33765213](https://pubmed.ncbi.nlm.nih.gov/33765213/) DOI: [10.1007/s10637-021-01105-6](https://doi.org/10.1007/s10637-021-01105-6)]
- 26 **Wen PY**, Weller M, Lee EQ, Alexander BM, Barnholtz-Sloan JS, Barthel FP, Batchelor TT, Bindra RS, Chang SM, Chiocca EA, Cloughesy TF, DeGroot JF, Galanis E, Gilbert MR, Hegi ME, Horbinski C, Huang RY, Lassman AB, Le Rhun E, Lim M, Mehta MP, Mellinghoff IK, Minniti G, Nathanson D, Platten M, Preusser M, Roth P, Sanson M, Schiff D, Short SC, Taphoorn MJB, Tonn JC, Tsang J, Verhaak RGW, von Deimling A, Wick W, Zadeh G, Reardon DA, Aldape KD, van den Bent MJ. Glioblastoma in adults: a Society for Neuro-Oncology (SNO) and European Society of Neuro-Oncology (EANO) consensus review on current management and future directions. *Neuro Oncol* 2020; **22**: 1073-1113 [PMID: [32328653](https://pubmed.ncbi.nlm.nih.gov/32328653/) DOI: [10.1093/neuonc/noaa106](https://doi.org/10.1093/neuonc/noaa106)]



Published by **Baishideng Publishing Group Inc**  
7041 Koll Center Parkway, Suite 160, Pleasanton, CA 94566, USA

**Telephone:** +1-925-3991568

**E-mail:** [bpgoffice@wjgnet.com](mailto:bpgoffice@wjgnet.com)

**Help Desk:** <https://www.f6publishing.com/helpdesk>

<https://www.wjgnet.com>

