

A case involving a choroidal metastatic mucinous abscess caused



ALL IMAGES VIDEOS

12,100 Results Any time ▾

### Metastatic Choroidal Abscess Due to *Pseudomonas aeruginosa* ...

<https://www.researchgate.net/publication/14104385...>

Purpose: The purpose of this article was to report a case of *Pseudomonas aeruginosa*-related endophthalmitis associated with a choroidal abscess in an immunocompetent patient, with no history of ...

### (PDF) Metastatic choroidal abscess and choroidal ...

<https://www.researchgate.net/publication/7987139...>

cases of metastatic choroidal abscess progress to ... and occasionally *Pseudomonas aeruginosa* [3], ... A choroidal abscess, caused by haematogenous spread of *N. asteroides*, may respond to ...

#### PEOPLE ALSO ASK

Who is the patient with the mucinous neoplasm? ▾

What kind of disease is low grade mucinous? ▾

How is mucinous neoplasm of the appendix treated? ▾

Feedback

### *Pseudomonas aeruginosa* choroidal abscess in a patient with ...

<https://www.researchgate.net/publication/6151120...>

To report a case of *Pseudomonas aeruginosa* endophthalmitis with choroidal abscess formation in a patient with bronchiectasis. Case report. A 75-year-old gentleman with bronchiectasis and P ...

ALL

IMAGES

VIDEOS

12,100 Results

Any time ▼

### Rare Case of Iliopsoas Abscess Secondary to Mucinous ...

<https://pubmed.ncbi.nlm.nih.gov/29854689>

Culture reports showed a polymicrobial infection with viridans group Streptococci and *Pseudomonas aeruginosa*. The abscess was re-explored and biopsy of the opening was taken. Histopathology of the tissue sample revealed metastatic cells of a mucin-secreting adenocarcinoma that had infiltrated the psoas muscle with a secondary pyogenic abscess.

Author: Aditya Menon, Vikas M Agashe, Mithun ... Publish Year: 2018

### Pseudomonas aeruginosa choroidal abscess in a patient with ...

<https://link.springer.com/article/10.1007/s10792-007-9126-x> ▼

Aug 09, 2007 · Purpose: To report a case of *Pseudomonas aeruginosa* endophthalmitis with choroidal abscess formation in a patient with bronchiectasis. Methods: Case report. Results: A 75-year-old gentleman with bronchiectasis and *P. aeruginosa* pneumonia developed painless loss of right eye vision. The patient had previously undergone bronchoscopy to exclude pulmonary neoplasm.

Cited by: 4

Author: Kenneth K. W. Li, Kenneth K. W. Li, Emily W....

Publish Year: 2008

### Rare Case of Iliopsoas Abscess Secondary to Mucinous ...

<https://europepmc.org/article/MED/29854689> ▼

Jan 01, 2018 · Rare Case of Iliopsoas Abscess Secondary to Mucinous Adenocarcinoma of the Colon: A Case Report. ... Culture reports showed a polymicrobial infection with viridans group Streptococci and *Pseudomonas aeruginosa*. The abscess was re-explored and biopsy of the opening was taken. Histopathology of the tissue sample revealed metastatic cells of a ...

Author: Aditya Menon, Vikas M Agashe, Mithun ... Publish Year: 2018

Estimated Reading Time: 8 mins

### Clinical Pathology of Bartholin's Glands: A Review of the ...

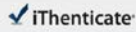
<https://www.ncbi.nlm.nih.gov/pmc/articles/PMC4483306>

May 20, 2015 · The cause of these infections is associated with bacterial cultures, though other complications may cause Bartholin's cyst, abscess or malignancy. Bartholin's gland neoplasm may correlate to the individual's blood type antigen as studies have revealed diagnosis of Bartholin's carcinoma in patients with rare blood types [ 1 ].

24 Jul 2021 00:22PM

2640 words • 0 matches • 0 sources

FAQ

 iThenticate

68482\_Auto\_Edited - IT check.docx

Quoted Excluded  
Bibliography Excluded  
0%  
0/2640 words

Name of Journal: *World Journal of Clinical Cases*

Manuscript NO: 68482

Manuscript Type: CASE REPORT

A case involving a choroidal metastatic mucinous abscess caused by *Pseudomonas aeruginosa*

a choroidal metastatic mucinous abscess

Zhao Li, Wen Gao, YM Tian, Yun Xiao

Match Overview

There are no matching sources for this report.

PAGE: 1 OF 10

Text Only Report

国内版

国际版

Choroidal metastatic mucinous abscess caused by Pseudomonas a



ALL

IMAGES

VIDEOS

12,100 Results

Any time ▾

### Metastatic Choroidal Abscess Due to Pseudomonas ...

<https://www.researchgate.net/publication/14104385...>

We describe two patients with cystic. fibrosis and choroidal abscesses due to. *P. aeruginosa*; bacteremic. spread of the organism from a distant source was presumed to. have occurred in both cases ...

Estimated Reading Time: 4 mins

### Pseudomonas aeruginosa choroidal abscess in a patient with ...

<https://link.springer.com/article/10.1007/s10792-007-9126-x> ▾

Aug 09, 2007 · Purpose: To report a case of *Pseudomonas aeruginosa* endophthalmitis with choroidal abscess formation in a patient with bronchiectasis. Methods: Case report. Results: A 75-year-old gentleman with bronchiectasis and *P. aeruginosa* pneumonia developed painless loss of right eye vision. The patient had previously undergone bronchoscopy to exclude pulmonary neoplasm.

Cited by: 4

Author: Kenneth K. W. Li, Kenneth K. W. Li, Emil...

Publish Year: 2008

### Pseudomonas aeruginosa choroidal abscess in a patient with ...

<https://www.researchgate.net/publication/6151120...>

To report a case of *Pseudomonas aeruginosa* endophthalmitis with choroidal abscess formation in a patient with bronchiectasis. Case report. A 75-year-old gentleman with bronchiectasis and *P...*

### Rare Case of Iliopsoas Abscess Secondary to Mucinous ...

<https://pubmed.ncbi.nlm.nih.gov/29854689>

Culture reports showed a polymicrobial infection with viridans group Streptococci and *Pseudomonas aeruginosa*. The abscess was re-explored and biopsy of the opening was taken. Histopathology of the tissue sample revealed metastatic cells of a mucin-secreting adenocarcinoma that had infiltrated the psoas muscle with a secondary pyogenic abscess.

Author: Aditya Menon, Vikas M Agashe, Mith...

Publish Year: 2018

### Rare Case of Iliopsoas Abscess Secondary to Mucinous ...

<https://europepmc.org/article/MED/29854689> ▾

Jan 01, 2018 · Rare Case of Iliopsoas Abscess Secondary to Mucinous Adenocarcinoma of the Colon: A Case Report. ... Culture reports showed a polymicrobial infection with viridans group Streptococci and