

ALL IMAGES VIDEOS

40,800 Results

Any time ▾

[PDF] Case report Life threatening hyperkalemia following ...<https://core.ac.uk/download/pdf/81800538.pdf>

Case report Open Access Life threatening hyperkalemia following cocaine ingestion: a case report Faisal Siddiqui1*, Roger Slater1 and Sara Ashraf2 Addresses: 1Department of Anaesthetics, Central Manchester & Manchester Childrens University Hospitals NHS Trust, Oxford Road, Manchester, M13 9WL, UK

(PDF) Life threatening hyperkalemia following cocaine ...https://www.academia.edu/8851624/Life_threatening... ▾

Open Access Case report Life threatening hyperkalemia following cocaine ingestion: a case report Faisal Siddiqui1*, Roger Slater1 and Sara Ashraf2 Addresses: 1Department of Anaesthetics, Central Manchester & Manchester Childrens University Hospitals NHS Trust, Oxford Road, Manchester, M13 9WL, UK 2 Department of Emergency Medicine, University Hospital of South Manchester, Southmoor Road ...

Life threatening hyperkalemia following cocaine ingestion ...<https://link.springer.com/article/10.4076/1757-1626-2-7355> ▾

Abstract. We present a case of life-threatening hyperkalemia after recreational cocaine ingestion. Acute cocaine-induced rhabdomyolysis led to hyperkalemia, cardiac arrhythmias and cardiogenic shock resulting in multi-organ failure.

Cited by: 2

Author: Faisal Siddiqui, Roger Slater, Sara Ashraf

Publish Year: 2009

Life-Threatening Hyperkalemia: A Complication of ...<https://journals.lww.com/anesthesia-analgesia/Full...>

The risk of hyperkalemia has raised concerns about the safety of spironolactone therapy for heart failure. In a recent report, 10% of patients treated with spironolactone in combination with angiotensin-converting

Fatal Dysrhythmia Following Potassium Replacement for ...

<https://westjem.com/case-report/fatal-dysrhythmia...> ▾

Introduction

Case Report

Discussion

Conclusion

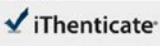
References

Hypokalemic paralysis is a rare cause of muscle weakness and cardiac arrhythmias that primarily affects male patients of Asian descent. Because it is rare in non-Asians¹ it can be misdiagnosed. **Thyrotoxic periodic paralysis (TPP)** is caused by a sudden shift of potassium into cells, leading to hypokalemia and muscle weakness and can lead to near-fatal or fatal arrhythmias. Immediate therapy with potassium chloride supplementation may foster a rapid recovery from weakness and prevent arrhythmias but risk...

02-Jul-2021 11:30AM

1343 words • 2 matches • 2 sources

FAQ

 iThenticate®

68610_Auto_Edited.docx

Quotes Excluded
Bibliography Excluded
2%

Name of Journal: *World Journal of Cardiology*

Manuscript NO: 68610

Manuscript Type: CASE REPORT

Sliding with the sines: A case report of fatal hyperkalemia

Kyaw Khaing Soe, Arnold Hoo Seto

Abstract

BACKGROUND

Classic electrocardiographic manifestations of hyperkalemia starting with peaked symmetrical T-waves are widely recognized in daily clinical practice but little evidence is documented how quickly it can evolve in real-time.

Match Overview

1


Internet 13 words
created on 04-May-2020
www.eigmet.com

1%


2


Crossref 10 words
"Abstracts from the 36th Annual Meeting of the Society of G...
neral Internal Medicine", Journal of General Internal Medicine,

1%



PAGE 1 OF 1





Text-Only Report

国内版 国际版

Sliding with the sines – fatal hyperkalemia: A case report



ALL IMAGES VIDEOS

12,700 Results Any time ▾

Profound hyperkalemia and the electrocardiogram: lack of ...

<https://library.emro.who.int/imemr/profound...>

Profound hyperkalemia and the electrocardiogram: lack of correlation: a case report; Profound hyperkalemia and the electrocardiogram: lack of correlation: a case report. Authors . Dowod Tarek Abdel Hamed Mostafa Ali, Jaffer Ismail ... Broad Subjects: Hyperkalemia , Etiology , Diagnosis , Therapy Citation: Tarek Abdel Hamed ...

[PDF] A Case Report of Fatal Outcome of Cerebral Venous ...

<https://www.semanticscholar.org/paper/A-Case...>

Here, we report a case of massive cerebral venous sinus thrombosis (CVST) with intracerebral hemorrhage in a young woman in her first trimester pregnancy, with underlying antithrombin III deficiency that leads to a fatal maternal outcome. Antithrombin III deficiency is a rare hereditary thrombophilia. It is associated with 2-4 fold higher risks ...

[PDF] Fatal Rebleeding from a Dural Arteriovenous ...

<https://www.cambridge.org/core/services/aop...>

Fatal Rebleeding from a Dural Arteriovenous Malformation of the Posterior Fossa: case report with pathological examination /. Max Findlay and Bruce W. Mielke Abstract: A seventy-year-old woman suffered a fatal cerebellar rehemorrhage from a large venous aneurysm associated with a dural arteriovenous malformation (AVM) of the posterior fossa ...

(PDF) Ecstasy-Induced Malignant Hyperthermia with Fatal ...

https://www.researchgate.net/publication/350690836_Ecstasy-Induced_Malignant...

PDF | 3,4-methylenedioxymetamphetamine (MDMA), also known as "ecstasy", "tulips", or "Molly", is an increasingly used "recreational drug" particularly... | Find, read and cite all ...

Pyopericardium – A fatal presentation: A case report ...

https://www.researchgate.net/publication/321079596_Pyopericardium_-_A_fatal...

Request PDF | On Jan 1, 2017, K.N.J.Prakash Raju and others published Pyopericardium – A fatal presentation: A case report | Find, read and cite all the research you need on ResearchGate

Ferrous sulfate poisoning; report of a fatal case ...