

World Journal of *Clinical Cases*

World J Clin Cases 2022 January 14; 10(2): 397-752



Contents

Thrice Monthly Volume 10 Number 2 January 14, 2022

EDITORIAL

- 397 New trends in treatment of muscle fatigue throughout rehabilitation of elderlies with motor neuron diseases
Mohamed A

MINIREVIEWS

- 401 What emotion dimensions can affect working memory performance in healthy adults? A review
Hou TY, Cai WP
- 412 Quadrilateral plate fractures of the acetabulum: Classification, approach, implant therapy and related research progress
Zhou XF, Gu SC, Zhu WB, Yang JZ, Xu L, Fang SY

ORIGINAL ARTICLE

Case Control Study

- 426 Methylprednisolone accelerate chest computed tomography absorption in COVID-19: A three-centered retrospective case control study from China
Lin L, Xue D, Chen JH, Wei QY, Huang ZH

Retrospective Study

- 437 Analysis of photostimulable phosphor image plate artifacts and their prevalence
Elkhateeb SM, Aloyouny AY, Omer MMS, Mansour SM
- 448 N6-methyladenine-modified DNA was decreased in Alzheimer's disease patients
Lv S, Zhou X, Li YM, Yang T, Zhang SJ, Wang Y, Jia SH, Peng DT
- 458 Inflammation-related indicators to distinguish between gastric stromal tumors and leiomyomas: A retrospective study
Zhai YH, Zheng Z, Deng W, Yin J, Bai ZG, Liu XY, Zhang J, Zhang ZT
- 469 Relationship between Ki-67 and CD44 expression and microvascular formation in gastric stromal tumor tissues
Ma B, Huang XT, Zou GJ, Hou WY, Du XH
- 477 Modified surgical method of supra- and infratentorial epidural hematoma and the related anatomical study of the squamous part of the occipital bone
Li RC, Guo SW, Liang C
- 485 Combined molybdenum target X-ray and magnetic resonance imaging examinations improve breast cancer diagnostic efficacy
Gu WQ, Cai SM, Liu WD, Zhang Q, Shi Y, Du LJ

- 492 Value of thyroglobulin combined with ultrasound-guided fine-needle aspiration cytology for diagnosis of lymph node metastasis of thyroid carcinoma

Zhang LY, Chen Y, Ao YZ

- 502 Locking compression plate + T-type steel plate for postoperative weight bearing and functional recovery in complex tibial plateau fractures

Li HF, Yu T, Zhu XF, Wang H, Zhang YQ

- 511 Effect of Mirena placement on reproductive hormone levels at different time intervals after artificial abortion

Jin XX, Sun L, Lai XL, Li J, Liang ML, Ma X

- 518 Diagnostic value of artificial intelligence automatic detection systems for breast BI-RADS 4 nodules

Lyu SY, Zhang Y, Zhang MW, Zhang BS, Gao LB, Bai LT, Wang J

Clinical Trials Study

- 528 Analysis of 20 patients with laparoscopic extended right colectomy

Zheng HD, Xu JH, Liu YR, Sun YF

Observational Study

- 538 Knowledge, attitude, practice and factors that influence the awareness of college students with regards to breast cancer

Zhang QN, Lu HX

- 547 Diagnosing early scar pregnancy in the lower uterine segment after cesarean section by intracavitary ultrasound

Cheng XL, Cao XY, Wang XQ, Lin HL, Fang JC, Wang L

- 554 Impact of failure mode and effects analysis-based emergency management on the effectiveness of craniocerebral injury treatment

Shao XL, Wang YZ, Chen XH, Ding WJ

- 563 Predictive value of alarm symptoms in Rome IV irritable bowel syndrome: A multicenter cross-sectional study

Yang Q, Wei ZC, Liu N, Pan YL, Jiang XS, Tantai XX, Yang Q, Yang J, Wang JJ, Shang L, Lin Q, Xiao CL, Wang JH

Prospective Study

- 576 5-min mindfulness audio induction alleviates psychological distress and sleep disorders in patients with COVID-19

Li J, Zhang YY, Cong XY, Ren SR, Tu XM, Wu JF

META-ANALYSIS

- 585 Efficacy and safety of argatroban in treatment of acute ischemic stroke: A meta-analysis

Ly B, Guo FF, Lin JC, Jing F

SCIENTOMETRICS

- 594 Biologic therapy for Crohn's disease over the last 3 decades
Shen JL, Zhou Z, Cao JS, Zhang B, Hu JH, Li JY, Liu XM, Juengpanich S, Li MS, Feng X

CASE REPORT

- 607 Novel compound heterozygous GPR56 gene mutation in a twin with lissencephaly: A case report
Lin WX, Chai YY, Huang TT, Zhang X, Zheng G, Zhang G, Peng F, Huang YJ
- 618 Patients with SERPINC1 rs2227589 polymorphism found to have multiple cerebral venous sinus thromboses despite a normal antithrombin level: A case report
Liao F, Zeng JL, Pan JG, Ma J, Zhang ZJ, Lin ZJ, Lin LF, Chen YS, Ma XT
- 625 Successful management of delirium with dexmedetomidine in a patient with haloperidol-induced neuroleptic malignant syndrome: A case report
Yang CJ, Chiu CT, Yeh YC, Chao A
- 631 Malignant solitary fibrous tumor in the central nervous system treated with surgery, radiotherapy and anlotinib: A case report
Zhang DY, Su L, Wang YW
- 643 Anesthesia and perioperative management for giant adrenal Ewing's sarcoma with inferior vena cava and right atrium tumor thrombus: A case report
Wang JL, Xu CY, Geng CJ, Liu L, Zhang MZ, Wang H, Xiao RT, Liu L, Zhang G, Ni C, Guo XY
- 656 Full-endoscopic spine surgery treatment of lumbar foraminal stenosis after osteoporotic vertebral compression fractures: A case report
Zhao QL, Hou KP, Wu ZX, Xiao L, Xu HG
- 663 Ethambutol-induced optic neuropathy with rare bilateral asymmetry onset: A case report
Sheng WY, Wu SQ, Su LY, Zhu LW
- 671 Vitrectomy with residual internal limiting membrane covering and autologous blood for a secondary macular hole: A case report
Ying HF, Wu SQ, Hu WP, Ni LY, Zhang ZL, Xu YG
- 677 Intervertebral bridging ossification after kyphoplasty in a Parkinson's patient with Kummell's disease: A case report
Li J, Liu Y, Peng L, Liu J, Cao ZD, He M
- 685 Synovial chondromatosis of the hip joint in a 6 year-old child: A case report
Yi RB, Gong HL, Arthur DT, Wen J, Xiao S, Tang ZW, Xiang F, Wang KJ, Song ZQ
- 691 Orthodontic retreatment of an adult woman with mandibular backward positioning and temporomandibular joint disorder: A case report
Yu LY, Xia K, Sun WT, Huang XQ, Chi JY, Wang LJ, Zhao ZH, Liu J

- 703** Autosomal recessive spinocerebellar ataxia type 4 with a *VPS13D* mutation: A case report
Huang X, Fan DS
- 709** Primary adrenal diffuse large B-cell lymphoma with normal adrenal cortex function: A case report
Fan ZN, Shi HJ, Xiong BB, Zhang JS, Wang HF, Wang JS
- 717** Varicella-zoster virus-associated meningitis, encephalitis, and myelitis with sporadic skin blisters: A case report
Takami K, Kenzaka T, Kumabe A, Fukuzawa M, Eto Y, Nakata S, Shinohara K, Endo K
- 725** Tension pneumocephalus following endoscopic resection of a mediastinal thoracic spinal tumor: A case report
Chang CY, Hung CC, Liu JM, Chiu CD
- 733** Accelerated Infliximab Induction for Severe Lower Gastrointestinal Bleeding in a Young Patient with Crohn's Disease: A Case Report
Zeng J, Shen F, Fan JG, Ge WS
- 741** Occupational fibrotic hypersensitivity pneumonia in a halogen dishes manufacturer: A case report
Wang M, Fang HH, Jiang ZF, Ye W, Liu RY
- 747** Using a fretsaw in treating chronic penial incarceration: A case report
Zhao Y, Xue XQ, Huang HF, Xie Y, Ji ZG, Fan XR

ABOUT COVER

Associate Editor of *World Journal of Clinical Cases*, Bruno Ramos Chrcanovic, DDS, MSc, PhD, Associate Professor, Department of Prosthodontics, Malmö University, Malmö 241 21, Sweden. bruno.chrcanovic@mau.se

AIMS AND SCOPE

The primary aim of *World Journal of Clinical Cases* (WJCC, *World J Clin Cases*) is to provide scholars and readers from various fields of clinical medicine with a platform to publish high-quality clinical research articles and communicate their research findings online.

WJCC mainly publishes articles reporting research results and findings obtained in the field of clinical medicine and covering a wide range of topics, including case control studies, retrospective cohort studies, retrospective studies, clinical trials studies, observational studies, prospective studies, randomized controlled trials, randomized clinical trials, systematic reviews, meta-analysis, and case reports.

INDEXING/ABSTRACTING

The WJCC is now indexed in Science Citation Index Expanded (also known as SciSearch®), Journal Citation Reports/Science Edition, Scopus, PubMed, and PubMed Central. The 2021 Edition of Journal Citation Reports® cites the 2020 impact factor (IF) for WJCC as 1.337; IF without journal self cites: 1.301; 5-year IF: 1.742; Journal Citation Indicator: 0.33; Ranking: 119 among 169 journals in medicine, general and internal; and Quartile category: Q3. The WJCC's CiteScore for 2020 is 0.8 and Scopus CiteScore rank 2020: General Medicine is 493/793.

RESPONSIBLE EDITORS FOR THIS ISSUE

Production Editor: *Jia-Hui Li*; Production Department Director: *Xu Guo*; Editorial Office Director: *Jim-Lai Wang*.

NAME OF JOURNAL

World Journal of Clinical Cases

ISSN

ISSN 2307-8960 (online)

LAUNCH DATE

April 16, 2013

FREQUENCY

Thrice Monthly

EDITORS-IN-CHIEF

Bao-Gan Peng, Jerzy Tadeusz Chudek, George Kontogeorgos, Maurizio Serati, Ja Hyeon Ku

EDITORIAL BOARD MEMBERS

<https://www.wjgnet.com/2307-8960/editorialboard.htm>

PUBLICATION DATE

January 14, 2022

COPYRIGHT

© 2022 Baishideng Publishing Group Inc

INSTRUCTIONS TO AUTHORS

<https://www.wjgnet.com/bpg/gerinfo/204>

GUIDELINES FOR ETHICS DOCUMENTS

<https://www.wjgnet.com/bpg/GerInfo/287>

GUIDELINES FOR NON-NATIVE SPEAKERS OF ENGLISH

<https://www.wjgnet.com/bpg/gerinfo/240>

PUBLICATION ETHICS

<https://www.wjgnet.com/bpg/GerInfo/288>

PUBLICATION MISCONDUCT

<https://www.wjgnet.com/bpg/gerinfo/208>

ARTICLE PROCESSING CHARGE

<https://www.wjgnet.com/bpg/gerinfo/242>

STEPS FOR SUBMITTING MANUSCRIPTS

<https://www.wjgnet.com/bpg/GerInfo/239>

ONLINE SUBMISSION

<https://www.f6publishing.com>

Clinical Trials Study

Analysis of 20 patients with laparoscopic extended right colectomy

Hui-Da Zheng, Jian-Hua Xu, Yu-Rong Liu, Ya-Feng Sun

ORCID number: Hui-Da Zheng 0000-0002-4986-8770; Jian-Hua Xu 0000-0001-5147-292X; Yu-Rong Liu 0000-0001-7280-1745; Ya-Feng Sun 0000-0002-0454-123X.

Author contributions: Zheng HD, Xu JH contributed equally to this study and should be regarded as co-first authors; Zheng HD and Xu JH designed the study, collected the data and performed the analysis; Zheng HD, Sun YF and Liu YR wrote the manuscript; Sun YF and Xu JH provided clinical advice, reviewed the manuscript and gave final approval of the version of the article to be published.

Institutional review board

statement: The Ethics Committee of The Second Affiliated Hospital of Fujian Medical University, No. 2021-258.

Clinical trial registration statement:

The data used in the study have been registered at www.Clinicaltrials.gov, No. NCT03936530.

Informed consent statement: All study participants or their legal guardians provided written informed consent prior to study enrollment.

Conflict-of-interest statement: The authors declare that they have no conflicts of interest.

Hui-Da Zheng, Jian-Hua Xu, Yu-Rong Liu, Ya-Feng Sun, Department of Gastrointestinal Surgery, The Second Affiliated Hospital of Fujian Medical University, Quanzhou 362000, Fujian Province, China

Corresponding author: Ya-Feng Sun, MD, PhD, Associate Chief Physician, Surgeon, Surgical Oncologist, Department of Gastrointestinal Surgery, The Second Affiliated Hospital of Fujian Medical University, No. 950 Donghai Street, Fengze District, Quanzhou 362000, Fujian Province, China. syf791006@163.com

Abstract

BACKGROUND

Currently, the standard surgical procedure for right colon cancer is complete mesocolic excision. Whether preventive extended lymph node dissection for colon cancer located in the hepatic flexure or right transverse colon should be performed remains controversial because the safety and effectiveness of the operation have not been proven, and infrapyloric lymph nodes (No. 206) and lymph nodes in the greater curvature of the stomach (No. 204) have not been strictly defined and distinguished as surgical indicators in previous studies.

AIM

To analyze the metastatic status of infrapyloric lymph nodes and lymph nodes of the greater curvature of the stomach and perioperative complications and systematically evaluate the feasibility and safety of laparoscopic extended right colectomy using prospective data collected retrospectively.

METHODS

The study was a clinical study. Twenty patients with colon cancer who underwent laparoscopic extended right colon resection in our hospital from June 2020 to May 2021 were included.

RESULTS

Among the patients who underwent extended right colon resection, there were no intraoperative complications or conversion to laparotomy; 2 patients had gastrocolic ligament lymph node metastasis, and 5 patients had postoperative complications. The patients with postoperative complications received conservative treatment.

CONCLUSION

Laparoscopic extended right colon resection is safe. However, malignant tumors located in the liver flexure or the right-side transverse colon are more likely to

Data sharing statement: No additional data are available.

CONSORT 2010 statement: The authors read the CONSORT 2010 statement, and the manuscript was prepared and revised according to the CONSORT 2010 statement.

Supported by the Malignant Tumor Clinical Medicine Research Center, Quanzhou City, Fujian Province, China, No. 2020N090s.

Country/Territory of origin: China

Specialty type: Oncology

Provenance and peer review: Unsolicited article; Externally peer reviewed.

Peer-review model: Single blind

Peer-review report's scientific quality classification

Grade A (Excellent): 0
Grade B (Very good): 0
Grade C (Good): C
Grade D (Fair): 0
Grade E (Poor): 0

Open-Access: This article is an open-access article that was selected by an in-house editor and fully peer-reviewed by external reviewers. It is distributed in accordance with the Creative Commons Attribution NonCommercial (CC BY-NC 4.0) license, which permits others to distribute, remix, adapt, build upon this work non-commercially, and license their derivative works on different terms, provided the original work is properly cited and the use is non-commercial. See: <http://creativecommons.org/licenses/by-nc/4.0/>

Received: June 22, 2021

Peer-review started: June 22, 2021

First decision: September 28, 2021

Revised: September 29, 2021

Accepted: December 10, 2021

Article in press: December 10, 2021

Published online: January 14, 2022

P-Reviewer: Sachdeva S

S-Editor: Wu YXJ

L-Editor: A

P-Editor: Wu YXJ

metastasize to the gastrocolic ligament lymph nodes, and notably, the incidence of gastroparesis was high. The number of patients was small, and the follow-up time was short. It is necessary to further increase the sample size to evaluate the No. 204 and No. 206 lymph node metastasis rates and the long-term survival impact.

Key Words: Laparoscopic extended right colectomy; Infrapyloric lymph nodes; Greater curvature of stomach lymph nodes; Gastroepiploic lymph nodes; Gastroparesis

©The Author(s) 2022. Published by Baishideng Publishing Group Inc. All rights reserved.

Core Tip: Whether laparoscopic extended right colectomy should be performed in patients with malignant tumors located in the hepatic flexure and right-side transverse colon remains controversial mainly because of the lack of an understanding of lymph node metastasis in the gastrocolic ligament and doubts regarding the safety of the operation. No prospective studies assessed the possibility and safety of laparoscopic extended right colon resection. Although the sample size in this article was small, the cases were strictly screened and had a certain degree of representativeness, which can provide some insight to surgeons.

Citation: Zheng HD, Xu JH, Liu YR, Sun YF. Analysis of 20 patients with laparoscopic extended right colectomy. *World J Clin Cases* 2022; 10(2): 528-537

URL: <https://www.wjgnet.com/2307-8960/full/v10/i2/528.htm>

DOI: <https://dx.doi.org/10.12998/wjcc.v10.i2.528>

INTRODUCTION

Colorectal cancer (CRC) is the second leading cause of cancer-related death[1]. Studies have shown that the survival rate of patients with right colon cancer is significantly lower than that of patients with colorectal malignancies in other locations[2]. Most colorectal surgeons consider complete mesocolic excision (CME) the standard surgery for right-side colon cancer, and CME can improve the long-term survival rate of patients. The principles are as follows: (1) Accurate dissection of the Toldt space and preservation of the colonic membrane; (2) Ligation of the root vessels; and (3) Extended lymph node dissection in tumors located in the liver curve and right half of the transverse colon[3,4]. So-called extended lymph node dissection refers to the removal of the infrapyloric lymph nodes and greater curvature lymph nodes that are 10 cm to 15 cm from the tumor[5]. In 1995, Toyota *et al*[6] found that 5 cases (2%) of colonic hepatic flexure cancer had infrapyloric lymph node metastasis and advocated that if lymph node metastasis is suspected, the infrapyloric lymph node should be removed. Feng *et al*[7] showed that the infrapyloric lymph node metastasis rate in colonic hepatic flexure cancer was 9.1%, and the greater gastric curvature lymph node metastasis rate was 7.1%. Near colonic hepatic flexure cancer has the possibility of metastasis to the infrapyloric and greater curvature lymph nodes. Few studies concerning the metastasis of the gastrocolic ligament (infrapyloric lymph nodes and greater curvature lymph nodes) in liver flexure and right-side transverse colon adenocarcinoma have been conducted, and these studies were retrospective with small sample sizes. Most extended operations did not sweep the infrapyloric lymph nodes, resulting in great heterogeneity at baseline. We aimed to analyze the metastasis of gastrocolic ligament lymph nodes and perioperative complications to evaluate the feasibility and safety of laparoscopic extended right colectomy.

MATERIALS AND METHODS

Patients

This prospective study included 20 patients who underwent laparoscopic extended right colectomy at the Gastrointestinal Surgery Department of The Second Affiliated Hospital of Fujian Medical University from June 2020 to May 2021. The study was



approved by the Ethics Committee of The Second Affiliated Hospital of Fujian Medical University.

The inclusion criteria were as follows: (1) Patients aged ≥ 18 years or ≤ 75 years; (2) An ASA score of I-III; (3) Colon adenocarcinoma or high-grade intraepithelial neoplasia pathologically confirmed by preoperative colonoscopy biopsy; (4) A tumor located on the near liver flexure of the colon or the right 1/3 of the transverse colon; (5) The surgical method of extended right hemicolectomy (CME); (6) A preoperative staging assessment using cT2-4aN0M0 or cTanyN+M0; and (7) Elective surgery. The exclusion criteria were as follows: (1) A number of lesions greater than 2; (2) Preoperative staging of cT1N0 or cT4bNany; (3) Distant metastasis or tumor invading the surrounding tissues; (4) History of malignant tumors or history of major abdominal surgery; and (5) Emergency surgery. All operations were performed by the same surgeon, who performed over 3000 Laparoscopic colorectal surgeries.

Surgical techniques

All operations were performed by the same colorectal surgeon, who has experience with 3000 cases of gastrointestinal tumor surgery. The intestinal segment was removed on the basis of CME[8]. We strictly defined the scope of lymph node dissection in No. 204 and No. 206 as follows: No. 206 was defined as lymph nodes in the area surrounding the root of the right gastroepiploic artery (up to its first branch and down to the junction of the right gastroepiploic vein and superior anterior pancreaticoduodenal vein), No. 204 was defined as lymph nodes distributed along the greater curvature of the stomach distal to the first branch of the right gastroepiploic artery. Each patient was placed in the supine position. The five-hole method was used (Figure 1A). (1) The surgical approach was the caudal ventral approach (Figure 1B); (2) The D3 lymph node tissue dissection method was as follows: centered on the left edge of the superior mesenteric artery (SMA) and separated toward the pancreatic neck; the SMA branch was first cut, and then, the superior mesenteric vein (SMV) branch was cut. This approach does not easily damage the SMA branch across the SMV or cause bleeding. Notably, the middle colonic artery had to be ligated and cut at the root (Figure 1C); (3) Radical resection of expanded right colon cancer requires sweeping the lymphatic tissue on the gastro-omental arch 10 cm from the cancer, including infrapyloric lymph nodes (No. 206) and greater curvature lymph nodes (No. 204) (Figure 1D). Care should be taken when separating the infrapyloric blood vessels, which easily causes bleeding and the rapid formation of hematomas, and it can be difficult to find the bleeding points; (4) Intestinal resection and anastomosis were performed as follows: we used an auxiliary incision to remove the intestine, cut along the precut line to remove the specimen, and performed an end-to-side anastomosis of the distal ileum and the distal transverse colon (Figure 1E); and (5) The skin was sutured.

Pathologic procedures

After the specimen was obtained, an attending physician with rich clinical experience cut the lymph node tissue according to the distribution of the blood vessels, including the lymph nodes at the beginning of the ileocolonic artery, right colon artery, and middle colon artery, and separated the No. 206 and No. 204 lymph nodes for the pathological examination.

Postoperative complications

The complications were described in accordance with the Clavien-Dindo classification [9]. The postoperative complications of the patients were recorded in detail.

RESULTS

The study lasted 11 mo and included 20 patients who strictly met the inclusion criteria. The entire operation process was performed smoothly in 20 patients, and there were no intraoperative conversions to laparotomy or serious intraoperative complications. The median age was 63.5 years (range, 26-75 years), and only one patient was younger than 40 years. The median intraoperative blood loss was 50 mL (range, 20-300 mL). The median operative time in our study was 150 min (range, 170-389 min). The median postoperative anal exhaust time was 3 d (range, 2-6 d). The median time to eat semiliquid food after surgery was 5 d (range, 4-7 d). The median length of hospital stay after surgery was 11.5 d (range, 8-24 d). One case (5%), 16 cases (80%), 3 cases (15%), 9 cases (45%), 7 cases (35%), and 4 cases (20%) had postoperative pathological

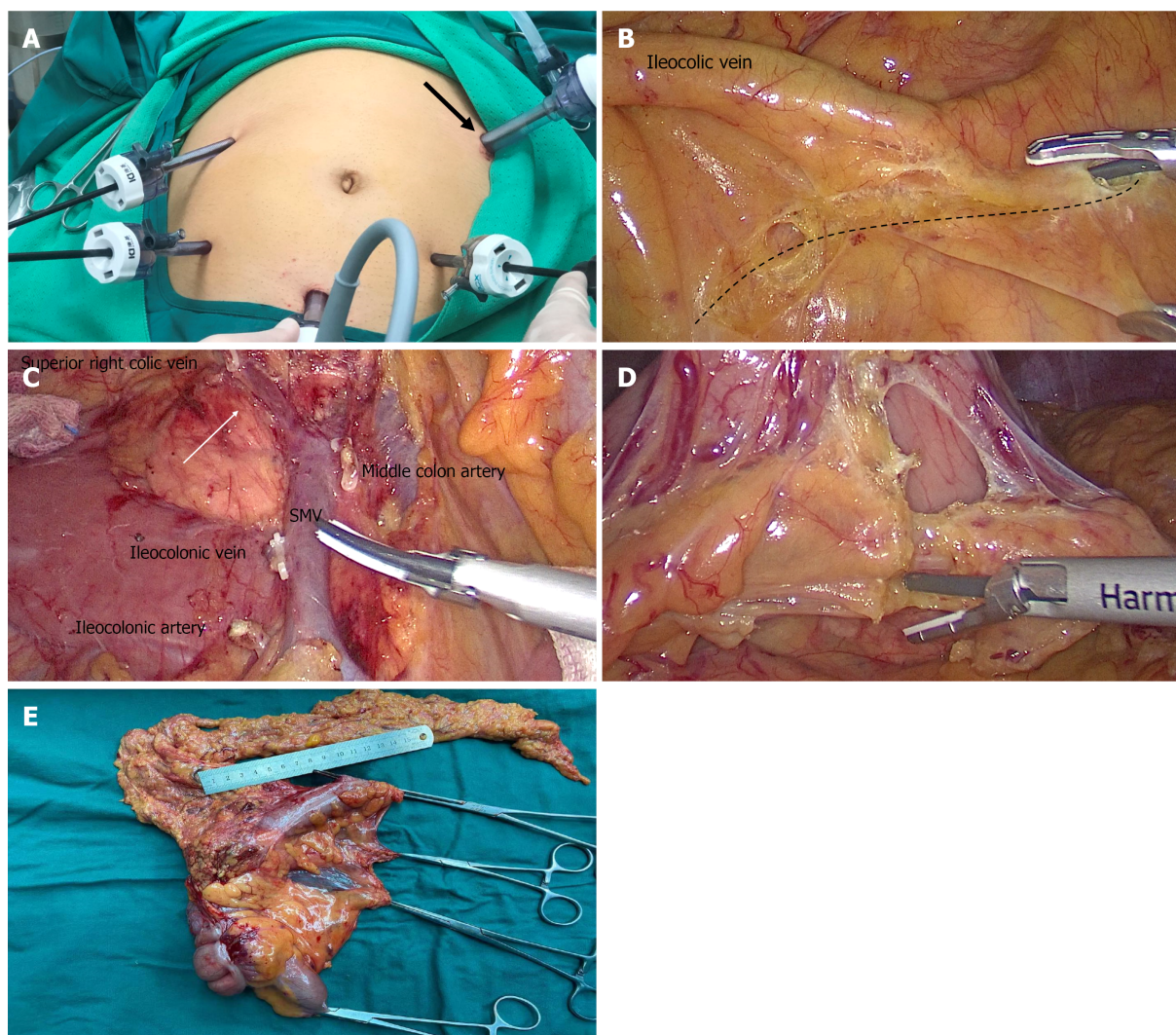


Figure 1 Surgery process photos. A: Five-hole method and main operation hole (black arrow); B: Caudal ventral approach in which the assistant lifts the ileocolonic vascular pedicle, and an ultrasonic knife is inserted obliquely in the direction of the superior mesenteric vein (SMV) (dotted line) into the small intestine ascending colon space; C: SMV with broken branches and Henle trunk (white arrow); D: Dissection of gastrocolic ligament lymph nodes; (E) Postoperative specimens.

stages T2, T3, T4, N0, N1, and N2, respectively. The detailed information is shown in [Table 1](#).

In total, 5 (25%) patients had postoperative complications, including 2 cases of delayed gastric emptying (gastroparesis), 2 cases of intestinal obstruction, 1 case of postoperative gastrointestinal bleeding, 1 case of wound infection, 1 case of pancreatic fistula, and 1 case of chylous ascites. One patient had three complications (wound infection, intestinal obstruction, and pancreatic fistula). All patients were cured by conservative treatment. The details are shown in [Table 2](#).

The number of lymph nodes retrieved and metastases found are shown in [Table 2](#). In total, 11 (55%) patients had lymph node metastasis, and 8 (40%) patients had apical lymph node metastases. The mean \pm SD of the number of lymph nodes dissected was 39.3 ± 10.9 nodes, and the median number of metastatic lymph nodes was 1 node (range, 0-28 nodes). The median number of No. 204 lymph nodes was 2 (range, 0-8 nodes), and the median number of No. 206 lymph nodes was 2.5 (range, 0-9 nodes); only 1 patient had lymph node metastasis of No. 206, and 1 patient had lymph node metastasis of No. 204. The details are shown in [Table 3](#).

The detailed information of the patients with No. 204 lymph node or No. 206 lymph node metastasis is shown in [Table 4](#). We found the following pattern: The patients with No. 204 lymph node or No. 206 lymph node metastasis generally had late T and N staging, and apical lymph nodes often had metastases. Moreover, cancer cells can usually be found in the vasculature or nerve tissue, affecting the survival time of patients.

Table 1 Patient demographics and pathological characteristics

Variable	n (%)
Age, median (range)	63.5 (26–75)
Sex (male)	15 (75)
BMI (> 25)	7 (35)
ASA ≤ 2	19 (95)
Tumor location	
Hepatic flexure	13 (65)
Right transverse	7 (35)
Pathology	
pT1	0 (0)
pT2	1 (5)
pT3	16 (80)
pT4	3 (15)
pN0	9 (45)
pN1	7 (35)
pN2	4 (20)
Perineural invasion	5 (25)
Vascular invasion	8 (40)
Defective mismatch repair	5 (25)
Intraoperative complications	0 (0)
Transition to open abdomen	0 (0)

CEA: Carcinoembryonic antigen; ASA: American Society of Anesthesiologists.

DISCUSSION

CME is currently recognized as a surgical method for right-side colon cancer that can improve lymph node collection and the length of surgical specimens without increasing intraoperative and postoperative complications[9]. Compared with left-side colon carcinoma and rectal carcinoma, the prognosis of right-side colon cancer is worse, which may be the result of inadequate tumor and lymph node resection, especially in the liver flexure and right transverse colon. Tumors often appear as No. 204 and No. 206 lymph node metastases if the lymph node is not cleared, which may increase the possibility of tumor recurrence and reduce the survival rate of patients with right colon cancer[2,4]. Although our study has a small sample size, the inclusion criteria are strict, and currently, similar prospective studies are lacking; thus, this study can provide a good reference for clinicians.

Laparoscopic extended right colectomy is one of the most challenging operations in colorectal surgery due to the difficulty in determining the origin of the middle colon artery because of the complex anatomy near the pancreatic neck[11]. The correct identification and cutting of the middle colon artery and careful separation of the inferior pylorus vessels are critical for the safe implementation of laparoscopic extended right hemicolectomy, representing a serious challenge for surgeons[12]. Therefore, the safety of laparoscopic extended right hemicolectomy is still controversial, but most studies suggest that the procedure is safe and feasible. Zhao *et al*[13] considered that laparoscopic extended right hemicolectomy was a technically feasible and safe surgical method and could obtain the same short-term oncological results as open surgery. In their study, 9 cases (9/220, 4.1%) were converted to open abdomen, 4 cases (4/9, 44.4%) were T4a, and two cases (2/9, 22.2%) had massive bleeding during the process of stripping the right gastrocnic artery root, which is less than 14% to 19% of the other randomized control study[14,15]. However, the above study did not clarify the lymph node metastasis incidence of No. 204 and No. 206 and only focused

Table 2 Peri- and postoperative patient outcomes

Variable	n (%)
Postoperative complication	5 (25)
Anastomotic leakage	0 (0)
Pancreatic fistula POPF grade	
Grade A	0 (0)
Grade B	1 (5)
Grade C	0 (0)
Intestinal obstruction	2 (10)
Chylous ascites	1 (5)
Incision infection	1 (5)
Gastroparesis	2 (10)
Organ infection	0 (0)
Gastrointestinal bleeding	1 (5)
Clavien-Dindo classification	
Grade I	1 (5)
Grade II	5 (25)
Grade III and above	1 (5)
Anal exhaust time, median (range) (d)	3 (2-6)
Semiliquid diet, median (range) (d)	5 (4-7)
Length of hospital stay	11.5 (8-24)

POPF: Postoperative pancreatic fistula.

Table 3 Lymph node yield and metastases

Variable	n (%)
Total LN yield, mean \pm SD	39.3 \pm 10.9
LN metastases, median (range)	1 (0-28)
No. 204 LN yield, median (range)	2 (0-8)
No. 206 LN yield, median (range)	2.5 (0-9)
Apical LN metastases	8 (40)
No. 204 LN metastases	1 (5)
No. 206 LN metastases	1 (5)

LN: Lymph node.

on a comparison of laparoscopic and open surgery.

We observed some characteristics of the postoperative complications in our study. The incidence rate of gastroparesis was 10% in the present study, which is significantly higher than that of right colectomy without clearing the lymph nodes of the gastrocolic ligament (10% *vs* 0.3%)[16]. It is generally believed that 30%-50% may cause gastroparesis in diabetic patients. However, our patients with gastroparesis had normal blood sugar[17]. We considered that the occurrence of gastroparesis was related to the patients who underwent gastrocolic lymph node dissection. Therefore, additional research is needed to determine the best surgical indications and avoid unnecessary and futile gastrocolic ligament lymph node dissection in the future. Few studies examined the causes of gastroparesis after extended right hemicolectomy. We suggest

Table 4 Characteristics of the patients with gastrocolic ligament lymph node metastasis

Patient	Patient 1	Patient 2
Age (yr)	69	61
Gender	Female	Female
BMI	30.04	20.96
Symptom	Abdominal pain	Abdominal pain
CEA (ng/mL)	33.28	25.39
ASA score	II	III
Location	R	H
Pathological type	Ulcerative	Ulcerative
Differentiation	M	m-p
T stage	T4a	T3
N stage	N2	N2
Tumor size (cm)	6.0 × 3.5	6.0 × 5.5
Mesocolic LN metastases/mesocolic LN yield (n)	5/34	28/58
Apical LN metastases/apical LN yield (n)	4/13	16/30
No. 204 LN metastases/GCLN yield (n)	1/2	0/2
No. 206 LN metastases/GCLN yield (n)	0/6	3/3
Venous invasion (n)	Yes	Yes
Perineural invasion (n)	No	Yes
Mismatch repair protein	Expression	Expression
Postoperative complications	No	No
Chemotherapy method	XELOX	XELOX
Relapse	No	Metastasis
Mortality	Alive	Death

CEA: Carcinoembryonic antigen; ASA: American Society of Anesthesiologists; CEA: Carcinoembryonic antigen; ASA: American Society of Anesthesiologists; GCLN: Gastrocolic ligament lymph node; R: Right transverse; T: Hepatic flexure; m-p: moderately differentiated-poorly differentiated; XELOX: Oxaliplatin combined with capecitabine.

that the ultrasound knife burns the stomach during the removal of the omental blood vessels, resulting in decreased gastric motility. You *et al*[18] suggested that preserving the right gastroepiploic vessels can reduce the incidence of gastroparesis; however, in this case, No. 206 lymph nodes cannot be completely cleared. According to our clinical experience, when dissociating from the arch, we should cut the blood vessels 0.5 cm away from the great curvature of the stomach when dissociating on the arch to avoid burning the stomach and causing gastroparesis. The other complications seem to be related to colectomy rather than gastrocolic ligament resection. Some authors[4] observed gastric perforation after extended right hemicolectomy, which may be related to gastrocolic ligament resection, and some patients had a dissecting thoracic aorta aneurysm, which may be due to an impaired blood supply to the main abdominal cavity. In our study, there were no intraoperative complications or conversion to laparotomy. The reasons may be that this study had a small sample because the inclusion criteria were strict and the operation was performed by the same gastrointestinal oncologist with extensive laparoscopic experience. In conclusion, we believe that laparoscopic extended right colectomy is safe but should be performed by skilled surgeons.

The probability of metastasis of gastrocolic ligament lymph nodes was 10% in our study. This result is similar to previous studies showing that the probability of lymph node metastasis of the gastrocolic ligament is relatively low. We found that the probability of lymph node metastasis of the gastrocolic ligament with tumors located in the hepatic flexure or right-side transverse colon is significantly higher than that of

colon cancer in other locations. Therefore, tumors located in high-risk locations should undergo extended right hemicolectomy combined with infrapyloric and greater curvature lymph node dissection[6]. The main risk factors for gastroduodenal lymph node metastasis in right colon cancer are nerve invasion, pN2 stage, carcinoembryonic antigen, poor differentiation and apical lymph node metastasis[4,16]. We can further confirm this conclusion given the data shown in Table 4. These factors are high-risk and lead to a poor prognosis in colon cancer patients, indicating that the occurrence of gastroduodenal lymph node metastasis is closely related to the patient survival rate.

Whether lymph node metastasis of the gastroduodenal ligament is regional lymph node metastasis or distant metastasis remains controversial[4,19]. Based on the limited available data, it is difficult to draw a conclusion. However, this does not affect the need for postoperative chemotherapy in some patients. Twelve patients received regular adjuvant chemotherapy, oxaliplatin combined with capecitabine. One patient died of liver metastasis and pulmonary infection 7 mo after the operation. The TNM stage of the patient was T3N2M0, with lymph node metastasis of the gastroduodenal ligament and vascular and nerve invasion, indicating a poor prognosis. The remaining patients had no recurrence or metastasis during the follow-up. Notably, Saluja *et al*[20] showed that there was no significant difference in survival between young patients and elderly patients. To date, few studies conducted a survival analysis of patients with laparoscopic extended right colectomy. The short-term efficacy and long-term prognosis still require further investigation.

This study demonstrated the rate of gastroduodenal lymph nodes located in the liver flexure or the right transverse colon and comprehensively evaluated the safety, feasibility, and short-term efficacy of lymph node dissection in this area, providing important clinical significance; however, there are still several limitations. First, this article reports a single-center analysis based on a clinical study. The inclusion and exclusion criteria were strict, and the length of time was short, resulting in a small sample size, which cannot reach the sample size required for calculation. Second, due to the current short follow-up time, the long-term prognosis of the patients cannot be assessed. A multicenter clinical study investigating this subject in the future is expected to further confirm the results we discussed and evaluate the long-term prognosis of patients.

CONCLUSION

Malignant tumors located in the hepatic flexure or right transverse colon have the possibility of gastroduodenal lymph node metastasis, and there are indications for laparoscopic extended right colectomy. The surgical approach is safe but could notably increase the incidence of gastroparesis. However, the prognostic effect still needs further analysis.

ARTICLE HIGHLIGHTS

Research background

Whether laparoscopic extended right colectomy is necessary for colon cancer with tumor located in hepatic flexure and right transverse colon is still controversial.

Research motivation

It is of great concern whether laparoscopic extended right colectomy is necessary for tumors located in the hepatic flexure and the right transverse colon. Currently, there is an urgent need to understand the law of lymph nodes of the gastroduodenal ligament and the safety of the operation.

Research objectives

This study aimed to study the necessity and safety of laparoscopic extended right colectomy.

Research methods

This is a clinical study of 20 patients who underwent laparoscopic extended right colectomy. This article describes the surgical technique of laparoscopic extended right

colectomy and the perioperative information of patients.

Research results

There were no intraoperative complications and conversion to laparotomy in 20 patients. Lymph node metastasis of gastrocolic ligament occurred in 10% of patients, and postoperative complications occurred in 5 patients.

Research conclusions

Laparoscopic extended right colectomy is safe, but it may significantly increase the risk of postoperative gastroparesis.

Research perspectives

This study is expected to increase the sample size and follow-up time.

REFERENCES

- Doubeni CA**, Corley DA, Jensen CD, Schottinger JE, Lee JK, Ghai NR, Levin TR, Zhao WK, Saia CA, Wainwright JV, Mehta SJ, Selby K, Doria-Rose VP, Zauber AG, Fletcher RH, Weiss NS. The effect of using fecal testing after a negative sigmoidoscopy on the risk of death from colorectal cancer. *J Med Screen* 2021; **28**: 140-147 [PMID: 32438892 DOI: 10.1177/0969141320921427]
- Nakagawa-Senda H**, Hori M, Matsuda T, Ito H. Prognostic impact of tumor location in colon cancer: the Monitoring of Cancer Incidence in Japan (MCIJ) project. *BMC Cancer* 2019; **19**: 431 [PMID: 31072372 DOI: 10.1186/s12885-019-5644-y]
- Søndenaa K**, Quirke P, Hohenberger W, Sugihara K, Kobayashi H, Kessler H, Brown G, Tudyka V, D'Hoore A, Kennedy RH, West NP, Kim SH, Heald R, Storli KE, Nesbakken A, Moran B. The rationale behind complete mesocolic excision (CME) and a central vascular ligation for colon cancer in open and laparoscopic surgery : proceedings of a consensus conference. *Int J Colorectal Dis* 2014; **29**: 419-428 [PMID: 24477788 DOI: 10.1007/s00384-013-1818-2]
- Olmi S**, Oldani A, Cesana G, Ciccarese F, Uccelli M, Giorgi R, Villa R, Maria De Carli S. Surgical Outcomes of Laparoscopic Right Colectomy with Complete Mesocolic Excision. *JSLS* 2020; **24** [PMID: 32518478 DOI: 10.4293/JSLS.2020.00023]
- Bertelsen CA**, Bols B, Ingeholm P, Jansen JE, Jepsen LV, Kristensen B, Neuenschwander AU, Gögenur I. Lymph node metastases in the gastrocolic ligament in patients with colon cancer. *Dis Colon Rectum* 2014; **57**: 839-845 [PMID: 24901684 DOI: 10.1097/DCR.000000000000144]
- Toyota S**, Ohta H, Anazawa S. Rationale for extent of lymph node dissection for right colon cancer. *Dis Colon Rectum* 1995; **38**: 705-711 [PMID: 7607029 DOI: 10.1007/BF02048026]
- Feng B**, Ling TL, Lu AG, Wang ML, Ma JJ, Li JW, Zang L, Sun J, Zheng MH. Completely medial vs hybrid medial approach for laparoscopic complete mesocolic excision in right hemicolonic cancer. *Surg Endosc* 2014; **28**: 477-483 [PMID: 24114515 DOI: 10.1007/s00464-013-3225-8]
- Hohenberger W**, Weber K, Matzel K, Papadopoulos T, Merkel S. Standardized surgery for colonic cancer: complete mesocolic excision and central ligation--technical notes and outcome. *Colorectal Dis* 2009; **11**: 354-64; discussion 364 [PMID: 19016817 DOI: 10.1111/j.1463-1318.2008.01735.x]
- Dindo D**, Demartines N, Clavien PA. Classification of surgical complications: a new proposal with evaluation in a cohort of 6336 patients and results of a survey. *Ann Surg* 2004; **240**: 205-213 [PMID: 15273542 DOI: 10.1097/01.sla.0000133083.54934.ae]
- Di Buono G**, Buscemi S, Cocorullo G, Sorce V, Amato G, Bonventre G, Maienza E, Galia M, Gulotta L, Romano G, Agrusa A. Feasibility and Safety of Laparoscopic Complete Mesocolic Excision (CME) for Right-sided Colon Cancer: Short-term Outcomes. A Randomized Clinical Study. *Ann Surg* 2021; **274**: 57-62 [PMID: 33177355 DOI: 10.1097/SLA.0000000000004557]
- Chew SS**, Adams WJ. Laparoscopic hand-assisted extended right hemicolectomy for cancer management. *Surg Endosc* 2007; **21**: 1654-1656 [PMID: 17593463 DOI: 10.1007/s00464-006-9128-1]
- Koh FH**, Tan KK. A Safe Method for Middle Colic Dissection and Ligation at its Origin in a Laparoscopic Extended Right Hemicolectomy. *Ann Surg Oncol* 2016; **23**: 665 [PMID: 27550618 DOI: 10.1245/s10434-016-5507-6]
- Zhao LY**, Chi P, Ding WX, Huang SR, Zhang SF, Pan K, Hu YF, Liu H, Li GX. Laparoscopic vs open extended right hemicolectomy for colon cancer. *World J Gastroenterol* 2014; **20**: 7926-7932 [PMID: 24976728 DOI: 10.3748/wjg.v20.i24.7926]
- 2017 and 2015 European Society of Coloproctology (ESCP) collaborating groups**. The impact of conversion on the risk of major complication following laparoscopic colonic surgery: an international, multicentre prospective audit. *Colorectal Dis* 2018; **20** Suppl 6: 69-89 [PMID: 30255643 DOI: 10.1111/codi.14371]
- Gorgun E**, Benlice C, Abbas MA, Stocchi L, Remzi FH. Conversion in laparoscopic colorectal surgery: Are short-term outcomes worse than with open surgery? *Tech Coloproctol* 2016; **20**: 845-851 [PMID: 27921183 DOI: 10.1007/s10151-016-1554-z]
- Huang S**, Wang X, Deng Y, Jiang W, Huang Y, Chi P. Gastrocolic Ligament Lymph Node

- Dissection for Transverse Colon and Hepatic Flexure Colon Cancer: Risk of Nodal Metastases and Complications in a Large-Volume Center. *J Gastrointest Surg* 2020; **24**: 2658-2660 [PMID: 32666497 DOI: 10.1007/s11605-020-04705-4]
- 17 **De Block CE**, De Leeuw IH, Pelckmans PA, Callens D, Máday E, Van Gaal LF. Delayed gastric emptying and gastric autoimmunity in type 1 diabetes. *Diabetes Care* 2002; **25**: 912-917 [PMID: 11978690 DOI: 10.2337/diacare.25.5.912]
 - 18 **You XL**, Lian YJ, Wu J, Wang YJ, Dai JW, Zhao XJ, Cheng ZY, Huang CJ, Li WQ, Zhou Y. [Clinical study on preserving right gastroepiploic vein during laparoscopic right hemicolectomy]. *Zhonghua Wei Chang Wai Ke Za Zhi* 2020; **23**: 1164-1169 [PMID: 33353271 DOI: 10.3760/cma.j.cn.441530-20200128-00035]
 - 19 **Uematsu D**, Akiyama G, Sugihara T, Magishi A, Yamaguchi T, Sano T. Laparoscopic radical lymph node dissection for advanced colon cancer close to the hepatic flexure. *Asian J Endosc Surg* 2017; **10**: 23-27 [PMID: 27515772 DOI: 10.1111/ases.12311]
 - 20 **Saluja SS**, Manipadam JM, Mishra PK, Sachdeva S, Solanki N, Shah H. Young onset colorectal cancer: How does it differ from its older counterpart? *Indian J Cancer* 2014; **51**: 565-569 [PMID: 26842197 DOI: 10.4103/0019-509X.175350]



Published by **Baishideng Publishing Group Inc**
7041 Koll Center Parkway, Suite 160, Pleasanton, CA 94566, USA

Telephone: +1-925-3991568

E-mail: bpgoffice@wjgnet.com

Help Desk: <https://www.f6publishing.com/helpdesk>

<https://www.wjgnet.com>

