

ALL IMAGES VIDEOS

9,820 Results

Any time ▾

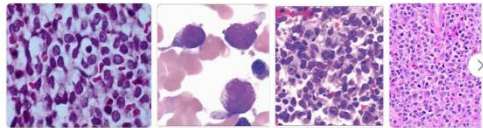
**Usefulness of allogeneic hematopoietic stem cell ...**<https://pubmed.ncbi.nlm.nih.gov/23788509>

No standard treatment has been established in childhood blastic plasmacytoid dendritic cell neoplasma (BPDCN) because of its rarity. We treated with acute lymphoblastic leukemia-type regimen for a child with BPDCN with skin and leukemic involvement. She has been disease-free for 4 years after allogeneic hematopoietic stem cell transplantation.

**Blastic plasmacytoid dendritic cell neoplasm with a ...**<https://onlinelibrary.wiley.com/doi/full/10.1002/dc.24463>

May 06, 2020 · Abstract. Blastic plasmacytoid dendritic cell neoplasm (BPDCN) is a rare and aggressive hematologic malignancy arising from plasmacytoid dendritic cell precursors. The disease typically manifests in the skin, but it also evolves into a leukemic phase or can be complicated by other myeloid malignancies, especially myelomonocytic tumors. The association between these neoplasms is not ...

Author: Miao Yan, Wensheng Wang, Xinan Cen, ... Publish Year: 2020

**Images of Blastic plasmacytoid dendritic cell neoplasm with skin a...**  
<bing.com/images>**Blastic NK cell lymphoma**

Symptoms

Diagnosis

Causes

Treatments



Blastic plasmacytoid dendritic cell neoplasm is a rare hematologic malignancy. It was initially regarded as a form of lymphocyte-derived cutaneous lymphoma and alternatively named CD4+CD56+ hematodermic tumor, blastic NK cell lymphoma, and agranular CD4+ NK cell leukemia. Later, however, the disease was determined to be a malignancy of plasmacytoid dendritic cells rather than lymphocytes and therefore termed blastic plasmacytoid dendritic cell neoplasm. In 2016, the World Health Organization designated BPDCN to be in its own separate category within the myeloid class of neoplasms. It is estimated that BPDCN constitutes 0.44% of all hematological malignancies.

Wikipedia

**People also search for**

Lung Cancer

Cancer

T-cell prolymphocytic leukemia

Breast Cancer

B-cell prolymphocytic leukemia

Guo JH, Zhang HW, Wang L, Bai W, Wang JF. Blastic plasmacytoid dendritic cell neoplasm with skin and bone marrow involvement: A case report. *World J Clin Cases* 2021; In press

**Core Tip:** Blastic plasmacytoid dendritic cell neoplasm (BPDCN) is difficult to diagnose because of the overlap in morphologic and immunophenotypic features with various cutaneous lymphatic hematopoietic tumors. We report the clinical symptoms, pathological characteristics, immunophenotype, treatment, and follow-up (from diagnosis until death) for three patients with BPDCN. It is necessary to clarify the clinicopathological features and biological behavior of BPDCN to improve the understanding of the disease by both clinicians and pathologists. The survival time of case 2 was significantly longer than usual, suggesting that the treatment received was suitable for clinical application.

## Match Breakdown

1 Crossref Posted Content 1557 words  
Jianghong Guo, Hongwei Zhang, Yanfeng Xi, Jiang Chang, Li Wang, Yaling Li, Wei Bai, Jinfen Wang "Blastic Plasmacytoid Dendritic Cell Neoplasm: A Case Report" 60%

Match 1 of 19

• Crossref Posted Content 1557 words  
Jianghong Guo, Hongwei Zhang, Yanfeng Xi, Jiang Chang, Li Wang, Yaling Li, Wei Bai, Jinfen Wang "Blastic Plasmacytoid Dendritic Cell Neoplasm: A Case Report" 60%

Internet 61 words  
crawled on 09-Aug-2021  
www.sciencegate.app 2%

• Crossref - 2 sources 35 words  
Minas P Economides, Marina Konopleva, Naveen Perera, et al. "Recent developments in the treatment of blastic plasmacytoid dendritic cell neoplasm" 1%

• Crossref 14 words  
"Poster Abstracts", The Journal of Dermatology, 2014. 1%

• Crossref 13 words  
Arthur Zimmermann "Chapter 87 Blastic Plasmacytoid Dendritic Cell Neoplasm", Springer Science and Business Media LLC 1%

• Crossref 13 words  
Zimmermann, Arthur "Blastic Plasmacytoid Dendritic Cell Neoplasm", Tumors and Tumor-Like Lesions of the Head and Neck 1%

Internet - 2 sources 13 words

Exclude Sources

国内版

国际版

Blastic plasmacytoid dendritic cell neoplasm with skin and bone m



ALL

IMAGES

VIDEOS

7,170 Results

Any time ▾

### Blastic plasmacytoid dendritic cell neoplasm: skin and ...

<https://pubmed.ncbi.nlm.nih.gov/25825579>

Blastic plasmacytoid dendritic cell neoplasm (BPDCN) is a distinct and rare neoplastic entity and was classified as a subgroup of acute myeloblastic leukemia by the WHO in 2008. The median survival of patients was 15.2 months in a large case series. Allogeneic or autologous bone marrow transplantati

Cited by: 10

Author: Figen Atalay, Gülşen Tükenmez Demirci, ...

Publish Year: 2015

### Blastic plasmacytoid dendritic cell neoplasm: skin and ...

<https://www.europepmc.org/articles/PMC4375161> ▾

Oct 14, 2014 · Blastic plasmacytoid dendritic cell neoplasm (BPDCN) is a distinct and rare neoplastic entity and was classified as a subgroup of acute myeloid leukemia by the WHO in 2008 . BPDCN originates from precursors of plasmacytoid dendritic cells. In pathological examination, the neoplastic cells express typical CD4, CD56, and CD123 .

Cited by: 10

Author: Figen Atalay, Gülşen Tükenmez Demirci, ...

Publish Year: 2015

### A Case of Cutaneous Blastic Plasmacytoid Dendritic Cell ...

<https://pubmed.ncbi.nlm.nih.gov/33938687>

Blastic plasmacytoid dendritic cell neoplasm (BPDCN) is a rare and aggressive primary cutaneous lymphoma characterized by transformed plasmacytoid dendritic cells that overexpress interleukin-3 receptor subunit alpha (IL3RA) also known as CD123. In addition to several therapies currently undergoing clinical trials, Tagraxofusp-erzs (Stemline ...

Author: Andjela Egger, Diana Coello, Robert S... Publish Year: 2021

### Blastic Plasmacytoid Dendritic Cell Neoplasm: Skin and ...

<https://link.springer.com/article/10.1007/s12288-014-0464-3> ▾

Oct 14, 2014 · Blastic plasmacytoid dendritic cell neoplasm (BPDCN) is a distinct and rare neoplastic entity and was classified as a subgroup of acute myeloid leukemia by the WHO in 2008 . BPDCN originates from precursors of plasmacytoid dendritic cells. In pathological examination, the neoplastic cells express typical CD4, CD56, and CD123 .

Cited by: 10

Author: Figen Atalay, Gülşen Tükenmez Demirci, ...