

# World Journal of *Clinical Cases*

*World J Clin Cases* 2022 January 7; 10(1): 1-396



## MINIREVIEWS

- 1 Omicron variant (B.1.1.529) of SARS-CoV-2: Mutation, infectivity, transmission, and vaccine resistance  
*Ren SY, Wang WB, Gao RD, Zhou AM*
- 12 Hepatitis B virus reactivation in rheumatoid arthritis  
*Wu YL, Ke J, Zhang BY, Zhao D*
- 23 Paradoxical role of interleukin-33/suppressor of tumorigenicity 2 in colorectal carcinogenesis: Progress and therapeutic potential  
*Huang F, Chen WY, Ma J, He XL, Wang JW*

## ORIGINAL ARTICLE

## Case Control Study

- 35 Changes in rheumatoid arthritis under ultrasound before and after sinomenine injection  
*Huang YM, Zhuang Y, Tan ZM*
- 43 Benefits of multidisciplinary collaborative care team-based nursing services in treating pressure injury wounds in cerebral infarction patients  
*Gu YH, Wang X, Sun SS*

## Retrospective Study

- 51 Outcomes and complications of open, laparoscopic, and hybrid giant ventral hernia repair  
*Yang S, Wang MG, Nie YS, Zhao XF, Liu J*
- 62 Surgical resection of intradural extramedullary tumors in the atlantoaxial spine *via* a posterior approach  
*Meng DH, Wang JQ, Yang KX, Chen WY, Pan C, Jiang H*
- 71 Vancomycin lavage for the incidence of acute surgical site infection following primary total hip arthroplasty and total knee arthroplasty  
*Duan MY, Zhang HZ*
- 79 Distribution of transient receptor potential vanilloid-1 channels in gastrointestinal tract of patients with morbid obesity  
*Atas U, Erin N, Tazegul G, Elpek GO, Yıldırım B*
- 91 Value of neutrophil-lymphocyte ratio in evaluating response to percutaneous catheter drainage in patients with acute pancreatitis  
*Gupta P, Das GC, Bansal A, Samanta J, Mandavdhare HS, Sharma V, Naseem S, Gupta V, Yadav TD, Dutta U, Varma N, Sandhu MS, Kochhar R*

- 104** Influence of overweight and obesity on the mortality of hospitalized patients with community-acquired pneumonia  
*Wang N, Liu BW, Ma CM, Yan Y, Su QW, Yin FZ*
- 117** Minimally invasive open reduction of greater tuberosity fractures by a modified suture bridge procedure  
*Kong LP, Yang JJ, Wang F, Liu FX, Yang YL*
- 128** Increased levels of lactate dehydrogenase and hypertension are associated with severe illness of COVID-19  
*Jin ZM, Shi JC, Zheng M, Chen QL, Zhou YY, Cheng F, Cai J, Jiang XG*
- 136** Age, alcohol, sex, and metabolic factors as risk factors for colonic diverticulosis  
*Yan Y, Wu JS, Pan S*
- 143** Evaluation of right-to-left shunt on contrast-enhanced transcranial Doppler in patent foramen ovale-related cryptogenic stroke: Research based on imaging  
*Xiao L, Yan YH, Ding YF, Liu M, Kong LJ, Hu CH, Hui PJ*
- 155** Characterization of focal hypermetabolic thyroid incidentaloma: An analysis with F-18 fluorodeoxyglucose positron emission tomography/computed tomography parameters  
*Lee H, Chung YS, Lee JH, Lee KY, Hwang KH*

### Clinical Trials Study

- 166** Low-dose intralesional injection of 5-fluorouracil and triamcinolone reduces tissue resident memory T cells in chronic eczema  
*Wu Y, Wang GJ, He HQ, Qin HH, Shen WT, Yu Y, Zhang X, Zhou ML, Fei JB*

### Observational Study

- 177** Alterations in blink and masseter reflex latencies in older adults with neurocognitive disorder and/or diabetes mellitus  
*Bricio-Barrios JA, Rios-Bracamontes E, Rios-Silva M, Huerta M, Serrano-Moreno W, Barrios-Navarro JE, Ortiz GG, Huerta-Trujillo M, Guzmán-Esquivel J, Trujillo X*
- 189** Predicting adolescent perfectionism: The role of socio-demographic traits, personal relationships, and media  
*Livazović G, Kuzmanović K*
- 205** Novel m.4268T>C mutation in the mitochondrial tRNA<sup>Leu</sup> gene is associated with hearing loss in two Chinese families  
*Zhao LJ, Zhang ZL, Fu Y*
- 217** Superior mesenteric venous thrombosis: Endovascular management and outcomes  
*Alnahhal K, Toskich BB, Nussbaum S, Li Z, Erben Y, Hakaim AG, Farres H*

### Randomized Controlled Trial

- 227** Zinc carnosine-based modified bismuth quadruple therapy *vs* standard triple therapy for *Helicobacter pylori* eradication: A randomized controlled study  
*Ibrahim N, El Said H, Choukair A*

## CASE REPORT

- 236** Acquired coagulation dysfunction resulting from vitamin K-dependent coagulation factor deficiency associated with rheumatoid arthritis: A case report  
*Huang YJ, Han L, Li J, Chen C*
- 242** Intraoperative thromboelastography-guided transfusion in a patient with factor XI deficiency: A case report  
*Guo WJ, Chen WY, Yu XR, Shen L, Huang YG*
- 249** Positron emission tomography and magnetic resonance imaging combined with computed tomography in tumor volume delineation: A case report  
*Zhou QP, Zhao YH, Gao L*
- 254** Successful response to camrelizumab in metastatic bladder cancer: A case report  
*Xie C, Yuan X, Chen SH, Liu ZY, Lu DL, Xu F, Chen ZQ, Zhong XM*
- 260** HER2 changes to positive after neoadjuvant chemotherapy in breast cancer: A case report and literature review  
*Wang L, Jiang Q, He MY, Shen P*
- 268** Hyper-accuracy three-dimensional reconstruction as a tool for better planning of retroperitoneal liposarcoma resection: A case report  
*Ye MS, Wu HK, Qin XZ, Luo F, Li Z*
- 275** Recurrent postmenopausal bleeding - just endometrial disease or ovarian sex cord-stromal tumor? A case report  
*Wang J, Yang Q, Zhang NN, Wang DD*
- 283** Complex proximal femoral fracture in a young patient followed up for 3 years: A case report  
*Li ZY, Cheng WD, Qi L, Yu SS, Jing JH*
- 289** Bilateral Hypertrophic Olivary Degeneration after Pontine Hemorrhage: A Case Report  
*Zheng B, Wang J, Huang XQ, Chen Z, Gu GF, Luo XJ*
- 296** Clinical characteristics and outcomes of primary intracranial alveolar soft-part sarcoma: A case report  
*Chen JY, Cen B, Hu F, Qiu Y, Xiao GM, Zhou JG, Zhang FC*
- 304** Removal of laparoscopic cerclage stitches *via* laparotomy and rivanol-induced labour: A case report and literature review  
*Na XN, Cai BS*
- 309** Cerebral venous sinus thrombosis in pregnancy: A case report  
*Zhou B, Huang SS, Huang C, Liu SY*
- 316** Eustachian tube teratoma: A case report  
*Li JY, Sun LX, Hu N, Song GS, Dou WQ, Gong RZ, Li CT*

- 323** Protein-losing enteropathy caused by a jejunal ulcer after an internal hernia in Petersen's space: A case report  
*Yasuda T, Sakurazawa N, Kuge K, Omori J, Arai H, Kakinuma D, Watanabe M, Suzuki H, Iwakiri K, Yoshida H*
- 331** Lunate dislocation with avulsed triquetral fracture: A case report  
*Li LY, Lin CJ, Ko CY*
- 338** Clinical manifestations and prenatal diagnosis of Ullrich congenital muscular dystrophy: A case report  
*Hu J, Chen YH, Fang X, Zhou Y, Chen F*
- 345** Diagnosis and guidance of treatment of breast cancer cutaneous metastases by multiple needle biopsy: A case report  
*Li ZH, Wang F, Zhang P, Xue P, Zhu SJ*
- 353** Test of incremental respiratory endurance as home-based, stand-alone therapy in chronic obstructive pulmonary disease: A case report  
*Dosbaba F, Hartman M, Batalik L, Brat K, Plutinsky M, Hnatiak J, Formiga MF, Cahalin LP*
- 361** Diagnostic and surgical challenges of progressive neck and upper back painless masses in Madelung's disease: A case report and review of literature  
*Yan YJ, Zhou SQ, Li CQ, Ruan Y*
- 371** Suspected cerebrovascular air embolism during endoscopic esophageal varices ligation under sedation with fatal outcome: A case report  
*Zhang CMJ, Wang X*
- 381** An atypical primary malignant melanoma arising from the cervical nerve root: A case report and review of literature  
*Shi YF, Chen YQ, Chen HF, Hu X*
- 388** Epidural blood patch for spontaneous intracranial hypotension with subdural hematoma: A case report and review of literature  
*Choi SH, Lee YY, Kim WJ*

**ABOUT COVER**

Editorial Board Member of *World Journal of Clinical Cases*, Ravi Kant, MD, Associate Professor, Division of Endocrinology, Diabetes and Metabolism, Medical University of South Carolina/Anmed Campus, Anderson, SC 29621, United States. rkant82@hotmail.com

**AIMS AND SCOPE**

The primary aim of *World Journal of Clinical Cases* (WJCC, *World J Clin Cases*) is to provide scholars and readers from various fields of clinical medicine with a platform to publish high-quality clinical research articles and communicate their research findings online.

WJCC mainly publishes articles reporting research results and findings obtained in the field of clinical medicine and covering a wide range of topics, including case control studies, retrospective cohort studies, retrospective studies, clinical trials studies, observational studies, prospective studies, randomized controlled trials, randomized clinical trials, systematic reviews, meta-analysis, and case reports.

**INDEXING/ABSTRACTING**

The WJCC is now indexed in Science Citation Index Expanded (also known as SciSearch®), Journal Citation Reports/Science Edition, Scopus, PubMed, and PubMed Central. The 2021 Edition of Journal Citation Reports® cites the 2020 impact factor (IF) for WJCC as 1.337; IF without journal self cites: 1.301; 5-year IF: 1.742; Journal Citation Indicator: 0.33; Ranking: 119 among 169 journals in medicine, general and internal; and Quartile category: Q3. The WJCC's CiteScore for 2020 is 0.8 and Scopus CiteScore rank 2020: General Medicine is 493/793.

**RESPONSIBLE EDITORS FOR THIS ISSUE**

Production Editor: Lin-YuTong Wang; Production Department Director: Xiang Li; Editorial Office Director: Jin-Lei Wang.

**NAME OF JOURNAL**

*World Journal of Clinical Cases*

**ISSN**

ISSN 2307-8960 (online)

**LAUNCH DATE**

April 16, 2013

**FREQUENCY**

Weekly

**EDITORS-IN-CHIEF**

Bao-Gan Peng

**EDITORIAL BOARD MEMBERS**

<https://www.wjgnet.com/2307-8960/editorialboard.htm>

**PUBLICATION DATE**

January 7, 2022

**COPYRIGHT**

© 2022 Baishideng Publishing Group Inc

**INSTRUCTIONS TO AUTHORS**

<https://www.wjgnet.com/bpg/gerinfo/204>

**GUIDELINES FOR ETHICS DOCUMENTS**

<https://www.wjgnet.com/bpg/GerInfo/287>

**GUIDELINES FOR NON-NATIVE SPEAKERS OF ENGLISH**

<https://www.wjgnet.com/bpg/gerinfo/240>

**PUBLICATION ETHICS**

<https://www.wjgnet.com/bpg/GerInfo/288>

**PUBLICATION MISCONDUCT**

<https://www.wjgnet.com/bpg/gerinfo/208>

**ARTICLE PROCESSING CHARGE**

<https://www.wjgnet.com/bpg/gerinfo/242>

**STEPS FOR SUBMITTING MANUSCRIPTS**

<https://www.wjgnet.com/bpg/GerInfo/239>

**ONLINE SUBMISSION**

<https://www.f6publishing.com>

## Protein-losing enteropathy caused by a jejunal ulcer after an internal hernia in Petersen's space: A case report

Tomohiko Yasuda, Nobuyuki Sakurazawa, Komei Kuge, Jun Omori, Hiroki Arai, Daisuke Kakinuma, Masanori Watanabe, Hideyuki Suzuki, Katsuhiko Iwakiri, Hiroshi Yoshida

**ORCID number:** Tomohiko Yasuda 0000-0001-9376-9932; Nobuyuki Sakurazawa 0000-0002-6762-7065; Komei Kuge 0000-0002-6896-3773; Jun Omori 0000-0002-4375-5070; Hiroki Arai 0000-0002-4595-142X; Daisuke Kakinuma 0000-0001-9853-8316; Masanori Watanabe 0000-0002-9002-3358; Hideyuki Suzuki 0000-0002-1621-6581; Katsuhiko Iwakiri 0000-0002-5558-6104; Hiroshi Yoshida 0000-0002-2463-9023.

**Author contributions:** Yasuda T wrote the original draft; Sakurazawa N, Kuge K, Omori J, Arai H, and Kakinuma D contributed to writing, review, and editing; Watanabe M, Suzuki H, and Iwakiri K contributed to the supervision.

**Informed consent statement:** Informed written consent was obtained from the patient for the publication of this report and any accompanying images.

**Conflict-of-interest statement:** The authors declare that they have no conflict of interest.

**CARE Checklist (2016) statement:** The authors have read the CARE Checklist (2016), and the manuscript was prepared and revised according to the CARE Checklist (2016).

Tomohiko Yasuda, Komei Kuge, Hiroki Arai, Daisuke Kakinuma, Masanori Watanabe, Hideyuki Suzuki, Department of Gastrointestinal Surgery, Nippon Medical School Chiba Hokusoh Hospital, Chiba 270-1694, Japan

Nobuyuki Sakurazawa, Hiroshi Yoshida, Department of Gastrointestinal and Hepato-Biliary-Pancreatic Surgery, Nippon Medical School, Tokyo 113-8603, Japan

Jun Omori, Katsuhiko Iwakiri, Department of Gastroenterology, Nippon Medical School, Tokyo 113-8603, Japan

**Corresponding author:** Tomohiko Yasuda, MD, PhD, Doctor, Department of Gastrointestinal Surgery, Nippon Medical School Chiba Hokusoh Hospital, 715, Kamagari, Inzai-shi, Chiba 270-1694, Japan. [t-yasuda@nms.ac.jp](mailto:t-yasuda@nms.ac.jp)

### Abstract

#### BACKGROUND

The incidence of internal hernias has recently increased in concordance with the popularization of laparoscopic surgery. Of particular concern are internal hernias occurring in Petersen's space, a space that is surgically created after treatment for gastric cancer and obesity. These hernias cause devastating sequelae, such as massive intestinal necrosis, fatal Roux limb necrosis, and superior mesenteric vein thrombus. In addition, protein-losing enteropathy (PLE) is a rare syndrome involving gastrointestinal protein loss, although its relationship with internal Petersen's hernias remains unknown.

#### CASE SUMMARY

A 75-year-old man with a history of laparotomy for early gastric cancer developed Petersen's hernia 1 year and 5 mo after surgery. He was successfully treated by reducing the incarcerated small intestine and closure of Petersen's defect without resection of the small intestine. Approximately 3 mo after his surgery for Petersen's hernia, he developed bilateral leg edema and hypoalbuminemia. He was diagnosed with PLE with an alpha-1 antitrypsin clearance of 733 mL/24 h. Double-balloon enteroscopy revealed extensive jejunal ulceration as the etiology, and it facilitated minimum bowel resection. Pathological analysis showed extensive jejunal ulceration and collagen hyperplasia with nonspecific inflammation of all layers without lymphangiectasia, lymphoma, or vascular abnormalities. His postoperative course was unremarkable, and his bilateral leg edema



**Country/Territory of origin:** Japan**Specialty type:** Medicine, research, and experimental**Provenance and peer review:** Unsolicited article; Externally peer reviewed.**Peer-review model:** Single blind**Peer-review report's scientific quality classification**

Grade A (Excellent): 0

Grade B (Very good): 0

Grade C (Good): C

Grade D (Fair): 0

Grade E (Poor): 0

**Open-Access:** This article is an open-access article that was selected by an in-house editor and fully peer-reviewed by external reviewers. It is distributed in accordance with the Creative Commons Attribution NonCommercial (CC BY-NC 4.0) license, which permits others to distribute, remix, adapt, build upon this work non-commercially, and license their derivative works on different terms, provided the original work is properly cited and the use is non-commercial. See: <http://creativecommons.org/licenses/by-nc/4.0/>

**Received:** June 21, 2021**Peer-review started:** June 21, 2021**First decision:** July 14, 2021**Revised:** July 29, 2021**Accepted:** November 29, 2021**Article in press:** November 29, 2021**Published online:** January 7, 2022**P-Reviewer:** Arslan M**S-Editor:** Wang JJ**L-Editor:** Webster JR**P-Editor:** Wang JJ

and hypoalbuminemia improved after 1 mo. There was no relapse over the 5-year follow-up period.

## CONCLUSION

PLE and extensive jejunal ulceration may occur after Petersen's hernia. Double-balloon enteroscopy helps identify and resect these lesions.

**Key Words:** Internal hernia; Ulcer; Protein-losing enteropathy; Double-balloon enteroscopy; Ischemia-reperfusion injury; Case report

©The Author(s) 2022. Published by Baishideng Publishing Group Inc. All rights reserved.

**Core Tip:** The incidence of internal hernias has recently increased in concordance with the increasing popularity of laparoscopic surgery. Protein-losing enteropathy (PLE) is a rare syndrome involving gastrointestinal protein loss. However, its relationship with internal Petersen's hernias remains unknown. This report presents a rare case of PLE caused by a jejunum segmental ulcer following an internal hernia in Petersen's space. PLE and extensive jejunal ulceration may follow the reduction of Petersen's hernia. Double-balloon enteroscopy revealed the etiology of PLE and enabled minimal bowel resection in this case.

**Citation:** Yasuda T, Sakurazawa N, Kuge K, Omori J, Arai H, Kakinuma D, Watanabe M, Suzuki H, Iwakiri K, Yoshida H. Protein-losing enteropathy caused by a jejunal ulcer after an internal hernia in Petersen's space: A case report. *World J Clin Cases* 2022; 10(1): 323-330

**URL:** <https://www.wjgnet.com/2307-8960/full/v10/i1/323.htm>

**DOI:** <https://dx.doi.org/10.12998/wjcc.v10.i1.323>

## INTRODUCTION

Internal hernias are the center of attention again as their incidence has increased worldwide with the popularization of laparoscopic surgery in what is considered a global gastrointestinal emergency[1-3]. Internal hernias were originally defined by Steinke[4] in 1932 as a state of intestinal intrusion or protrusion into an unusual fossa, fovea, or foramen in the abdominal cavity and are often found in strangulated bowel obstruction as well as after surgery for gastric cancer and obesity in Petersen's space. This surgically created space is surrounded by the transverse colon and jejunal mesentery. Internal hernias in this space are a fairly common postoperative complication, with a reported incidence of 1.2%–2.3% after gastrectomy with Roux-en-Y reconstruction for gastric cancer[5,6]. This surgical complication causes disastrous sequelae, such as massive intestinal necrosis, fatal Roux limb necrosis, and superior mesenteric vein (SMV) thrombus[7]. Protein-losing enteropathy (PLE) is a rare syndrome characterized by a loss of serum protein in the gastrointestinal tract. It may accompany edema, ascites, pleural effusion, and malnutrition, which often complicate various diseases and make diagnosis difficult. Although there are many reported causes of PLE thus far, the rarity of the disease and the difficulty in diagnosis often make the relationship with the primary disease unclear[8]. Furthermore, it is unknown whether an internal hernia in Petersen's space causes PLE due to delayed jejunal ulceration, even if the hernia is reduced without resection of the small intestine.

Here we report the case of a patient who presented with bilateral leg edema and hypoalbuminemia 4 mo after developing an internal hernia in Petersen's space. The etiology of this PLE was found to be a wide area of jejunal ulceration with stenosis, with the diagnosis confirmed through double-balloon endoscopy (DBE). DBE facilitated a combination of detailed observation, amidotrizoic acid radiography, tissue biopsy, and India ink injection, not only revealing a rare form of extensive jejunal ulceration after an internal hernia in Petersen's space but also proving to be an effective procedure from diagnosis to successful treatment with minimal bowel resection.



## CASE PRESENTATION

### **Chief complaints**

Following an open gastrectomy for early-stage gastric cancer and a subsequent internal hernia in Petersen's space, reduction of this internal hernia, and incident bilateral leg edema, a 75-year-old man presented at the emergency room of our medical center with a recurrence of post-surgical bilateral leg edema.

### **History of present illness**

A 75-year-old man with a history of diabetes and hypertension had undergone an open gastrectomy for early-stage gastric cancer 1 year and 5 mo before the occurrence of an internal hernia in Petersen's space. Following the initial surgery, he was treated conservatively on an outpatient basis without receiving chemotherapy and showed no recurrence or metastasis. At this point (1 year and 5 mo after the gastric cancer surgery), he presented at the emergency room of our medical center with complaints of mild, occasional abdominal distention and pain after meals that had mainly resolved naturally and a worrisome continued loss of appetite over approximately the past two weeks. Following imaging examinations described below, an internal hernia in Petersen's space was suspected, and laparoscopy was immediately performed. The operation revealed small intestine intrusion in Petersen's space, which was challenging to reduce laparoscopically. The patient underwent laparotomy, and the incarcerated small intestine was restored successfully, and the Petersen's defect was sutured using a non-absorbable thread. There was no necrosis of the intestine, and bowel resection was not performed. After surgery, the patient was managed with analgesia (mainly epidural anesthesia). He was administered non-steroidal anti-inflammatory drugs (NSAIDs), such as flurbiprofen axetil (twice on the day of surgery and the next day) during his hospitalization and later follow-up. Excluding a mild surgical site infection, the patient had a good postoperative course and was discharged on the fifteenth day after surgery.

Approximately 3 mo after his surgery for Petersen's hernia, the patient developed bilateral leg edema, with laboratory findings and diagnostic imaging scans described in detail below. Briefly, as a contrast-enhanced computed tomography (CT) scan showed no thrombus in the SMV but a slight thrombus in the lower limb, the patient was started on oral edoxaban. Although the etiology of this complication was not discerned, prompt recovery of his leg edema after administration of albumin solutions and diuretics resulted in early discharge. However, the leg edema resurfaced three weeks after discharge, and the patient was re-admitted for examination.

### **History of past illness**

The patient had a history of Type II diabetes mellitus and hypertension. Apart from this, his medical history was uncomplicated before early-stage gastric cancer, with no chronic or acute major illnesses, infections, or injuries.

### **Personal and family history**

The patient's height was 157 cm, and his weight was 51 kg. He was retired and did not have any family history of cancer or allergies to food and drugs. His medical history included Type II diabetes mellitus and hypertension, both of which were well controlled without oral treatment and insulin injection or any diet at the time of presentation. He had been taking magnesium oxide (330 mg × 6 tablets), mosapride citrate (5 mg × 3 tablets), Pancrelipase (150 mg × 6 capsules), and Kampo Daikenchuto (2.5 g × 6 packages) after surgery for gastric cancer, and he also took edoxaban for lower limb thrombosis and furosemide (20 mg × 2 tablets) and spironolactone (25 mg × 2 tablets) for the bilateral leg edema.

Blood test results, including those for renal and hepatic function, at the time of admission were as follows: Total protein, 4.2 g/dL; albumin, 1.9 g/dL; blood urea nitrogen, 33.1 mg/dL; creatinine, 0.83 mg/dL; Na, 136 mEq/L; K, 4.4 mEq/L; Cl, 100 mEq/L; Ca, 7.1 mg/dL; aspartate aminotransferase, 45 U/L; alanine aminotransferase, 33 U/L; total bilirubin, 0.6 mg/dL; direct bilirubin, 0.2 mg/dL; lactate dehydrogenase, 336 U/L; creatine phosphokinase, 116 U/L; amylase, 51 U/L; cholinesterase, 70 U/L; total cholesterol, 131 mg/dL; high density lipoprotein cholesterol, 51 mg/dL; low density lipoprotein cholesterol, 63 mg/dL; and triglyceride, 88 mg/dL.

He followed an ordinary diet before admission and switched to a low-fat, high-protein, elemental diet in the hospital.

### Physical examination

During the patient's second incidence of bilateral leg edema, we performed technetium diethyl-enetriamine-pentaacetic acid human serum albumin lymphoscintigraphy, which showed accumulation in the ascending and transverse colon. However, no abnormalities were found on colonoscopy. Capsule endoscopy was performed to examine the small intestine, revealing an extensive jejunal ulcer with stenosis. The capsule was stalled by this stenosis. Oral DBE was performed to retrieve the capsule and closely examine the lesions in the jejunum, revealing continuous jejunal ulceration with circumferential stenosis and erosion extending approximately 8 cm. Tissue biopsy was performed to differentiate lymphoma and small intestine cancer, and India ink injection was used to mark the lesion *via* DBE. Transanal DBE could not reach the jejunal ulcer and stenosis. No other lesions were found in the intestine.

### Laboratory examinations

As previously described, approximately 3 mo following this patient's surgery for Petersen's hernia, he developed bilateral leg edema. Four months after the surgery, his serum albumin had dropped to 1.9 g/dL, and his total serum protein levels had dropped to 4.2 g/dL, resulting in admission to the hospital for additional examination. At the first incidence of leg edema, blood tests showed no liver dysfunction, and urine tests for protein were negative. In addition, no signs of lymphoma or small intestine cancer were detected by histopathology during diagnostic tests performed following the second incidence of leg edema.

### Imaging examinations

Upon the patient's presentation with Petersen's hernia, a contrast-enhanced CT scan showed an SMV twisted around the superior mesenteric artery in a spiral-like pattern, as well as venous congestion in the small intestine mesentery (Figure 1). On presentation for bilateral leg edema following his surgery for Petersen's hernia, a contrast-enhanced CT scan showed no thrombus in the SMV but a slight thrombus in the lower limb. At his presentation for the second occurrence of bilateral leg edema, amidotrizoic acid radiography revealed lesion stenosis and poor dilation over a segment approximately 6 cm in length (Figure 2).

---

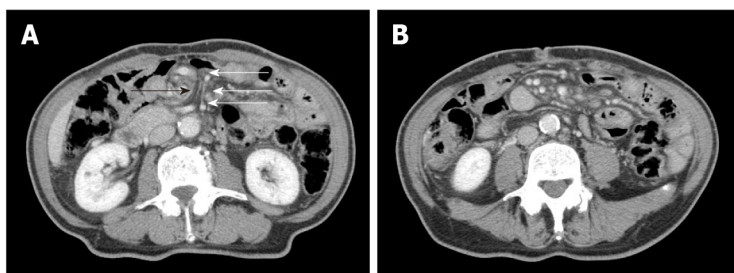
## FINAL DIAGNOSIS

As this patient had no signs of inflammatory bowel disease (*e.g.*, diarrhea or similar gastrointestinal symptoms), based on the previously described physical examinations, procedures, laboratory findings, and imaging scans, he was diagnosed with PLE with an alpha-1 antitrypsin clearance of 733 mL/24 h. Oral DBE revealed an extensive and continuous jejunal ulcer with circumferential stenosis and erosion extending approximately 8 cm; amidotrizoic acid radiography revealed that this stenosis and poor dilation extended approximately 6 cm (Figure 2). No signs of lymphoma or small intestine cancer were detected, and PLE was diagnosed as an extensive jejunal ulcer with stenosis, occurring as a post-surgical complication following an internal hernia in Petersen's space.

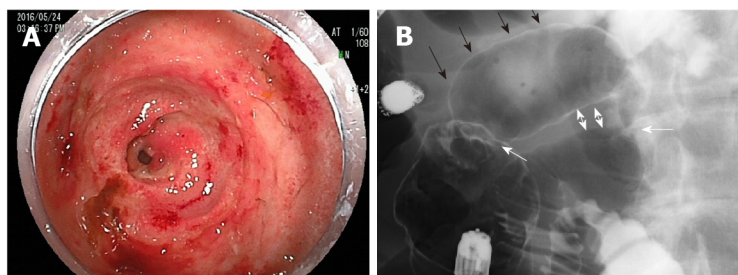
---

## TREATMENT

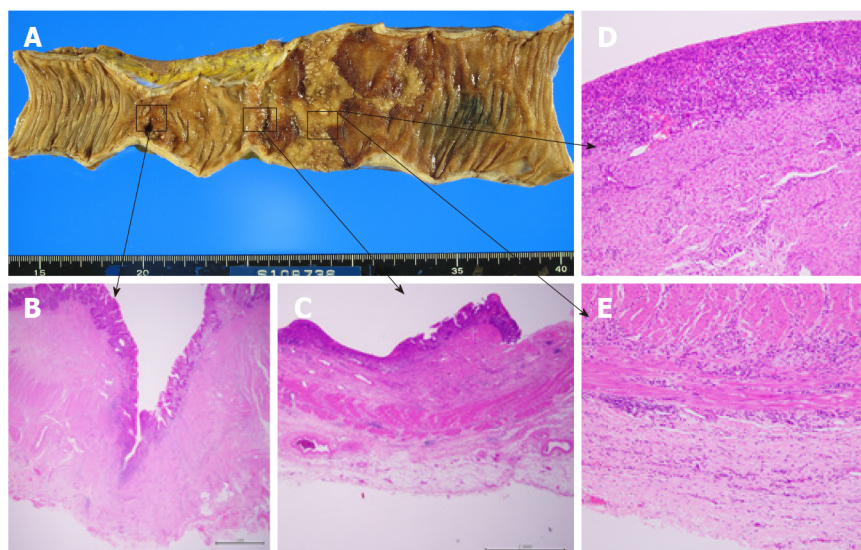
One week after the DBE, albumin solutions were administered again to treat bilateral leg edema, and laparotomy was performed. The jejunum proximal to the stenosis was extensively dilated, and marked ulcerative lesions were found. Therefore, only the jejunum between the stenosis and the marked jejunum was resected, and the remaining jejunum was anastomosed. The patient had a good postoperative course and was discharged on the 16<sup>th</sup> day following the final surgery. Pathological findings examining the ulcerative lesions showed a deep-mining ulcer in the jejunum (to the muscularis propria) with collagen hyperplasia and a shallow ulcer with extensive epithelial loss and chronic inflammatory cell infiltration in all layers; pathological findings showed no evidence of lymphangiectasia, lymphoma, or vascular abnormalities (Figure 3).



**Figure 1 Results of computed tomography scans.** A: The superior mesenteric vein (indicated with white arrows) twisted around the superior mesenteric artery (indicated with black arrows) in a spiral-like pattern; B: Venous congestion in the small intestine mesentery.



**Figure 2 Results of double-balloon enteroscopy and amidotrizoic acid radiography.** A: Double-balloon enteroscopy revealed a jejunal ulcer with circumferential stenosis and continuous erosion; B: Amidotrizoic acid radiography showed two stenoses (indicated with white arrows) with poor dilation between the two lesions (black arrows) and adhesion on the anal side (two-way arrows).



**Figure 3 Macroscopic and microscopic findings.** A: Findings revealed a deep ulcer with stenosis and a shallow ulcer in continuous erosion, along with normal mucosa marked with Indian ink on the oral side; B: Pathological findings revealed a deep-mining ulcer (to the muscularis propria) with collagen hyperplasia; C: A shallow ulcer with epithelial loss; D: An abscess, with a shallow ulcer with chronic inflammatory cell infiltration from the mucosa to the subserosa; E: A shallow ulcer with chronic inflammatory cell infiltration from the mucosa to the subserosa.

## OUTCOME AND FOLLOW-UP

One month after discharge, the patient was edema-free, and his serum albumin and total protein levels had recovered to within normal limits. He has been free from leg edema and hypoalbuminemia over five years of follow-up.

## DISCUSSION

This case report demonstrated two clinically important points. First, PLE complicated by extensive jejunal ulceration can develop in a delayed manner following the reduction of Petersen's hernia. Second, late-onset ulceration and stenosis of the jejunum occur in a segment of the small intestine vasculature following reduction of Petersen's hernia, and preoperative DBE can help identify and successfully resect such lesions.

According to a recent review, PLE can be divided into erosive and non-erosive intestinal lesions[8]. Common causes of erosive lesions of the small intestine include Crohn's disease, NSAID-associated enteritis, lymphoma, cytomegalovirus infection, and tuberculous enteritis, while rare causes include celiac disease, systemic vasculitis, ischemia, radiation-induced stenosis, and cryptogenic multifocal ulcerous stenosing enteritis[9]. Even a small jejunal ulcer can lead to PLE[10]. The major causes of non-erosive lesions are increased central venous pressure due to congestive heart failure, constrictive pericarditis, post-Fontan operation, and increased intralymphatic pressure due to lymphoma and primary intestinal lymphangiectasia[8]. To date, there have been few reports showing associations between hernias and PLE. Two previous reports showed congestion of mesenteric venous and lymphatic flow due to an internal hernia and bacterial overgrowth in the blind loop due to an incisional hernia; in these reports, PLE developed from non-erosive lesions and was successfully resolved by hernia repair[11,12]. This case report illustrates PLE caused by a completely different mechanism (an internal hernia after the surgical creation of Petersen's space). To the best of our knowledge, this is the first report to show that a wide area of jejunal ulceration caused by ischemic attacks, including internal hernias, can lead to PLE.

Possible explanations for this mechanism include intestinal ischemia-reperfusion-induced inflammation and the characteristic wide Petersen's space. It has long been shown in animal experiments that ischemia-reperfusion injury after a limited period of ischemia (*i.e.*, the "window of reperfusion injury") causes intense inflammation in all layers of the intestine[13,14]. It has likewise been shown that intensive inflammation due to prolonged intestinal ischemia reperfusion results in failure to restore damaged epithelium[15]. As Petersen's hernia has a wide hernial orifice and an accommodating space, intestinal necrosis is rare. However, a large amount of the small intestine is incarcerated. Therefore, extensive unrepaired epithelium caused by ischemia-reperfusion-induced inflammation in cases of Petersen's hernia can lead to PLE.

The efficacy of DBE for the diagnosis of PLE as well as obscure gastrointestinal bleeding and small bowel strictures has been demonstrated previously[16-23,25]. DBE has also been reported to be useful for not only treatments such as hemostasis, polypectomy, and balloon dilation but also preoperative India ink injection[24-29]. In this case, DBE revealed extensive intestinal damage with stenosis, poor dilation of > 5 cm, and a continuous ulcer of approximately 8 cm. Although resection of this sizable segmental lesion (which was due to ischemia) required minimal bowel resection, a dilated intestine (due to stenosis) makes surgical identification of extensive ulceration difficult. DBE effectively determined the extent of the lesion in the intestinal lumen before surgery, facilitating a combination of detailed observation, amidotrizoic acid radiography, tissue biopsy, and India ink injection. Thus, it not only revealed a rare form of extensive jejunal ulceration after an internal hernia in Petersen's space but also proved to be an effective procedure from diagnosis to successful treatment with minimal bowel resection.

## CONCLUSION

Following the reduction of Petersen's hernia, PLE complicated by extensive jejunal ulceration may develop in a delayed fashion. DBE is useful for identifying and resecting this lesion in segments of the small intestine vasculature. PLE after reduction of Petersen's hernia may be misdiagnosed as hypoalbuminemia due to undernutrition after gastric surgery and various other diseases, and hence the presenting symptomatology requires a search for small intestinal lesions that may underlie this presentation. Small bowel strictures after an ischemic attack have been reported to occur at intervals of several weeks following ischemia[30]. Therefore, even patients who have successfully recovered from Petersen's hernia should be carefully followed up to detect delayed ulceration and stenosis at an early stage. While many patients with Petersen's hernia do not suffer from ischemia-reperfusion injury, it is unclear why



this injury occurred in the incarcerated intestine in this case (resulting in a delayed jejunal ulcer). It is necessary to investigate the causes of ischemia-reperfusion injury after the reduction of Petersen's hernias.

## REFERENCES

- 1 Fan HP, Yang AD, Chang YJ, Juan CW, Wu HP. Clinical spectrum of internal hernia: a surgical emergency. *Surg Today* 2008; **38**: 899-904 [PMID: 18820864 DOI: 10.1007/s00595-007-3756-5]
- 2 Martin LC, Merkle EM, Thompson WM. Review of internal hernias: radiographic and clinical findings. *AJR Am J Roentgenol* 2006; **186**: 703-717 [PMID: 16498098 DOI: 10.2214/AJR.05.0644]
- 3 Ong AW, Myers SR. Early postoperative small bowel obstruction: A review. *Am J Surg* 2020; **219**: 535-539 [PMID: 31735260 DOI: 10.1016/j.amjsurg.2019.11.008]
- 4 Steinke CR. Internal hernia: Three additional case reports. *Arch Surg* 1932; **25**: 909-925 [DOI: 10.1001/archsurg.1932.01160230092008]
- 5 Yoshikawa K, Shimada M, Kurita N, Sato H, Iwata T, Higashijima J, Chikakiyo M, Nishi M, Kashiwara H, Takasu C, Matsumoto N, Eto S. Characteristics of internal hernia after gastrectomy with Roux-en-Y reconstruction for gastric cancer. *Surg Endosc* 2014; **28**: 1774-1778 [PMID: 24399525 DOI: 10.1007/s00464-013-3384-7]
- 6 Kelly KJ, Allen PJ, Brennan MF, Gollub MJ, Coit DG, Strong VE. Internal hernia after gastrectomy for cancer with Roux-Y reconstruction. *Surgery* 2013; **154**: 305-311 [PMID: 23889956 DOI: 10.1016/j.surg.2013.04.027]
- 7 Fabozzi M, Brachet Contul R, Millo P, Alliet R. Intestinal infarction by internal hernia in Petersen's space after laparoscopic gastric bypass. *World J Gastroenterol* 2014; **20**: 16349-16354 [PMID: 25473194 DOI: 10.3748/wjg.v20.i43.16349]
- 8 Umar SB, DiBaise JK. Protein-losing enteropathy: case illustrations and clinical review. *Am J Gastroenterol* 2010; **105**: 43-9; quiz 50 [PMID: 19789526 DOI: 10.1038/ajg.2009.561]
- 9 Keuchel M, Kurniawan N, Baltes P. Small bowel ulcers: when is it not inflammatory bowel disease? *Curr Opin Gastroenterol* 2019; **35**: 213-222 [PMID: 30865040 DOI: 10.1097/MOG.0000000000000522]
- 10 Chandra Chakinala R, Katchi T, Jolly GP, Haq KF, Solanki S, Barbash B. Ulcerative Jejunoileitis Presenting as Protein-Losing Enteropathy: A Diagnostic and Therapeutic Dilemma. *Am J Ther* 2020; **27**: e297-e298 [PMID: 31789630 DOI: 10.1097/MJT.0000000000000827]
- 11 Tainaka T, Ikegami R, Watanabe Y. Left paraduodenal hernia leading to protein-losing enteropathy in childhood. *J Pediatr Surg* 2005; **40**: E21-E23 [PMID: 15750912 DOI: 10.1016/j.jpedsurg.2004.10.004]
- 12 Evans JD, Perera MT, Pal C, Neuberger J, Mirza DF. Late post liver transplant protein losing enteropathy: rare complication of incisional hernia. *World J Gastroenterol* 2013; **19**: 4409-4412 [PMID: 23885154 DOI: 10.3748/wjg.v19.i27.4409]
- 13 Park PO, Haglund U, Bulkley GB, Fält K. The sequence of development of intestinal tissue injury after strangulation ischemia and reperfusion. *Surgery* 1990; **107**: 574-580 [PMID: 2159192]
- 14 Parks DA, Granger DN. Contributions of ischemia and reperfusion to mucosal lesion formation. *Am J Physiol* 1986; **250**: G749-G753 [PMID: 3717337 DOI: 10.1152/ajpgi.1986.250.6.G749]
- 15 Grootjans J, Lenaerts K, Derikx JP, Matthijsen RA, de Bruijn AP, van Bijnen AA, van Dam RM, Dejong CH, Buurman WA. Human intestinal ischemia-reperfusion-induced inflammation characterized: experiences from a new translational model. *Am J Pathol* 2010; **176**: 2283-2291 [PMID: 20348235 DOI: 10.2353/ajpath.2010.091069]
- 16 Takenaka H, Ohmiya N, Hirooka Y, Nakamura M, Ohno E, Miyahara R, Kawashima H, Itoh A, Watanabe O, Ando T, Goto H. Endoscopic and imaging findings in protein-losing enteropathy. *J Clin Gastroenterol* 2012; **46**: 575-580 [PMID: 22138845 DOI: 10.1097/MCG.0b013e31823832ac]
- 17 Kamata Y, Iwamoto M, Nara H, Kamimura T, Takayashiki N, Yamamoto H, Sugano K, Yoshio T, Okazaki H, Minota S. A case of rheumatoid arthritis with protein losing enteropathy induced by multiple diaphragmatic strictures of the small intestine: successful treatment by bougieing under double-balloon enteroscopy. *Gut* 2006; **55**: 1372 [PMID: 16905713 DOI: 10.1136/gut.2006.100446]
- 18 Pungpapong S, Stark ME, Cangemi JR. Protein-losing enteropathy from eosinophilic enteritis diagnosed by wireless capsule endoscopy and double-balloon enteroscopy. *Gastrointest Endosc* 2007; **65**: 917-8; discussion 918 [PMID: 17208236 DOI: 10.1016/j.gie.2006.08.031]
- 19 Gerson LB, Fidler JL, Cave DR, Leighton JA. ACG Clinical Guideline: Diagnosis and Management of Small Bowel Bleeding. *Am J Gastroenterol* 2015; **110**: 1265-87; quiz 1288 [PMID: 26303132 DOI: 10.1038/ajg.2015.246]
- 20 Otani K, Watanabe T, Shimada S, Hosomi S, Nagami Y, Tanaka F, Kamata N, Taira K, Yamagami H, Tanigawa T, Shiba M, Fujiwara Y. Clinical Utility of Capsule Endoscopy and Double-Balloon Enteroscopy in the Management of Obscure Gastrointestinal Bleeding. *Digestion* 2018; **97**: 52-58 [PMID: 29393257 DOI: 10.1159/000484218]
- 21 Kakiya Y, Shiba M, Okamoto J, Kato K, Minamino H, Ominami M, Fukunaga S, Nagami Y, Sugimori S, Tanigawa T, Yamagami H, Watanabe T, Tominaga K, Fujiwara Y, Arakawa T. A comparison between capsule endoscopy and double balloon enteroscopy using propensity score-matching analysis in patients with previous obscure gastrointestinal bleeding. *Scand J Gastroenterol*

- 2017; **52**: 306-311 [PMID: [27841035](#) DOI: [10.1080/00365521.2016.1253766](#)]
- 22 **Kroner PT**, Brahmabhatt BS, Bartel MJ, Stark ME, Lukens FJ. Yield of double-balloon enteroscopy in the diagnosis and treatment of small bowel strictures. *Dig Liver Dis* 2016; **48**: 446-448 [PMID: [26725164](#) DOI: [10.1016/j.dld.2015.11.019](#)]
- 23 **Hayashi Y**, Yamamoto H, Taguchi H, Sunada K, Miyata T, Yano T, Arashiro M, Sugano K. Nonsteroidal anti-inflammatory drug-induced small-bowel lesions identified by double-balloon endoscopy: endoscopic features of the lesions and endoscopic treatments for diaphragm disease. *J Gastroenterol* 2009; **44** Suppl 19: 57-63 [PMID: [19148795](#) DOI: [10.1007/s00535-008-2277-3](#)]
- 24 **Nishimura N**, Yamamoto H, Yano T, Hayashi Y, Sato H, Miura Y, Shinhata H, Sunada K, Sugano K. Balloon dilation when using double-balloon enteroscopy for small-bowel strictures associated with ischemic enteritis. *Gastrointest Endosc* 2011; **74**: 1157-1161 [PMID: [21924719](#) DOI: [10.1016/j.gie.2011.07.024](#)]
- 25 **Gill RS**, Kaffes AJ. Small bowel stricture characterization and outcomes of dilatation by double-balloon enteroscopy: a single-centre experience. *Therap Adv Gastroenterol* 2014; **7**: 108-114 [PMID: [24790641](#) DOI: [10.1177/1756283X13513995](#)]
- 26 **Belsha D**, Urs A, Attard T, Thomson M. Effectiveness of Double-balloon Enteroscopy-facilitated Polypectomy in Pediatric Patients With Peutz-Jeghers Syndrome. *J Pediatr Gastroenterol Nutr* 2017; **65**: 500-502 [PMID: [28319601](#) DOI: [10.1097/MPG.0000000000001576](#)]
- 27 **Tang L**, Huang LY, Cui J, Wu CR. Effect of Double-Balloon Enteroscopy on Diagnosis and Treatment of Small-Bowel Diseases. *Chin Med J (Engl)* 2018; **131**: 1321-1326 [PMID: [29786046](#) DOI: [10.4103/0366-6999.232802](#)]
- 28 **Urs AN**, Martinelli M, Rao P, Thomson MA. Diagnostic and therapeutic utility of double-balloon enteroscopy in children. *J Pediatr Gastroenterol Nutr* 2014; **58**: 204-212 [PMID: [24126830](#) DOI: [10.1097/MPG.000000000000192](#)]
- 29 **Sato T**, Kogure H, Nakai Y, Ishigaki K, Hakuta R, Saito K, Saito T, Takahara N, Hamada T, Mizuno S, Yamada A, Tada M, Isayama H, Koike K. Double-balloon endoscopy-assisted treatment of hepaticojejunostomy anastomotic strictures and predictive factors for treatment success. *Surg Endosc* 2020; **34**: 1612-1620 [PMID: [31218422](#) DOI: [10.1007/s00464-019-06924-6](#)]
- 30 **Kim JS**, Kim HJ, Hong SM, Park SH, Lee JS, Kim AY, Ha HK. Post-Ischemic Bowel Stricture: CT Features in Eight Cases. *Korean J Radiol* 2017; **18**: 936-945 [PMID: [29089826](#) DOI: [10.3348/kjr.2017.18.6.936](#)]



Published by **Baishideng Publishing Group Inc**  
7041 Koll Center Parkway, Suite 160, Pleasanton, CA 94566, USA

**Telephone:** +1-925-3991568

**E-mail:** [bpgoffice@wjgnet.com](mailto:bpgoffice@wjgnet.com)

**Help Desk:** <https://www.f6publishing.com/helpdesk>

<https://www.wjgnet.com>

