

World Journal of *Clinical Cases*

World J Clin Cases 2022 April 26; 10(12): 3639-3968



Contents

Thrice Monthly Volume 10 Number 12 April 26, 2022

EVIDENCE REVIEW

- 3639 Tilt and decentration with various intraocular lenses: A narrative review
Chen XY, Wang YC, Zhao TY, Wang ZZ, Wang W

REVIEW

- 3647 Role of zonula occludens in gastrointestinal and liver cancers
Ram AK, Vairappan B

MINIREVIEWS

- 3662 Pathophysiological mechanisms of hepatic stellate cells activation in liver fibrosis
Garbuzenko DV

ORIGINAL ARTICLE

Retrospective Cohort Study

- 3677 Predictors of unfavorable outcome at 90 days in basilar artery occlusion patients
Chiu YC, Yang JL, Wang WC, Huang HY, Chen WL, Yen PS, Tseng YL, Chen HH, Tsai ST

Retrospective Study

- 3686 Role of multidetector computed tomography in patients with acute infectious colitis
Yu SJ, Heo JH, Choi EJ, Kim JH, Lee HS, Kim SY, Lim JH
- 3698 Efficacy and prognostic factors of neoadjuvant chemotherapy for triple-negative breast cancer
Ding F, Chen RY, Hou J, Guo J, Dong TY
- 3709 Relationship between subgroups of central and lateral lymph node metastasis in clinically node-negative papillary thyroid carcinoma
Zhou J, Li DX, Gao H, Su XL
- 3720 Nomogram to predict postoperative complications in elderly with total hip replacement
Tan XJ, Gu XX, Ge FM, Li ZY, Zhang LQ
- 3729 Flap failure prediction in microvascular tissue reconstruction using machine learning algorithms
Shi YC, Li J, Li SJ, Li ZP, Zhang HJ, Wu ZY, Wu ZY
- Observational Study**
- 3739 Surgery in platinum-resistant recurrent epithelial ovarian carcinoma
Zhao LQ, Gao W, Zhang P, Zhang YL, Fang CY, Shou HF

- 3754** Anorectal dysfunction in patients with mid-low rectal cancer after surgery: A pilot study with three-dimensional high-resolution manometry

Pi YN, Xiao Y, Wang ZF, Lin GL, Qiu HZ, Fang XC

Randomized Controlled Trial

- 3764** Effect of wrist-ankle acupuncture on propofol dosage during painless colonoscopy: A randomized controlled prospective study

He T, Liu C, Lu ZX, Kong LL, Li Y, Xu Z, Dong YJ, Hao W

META-ANALYSIS

- 3773** Melatonin intervention to prevent delirium in hospitalized patients: A meta-analysis

You W, Fan XY, Lei C, Nie CC, Chen Y, Wang XL

- 3787** Risk factors for hospital readmissions in pneumonia patients: A systematic review and meta-analysis

Fang YY, Ni JC, Wang Y, Yu JH, Fu LL

CASE REPORT

- 3801** Anti-programmed death 1 antibody in the treatment of coexistent *Mycobacterium fortuitum* and lung cancer: A case report

Zhang CC, Chen P

- 3808** Acute pancreatitis-induced thrombotic thrombocytopenic purpura: A case report

Wang CH, Jin HF, Liu WG, Guo Y, Liu Z

- 3814** Successful management of life-threatening aortoesophageal fistula: A case report and review of the literature

Zhong XQ, Li GX

- 3822** Isolated coagulopathy without classic CRAB symptoms as the initial manifestation of multiple myeloma: A case report

Zhang Y, Xu F, Wen JJ, Shi L, Zhou QL

- 3828** Evaluation of intracoronary function after reduction of ventricular rate by esmolol in severe stenotic myocardial bridge: A case report

Sun LJ, Yan DG, Huang SW

- 3834** Pediatric living donor liver transplantation using liver allograft after *ex vivo* backtable resection of hemangioma: A case report

Li SX, Tang HN, Lv GY, Chen X

- 3842** Kimura's disease in soft palate with clinical and histopathological presentation: A case report

Li W

- 3849** Combined targeted therapy and immunotherapy in anaplastic thyroid carcinoma with distant metastasis: A case report

Ma DX, Ding XP, Zhang C, Shi P

- 3856** Successful multimodality treatment of metastatic gallbladder cancer: A case report and review of literature
Zhang B, Li S, Liu ZY, Peiris KGK, Song LF, Liu MC, Luo P, Shang D, Bi W
- 3866** Ischemic colitis after receiving the second dose of a COVID-19 inactivated vaccine: A case report
Cui MH, Hou XL, Liu JY
- 3872** Cryoballoon pulmonary vein isolation and left atrial appendage occlusion prior to atrial septal defect closure: A case report
Wu YC, Wang MX, Chen GC, Ruan ZB, Zhang QQ
- 3879** Surgical treatment for a combined anterior cruciate ligament and posterior cruciate ligament avulsion fracture: A case report
Yoshida K, Hakozaki M, Kobayashi H, Kimura M, Konno S
- 3886** Successful robot-assisted partial nephrectomy for giant renal hilum angiomyolipoma through the retroperitoneal approach: A case report
Luo SH, Zeng QS, Chen JX, Huang B, Wang ZR, Li WJ, Yang Y, Chen LW
- 3893** Cryptococcal antigen testing of lung tissue homogenate improves pulmonary cryptococcosis diagnosis: Two case reports
Wang WY, Zheng YL, Jiang LB
- 3899** Combined use of extracorporeal membrane oxygenation with interventional surgery for acute pancreatitis with pulmonary embolism: A case report
Yan LL, Jin XX, Yan XD, Peng JB, Li ZY, He BL
- 3907** Dynamic navigation system-guided trans-inferior alveolar nerve implant placement in the atrophic posterior mandible: A case report
Chen LW, Zhao XE, Yan Q, Xia HB, Sun Q
- 3916** Anti-glomerular basement membrane disease with IgA nephropathy: A case report
Guo C, Ye M, Li S, Zhu TT, Rao XR
- 3923** Amniotic membrane transplantation in a patient with impending perforated corneal ulcer caused by *Streptococcus mitis*: A case report and review of literature
Hsiao FC, Meir YJJ, Yeh LK, Tan HY, Hsiao CH, Ma DHK, Wu WC, Chen HC
- 3930** Steriod for Autoimmune pancreatitis complicating by gastric varices: A case report
Hao NB, Li X, Hu WW, Zhang D, Xie J, Wang XL, Li CZ
- 3936** Antithrombotic treatment strategy for patients with coronary artery ectasia and acute myocardial infarction: A case report
Liu RF, Gao XY, Liang SW, Zhao HQ
- 3944** Mesh plug erosion into the small intestine after inguinal hernia repair: A case report
Xie TH, Wang Q, Ha SN, Cheng SJ, Niu Z, Ren XX, Sun Q, Jin XS
- 3951** Recurrence of infectious mononucleosis in adults after remission for 3 years: A case report
Zhang XY, Teng QB

- 3959** Vertical direction impaction of kissing molars: A case report

Wen C, Jiang R, Zhang ZQ, Lei B, Yan YZ, Zhong YQ, Tang L

LETTER TO THE EDITOR

- 3966** Comment on “Outcomes of different minimally invasive surgical treatments for vertebral compression fractures: An observational study”

Ma L, Luo ZW, Sun YY

ABOUT COVER

Editorial Board Member of *World Journal of Clinical Cases*, Potluri Leela Ravishankar, MDS, Professor, Department of Periodontics, SRM Kattankulathur Dental College and Hospital, SRM University, Chennai 603203, Tamil Nadu, India. plrs6@yahoo.com

AIMS AND SCOPE

The primary aim of *World Journal of Clinical Cases* (WJCC, *World J Clin Cases*) is to provide scholars and readers from various fields of clinical medicine with a platform to publish high-quality clinical research articles and communicate their research findings online.

WJCC mainly publishes articles reporting research results and findings obtained in the field of clinical medicine and covering a wide range of topics, including case control studies, retrospective cohort studies, retrospective studies, clinical trials studies, observational studies, prospective studies, randomized controlled trials, randomized clinical trials, systematic reviews, meta-analysis, and case reports.

INDEXING/ABSTRACTING

The WJCC is now indexed in Science Citation Index Expanded (also known as SciSearch®), Journal Citation Reports/Science Edition, Scopus, PubMed, and PubMed Central. The 2021 Edition of Journal Citation Reports® cites the 2020 impact factor (IF) for WJCC as 1.337; IF without journal self cites: 1.301; 5-year IF: 1.742; Journal Citation Indicator: 0.33; Ranking: 119 among 169 journals in medicine, general and internal; and Quartile category: Q3. The WJCC's CiteScore for 2020 is 0.8 and Scopus CiteScore rank 2020: General Medicine is 493/793.

RESPONSIBLE EDITORS FOR THIS ISSUE

Production Editor: *Ying-Yi Yuan*, Production Department Director: *Xu Guo*, Editorial Office Director: *Jin-Lei Wang*.

NAME OF JOURNAL

World Journal of Clinical Cases

ISSN

ISSN 2307-8960 (online)

LAUNCH DATE

April 16, 2013

FREQUENCY

Thrice Monthly

EDITORS-IN-CHIEF

Bao-Gan Peng, Jerzy Tadeusz Chudek, George Kontogeorgos, Maurizio Serati, Ja Hyeon Ku

EDITORIAL BOARD MEMBERS

<https://www.wjgnet.com/2307-8960/editorialboard.htm>

PUBLICATION DATE

April 26, 2022

COPYRIGHT

© 2022 Baishideng Publishing Group Inc

INSTRUCTIONS TO AUTHORS

<https://www.wjgnet.com/bpg/gerinfo/204>

GUIDELINES FOR ETHICS DOCUMENTS

<https://www.wjgnet.com/bpg/GerInfo/287>

GUIDELINES FOR NON-NATIVE SPEAKERS OF ENGLISH

<https://www.wjgnet.com/bpg/gerinfo/240>

PUBLICATION ETHICS

<https://www.wjgnet.com/bpg/GerInfo/288>

PUBLICATION MISCONDUCT

<https://www.wjgnet.com/bpg/gerinfo/208>

ARTICLE PROCESSING CHARGE

<https://www.wjgnet.com/bpg/gerinfo/242>

STEPS FOR SUBMITTING MANUSCRIPTS

<https://www.wjgnet.com/bpg/GerInfo/239>

ONLINE SUBMISSION

<https://www.f6publishing.com>



Successful management of life-threatening aortoesophageal fistula: A case report and review of the literature

Xue-Qing Zhong, Guo-Xiong Li

Specialty type: Gastroenterology and hepatology

Provenance and peer review: Unsolicited article; Externally peer reviewed.

Peer-review model: Single blind

Peer-review report's scientific quality classification

Grade A (Excellent): 0
Grade B (Very good): 0
Grade C (Good): 0
Grade D (Fair): 0
Grade E (Poor): 0

P-Reviewer: Vosoughi F, Iran

Received: June 23, 2021

Peer-review started: June 23, 2021

First decision: July 16, 2021

Revised: July 30, 2021

Accepted: March 4, 2022

Article in press: March 4, 2022

Published online: April 26, 2022



Xue-Qing Zhong, Guo-Xiong Li, Department of Gastroenterology and Hepatology, Hangzhou Normal University Affiliated Hospital, Hangzhou 310015, Zhejiang Province, China

Xue-Qing Zhong, Medical College, Hangzhou Normal University, Hangzhou 311121, Zhejiang Province, China

Corresponding author: Guo-Xiong Li, MD, Professor, Department of Gastroenterology and Hepatology, Hangzhou Normal University Affiliated Hospital, No.126, Wenzhou Road, Hangzhou 310015, Zhejiang Province, China. guoxiongli849@hotmail.com

Abstract

BACKGROUND

Aortoesophageal fistula (AEF) is a rare but life-threatening cause of upper gastrointestinal bleeding. Only a handful of cases of successful management of AEF caused by esophageal cancer have been reported. The purpose of this study is to report a case of AEF managed by endovascular aortic repair and review the relevant literature.

CASE SUMMARY

A 66-year-old man with upper gastroenterology bleeding presented at the Emergency Department of our hospital complaining of chest pain, fever and hematemesis for 6 h. He had vomited 400 mL of bright-red blood and experienced severe chest pain 6 h prior. He had a past medical history of advanced esophageal cancer. He received chemoradiotherapy but stopped 8 mo prior because of intolerance. A chest contrast computed tomographic scan revealed communication between the esophagus and the descending aorta as well as a descending aortic pseudoaneurysm. According to the symptoms and imaging findings, AEF was our primary consideration. The patient underwent aortic angiography, which indicated AEF and descending aortic pseudoaneurysm. Emergency percutaneous thoracic endovascular aortic repair (TEVAR) of the descending aorta was performed, and bleeding was controlled after TEVAR. He received antibiotics and was discharged after treatment. However, he died 2 mo after the TEVAR due to cancer progression.

CONCLUSION

Although AEF is a lethal condition, timely diagnosis and TEVAR may successfully control bleeding.

Key Words: Upper gastrointestinal bleeding; Aorto-esophageal fistula; Thoracic endovascular aortic repair; Esophageal cancer; Chest pain; Case report

©The Author(s) 2022. Published by Baishideng Publishing Group Inc. All rights reserved.

Core Tip: Aorto-esophageal fistula (AEF) is a rare but life-threatening cause of upper gastrointestinal bleeding. However, only a few cases of successful management of AEF have been reported. Herein, we report the case of a 66-year-old man with life-threatening upper gastroenterology bleeding (UGB) caused by AEF who was successfully treated by thoracic endovascular aortic repair (TEVAR). The bleeding was controlled after TEVAR; he received antibiotics and was discharged. He died 2 mo later due to cancer progression. UGB caused by AEF is a lethal condition, but TEVAR is an effective treatment.

Citation: Zhong XQ, Li GX. Successful management of life-threatening aorto-esophageal fistula: A case report and review of the literature. *World J Clin Cases* 2022; 10(12): 3814-3821

URL: <https://www.wjgnet.com/2307-8960/full/v10/i12/3814.htm>

DOI: <https://dx.doi.org/10.12998/wjcc.v10.i12.3814>

INTRODUCTION

Primary aorto-esophageal fistula (AEF) is communication between the primary aorta and the esophagus. AEF is a rare but lethal cause of upper gastroenterology bleeding (UGB). As there is a significant risk of massive bleeding, sepsis and ultimately death, emergent and aggressive treatment is needed for AEF. Indeed, upper gastrointestinal bleeding in patients caused by malignant AEF is lethal unless immediate treatment is performed[1]. To date, AEF has not been fully described, and no treatment guidelines exist. Despite some studies about AEF caused by advanced esophageal cancer, the management of AEF due to esophageal cancer remains to be explored[2]. Thoracic endovascular aortic repair (TEVAR) is a good treatment for malignant AEF. Here, we present a case of UGB caused by malignant AEF that was successfully controlled by TEVAR. We detected AEF timely manner in this case. We emphasize that contrast-enhanced computer tomography (CT) scans should be performed immediately when a patient with esophageal cancer has hematemesis and chest pain. We searched PubMed for articles related to AEF associated with esophageal cancer written in English and reviewed these cases to gain a further understanding of the disease.

CASE PRESENTATION

Chief complaints

A 66-year-old male patient was admitted to the Emergency Department complaining of hematemesis and chest pain.

History of present illness

The 66-year-old male patient was admitted to the Emergency Department complaining of chest pain, fever and hematemesis for 6 h. He had vomited 400 mL of bright-red blood and experienced severe chest pain 6 h prior. The pain was retrosternal with radiation toward the back. The pain was sharp and could not be relieved. He also had fever as well as progressive dysphagia and weight loss. He did not undergo any surgical procedure to relieve the dysphagia.

History of past illness

The patient had previously been diagnosed with stage III (cT4N1M0) esophageal squamous-cell carcinoma (ESCC) 11 mo prior and was treated with chemoradiotherapy (CRT), including albumin-bound paclitaxel plus a radiation dose of 60 Gy. He stopped radiotherapy 10 mo prior and chemotherapy 8 mo prior because of intolerance. He did not undergo any surgical procedure.

Personal and family history

There was no notable family history.

Physical examination

On initial evaluation, the patient had a temperature of 38.9 °C, a heart rate 110 beats per minute, a

respiratory rate 20 breaths per minute, blood pressure of 92/50 mmHg and oxygen saturation at 98% on room air. The patient was conscious, and he complied with the physical examination. He had no abdominal tenderness. His bowel sounds occurred at a rate of 4 per minute.

Laboratory examinations

Blood analysis revealed mild leukocytosis of $11.11 \times 10^9/L$, with predominant neutrophils (91.4%). The patient's hemoglobin level was 83 g/L, the platelet count was normal, and serum C reactive protein was increased to 242.84 mg/L (normal range < 10.0 mg/L). The prothrombin time was 12.5 s (normal value 10.9 s). The partial thromboplastin time was normal, and d-dimers were increased to 6.42 mg/L FEU (normal range < 0.55 mg/L FEU). Blood urea nitrogen was 9.66 mmol/L (normal range 3.10-8.80 mmol/L).

Imaging examinations

A computed tomographic scan revealed communication between the esophagus and descending aorta as well as a descending aortic pseudoaneurysm (Figure 1). Aortic angiography indicated AEF and descending aortic pseudoaneurysm (Figure 2A and B).

FINAL DIAGNOSIS

The final diagnosis was AEF.

TREATMENT

Following admission to the Emergency Department, the patient immediately received fluid resuscitation. His blood pressure increased to over 90/60 mmHg. Conventionally, AEF is treated by open surgery. However, emergency open surgery has a high mortality of 55.5% for AEF[3]. Because of the unstable hemodynamics of the patient, emergency percutaneous TEVAR of the descending aorta was performed. Aortic angiography showed no aortic pseudoaneurysm or contrast agent leakage after TEVAR (Figure 2C). The bleeding stopped, and his vital signs were stable. The patient refused surgery or gastrostomy after TEVAR. As he had an infection, he received biapenem 0.3 g TID intravenously for 3 wk. He underwent oral fasting and parenteral nutrition treatment for 3 wk. Upon completion of the 3 wk of intravenous antibiotic therapy with biapenem, the patient was discharged from our hospital free of symptoms.

OUTCOME AND FOLLOW-UP

After TEVAR, aorta angiography showed that there was no aortic pseudoaneurysm or contrast agent leakage (Figure 2B). The bleeding was stopped, and his vital signs were stable after TEVAR. Three wk later, he was discharged stably after treatment with antibiotics. He died 2 mo after TEVAR due to cancer progression.

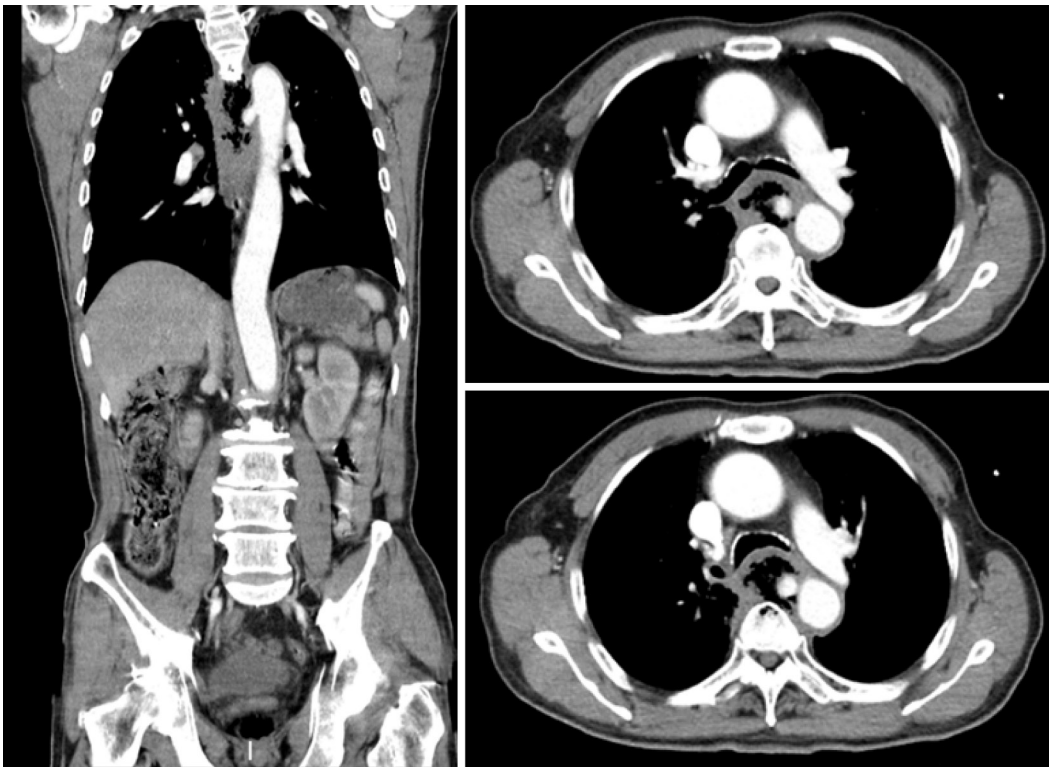
DISCUSSION

AEF is a rare cause of upper gastrointestinal bleeding. The incidence of AEF is approximately 0.07%[4]. However, the mortality of AEF is high[5,6]. The main etiologic factors of AEF include aneurysm (54.2%), foreign body (19.2%) and esophageal cancer (17%)[7,8]. Other causes of AEF include radiotherapy[9,10] and infection[11,12].

The typical sign of AEF is Chiari's triad, which involves mid-thoracic pain, sentinel hemorrhage, and final exsanguination following a symptom-free interval[10]. However, the proportion of AEF patients with Chiari's triad is not high[6].

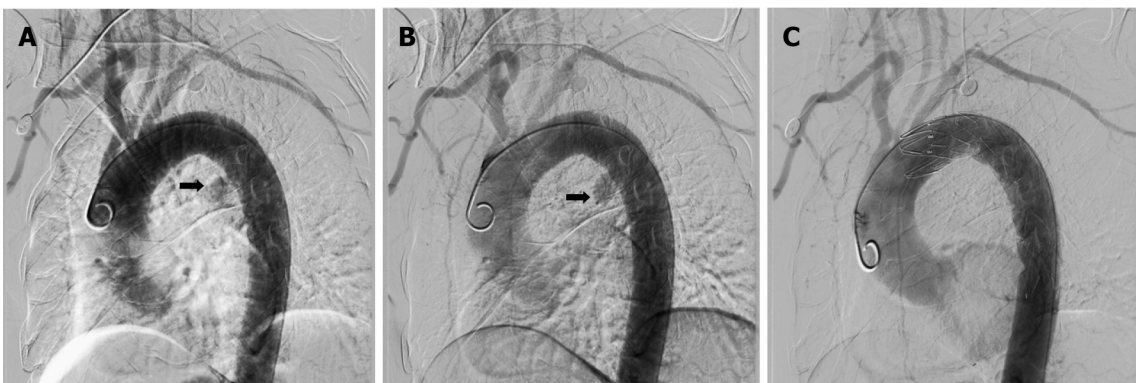
Endoscopy is the first choice for investigating upper gastrointestinal bleeding, but UGB caused by AEF with esophageal cancer cannot always be diagnosed in a timely manner. There is also a risk of dislodging clots and causing fatal bleeding with endoscopy[13]. Previous studies have shown that most patients with stable circulation and an aortic gastrointestinal fistula had undergone gastroscopy, but only approximately 25% were diagnosed with an aortic gastrointestinal fistula in time[6].

Contrast-enhanced CT is very helpful in the diagnosis of aortic esophageal fistula and can clearly show the aorta, aortic mural gas, pseudo aortic fistula, or aortic fistula ruptured into the esophagus. Aortic angiography can diagnose aortic-esophageal fistula at an early stage, and thoracic aortic angiography can show thoracic aortic aneurysms. Contrast agent leaking into the esophagus indicates a



DOI: 10.12998/wjcc.v10.i12.3814 Copyright ©The Author(s) 2022.

Figure 1 computer tomography scan. The descending aortic pseudoaneurysm broke into the esophagus.



DOI: 10.12998/wjcc.v10.i12.3814 Copyright ©The Author(s) 2022.

Figure 2 Aortic angiography. A: There was leakage of contrast in the initial segment of the descending aorta; B: The pseudoaneurysm of the descending aorta; C: The pseudoaneurysm was blocked, and the bleeding was controlled after thoracic endovascular aortic repair.

diagnosis of AEF in a timely fashion. In the present case, an AEF was diagnosed by a contrast-enhanced CT scan at the time of presentation, and aortic angiography confirmed the diagnosis.

In the past 20 years, TEVAR has gradually become the first choice for AEF instead of surgery[2,14,15]. Since Parodi *et al*[16] first reported endovascular stent grafts to treat abdominal aortic aneurysms, this method has developed rapidly. TEVAR can prevent sudden death and gain time for surgical treatment, radiotherapy and chemotherapy[17,18]. To date, TEVAR is the only option for AEF caused by unresectable esophageal cancer[19]. Compared to surgery, TEVAR has many advantages for the treatment of AEF, such as a good hemostatic effect, no need to open the chest, less damage, no aortic clipping, and less cerebral ischemic damage. As Sasaki *et al*[19] reported, TEVAR can extend the survival time by an average of 4 mo for AEF caused by advanced esophageal cancer. Additionally, Mezzetto *et al*[20] performed prophylactic TEVAR in patients with esophageal cancer involving the aorta in preparation for future radiotherapy and chemotherapy. Overall, prophylactic TEVAR may be future trend but still needs more validation.

There are only 12 reports of 19 cases of primary AEF due to esophageal cancer treated by TEVAR in PubMed written in English[1,2,19,21-29]. Table 1 shows the clinical features of the patients in previous

Table 1 Reported cases of aorto-esophageal fistula treated with thoracic endovascular aortic repair in patients with esophageal cancer

Ref.	Age (yr)	Sex	Symptoms	Performed endoscopy	Definitive diagnosis by contrast CT	Location of fistula	Treatment	Cause of death	Prognosis
Kato <i>et al</i> [23]	59	Male	Hematemesis	No	No	DTA	TEVAR	Pneumonia	6 mo, death
Ikeda <i>et al</i> [25]	64	Male	Massive upper intestinal bleeding	No	Yes	DTA	TEVAR	-	6 mo, alive
Feezor <i>et al</i> [27]	48	Male	Hematemesis	No	Yes	DTA	TEVAR	Hemoptysis	3 mo, death
Ghosh <i>et al</i> [26]	47	Male	Hematemesis	Yes	Yes	DTA	TEVAR+ esophageal stent	Cancer	2 mo, death
Ishikawa <i>et al</i> [24]	75	Female	Hematemesis	Yes	No	DTA	TEVAR	Sepsis	5 mo, death
Ishikawa <i>et al</i> [24]	81	Male	Chest discomfort, anorexia	Yes	No	DTA	TEVAR	-	12 mo, alive
Ishikawa <i>et al</i> [24]	66	Female	No symptoms	No	Yes	DTA	TEVAR	-	6 mo, alive
Dorweiler <i>et al</i> [28]	60	Female	Unknown	Unknown	Unknown	Unknown	TEVAR	Cancer cachexia	7 mo, death
Dorweiler <i>et al</i> [28]	71	Male	Unknown	Unknown	Unknown	Unknown	TEVAR	Sepsis	0 mo, death
Dorweiler <i>et al</i> [28]	68	Male	Unknown	Unknown	Unknown	Unknown	TEVAR	Sepsis/pneumonia	3 mo, death
Wong <i>et al</i> [1]	87	Female	Hematemesis	Yes	Yes	DTA	TEVAR	Cancer	3 mo, death
Wong <i>et al</i> [1]	58	Male	Hematemesis	Yes	No	DTA	TEVAR	Cancer	4 mo, death
Nagata <i>et al</i> [22]	58	Male	Hypotension	Yes	Yes	DTA	TEVAR	Cancer	2 mo, death
Sasaki <i>et al</i> [19]	67	Male	Hematemesis	Yes	No	DTA	TEVAR	Cancer	4 mo, death
Iwabu <i>et al</i> [2]	69	Male	Bloody bowel discharge	No	No	DTA	TEVAR	Cancer	7 mo, death
Guerrero <i>et al</i> [21]	69	Male	Hematemesis, chest pain, hypotension	Yes	Yes	DTA	TEVAR	Hematemesis	0 mo, death
Chen <i>et al</i> [29]	55	Male	Hematemesis	Unknown	No	DTA	EMB+TEVAR	Cancer	4 mo, death
Chen <i>et al</i> [29]	53	Male	Hematemesis	Unknown	Yes	DTA	EMB+TEVAR	Cancer	7 mo, death
Chen <i>et al</i> [29]	61	Male	Hematemesis	Unknown	Yes	AA	TEVAR	-	6 mo, alive
Our case	66	Male	Hematemesis and Chest pain	No	Yes	DTA	TEVAR	Cancer	2 mo, death

AEF: Aorto-esophageal fistula; EMB: Embolization of the aortic fistula; DTA: Descending thoracic aorta; AA: Aortic arch; TEVAR: Thoracic endovascular aortic repair.

studies and those of the present case[1,2,19,21-29]. Of these 20 cases, 4 were women and 16 men. Their average age was 64.1 years (range 47-87 years). Most of the patients had hematemesis, and a few of them had chest pain. It is worth noting that a few of the patients had no special symptoms. Seventeen patients underwent enhanced CT. Enhanced CT immediately detected AEF in 10 of the cases (10/17, 58.8%). This indicates that when a patient has hematemesis, an enhanced CT scan should be performed. The location of the fistula was not mentioned for three cases. The fistula in 16 cases was located in the descending thoracic aorta; one was located in the aortic arch. All of these cases were treated with TEVAR. Two cases were treated with embolization of the aortic fistula (EMB) at the same time as TEVAR. One case was treated with an esophageal stent in addition to TEVAR. Among the 20 patients, 2

died on the day of TEVAR, whereas 4 remained alive during follow-up. The average survival time of the patients was 3.68 mo.

In our case, the patient had been diagnosed with unresectable esophageal cancer 11 mo prior. He was admitted to our hospital because of hematemesis and chest pain. His vital signs were not stable, with hypotension and fever. Contrast-enhanced CT was performed immediately on the admission, and the patient was diagnosed with AEF according to the results. Endoscopy is known to be the most sensitive and specific method for the diagnosis of UGB, though there is a risk of precipitating fatal hemorrhage in AEF[30]. As the patient was diagnosed with AEF by a contrast-enhanced CT scan, we did not perform endoscopy. We performed successful emergent TEVAR because of the patient's hemodynamic instability and stopped his upper gastrointestinal bleeding. Coselli *et al*[31] reported that among patients with AEF, 60% died within the first 6 h when hematemesis began[29]. Management of patients with AEF requires accurate diagnosis in a timely manner[29]. In our case, timely diagnosis ensured prompt treatment and a good treatment effect. Overall, the importance of immediate contrast-enhanced CT scans for patients with AEF must be emphasized. Our patient underwent endoscopy 8 d after TEVAR, revealing esophageal stricture but no other sources of bleeding. Esophageal stent placement and gastrostomy were recommended, but the patient refused. The patient also refused surgery or gastrostomy after TEVAR. As previous studies report that long-term antibiotic treatment is necessary, the patient received antibiotic treatment for 3 wk until discharge from our hospital. Although he died 2 mo later due to cancer progression, TEVAR prevented his sudden death. This case indicates that TEVAR is effective for the treatment of AEF.

As previously reported, chemoradiotherapy is a major cause of AEF[32,33], and doses higher than 35 Gy are an important factor causing AEF[28,33]. In a retrospective study involving 116 patients, Kawakami *et al*[34] reported that CRP ≥ 1.00 mg/dL is a risk factor for esophageal fistula in ESCC treated with CRT. Thus, cancer inflammation is a factor for fistula development[35]. In the present case, the patient underwent chemoradiotherapy. He had fever, and his CRP level was high. AEF in this patient may be attributed to tumor invasion into the aorta, chemoradiotherapy and/or inflammation.

A patient with AEF may die due to infection, even when TEVAR is performed[23,24,28], and prevention of infection is a challenge after TEVAR. Some studies have suggested lifelong antibiotic suppression, which has many side effects, such as gut dysbiosis. At present, some antimicrobial coatings on the surface of biliary stents have been designed and found to be effective[36]. Additional studies are needed to explore whether antimicrobial coatings on the surface of stents can be applied in TEVAR. In summary, we should perform contrast-CT scans if a patient with esophageal cancer is vomiting bright-red blood or has chest pain, especially those with hemodynamic instability. When AEF is suspected, TEVAR should be performed without endoscopy. TEVAR is effective for AEF caused by esophageal cancer. Additional studies are needed to explore how to prevent infection after TEVAR.

CONCLUSION

Successful management of AEF is rare. Patients who have hematemesis with esophageal cancer should undergo contrast-CT scans in a timely manner. Timely diagnosis of AEF is very important. TEVAR is effective for AEF caused by esophageal cancer. Infection is a challenge after TEVAR.

FOOTNOTES

Author contributions: Zhong XQ was the patient's doctor, reviewed the literature and contributed to manuscript draft; Li GX reviewed the literature and contributed to manuscript draft; Both authors issued final approval for the version to be submitted.

Supported by the Natural Science Foundation of Zhejiang Province (No. LQ19H030002).

Informed consent statement: As the patient died, the patient's son informed consent.

Conflict-of-interest statement: The authors declare that they have no conflicts of interest.

CARE Checklist (2016) statement: The authors have read the CARE Checklist (2016), and the manuscript was prepared and revised according to the CARE Checklist (2016).

Open-Access: This article is an open-access article that was selected by an in-house editor and fully peer-reviewed by external reviewers. It is distributed in accordance with the Creative Commons Attribution NonCommercial (CC BY-NC 4.0) license, which permits others to distribute, remix, adapt, build upon this work non-commercially, and license their derivative works on different terms, provided the original work is properly cited and the use is non-commercial. See: <https://creativecommons.org/licenses/by-nc/4.0/>

Country/Territory of origin: China

ORCID number: Xue-Qing Zhong 0000-0003-4105-3101; Guo-Xiong Li 0000-0002-6132-4522.

S-Editor: Chang KL

L-Editor: A

P-Editor: Chang KL

REFERENCES

- 1 **Wong PC**, Chan YC, Law Y, Keung Cheng SW. Emergency aortic stent-graft treatment for malignant aorto-esophageal fistula. *Asian Cardiovasc Thorac Ann* 2017; **25**: 649-652 [PMID: 29096524 DOI: 10.1177/0218492317741788]
- 2 **Iwabu J**, Namikawa T, Yokota K, Kitagawa H, Kihara K, Hirose N, Hanazaki K. Successful management of aorto-esophageal fistula caused by esophageal cancer using thoracic endovascular aortic repair. *Clin J Gastroenterol* 2020; **13**: 678-682 [PMID: 32449088 DOI: 10.1007/s12328-020-01132-5]
- 3 **Kieffer E**, Chiche L, Gomes D. Aorto-esophageal fistula: value of in situ aortic allograft replacement. *Ann Surg* 2003; **238**: 283-290 [PMID: 12894023 DOI: 10.1097/01.sla.0000080828.37493.e0]
- 4 **Voorhoeve R**, Moll FL, de Letter JA, Bast TJ, Wester JP, Slee PH. Primary aortoenteric fistula: report of eight new cases and review of the literature. *Ann Vasc Surg* 1996; **10**: 40-48 [PMID: 8688296 DOI: 10.1007/BF02002340]
- 5 **Saha BK**. Few and Far Between: A Case of Aorto-esophageal Fistula in Locally Advanced Esophageal Cancer. *Am J Med Sci* 2021; **361**: e3-e4 [PMID: 32631579 DOI: 10.1016/j.amjms.2020.06.010]
- 6 **Saers SJ**, Scheltinga MR. Primary aortoenteric fistula. *Br J Surg* 2005; **92**: 143-152 [PMID: 15685700 DOI: 10.1002/bjs.4928]
- 7 **Hollander JE**, Quick G. Aorto-esophageal fistula: a comprehensive review of the literature. *Am J Med* 1991; **91**: 279-287 [PMID: 1892150 DOI: 10.1016/0002-9343(91)90129-I]
- 8 **Xi EP**, Zhu J, Zhu SB, Liu Y, Yin GL, Zhang Y, Zhang XM, Dong YQ. Surgical treatment of aorto-esophageal fistula induced by a foreign body in the esophagus: 40 years of experience at a single hospital. *Surg Endosc* 2013; **27**: 3412-3416 [PMID: 23529574 DOI: 10.1007/s00464-013-2926-3]
- 9 **Sivaraman SK**, Drummond R. Radiation-induced aorto-esophageal fistula: an unusual case of massive upper gastrointestinal bleeding. *J Emerg Med* 2002; **23**: 175-178 [PMID: 12359287 DOI: 10.1016/s0736-4679(02)00488-2]
- 10 **Kawaguchi Y**, Fu K, Morimoto T, Shimizu T, Izumi Y, Kawabe M, Miyazaki A. Aorto-esophageal fistula after radiation therapy for esophageal cancer (with video). *Gastrointest Endosc* 2011; **74**: 922; discussion 922-922; discussion 923 [PMID: 21855871 DOI: 10.1016/j.gie.2011.06.010]
- 11 **Lee OJ**, Kim SH. Aorto-esophageal fistula associated with tuberculous mediastinitis, mimicking esophageal Dieulafoy's disease. *J Korean Med Sci* 2002; **17**: 266-269 [PMID: 11961316 DOI: 10.3346/jkms.2002.17.2.266]
- 12 **Shin HK**, Choi CW, Lim JW, Her K. Two-stage Surgery for an Aorto-esophageal Fistula Caused by Tuberculous Esophagitis. *J Korean Med Sci* 2015; **30**: 1706-1709 [PMID: 26539019 DOI: 10.3346/jkms.2015.30.11.1706]
- 13 **McGinnis GJ**, Holland JM, Thomas CR, Jr., Nabavizadeh N. Massive hemorrhage following definitive esophageal chemoradiation: Teaching case of a fatal aorto-esophageal fistula and lessons learned. *Clin Case Rep* 2017; **5**: 2074-2079 [DOI: 10.1002/ccr3.1239]
- 14 **Takeno S**, Ishii H, Nanashima A, Nakamura K. Aorto-esophageal fistula: review of trends in the last decade. *Surg Today* 2020; **50**: 1551-1559 [PMID: 31844987 DOI: 10.1007/s00595-019-01937-z]
- 15 **Lichtenstein JB**, Brar HS, Wang C, Lei L, Zhang W, Fan X. An aorto-oesophageal fistula treated with total arch repair combined with oesophageal repair. *Interact Cardiovasc Thorac Surg* 2021 [DOI: 10.1093/icvts/ivab038]
- 16 **Parodi JC**, Criado FJ, Barone HD, Schönholz C, Queral LA. Endoluminal aortic aneurysm repair using a balloon-expandable stent-graft device: a progress report. *Ann Vasc Surg* 1994; **8**: 523-529 [PMID: 7865389 DOI: 10.1007/BF02017407]
- 17 **Sinclair EM**, Stevens JP, McElhanon B, Meisel JA, Santore MT, Chahine AA, Riedesel EL. Development and repair of aorto-esophageal fistula following esophageal button battery impaction: A case report. *J Pediatr Surg Case Rep* 2021; **66** [PMID: 33767967 DOI: 10.1016/j.epsc.2021.101782]
- 18 **Yadav A**, Shrestha UK, Shrestha KR, Gurung D. Thoracic aortic aneurysm causing aorto-esophageal fistula-our experience with a rare disease. *J Surg Case Rep* 2020; **2020**: rjaa242 [PMID: 32728417 DOI: 10.1093/jscr/rjaa242]
- 19 **Sasaki A**, Egashira H, Tokoro S, Ichita C, Takizawa S, Tsukiyama T, Ogino H, Kawachi J, Shimoyama R, Kako M. Thoracic Endovascular Aortic Repair of Esophageal Cancer-Associated Aorto-esophageal Fistula: A Case Report and Literature Review. *Case Rep Oncol Med* 2018; **2018**: 9851397 [PMID: 30662781 DOI: 10.1155/2018/9851397]
- 20 **Mezzetto L**, Scorsone L, De Pasqual CA, Weindelmayer J, Giacomuzzi S, de Manzoni G, Veraldi GF. Preliminary Experience with Prophylactic Thoracic Endovascular Aortic Repair in Patients Affected by Advanced Esophageal Cancer. *Ann Vasc Surg* 2019; **61**: 142-147 [PMID: 31394222 DOI: 10.1016/j.avsg.2019.05.066]
- 21 **Guerrero I**, Cuenca JA, Cardenas YR, Nates JL. Hemorrhagic Shock Secondary to Aorto-esophageal Fistula as a Complication of Esophageal Cancer. *Cureus* 2020; **12**: e7146 [PMID: 32257691 DOI: 10.7759/cureus.7146]
- 22 **Nagata T**, Wang Y, Asanuma M. Emergency thoracic aortic stent grafting for aorto-esophageal fistula in advanced esophageal cancer. *J Card Surg* 2017; **32**: 650-651 [PMID: 29027268 DOI: 10.1111/jocs.13218]
- 23 **Kato N**, Tadanori H, Tanaka K, Yasuda F, Iwata M, Kawarada Y, Yada I, Takeda K. Aorto-esophageal fistula-relief of massive hematemesis with an endovascular stent-graft. *Eur J Radiol* 2000; **34**: 63-66 [PMID: 10802211 DOI: 10.1016/s0720-048x(99)00107-2]
- 24 **Ishikawa N**, Maruta K, Oi M, Iizuka H, Kawaura H, Omoto T. Thoracic endovascular repair for aorto-esophageal fistula in patients with esophageal carcinoma: report of 3 cases. *Vasc Endovascular Surg* 2013; **47**: 65-69 [PMID: 23223179 DOI: 10.1177/1538574412467858]

- 25 **Ikedo Y**, Morita N, Kurihara H, Niimi M, Okinaga K. A primary aorto-esophageal fistula due to esophageal carcinoma successfully treated with endoluminal aortic stent grafting. *J Thorac Cardiovasc Surg* 2006; **131**: 486-487 [PMID: 16434290 DOI: 10.1016/j.jtcvs.2005.08.042]
- 26 **Ghosh SK**, Rahman FZ, Bown S, Harris P, Fong K, Langmead L. Survival following Treatment of Aorto-esophageal Fistula with Dual Esophageal and Aortic Intervention. *Case Rep Gastroenterol* 2011; **5**: 40-44 [PMID: 21326857 DOI: 10.1159/000323700]
- 27 **Feezor RJ**, Hess PJ, Lee WA. Endovascular treatment of a malignant aorto-esophageal fistula. *J Vasc Surg* 2009; **49**: 778 [PMID: 19268781 DOI: 10.1016/j.jvs.2008.05.066]
- 28 **Dorweiler B**, Weigang E, Duenschede F, Pitton MB, Dueber C, Vahl CF. Strategies for endovascular aortic repair in aortobronchial and aorto-esophageal fistulas. *Thorac Cardiovasc Surg* 2013; **61**: 575-580 [PMID: 23828238 DOI: 10.1055/s-0033-1347294]
- 29 **Chen C**, Kim JW, Shin JH, Kwon Y, Kim J, Lee IJ. Management of life-threatening aorto-esophageal fistula: experiences learned from eight patients. *Acta Radiol* 2021; **62**: 447-452 [PMID: 32551870 DOI: 10.1177/0284185120933228]
- 30 **Benson MJ**, Rouse D, van Someren N, Wingate DL, Swain CP. Fatal hemorrhage from an aorto-esophageal fistula precipitated by flexible endoscopy. *Gastrointest Endosc* 1991; **37**: 193-196 [PMID: 2032609 DOI: 10.1016/s0016-5107(91)70686-x]
- 31 **Coselli JS**, Crawford ES. Primary aorto-esophageal fistula from aortic aneurysm: successful surgical treatment by use of omental pedicle graft. *J Vasc Surg* 1990; **12**: 269-277 [PMID: 2144597]
- 32 **Flores J**, Shiiya N, Kuniyama T, Yoshimoto K, Yasuda K. Aorto-esophageal fistula: alternatives of treatment case report and literature review. *Ann Thorac Cardiovasc Surg* 2004; **10**: 241-246 [PMID: 15458376]
- 33 **Parikh MP**, Sherid M, Panginikkod S, Rawal HA, Gopalakrishnan V. Radiation therapy-induced aorto-esophageal fistula: a case report and review of literature. *Gastroenterol Rep (Oxf)* 2016; **4**: 165-167 [PMID: 25381204 DOI: 10.1093/gastro/gou081]
- 34 **Kawakami T**, Tsushima T, Omae K, Ogawa H, Shirasu H, Kito Y, Yoshida Y, Hamauchi S, Todaka A, Machida N, Yokota T, Yamazaki K, Fukutomi A, Onozawa Y, Yasui H. Risk factors for esophageal fistula in thoracic esophageal squamous cell carcinoma invading adjacent organs treated with definitive chemoradiotherapy: a monocentric case-control study. *BMC Cancer* 2018; **18**: 573 [PMID: 29776344 DOI: 10.1186/s12885-018-4486-3]
- 35 **Mantovani A**, Allavena P, Sica A, Balkwill F. Cancer-related inflammation. *Nature* 2008; **454**: 436-444 [PMID: 18650914 DOI: 10.1038/nature07205]
- 36 **Obermeier A**, Würstle S, Tübel J, Stolte P, Feihl S, Lipovcic N, Lanzinger S, Mühlhofer H, Weber A, Schmid RM, Burgkart R, Schneider J. Novel antimicrobial coatings based on polylactide for plastic biliary stents to prevent post-endoscopic retrograde cholangiography cholangitis. *J Antimicrob Chemother* 2019; **74**: 1911-1920 [PMID: 30993324 DOI: 10.1093/jac/dkz128]



Published by **Baishideng Publishing Group Inc**
7041 Koll Center Parkway, Suite 160, Pleasanton, CA 94566, USA

Telephone: +1-925-3991568

E-mail: bpgoffice@wjgnet.com

Help Desk: <https://www.f6publishing.com/helpdesk>

<https://www.wjgnet.com>

