

Name of Journal: *World Journal of Gastroenterology*

Manuscript NO: 69815

Manuscript Title: Severe tinnitus and migraine headache in a 37-year-old woman treated with trastuzumab for breast cancer: A case report

Dear editors:

Thank you for your kind letter and for the reviewers' constructive comments concerning our manuscript. These comments are all valuable and helpful for improving our article. Based on the comments we received, careful modifications have been made to the original manuscript. According to the comments of Reviewer 2, we have changed the title of the manuscript from "Severe tinnitus and migraine headache in a 37-year-old woman treated with trastuzumab" to "Severe tinnitus and migraine headache in a 37-year-old woman treated with trastuzumab for breast cancer: A case report". We have uploaded the revised manuscript for your further assessment. Below, we present an itemized response to each comment.

We look forward to hearing from you regarding our submission. We would be glad to respond to any further questions and comments that you may have.

Thank you and best regards.

Sincerely,

Corresponding author: **Yong-Zhi Liu**, MD,

Department of Breast Surgery

General Hospital of Benxi Iron & Steel Industry

Group of Liaoning Health Industry Group, Benxi 117000, China

Phone: +86-15804142064

E-mail: jackdemi@163.com

Reviewer #1:

Scientific Quality: Grade B (Very good)

Language Quality: Grade A (Priority publishing)

Conclusion: Accept (General priority)

Specific Comments to Authors: Title reflect the main subject of the manuscript. Abstract summarize and reflect the work described in the manuscript. The key words reflect the focus of the manuscript. Background adequately describe the manuscript, present status and significance of the study. The manuscript describe the clinical case in adequate detail. The manuscript interpret the findings adequately, concisely, clearly, logically and appropriately, being conscient of its limitations (only one case studied) The findings and their applicability or relevance to the literature are stated in a clear and definite manner. Discussion is accurate and sufficient to explain the scientific significance and relevance to clinical practice. The manuscript does not need biostatistics of use of SI units. The references are cited appropriately, but the most recent reference is from 2014, 7 years ago, and the others are from 2009 and more long-standing but not out-of-date so I think it would be better if the manuscript includes some more recent references, but it is not a key point because the references included are important and authoritative. The authors do not self-cite, omit, incorrectly cite and/or over-cite references. The style, language and grammar are accurate and appropriate, and in general, the manuscript is concisely and coherently presented and organized.

Response: Thank you for your kind letter and we have revised our manuscript and figures.

Reviewer #2:

Scientific Quality: Grade B (Very good)

Language Quality: Grade B (Minor language polishing)

Conclusion: Minor revision

Specific Comments to Authors: The article presents an interesting case of a rare side effect of the commonly used drug in breast cancer therapy.

Response: We sincerely appreciate the reviewer for the constructive comments and helpful suggestions, which have significantly improved our work. Below please find our response to each of these comments.

Comment #1: *Title: 1) Not clear enough, I recommend (Severe tinnitus and migraine headache in a 37-year-old woman treated with trastuzumab for breast cancer)*

Response: We thank the reviewer for this comment.

We have changed the title of the manuscript from “**Severe tinnitus and migraine headache in a 37-year-old woman treated with trastuzumab**” to “**Severe tinnitus and migraine headache in a 37-year-old woman treated with trastuzumab for breast cancer: A case report**”.

Comment #2: *ABSTRACT 2)Case summary: “A 37-year-old young “ no need for the word (young).*

Response: We have changed the sentence from “A 37-year-old young woman...” to “A 37-year-old woman...”

Comment #3: *CASE PRESENTATION 3)“A 37-year-old Chinese young woman was diagnosed with hormone receptor-positive and HER2-positive invasive ductal cancer in her left breast” Replace by: (A 37-year-old Chinese woman was diagnosed as hormone receptor-positive and HER2-positive infiltrating duct carcinoma in her left breast).*

Response: We appreciate the encouraging remarks and valuable comments of the reviewer. We have changed the sentence from “A 37-year-old Chinese young woman was diagnosed with hormone receptor-positive and HER2-positive invasive ductal cancer in her left breast” to “A 37-year-old Chinese woman was diagnosed as hormone receptor-positive and HER2-positive infiltrating duct carcinoma in her left breast”.

Comment #4: *History of past illness: What about ENT past history and history of migraine?*

Response: We thank the reviewer for this insightful comment, which prompted us to reconsider this section. The text in the *History of past illness* section has been modified accordingly:

Our modification: The patient’s prior medical history was unremarkable. The patient

did not demonstrate any history of drug allergies and had no history of ear, nose, and throat (ENT), migraine or other central nervous system diseases.

Comment #5,6: *5)Physical examination: what you mentioned here is confusing. 6)You can exclude physical laboratory and imaging examination sections and replace this by the gross features under the section of diagnosis. No significance of describing those examination features before surgery.*

Response: We sincerely thank the reviewer for pointing this out.

Our modification:

Physical examination upon admission

A physical examination of the patient revealed a 1.0 cm × 1.0 cm non-tender mass in the upper outer quadrant of the left breast. Her physical examination confirmed no signs of ENT diseases, central nervous system diseases or cerebral metastasis. And she had a body mass index (BMI) of 30.4.

Laboratory examinations

Laboratory examinations (routine blood analysis, liver biochemical analysis, renal function, tumor markers, etc.) were normal.

Imaging examinations

The patient's lungs, bones and liver were normal. Imaging examination did not demonstrate any evidence of distant metastases. A cerebral magnetic resonance imaging (MRI) scan revealed no sign of intracranial or skeletal cranial metastases or any vascular disorders.

Comment #7: *7) Treatment: "No other abnormalities were observed": what does it mean?*

Response: We deleted this sentence.

Comment #8: *DISCUSSION 8) "The first case was reported in 2003 by Keiichiro Tada et al" Remove "Keiichiro" and the same for Frank G. van Rooij et al.*

Response: As pointed out by the reviewer, we have changed the sentences to "The first case of trastuzumab-related strictly unilateral headache was reported in 2003: a 59-year-old patient experienced severe headache, back pain, fatigue, and a decrease in blood

pressure after trastuzumab administration. The second case of trastuzumab-induced throbbing headache was reported in 2009. A 31-year-old woman experienced a very strictly unilateral headache with photophobia, nausea, and vomiting following infusion of trastuzumab.”

Comment #9: *Try to discuss the “tinnitus and migraine” coming together in other conditions other than adverse reactions of trastuzumab, because yet little is known on how headaches impact tinnitus but some literatures studied this relationship.*

Response: We greatly appreciate the reviewer for this thought-provoking question. We have modified the text in the Discussion section (paragraph 4,5: in revised main text)

“...Tinnitus is a subjective complaint defined as a sound in the head or ears that occurs in the absence of any external acoustical source. Studies report tinnitus prevalence ranging from 5.1–42.7% by different age groups and generally showing an increase in prevalence as age increases. Young adults with migraines are more likely to suffer from tinnitus ^[10]. There is limited knowledge of direct biological links between migraine and tinnitus. One cross-sectional study showed that headache was associated with tinnitus, and the association was stronger for individuals reporting migraine with aura ^[11]. Ear injuries, central sensitization, and visual snow can cause tinnitus and may be related to the occurrence of migraines ^[12,13]. Migraine, tinnitus, anxiety and depression are prevalently comorbid disorders and have been frequently reported in patients with visual snow. Visual snow may start during or shortly after migrant aura. One theory suggests that there is a bidirectional relationship among depression, visual snow and migraine ^[14]. But in this case, the young patient did not have any past histories and clinical symptoms in the later following-up.

Studies suggest that ototoxicity is a possible adverse effect during treatment with taxanes^[15]. Although Sarafranz and Ahmadi ^[16] did not observe tinnitus or hearing loss as the significant side-effects of taxanes, Xuan L *et al.* ^[17]

presented two cases of ototoxicity caused by docetaxel-based chemotherapy regimens and speculated that docetaxel may result in degeneration of nerve fibers through disrupted axon transportation. They also suggest that clinicians note the adverse effect on the audiovestibular system caused by neurotoxic chemotherapy ^[17] ...”

Conclusion 10) “It reminds us to the awareness of adverse reactions” complete the sentence (eg. adverse reactions of the breast cancer drugs”

Response: we have changed the sentences to “This case report serves as a reminder to be aware of adverse reactions of the breast cancer drugs.”

EDITORIAL OFFICE’S COMMENTS

1. Scientific quality: Grade B: Very good and Grade B: Very good
2. Scientific quality: Grade B: Very good and Grade B: Very good Although is a very interesting manuscript. I found several issues according to peer-review evaluation: References are outdated and not reasonable for case report. The list of references are not reasonable for a brief case report. A total of 18 references are cited, none in last 3 years. Figure does not reflect the focus of case report (just a picture of FISH HER2 report instead of a nurse report of symptoms about vital signs, trastuzumab vial or cerebral MRI, for example). Discussion is too shortly. There is no discussion about the use of pertuzumab (another HER2-targeted therapy). If patient presented sudden tinnitus, an expect conduct is to avoid using of pertuzumab in order to avoid or increase reactions. Also, docetaxel could be related with the reaction (neuropathy, tinnitus), there is no discussion about the adverse effects and possible reactions with taxanes.

Response:

We tried our best to revised the article according to the editors. We thank the reviewers for bringing these important issues to our attention. We have included several references in revised main text. Below, please find our response to each of these points.

Our modification: (INTRODUCTION: in revised main text)

1. “...is the first HER2-targeted therapy approved for the treatment of HER2-

positive breast cancer^[1].”

2. “Ear injuries, central sensitization, and visual snow can cause tinnitus and may be related to the occurrence of migraines^[12,13].”
3. “Visual snow may start during or shortly after migrant aura. One theory suggests that there is a bidirectional relationship among depression, visual snow and migraine^[14].”
4. “Studies suggest that ototoxicity is a possible adverse effect during treatment with taxanes^[15]. Although Sarafranz and Ahmadi^[16] did not observe tinnitus or hearing loss as the significant side-effects of taxanes, Xuan L et al.^[17] presented two cases of ototoxicity caused by docetaxel-based chemotherapy regimens and speculated that docetaxel may result in degeneration of nerve fibers through disrupted axon transportation. They also suggest that clinicians note the adverse effect on the audiovestibular system caused by neurotoxic chemotherapy^[17]. “

(REFERENCES: in revised main text)

1. **Gradishar WJ**, Moran MS, Abraham J, Aft R, Agnese D, Allison KH, Blair SL, Burstein HJ, Dang C, Elias AD, Giordano SH, Goetz MP, Goldstein LJ, Hurvitz SA, Isakoff SJ, Jankowitz RC, Javid SH, Krishnamurthy J, Leitch M, Lyons J, Mastro J, Mayer IA, Mortimer J, O'Regan RM, Patel SA, Pierce LJ, Rugo HS, Sitapati A, Smith KL, Smith ML, Soliman H, Stringer Reasor EM, Telli ML, Ward JH, Wisinski KB, Young JS, Burns JL, Kumar R. NCCN Guidelines® Insights: Breast Cancer, Version 4.2021. J Natl Compr Canc Netw. 2021 May 1;19(5):484-493 [PMID: [34030128](#) DOI: [10.6004/jnccn.2021.0023](#)]

DOI: [10.1155/2015/797416](#)]

13. **García A**, Madrigal J, Castillo M. Vestibular Migraine and Tinnitus: A Challenging Narrative. Cureus. 2021 Jun 28;13(6):e15998. [PMID: [34336489](#) DOI: [10.7759/cureus.15998](#)]

14. **Lugo A**, Edvall NK, Lazar A, Mehraei G, LopezEscamez JA, Bulla J, Uhlen I, Canlon B, Gallus S, Cederroth CR. Relationship between headaches and tinnitus in a Swedish study. Sci Rep. 2020 May 22;10(1):8494. [PMID: [32444677](#) DOI: [10.1038/s41598-020-65395-1](#)]

17. **Xuan L**, Sun B, Meng X, Liu C, Cong Y, Wu S. Ototoxicity in patients with invasive ductal breast cancer who were treated with docetaxel: report of two cases. Cancer Biol Ther 2020 11 01;21(11). [PMID: [33121320](#) DOI: [10.1080/15384047.2020.1831370](#)]

Our modification: (Figure 1: in revised main text)

Figure Legends

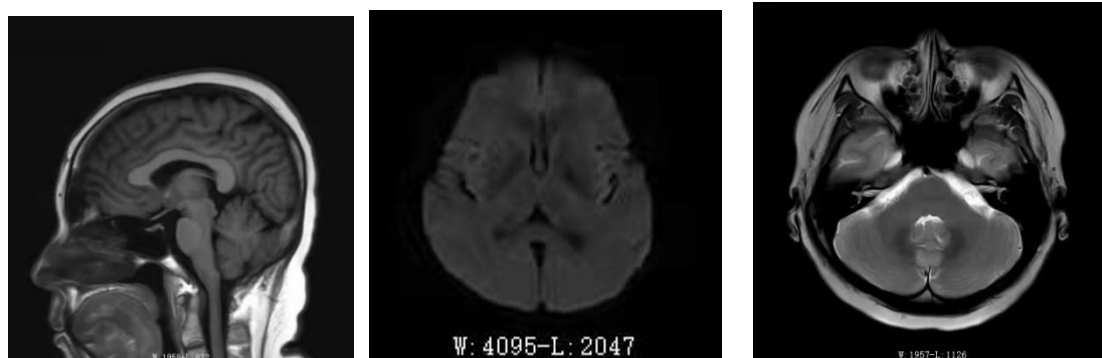


Figure 1 Brain magnetic resonance images of the patient. A: Axial view of T1-weighted image shows no brain dysplasia, encephalomalacia or abnormal white matter signal; B: Diffusion-weighted image shows no abnormal signals; C: T2-weighted scan shows that the bilateral internal auditory canal, cochlear, auditory and cranial nerve have no abnormal signals.

Our modification: (TREATMENT, DISCUSSION: in revised main text)

“The premedication agent (dexamethasone; 8 mg every 12 h for three doses beginning 12 h before administration of docetaxel) was administered before docetaxel to decrease the occurrences of anaphylactic reactions (ARs). Because ARs have been frequently reported with taxanes, drug administration occurred in the order of trastuzumab, pertuzumab and docetaxel.”

“Multidisciplinary team members carefully assessed, communicated and informed the patient of appropriate treatment benefit and risk. Subsequently, pertuzumab (840 mg) and docetaxel (100 mg/kg) therapy was initiated, and no adverse events were observed.”

“Tinnitus is a subjective complaint defined as a sound in the head or ears that occurs in the absence of any external acoustical source. Studies report tinnitus prevalence ranging from 5.1–42.7% by different age groups and generally showing an increase in prevalence as age increases. Young adults with migraines are more likely to suffer from tinnitus^[10]. There is limited knowledge of direct biological links between migraine and tinnitus. One cross-sectional study showed that headache was associated

with tinnitus, and the association was stronger for individuals reporting migraine with aura ^[11]. Ear injuries, central sensitization, and visual snow can cause tinnitus and may be related to the occurrence of migraines ^[12,13]. Migraine, tinnitus, anxiety and depression are prevalently comorbid disorders and have been frequently reported in patients with visual snow. Visual snow may start during or shortly after migrant aura. One theory suggests that there is a bidirectional relationship among depression, visual snow and migraine ^[14]. But in this case, the young patient did not have any past histories and clinical symptoms in the later following-up.”

“Studies suggest that ototoxicity is a possible adverse effect during treatment with taxanes^[15]. Although Sarafraz and Ahmadi ^[16] did not observe tinnitus or hearing loss as the significant side-effects of taxanes, Xuan L *et al.* ^[17] presented two cases of ototoxicity caused by docetaxel-based chemotherapy regimens and speculated that docetaxel may result in degeneration of nerve fibers through disrupted axon transportation. They also suggest that clinicians note the adverse effect on the audiovestibular system caused by neurotoxic chemotherapy ^[17].”