

# World Journal of *Clinical Cases*

*World J Clin Cases* 2022 March 26; 10(9): 2660-2975



## Contents

Thrice Monthly Volume 10 Number 9 March 26, 2022

## REVIEW

- 2660 Role of metabolites derived from gut microbiota in inflammatory bowel disease  
*Zheng L, Wen XL, Duan SL*

## MINIREVIEWS

- 2678 Roles of Wnt/ $\beta$ -catenin signaling pathway related microRNAs in esophageal cancer  
*Chu CY, Wang R, Liu XL*
- 2687 Animal models applied to acute-on-chronic liver failure: Are new models required to understand the human condition?  
*Gama JFG, Cardoso LMDF, Lagrota-Candido JM, Alves LA*

## ORIGINAL ARTICLE

## Case Control Study

- 2700 Associations between coagulation factor XII, coagulation factor XI, and stability of venous thromboembolism: A case-control study  
*Meng Y, Li Y, Ye YJ, Ma Q, Zhang JB, Qin H, Deng YY, Tian HY*

## Retrospective Cohort Study

- 2710 Nomogram to predict the risk of endoscopic removal failure with forceps/baskets for treating submandibular stones  
*Huang Y, Liang PS, Yang YC, Cai WX, Tao Q*
- 2721 Association between anesthesia technique and complications after hip surgery in the elderly population  
*Guo LS, Wang LN, Xiao JB, Zhong M, Zhao GF*

## Retrospective Study

- 2733 Perforating and nonperforating indications in repeated surgeries for Crohn's disease  
*Shen WS, Huang XH, Liu RQ, Li CY, Li Y, Zhu WM*
- 2743 Treatment of *Pneumocystis jirovecii* pneumonia in non-human immunodeficiency virus-infected patients using a combination of trimethoprim-sulfamethoxazole and caspofungin  
*Wu HH, Fang SY, Chen YX, Feng LF*
- 2751 Acute kidney injury in traumatic brain injury intensive care unit patients  
*Huang ZY, Liu Y, Huang HF, Huang SH, Wang JX, Tian JF, Zeng WX, Lv RG, Jiang S, Gao JL, Gao Y, Yu XX*
- 2764 Enucleation combined with guided bone regeneration in small and medium-sized odontogenic jaw cysts  
*Cao YT, Gu QH, Wang YW, Jiang Q*

**Clinical Trials Study**

- 2773 Determination of the ED<sub>95</sub> of intranasal sufentanil combined with intranasal dexmedetomidine for moderate sedation during endoscopic ultrasonography

*Zou Y, Li N, Shao LJZ, Liu FK, Xue FS, Tao X*

**Observational Study**

- 2783 Overexpression of Ubiquilin4 is associated with poor prognosis in patients with cervical cancer

*Wang LN, Huang KJ, Wang L, Cheng HY*

**Randomized Clinical Trial**

- 2792 Peplau's interpersonal relationship theory combined with bladder function training on patients with prostate cancer

*Yang XH, Wu LF, Yan XY, Zhou Y, Liu X*

**SYSTEMATIC REVIEWS**

- 2801 Efficacy of bone grafts in jaw cystic lesions: A systematic review

*Wang J, Yao QY, Zhu HY*

**CASE REPORT**

- 2811 Short stature associated with a novel mutation in the aggrecan gene: A case report and literature review

*Yin LP, Zheng HX, Zhu H*

- 2818 Treatment with sorafenib plus camrelizumab after splenectomy for primary splenic angiosarcoma with liver metastasis: A case report and literature review

*Pan D, Li TP, Xiong JH, Wang SB, Chen YX, Li JF, Xiao Q*

- 2829 Sarcomatoid intrahepatic cholangiocarcinoma with good patient prognosis after treatment with Huaier granules following hepatectomy: A case report

*Feng JY, Li XP, Wu ZY, Ying LP, Xin C, Dai ZZ, Shen Y, Wu YF*

- 2836 Sequential occurrence of T790M mutation and small cell lung cancer transformation in EGFR-positive lung adenocarcinoma: A case report

*Hong E, Chen XE, Mao J, Zhou JJ, Chen L, Xu JY, Tao W*

- 2844 Early diagnosis of Gitelman syndrome in a young child: A case report

*Wu CY, Tsai MH, Chen CC, Kao CH*

- 2851 Congenital intestinal malrotation with gastric wall defects causing extensive gut necrosis and short gut syndrome: A case report

*Wang Y, Gu Y, Ma D, Guo WX, Zhang YF*

- 2858 Delusional parasitosis as premotor symptom of parkinson's disease: A case report

*Oh M, Kim JW, Lee SM*

- 2864** Laninamivir-induced ischemic enterocolitis: A case report  
*Suzuki C, Kenzaka T*
- 2871** Intramural pregnancy after *in vitro* fertilization and embryo transfer: A case report  
*Xie QJ, Li X, Ni DY, Ji H, Zhao C, Ling XF*
- 2878** Bilateral ureteral reimplantation in a patient with an intraperitoneal ectopic bipenis: A case report  
*Jia YT, Shi BL, Zhang J, Li YY, Zhu J*
- 2883** Lumbar disc sequestration mimicking a tumor: Report of four cases and a literature review  
*Li ST, Zhang T, Shi XW, Liu H, Yang CW, Zhen P, Li SK*
- 2895** Parasitic leiomyoma in the trocar site after laparoscopic myomectomy: A case report  
*Roh CK, Kwon HJ, Jung MJ*
- 2901** Giant nontraumatic myositis ossificans in a child: A case report  
*Xia AN, Wang JS*
- 2908** Paradoxical carbon dioxide embolism during laparoscopic hepatectomy without intracardiac shunt: A case report  
*Jeon S, Hong JM, Lee HJ, Kim Y, Kang H, Hwang BY, Lee D, Jung YH*
- 2916** Local hyperthermia combined with chemotherapy for the treatment of multiple recurrences of *undifferentiated pleomorphic sarcoma*: A case report  
*Zhou YT, Wang RY, Zhang Y, Li DY, Yu J*
- 2923** Acute coronary artery stent thrombosis caused by a spasm: A case report  
*Meng LP, Wang P, Peng F*
- 2931** Turner syndrome with primary myelofibrosis, cirrhosis and ovarian cystic mass: A case report  
*Xu LW, Su YZ, Tao HF*
- 2938** Esophageal myoepithelial carcinoma: Four case reports  
*Lu H, Zhao HP, Liu YY, Yu J, Wang R, Gao JB*
- 2948** Ipsilateral hemifacial microsomia with dextrocardia and pulmonary hypoplasia: A case report  
*Guo R, Chang SH, Wang BQ, Zhang QG*
- 2954** Upper gastrointestinal bleeding from a Mallory-Weiss tear associated with transesophageal echocardiography during successful cardiopulmonary resuscitation: A case report  
*Tang MM, Fang DF, Liu B*
- 2961** Malignant struma ovarii with papillary carcinoma combined with retroperitoneal lymph node metastasis: A case report  
*Xiao W, Zhou JR, Chen D*

- 2969** Occult colon cancer with sepsis as the primary manifestation identified by bone marrow puncture: A case report

*Wang HJ, Zhou CJ*

**ABOUT COVER**

Editorial Board Member of *World Journal of Clinical Cases*, Arunchai Chang, MD, Assistant Professor, Lecturer, Staff Physician, Division of Gastroenterology, Department of Internal Medicine, Hatyai Hospital, Hatyai 90110, Songkhla, Thailand. busmdcu58@gmail.com

**AIMS AND SCOPE**

The primary aim of *World Journal of Clinical Cases* (WJCC, *World J Clin Cases*) is to provide scholars and readers from various fields of clinical medicine with a platform to publish high-quality clinical research articles and communicate their research findings online.

WJCC mainly publishes articles reporting research results and findings obtained in the field of clinical medicine and covering a wide range of topics, including case control studies, retrospective cohort studies, retrospective studies, clinical trials studies, observational studies, prospective studies, randomized controlled trials, randomized clinical trials, systematic reviews, meta-analysis, and case reports.

**INDEXING/ABSTRACTING**

The WJCC is now indexed in Science Citation Index Expanded (also known as SciSearch®), Journal Citation Reports/Science Edition, Scopus, PubMed, and PubMed Central. The 2021 Edition of Journal Citation Reports® cites the 2020 impact factor (IF) for WJCC as 1.337; IF without journal self cites: 1.301; 5-year IF: 1.742; Journal Citation Indicator: 0.33; Ranking: 119 among 169 journals in medicine, general and internal; and Quartile category: Q3. The WJCC's CiteScore for 2020 is 0.8 and Scopus CiteScore rank 2020: General Medicine is 493/793.

**RESPONSIBLE EDITORS FOR THIS ISSUE**

Production Editor: *Ying-Yi Yuan*, Production Department Director: *Xiang Li*, Editorial Office Director: *Jin-Lei Wang*.

**NAME OF JOURNAL**

*World Journal of Clinical Cases*

**ISSN**

ISSN 2307-8960 (online)

**LAUNCH DATE**

April 16, 2013

**FREQUENCY**

Thrice Monthly

**EDITORS-IN-CHIEF**

Bao-Gan Peng, Jerzy Tadeusz Chudek, George Kontogeorgos, Maurizio Serati, Ja Hyeon Ku

**EDITORIAL BOARD MEMBERS**

<https://www.wjgnet.com/2307-8960/editorialboard.htm>

**PUBLICATION DATE**

March 26, 2022

**COPYRIGHT**

© 2022 Baishideng Publishing Group Inc

**INSTRUCTIONS TO AUTHORS**

<https://www.wjgnet.com/bpg/gerinfo/204>

**GUIDELINES FOR ETHICS DOCUMENTS**

<https://www.wjgnet.com/bpg/GerInfo/287>

**GUIDELINES FOR NON-NATIVE SPEAKERS OF ENGLISH**

<https://www.wjgnet.com/bpg/gerinfo/240>

**PUBLICATION ETHICS**

<https://www.wjgnet.com/bpg/GerInfo/288>

**PUBLICATION MISCONDUCT**

<https://www.wjgnet.com/bpg/gerinfo/208>

**ARTICLE PROCESSING CHARGE**

<https://www.wjgnet.com/bpg/gerinfo/242>

**STEPS FOR SUBMITTING MANUSCRIPTS**

<https://www.wjgnet.com/bpg/GerInfo/239>

**ONLINE SUBMISSION**

<https://www.f6publishing.com>



## Short stature associated with a novel mutation in the aggrecan gene: A case report and literature review

Li-Ping Yin, Hong-Xue Zheng, Hong Zhu

**Specialty type:** Genetics and heredity

**Provenance and peer review:**

Unsolicited article; Externally peer reviewed.

**Peer-review model:** Single blind

**Peer-review report's scientific quality classification**

Grade A (Excellent): A

Grade B (Very good): 0

Grade C (Good): 0

Grade D (Fair): 0

Grade E (Poor): 0

**P-Reviewer:** Scicchitano P

**Received:** July 27, 2021

**Peer-review started:** July 27, 2021

**First decision:** October 22, 2021

**Revised:** November 2, 2021

**Accepted:** February 19, 2022

**Article in press:** February 19, 2022

**Published online:** March 26, 2022



Li-Ping Yin, Hong-Xue Zheng, Hong Zhu, Department of Paediatrics, The First People's Hospital of Changzhou, The Third Affiliated Hospital of Soochow University, Changzhou 213000, Jiangsu Province, China

**Corresponding author:** Hong Zhu, PhD, Professor, Department of Paediatrics, The First People's Hospital of Changzhou, The Third Affiliated Hospital of Soochow University, No. 185 Juqian Street, Changzhou 213000, Jiangsu Province, China. [zhuhongcz@126.com](mailto:zhuhongcz@126.com)

### Abstract

#### BACKGROUND

Mutations in the aggrecan (ACAN) gene are identified in patients with: spondyloepiphyseal dysplasia, Kimberley type; short stature with advanced bone age (BA); in the presence or absence of heterozygous ACAN mutation-induced early-onset osteoarthritis and/or osteochondritis dissecans; and spondyloepimetaphyseal dysplasia, ACAN type. Heterozygous mutations contribute to spondyloepiphyseal dysplasia, Kimberley type (MIM#608361), which is a milder skeletal dysplasia. In contrast, homozygous mutations cause a critical skeletal dysplasia, which is called spondyloepimetaphyseal dysplasia, ACAN type (MIM#612813). Lately, investigations on exome and genome sequencing have shown that ACAN mutations can also lead to idiopathic short stature with or without an advanced BA, in the presence or absence of early-onset osteoarthritis and/or osteochondritis dissecans (MIM#165800). We herein reported a heterozygous defect of ACAN in a family with autosomal dominant short stature, BA acceleration, and premature growth cessation.

#### CASE SUMMARY

A 2-year-old male patient visited us due to growth retardation. The patient presented symmetrical short stature (height 79 cm, < -2 SD) without facial features and other congenital abnormalities. Whole-exome sequencing revealed a heterozygous pathogenic variant c. 871C>T (p. Gln291\*) of ACAN, which was not yet reported in cases of short stature. This mutation was also detected in his father and paternal grandmother. According to the Human Gene Mutation Database, 67 ACAN mutations are registered. Most of these mutations are genetically inheritable, and very few children with short stature are associated with ACAN mutations. To date, heterozygous ACAN mutations have been reported in approximately 40 families worldwide, including a few individuals with a decelerated BA.

#### CONCLUSION

Heterozygous c. 871C>T (p. Gln291\*) variation of the *ACAN* gene was the disease-causing variant in this family. Collectively, our newly discovered mutation expanded the spectrum of *ACAN* gene mutations.

**Key Words:** Short stature; Aggrecan gene; Mutation; Bone age; Case report

©The Author(s) 2022. Published by Baishideng Publishing Group Inc. All rights reserved.

**Core Tip:** Because of the diversity of clinical manifestations, phenotype overlap, and high genetic heterogeneity of short stature, the etiology of dwarfism cannot be determined by merely inquiring about the medical history, clinical performances, and routine laboratory examination. Gene detection can provide clear clinical diagnostic evidence, decrease the medical error and missed diagnosis of the disorder, instruct genetic counseling, and supply a trustworthy principle for fetal diagnosis. This case expanded the spectrum of aggrecan gene mutations.

**Citation:** Yin LP, Zheng HX, Zhu H. Short stature associated with a novel mutation in the aggrecan gene: A case report and literature review. *World J Clin Cases* 2022; 10(9): 2811-2817

**URL:** <https://www.wjgnet.com/2307-8960/full/v10/i9/2811.htm>

**DOI:** <https://dx.doi.org/10.12998/wjcc.v10.i9.2811>

## INTRODUCTION

Children often visit pediatric endocrinologists because of their short stature. However, the clinical definition and therapeutic regimen of pediatric growth disorders have been significantly changed by recent advances in genetic methodology. Idiopathic short stature and advanced bone age (BA), in the presence or absence of heterozygous aggrecan (*ACAN*) mutation-induced early-onset osteoarthritis and/or osteochondritis dissecans exemplify these changes well. Herein, we presented the case and his affected members with symmetrical short stature, and a heterozygous variant of the *ACAN* gene was the disease-causing variant in this family.

## CASE PRESENTATION

### Chief complaints

A 2-year-old boy with growth retardation for over 1 year.

### History of present illness

This boy was born at 40 wk of gestation following a common pregnancy and parturition. At birth, his weight was 2.75 kg, while there was no specific body length measurement. At 2 years of age, the patient visited us due to his short stature. His height was 79 cm (-2.7 SD), with a bodyweight of 10 kg, and his occipitofrontal circumference was 49 cm. No dysmorphic features were detected. His mental and motor development were normal.

### History of past illness

The patient was not associated with any previous illness.

### Personal and family history

The height of his father and paternal grandmother was 152 cm (< -3.0 SD) and 138 cm (< -3.0 SD), respectively.

### Physical examination

The physical test showed retarded growth (height, 79 cm; weight, 10 kg). He presented symmetrical short stature without facial features and other congenital abnormalities.

### Laboratory examinations

The peripheral blood was collected from the patient and his family members, followed by DNA extraction. Whole-exome sequencing was performed using an xGen Exam research panel v1.0 (IDT) on a HiSeq 4000 (Illumina). Any known disease associations were determined using the Online Mendelian



Inheritance of Man (<http://www.omim.org>) database. A heterozygous mutation in *ACAN* (NM\_013227.3) was identified in all affected individuals. This *ACAN* mutation was predicted to cause the resultant termination at codon 291 (c.871C>T; p.Gln291\*) (Figure 1).

### Imaging examinations

His BA was evaluated as 3 years and 6 mo to 4 years (Figure 2).

---

## FINAL DIAGNOSIS

---

Short stature caused by *ACAN* mutation.

---

## TREATMENT

---

The patient received growth hormone (GH) treatment.

---

## OUTCOME AND FOLLOW-UP

---

The height of the patient was increased by about 1 cm per month after GH treatment. During the treatment, no adverse events were recorded.

---

## DISCUSSION

---

The *ACAN* gene encoding aggrecan is usually localized on chromosome 15q26[1,2]. Its full-length clone has been obtained by Doege *et al*[3]. The kernel protein of *ACAN* is composed of three disulfide-bonded globular domains (G1, G2, and G3) and intervening extended domains[4]. The interglobular domain is a protruding site for breaking proteins into smaller polypeptides or amino acids, and many proteinases can cleave between the G1 and G2 domains[5,6]. An extended GAG-attachment region separates the G2 and G3 domains, which is differentiated into three parts. The keratan sulfate (KS)-rich domain lies adjacent to the G2 domain. The KS-rich domain is likened to the chondroitin sulfate (CS)-rich domain, which is differentiated into two subdomains (CS1 and CS2), and the amino acid sequences of these two subdomains are different. The CS2 domain is connected to the G3 domain, which is located at the carboxy terminus of the core protein. The G3 region consists of two epidermal growth factor-like domains, one C-type lectin-like domain, and one complement regulatory protein-like domain[7]. The G3 region plays a fundamental role in the normal trafficking of *ACAN* within the chondrocytes, and such a region is also involved in the release of *ACAN* into the extracellular matrix[8]. In the extracellular matrix, the G3 domain is not detected in some *ACAN* molecules[9,10], which can probably be attributed to proteolytic cleavage.

There are 19 exons in the human *ACAN* gene[11]. The G1 region, interglobular domain, and G2 region are encoded by exons 3-6, exon 7, and exons 8-10, respectively. The GAG attachment region is encoded by exons 11 and 12, in which exon 11 encodes the first part of the KS-rich domain, and the large exon 12 encodes the remainder of the KS-rich domain as well as the CS1 and CS2 domains. The exons 13-19 encode the G3 region, exons 13 and 14 each encode an epidermal growth factor-like domain, exons 15-17 encode the lectin-like domain, and exon 18 encodes the complement regulatory protein-like domain.

*ACAN* is the main proteoglycan of the extracellular matrix of the growth plate cartilage[12]. Mutations in *ACAN* are associated with growth defects[13]. The research of Gleghorn *et al*[14] first reported an *ACAN* mutation that causes human disease. They have identified the heterozygosity for a 1-bp insertion in the *ACAN* gene with spondyloepiphyseal dysplasia, Kimberley type-affected members. This mutation can forecast the synthesis of a truncated protein that is about 60% of the normal size. The truncated protein lacks half of the CS1 domain, the complete CS2 domain, and the G3 domain, while it includes a novel sequence of 212 aa.

Watanabe *et al*[15] showed that heterozygotes have two obvious phenotypes: slight dwarfism and age-related hyperlordosis, the anterior concavity in the curvature of the spine. In the families analyzed by some studies[16-18], heterozygotes are detected in all affected members, who exhibit the clinical features of short stature and advanced BA. These data indicate that various pathogenic heterozygous *ACAN* variants (Table 1) affect the chondrogenesis of the growth plate in a similar pattern. Therefore, the growth plate chondrogenesis is impaired by functional haploinsufficiency of *ACAN* rather than various mutation-specific mechanisms. However, a dysfunctional C-type lectin domain in the *ACAN* protein leads to a more severe phenotype, impairing the functions of the growth plate and articular

**Table 1** Summary of pathogenic heterozygous mutations of aggrecan gene

cDNA	Variant
c.223T>C	p.Trp75Arg
c.273del	p.Arg93fs
c.1172del	p.Gly391fs
c.1227del	p.Ser410fs
c.1425del	p.Val478fs
c.1745del	p.Phe582fs
c.2026+1G>A	-
c.2541del	p.Val848fs
c.3758dup	p.Gly1254fs
c.4138G>T	p.Val1380Phe
c.4186del	p.Ser1396fs
c.4657G>T	p.Glu1553Ter
c.5061T>A	p.Ser1687Arg
c.5337del	p.Phe1780fs
c.5391del	p.Gln1798fs
c.5491_5500del	p.Phe1831fs
c.6534del	p.Thr2179fs
c.7178T>C	p.Leu2393Pro
c.7204C>T	p.Gln2402Ter
c.7255G>A	p.Asp2419Asn
c.7317G>A	p.Trp2439Ter
c.7363G>A	p.Val2455Met

Arg: Arginine; Asn: Asparagine; Asp: Aspartic acid; Del: Deletion; dup: Duplication; Gln: Glutamine; Glu: Glutamic acid; Gly: Glycine; fs: Frameshift; Leu: Leucine; Met: Methionine; Phe: Phenylalanine; Pro: Proline; Ser: Serine; Ter: Termination codon; Thr: Threonine; Trp: Tryptophan; Val: Valine.

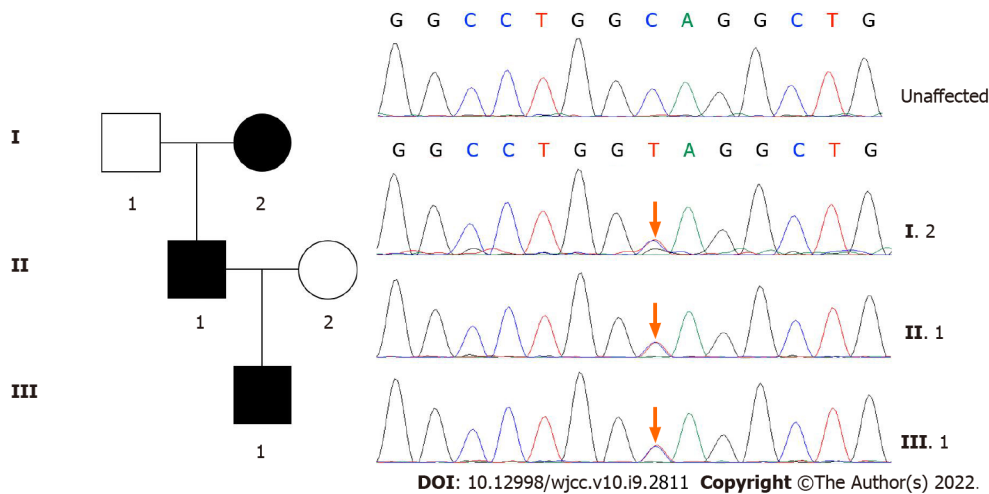
cartilage. All these studies provide a reasonable explanation for why those families have short stature but no evidence of early-onset osteoarthritis. The proband and affected members of our case also presented with autosomal dominant short stature and no indications of chondrodysplasia.

The combination of short stature and advanced BA is rare. Most known causative mutations either impair proteoglycan synthesis[19-21] or reduce signaling through the cAMP-protein kinase A signaling pathway[22-24].

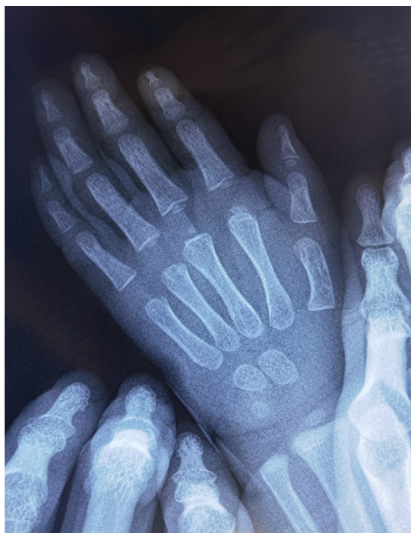In the clinical studies of *ACAN* patients, the length in the lower part of most heterozygous carriers of *ACAN* variants show a normal range at birth, while some of them are born short for gestational age[25]. Some researchers have suggested that individuals treated with GH have an improvement in adult height. In addition to GH treatment, some patients also simultaneously receive treatment with gonadotropin-releasing hormone analogue. This treatment can be given to patients after the administration of an aromatase inhibitor, which can successfully postpone bone maturation, and such therapy can benefit those carrying confirmed *ACAN* mutations[26-31].

## CONCLUSION

In the present study, a heterozygous mutation in the *ACAN* gene was identified in a Chinese family with short stature. We hypothesized that this mutation could induce early truncation of the *ACAN* protein. Genetic testing is important for diagnosis and treatment.



**Figure 1** Family map and whole-exome sequencing of the patient. The mutation was not found in the unaffected grandfather or mother or public variant databases.



DOI: 10.12998/wjcc.v10.i9.2811 Copyright ©The Author(s) 2022.

**Figure 2** Bone age. The bone age was equivalent to 3.5-4 years at the age of 2 years.

## ACKNOWLEDGEMENTS

We gratefully acknowledge the kind cooperation of the patient, the family members, and the staff from the unit for their assistance in conducting this study.

## FOOTNOTES

**Author contributions:** Yin LP and Zheng HX collected the medical records of the patient, reviewed the literature, and drafted the manuscript; Zhu H revised the manuscript; all authors agreed to submit the final version.

**Informed consent statement:** The patient signed the informed consent and permitted publication of his information and any accompanying images.

**Conflict-of-interest statement:** The authors declare that there was no conflict of interest to report.

**CARE Checklist (2016) statement:** The authors have read the CARE Checklist (2016), and the manuscript was prepared and revised according to the CARE Checklist (2016).

**Open-Access:** This article is an open-access article that was selected by an in-house editor and fully peer-reviewed by external reviewers. It is distributed in accordance with the Creative Commons Attribution NonCommercial (CC BY-

NC 4.0) license, which permits others to distribute, remix, adapt, build upon this work non-commercially, and license their derivative works on different terms, provided the original work is properly cited and the use is non-commercial. See: <http://creativecommons.org/licenses/by-nc/4.0/>

**Country/Territory of origin:** China

**ORCID number:** Li-Ping Yin [0000-0002-5965-037X](#); Hong-Xue Zheng [0000-0003-0929-6621](#); Hong Zhu [0000-0001-5078-1288](#).

**S-Editor:** Liu JH

**L-Editor:** Filipodia

**P-Editor:** Liu JH

## REFERENCES

- 1 **Korenberg JR**, Chen XN, Doege K, Grover J, Roughley PJ. Assignment of the human aggrecan gene (AGC1) to 15q26 using fluorescence in situ hybridization analysis. *Genomics* 1993; **16**: 546-548 [PMID: [8314595](#) DOI: [10.1006/geno.1993.1228](#)]
- 2 **Just W**, Klett C, Vetter U, Vogel W. Assignment of the human aggrecan gene AGC1 to 15q25-->q26.2 by in situ hybridization. *Hum Genet* 1993; **92**: 516-518 [PMID: [8244345](#) DOI: [10.1007/BF00216462](#)]
- 3 **Doege KJ**, Sasaki M, Kimura T, Yamada Y. Complete coding sequence and deduced primary structure of the human cartilage large aggregating proteoglycan, aggrecan. Human-specific repeats, and additional alternatively spliced forms. *J Biol Chem* 1991; **266**: 894-902 [PMID: [1985970](#) DOI: [10.1016/S0021-9258\(17\)35257-2](#)]
- 4 **Kiani C**, Chen L, Wu YJ, Yee AJ, Yang BB. Structure and function of aggrecan. *Cell Res* 2002; **12**: 19-32 [PMID: [11942407](#) DOI: [10.1038/sj.cr.7290106](#)]
- 5 **Fosang AJ**, Hardingham TE. Isolation of the N-terminal globular protein domains from cartilage proteoglycans. Identification of G2 domain and its lack of interaction with hyaluronate and link protein. *Biochem J* 1989; **261**: 801-809 [PMID: [2803245](#) DOI: [10.1042/bj2610801](#)]
- 6 **Paulsson M**, Yurchenco PD, Ruben GC, Engel J, Timpl R. Structure of low density heparan sulfate proteoglycan isolated from a mouse tumor basement membrane. *J Mol Biol* 1987; **197**: 297-313 [PMID: [2960821](#) DOI: [10.1016/0022-2836\(87\)90125-2](#)]
- 7 **Day JM**, Olin AI, Murdoch AD, Canfield A, Sasaki T, Timpl R, Hardingham TE, Aspberg A. Alternative splicing in the aggrecan G3 domain influences binding interactions with tenascin-C and other extracellular matrix proteins. *J Biol Chem* 2004; **279**: 12511-12518 [PMID: [14722076](#) DOI: [10.1074/jbc.M400242200](#)]
- 8 **Aspberg A**. The different roles of aggrecan interaction domains. *J Histochem Cytochem* 2012; **60**: 987-996 [PMID: [23019016](#) DOI: [10.1369/0022155412464376](#)]
- 9 **Dennis JE**, Carrino DA, Schwartz NB, Caplan AI. Ultrastructural characterization of embryonic chick cartilage proteoglycan core protein and the mapping of a monoclonal antibody epitope. *J Biol Chem* 1990; **265**: 12098-12103 [PMID: [1694854](#) DOI: [10.1016/0008-6215\(90\)84066-4](#)]
- 10 **Wiedemann H**, Paulsson M, Timpl R, Engel J, Heinegård D. Domain structure of cartilage proteoglycans revealed by rotary shadowing of intact and fragmented molecules. *Biochem J* 1984; **224**: 331-333 [PMID: [6508768](#) DOI: [10.1042/bj2240331](#)]
- 11 **Valhmu WB**, Palmer GD, Rivers PA, Ebara S, Cheng JF, Fischer S, Ratcliffe A. Structure of the human aggrecan gene: exon-intron organization and association with the protein domains. *Biochem J* 1995; **309** ( Pt 2): 535-542 [PMID: [7626017](#) DOI: [10.1042/bj3090535](#)]
- 12 **Lauing KL**, Cortes M, Domowicz MS, Henry JG, Baria AT, Schwartz NB. Aggrecan is required for growth plate cytoarchitecture and differentiation. *Dev Biol* 2014; **396**: 224-236 [PMID: [25446537](#) DOI: [10.1016/j.ydbio.2014.10.005](#)]
- 13 **Gibson BG**, Briggs MD. The aggrecanopathies; an evolving phenotypic spectrum of human genetic skeletal diseases. *Orphanet J Rare Dis* 2016; **11**: 86 [PMID: [27353333](#) DOI: [10.1186/s13023-016-0459-2](#)]
- 14 **Gleghorn L**, Ramesar R, Beighton P, Wallis G. A mutation in the variable repeat region of the aggrecan gene (AGC1) causes a form of spondyloepiphyseal dysplasia associated with severe, premature osteoarthritis. *Am J Hum Genet* 2005; **77**: 484-490 [PMID: [16080123](#) DOI: [10.1086/444401](#)]
- 15 **Watanabe H**, Nakata K, Kimata K, Nakanishi I, Yamada Y. Dwarfism and age-associated spinal degeneration of heterozygote cmd mice defective in aggrecan. *Proc Natl Acad Sci U S A* 1997; **94**: 6943-6947 [PMID: [9192671](#) DOI: [10.1073/pnas.94.13.6943](#)]
- 16 **Stattin EL**, Wiklund F, Lindblom K, Onnerfjord P, Jonsson BA, Tegner Y, Sasaki T, Struglics A, Lohmander S, Dahl N, Heinegård D, Aspberg A. A missense mutation in the aggrecan C-type lectin domain disrupts extracellular matrix interactions and causes dominant familial osteochondritis dissecans. *Am J Hum Genet* 2010; **86**: 126-137 [PMID: [20137779](#) DOI: [10.1016/j.ajhg.2009.12.018](#)]
- 17 **Nilsson O**, Guo MH, Dunbar N, Popovic J, Flynn D, Jacobsen C, Lui JC, Hirschhorn JN, Baron J, Dauber A. Short stature, accelerated bone maturation, and early growth cessation due to heterozygous aggrecan mutations. *J Clin Endocrinol Metab* 2014; **99**: E1510-E1518 [PMID: [24762113](#) DOI: [10.1210/jc.2014-1332](#)]
- 18 **Quintos JB**, Guo MH, Dauber A. Idiopathic short stature due to novel heterozygous mutation of the aggrecan gene. *J Pediatr Endocrinol Metab* 2015; **28**: 927-932 [PMID: [25741789](#) DOI: [10.1515/jpem-2014-0450](#)]
- 19 **Kim OH**, Nishimura G, Song HR, Matsui Y, Sakazume S, Yamada M, Narumi Y, Alanay Y, Unger S, Cho TJ, Park SS, Ikegawa S, Meinecke P, Superti-Furga A. A variant of Desbuquois dysplasia characterized by advanced carpal bone age,

- short metacarpals, and elongated phalanges: report of seven cases. *Am J Med Genet A* 2010; **152A**: 875-885 [PMID: [20358597](#) DOI: [10.1002/ajmg.a.33347](#)]
- 20 **Nizon M**, Huber C, De Leonardis F, Merrina R, Forlino A, Fradin M, Tuysuz B, Abu-Libdeh BY, Alanay Y, Albrecht B, Al-Gazali L, Basaran SY, Clayton-Smith J, Désir J, Gill H, Grealis MT, Koparir E, van Maarle MC, MacKay S, Mortier G, Morton J, Sillence D, Vilain C, Young I, Zerres K, Le Merrer M, Munnich A, Le Goff C, Rossi A, Cormier-Daire V. Further delineation of CANT1 phenotypic spectrum and demonstration of its role in proteoglycan synthesis. *Hum Mutat* 2012; **33**: 1261-1266 [PMID: [22539336](#) DOI: [10.1002/humu.22104](#)]
  - 21 **Bui C**, Huber C, Tuysuz B, Alanay Y, Bole-Feysot C, Leroy JG, Mortier G, Nitschke P, Munnich A, Cormier-Daire V. XYLT1 mutations in Desbuquois dysplasia type 2. *Am J Hum Genet* 2014; **94**: 405-414 [PMID: [24581741](#) DOI: [10.1016/j.ajhg.2014.01.020](#)]
  - 22 **Mantovani G**, Ferrante E, Giavoli C, Linglart A, Cappa M, Cisternino M, Maghnie M, Ghizzoni L, de Sanctis L, Lania AG, Beck-Peccoz P, Spada A. Recombinant human GH replacement therapy in children with pseudohypoparathyroidism type Ia: first study on the effect on growth. *J Clin Endocrinol Metab* 2010; **95**: 5011-5017 [PMID: [20719837](#) DOI: [10.1210/jc.2010-1649](#)]
  - 23 **Linglart A**, Menguy C, Couvineau A, Auzan C, Gunes Y, Cancel M, Motte E, Pinto G, Chanson P, Bougnères P, Clauser E, Silve C. Recurrent PRKARIA mutation in acrodyostosis with hormone resistance. *N Engl J Med* 2011; **364**: 2218-2226 [PMID: [21651393](#) DOI: [10.1056/NEJMoa1012717](#)]
  - 24 **Lindstrand A**, Grigelioniene G, Nilsson D, Pettersson M, Hofmeister W, Anderlid BM, Kant SG, Ruivenkamp CA, Gustavsson P, Valta H, Geiberger S, Topa A, Lagerstedt-Robinson K, Taylan F, Wincet J, Laurell T, Pekkinen M, Nordenskjöld M, Mäkitie O, Nordgren A. Different mutations in PDE4D associated with developmental disorders with mirror phenotypes. *J Med Genet* 2014; **51**: 45-54 [PMID: [24203977](#) DOI: [10.1136/jmedgenet-2013-101937](#)]
  - 25 **Hauer NN**, Sticht H, Boppudi S, Büttner C, Kraus C, Trautmann U, Zenker M, Zweier C, Wiesener A, Jamra RA, Wiczorek D, Kelkel J, Jung AM, Uebe S, Ekici AB, Rohrer T, Reis A, Dörr HG, Thiel CT. Genetic screening confirms heterozygous mutations in ACAN as a major cause of idiopathic short stature. *Sci Rep* 2017; **7**: 12225 [PMID: [28939912](#) DOI: [10.1038/s41598-017-12465-6](#)]
  - 26 **Hu X**, Gui B, Su J, Li H, Li N, Yu T, Zhang Q, Xu Y, Li G, Chen Y, Qing Y; Chinese Genetic Short Stature Consortium, Li C, Luo J, Fan X, Ding Y, Li J, Wang J, Wang X, Chen S, Shen Y. Novel pathogenic ACAN variants in non-syndromic short stature patients. *Clin Chim Acta* 2017; **469**: 126-129 [PMID: [28396070](#) DOI: [10.1016/j.cca.2017.04.004](#)]
  - 27 **van der Steen M**, Pfundt R, Maas SJWH, Bakker-van Waarde WM, Odink RJ, Hokken-Koelega ACS. ACAN Gene Mutations in Short Children Born SGA and Response to Growth Hormone Treatment. *J Clin Endocrinol Metab* 2017; **102**: 1458-1467 [PMID: [27710243](#) DOI: [10.1210/jc.2016-2941](#)]
  - 28 **Crippa M**, Giangiobbe S, Villa R, Bestetti I, De Filippis T, Fatti L, Taurino J, Larizza L, Persani L, Bellini F, Finelli P, Bonati MT. A balanced reciprocal translocation t(10;15)(q22.3;q26.1) interrupting ACAN gene in a family with proportionate short stature. *J Endocrinol Invest* 2018; **41**: 929-936 [PMID: [29302920](#) DOI: [10.1007/s40618-017-0819-3](#)]
  - 29 **Gkourogianni A**, Andrew M, Tyzinski L, Crocker M, Douglas J, Dunbar N, Fairchild J, Funari MF, Heath KE, Jorge AA, Kurtzman T, LaFranchi S, Lalani S, Lebl J, Lin Y, Los E, Newbern D, Nowak C, Olson M, Popovic J, Pruhová Š, Elblova L, Quintos JB, Segerlund E, Senthordi L, Shinawi M, Stattin EL, Swartz J, Angel AG, Cuéllar SD, Hosono H, Sanchez-Lara PA, Hwa V, Baron J, Nilsson O, Dauber A. Clinical Characterization of Patients With Autosomal Dominant Short Stature due to Aggrecan Mutations. *J Clin Endocrinol Metab* 2017; **102**: 460-469 [PMID: [27870580](#) DOI: [10.1210/jc.2016-3313](#)]
  - 30 **Stavber L**, Hovnik T, Kotnik P, Lovrečić L, Kovač J, Tesovnik T, Bertok S, Dovč K, Debeljak M, Battelino T, Avbelj Stefanija M. High frequency of pathogenic ACAN variants including an intragenic deletion in selected individuals with short stature. *Eur J Endocrinol* 2020; **182**: 243-253 [PMID: [31841439](#) DOI: [10.1530/EJE-19-0771](#)]
  - 31 **Dateki S**, Nakatomi A, Watanabe S, Shimizu H, Inoue Y, Baba H, Yoshiura KI, Moriuchi H. Identification of a novel heterozygous mutation of the Aggrecan gene in a family with idiopathic short stature and multiple intervertebral disc herniation. *J Hum Genet* 2017; **62**: 717-721 [PMID: [28331218](#) DOI: [10.1038/jhg.2017.33](#)]



Published by **Baishideng Publishing Group Inc**  
7041 Koll Center Parkway, Suite 160, Pleasanton, CA 94566, USA

**Telephone:** +1-925-3991568

**E-mail:** [bpgoffice@wjgnet.com](mailto:bpgoffice@wjgnet.com)

**Help Desk:** <https://www.f6publishing.com/helpdesk>

<https://www.wjgnet.com>

