

# World Journal of *Clinical Cases*

*World J Clin Cases* 2022 September 16; 10(26): 9180-9549



## Contents

Thrice Monthly Volume 10 Number 26 September 16, 2022

### REVIEW

- 9180** Assisting individuals with diabetes in the COVID-19 pandemic period: Examining the role of religious factors and faith communities

*Eseadi C, Ossai OV, Onyishi CN, Ilechukwu LC*

- 9192** Role of octreotide in small bowel bleeding

*Khedr A, Mahmoud EE, Attallah N, Mir M, Boike S, Rauf I, Jama AB, Mushtaq H, Surani S, Khan SA*

### MINIREVIEWS

- 9207** Internet of things-based health monitoring system for early detection of cardiovascular events during COVID-19 pandemic

*Dami S*

- 9219** Convergence mechanism of mindfulness intervention in treating attention deficit hyperactivity disorder: Clues from current evidence

*Xu XP, Wang W, Wan S, Xiao CF*

- 9228** Clinical presentation, management, screening and surveillance for colorectal cancer during the COVID-19 pandemic

*Akbulut S, Hargura AS, Garzali IU, Aloun A, Colak C*

- 9241** Early diagnostic value of liver stiffness measurement in hepatic sinusoidal obstruction syndrome induced by hematopoietic stem cell transplantation

*Tan YW, Shi YC*

### ORIGINAL ARTICLE

#### Case Control Study

- 9254** Local inflammatory response to gastroesophageal reflux: Association of gene expression of inflammatory cytokines with esophageal multichannel intraluminal impedance-pH data

*Morozov S, Sentsova T*

#### Retrospective Study

- 9264** Evaluation of high-risk factors and the diagnostic value of alpha-fetoprotein in the stratification of primary liver cancer

*Jiao HB, Wang W, Guo MN, Su YL, Pang DQ, Wang BL, Shi J, Wu JH*

- 9276** One-half layer pancreaticojejunostomy with the rear wall of the pancreas reinforced: A valuable anastomosis technique

*Wei JP, Tai S, Su ZL*

- 9285** Development and validation of an epithelial-mesenchymal transition-related gene signature for predicting prognosis

*Zhou DH, Du QC, Fu Z, Wang XY, Zhou L, Wang J, Hu CK, Liu S, Li JM, Ma ML, Yu H*

### Observational Study

- 9303** Incidence and risk factor analysis for swelling after apical microsurgery

*Bi C, Xia SQ, Zhu YC, Lian XZ, Hu LJ, Rao CX, Jin HB, Shang XD, Jin FF, Li JY, Zheng P, Wang SH*

### CASE REPORT

- 9310** Acute carotid stent thrombosis: A case report and literature review

*Zhang JB, Fan XQ, Chen J, Liu P, Ye ZD*

- 9318** Congenital ovarian anomaly manifesting as extra tissue connection between the two ovaries: A case report

*Choi MG, Kim JW, Kim YH, Kim AM, Kim TY, Ryu HK*

- 9323** Cefoperazone-sulbactam and ornidazole for *Gardnerella vaginalis* bloodstream infection after cesarean section: A case report

*Mu Y, Li JJ, Wu X, Zhou XF, Tang L, Zhou Q*

- 9332** Early-onset ophthalmoplegia, cervical dyskinesia, and lower extremity weakness due to partial deletion of chromosome 16: A case report

*Xu M, Jiang J, He Y, Gu WY, Jin B*

- 9340** Posterior mediastinal extralobar pulmonary sequestration misdiagnosed as a neurogenic tumor: A case report

*Jin HJ, Yu Y, He W, Han Y*

- 9348** Unexpected difficult airway due to severe upper tracheal distortion: A case report

*Zhou JW, Wang CG, Chen G, Zhou YF, Ding JF, Zhang JW*

- 9354** Special epithelioid trophoblastic tumor: A case report

*Wang YN, Dong Y, Wang L, Chen YH, Hu HY, Guo J, Sun L*

- 9361** Intrahepatic multicystic biliary hamartoma: A case report

*Wang CY, Shi FY, Huang WF, Tang Y, Li T, He GL*

- 9368** ST-segment elevation myocardial infarction in Kawasaki disease: A case report and review of literature

*Lee J, Seo J, Shin YH, Jang AY, Suh SY*

- 9378** Bilateral hypocalcaemic cataracts due to idiopathic parathyroid insufficiency: A case report

*Li Y*

- 9384** Single organ hepatic artery vasculitis as an unusual cause of epigastric pain: A case report

*Kaviani R, Farrell J, Dehghan N, Moosavi S*

- 9390** Congenital lipoid adrenal hyperplasia with Graves' disease: A case report

*Wang YJ, Liu C, Xing C, Zhang L, Xu WF, Wang HY, Wang FT*

- 9398** Cytokine release syndrome complicated with rhabdomyolysis after chimeric antigen receptor T-cell therapy: A case report  
*Zhang L, Chen W, Wang XM, Zhang SQ*
- 9404** Antiphospholipid syndrome with renal and splenic infarction after blunt trauma: A case report  
*Lee NA, Jeong ES, Jang HS, Park YC, Kang JH, Kim JC, Jo YG*
- 9411** Uncontrolled high blood pressure under total intravenous anesthesia with propofol and remifentanyl: A case report  
*Jang MJ, Kim JH, Jeong HJ*
- 9417** Noncirrhotic portal hypertension due to peripheral T-cell lymphoma, not otherwise specified: A case report  
*Wu MM, Fu WJ, Wu J, Zhu LL, Niu T, Yang R, Yao J, Lu Q, Liao XY*
- 9428** Resumption of school after lockdown in COVID-19 pandemic: Three case reports  
*Wang KJ, Cao Y, Gao CY, Song ZQ, Zeng M, Gong HL, Wen J, Xiao S*
- 9434** Complete recovery from segmental zoster paresis confirmed by magnetic resonance imaging: A case report  
*Park J, Lee W, Lim Y*
- 9440** Imaging findings of immunoglobulin G4-related hypophysitis: A case report  
*Lv K, Cao X, Geng DY, Zhang J*
- 9447** Systemic lupus erythematosus presenting with progressive massive ascites and CA-125 elevation indicating Tjalma syndrome? A case report  
*Wang JD, Yang YF, Zhang XF, Huang J*
- 9454** Locally advanced cervical rhabdomyosarcoma in adults: A case report  
*Xu LJ, Cai J, Huang BX, Dong WH*
- 9462** Rapid progressive vaccine-induced immune thrombotic thrombocytopenia with cerebral venous thrombosis after ChAdOx1 nCoV-19 (AZD1222) vaccination: A case report  
*Jiang SK, Chen WL, Chien C, Pan CS, Tsai ST*
- 9470** Burkitt-like lymphoma with 11q aberration confirmed by needle biopsy of the liver: A case report  
*Yang HJ, Wang ZM*
- 9478** Common carotid artery thrombosis and malignant middle cerebral artery infarction following ovarian hyperstimulation syndrome: A case report  
*Xu YT, Yin QQ, Guo ZR*
- 9484** Postoperative radiotherapy for thymus salivary gland carcinoma: A case report  
*Deng R, Li NJ, Bai LL, Nie SH, Sun XW, Wang YS*
- 9493** Follicular carcinoma of the thyroid with a single metastatic lesion in the lumbar spine: A case report  
*Chen YK, Chen YC, Lin WX, Zheng JH, Liu YY, Zou J, Cai JH, Ji ZQ, Chen LZ, Li ZY, Chen YX*



- 9502** Guillain-Barré syndrome and hemophagocytic syndrome heralding the diagnosis of diffuse large B cell lymphoma: A case report  
*Zhou QL, Li ZK, Xu F, Liang XG, Wang XB, Su J, Tang YF*
- 9510** Intravitreal injection of conbercept for bullous retinal detachment: A case report  
*Xiang XL, Cao YH, Jiang TW, Huang ZR*
- 9518** Supratentorial hemangioblastoma at the anterior skull base: A case report  
*Xu ST, Cao X, Yin XY, Zhang JY, Nan J, Zhang J*

**META-ANALYSIS**

- 9524** Certain sulfonylurea drugs increase serum free fatty acid in diabetic patients: A systematic review and meta-analysis  
*Yu M, Feng XY, Yao S, Wang C, Yang P*

**LETTER TO THE EDITOR**

- 9536** Glucose substrate in the hydrogen breath test for gut microbiota determination: A recommended noninvasive test  
*Xie QQ, Wang JF, Zhang YF, Xu DH, Zhou B, Li TH, Li ZP*
- 9539** A rare cause of acute abdomen after a Good Friday  
*Pante L, Brito LG, Franciscatto M, Brambilla E, Soldera J*
- 9542** Obesity is associated with colitis in women but not necessarily causal relationship  
*Shen W, He LP, Zhou LL*
- 9545** Risk stratification of primary liver cancer  
*Tan YW*

**ABOUT COVER**

Editorial Board Member of *World Journal of Clinical Cases*, Youngmin Oh, MD, PhD, Associate Professor, Neurosurgeon, Department of Neurosurgery, Jeonbuk National University Medical School/Hospital, Jeonju 54907, Jeollabukdo, South Korea. timoh@jbnu.ac.kr

**AIMS AND SCOPE**

The primary aim of *World Journal of Clinical Cases* (WJCC, *World J Clin Cases*) is to provide scholars and readers from various fields of clinical medicine with a platform to publish high-quality clinical research articles and communicate their research findings online.

WJCC mainly publishes articles reporting research results and findings obtained in the field of clinical medicine and covering a wide range of topics, including case control studies, retrospective cohort studies, retrospective studies, clinical trials studies, observational studies, prospective studies, randomized controlled trials, randomized clinical trials, systematic reviews, meta-analysis, and case reports.

**INDEXING/ABSTRACTING**

The WJCC is now abstracted and indexed in Science Citation Index Expanded (SCIE, also known as SciSearch®), Journal Citation Reports/Science Edition, Current Contents®/Clinical Medicine, PubMed, PubMed Central, Scopus, Reference Citation Analysis, China National Knowledge Infrastructure, China Science and Technology Journal Database, and Superstar Journals Database. The 2022 Edition of Journal Citation Reports® cites the 2021 impact factor (IF) for WJCC as 1.534; IF without journal self cites: 1.491; 5-year IF: 1.599; Journal Citation Indicator: 0.28; Ranking: 135 among 172 journals in medicine, general and internal; and Quartile category: Q4. The WJCC's CiteScore for 2021 is 1.2 and Scopus CiteScore rank 2021: General Medicine is 443/826.

**RESPONSIBLE EDITORS FOR THIS ISSUE**

Production Editor: Hua-Ge Yin; Production Department Director: Xu Guo; Editorial Office Director: Jin-Lei Wang.

**NAME OF JOURNAL**

*World Journal of Clinical Cases*

**ISSN**

ISSN 2307-8960 (online)

**LAUNCH DATE**

April 16, 2013

**FREQUENCY**

Thrice Monthly

**EDITORS-IN-CHIEF**

Bao-Gan Peng, Jerzy Tadeusz Chudek, George Kontogeorgos, Maurizio Serati, Ja Hyeon Ku

**EDITORIAL BOARD MEMBERS**

<https://www.wjgnet.com/2307-8960/editorialboard.htm>

**PUBLICATION DATE**

September 16, 2022

**COPYRIGHT**

© 2022 Baishideng Publishing Group Inc

**INSTRUCTIONS TO AUTHORS**

<https://www.wjgnet.com/bpg/gerinfo/204>

**GUIDELINES FOR ETHICS DOCUMENTS**

<https://www.wjgnet.com/bpg/GerInfo/287>

**GUIDELINES FOR NON-NATIVE SPEAKERS OF ENGLISH**

<https://www.wjgnet.com/bpg/gerinfo/240>

**PUBLICATION ETHICS**

<https://www.wjgnet.com/bpg/GerInfo/288>

**PUBLICATION MISCONDUCT**

<https://www.wjgnet.com/bpg/gerinfo/208>

**ARTICLE PROCESSING CHARGE**

<https://www.wjgnet.com/bpg/gerinfo/242>

**STEPS FOR SUBMITTING MANUSCRIPTS**

<https://www.wjgnet.com/bpg/GerInfo/239>

**ONLINE SUBMISSION**

<https://www.f6publishing.com>



## Acute carotid stent thrombosis: A case report and literature review

Jian-Bin Zhang, Xue-Qiang Fan, Jie Chen, Peng Liu, Zhi-Dong Ye

**Specialty type:** Surgery

**Provenance and peer review:**

Unsolicited article; Externally peer reviewed.

**Peer-review model:** Single blind

**Peer-review report's scientific quality classification**

Grade A (Excellent): 0  
Grade B (Very good): 0  
Grade C (Good): C  
Grade D (Fair): 0  
Grade E (Poor): 0

**P-Reviewer:** Ozdemir HI, Turkey

**Received:** August 6, 2021

**Peer-review started:** August 6, 2021

**First decision:** November 6, 2021

**Revised:** November 10, 2021

**Accepted:** August 5, 2022

**Article in press:** August 5, 2022

**Published online:** September 16, 2022



Jian-Bin Zhang, Xue-Qiang Fan, Jie Chen, Peng Liu, Zhi-Dong Ye, Department of Cardiovascular Surgery, China-Japan Friendship Hospital, Beijing 100029, China

**Corresponding author:** Zhi-Dong Ye, MD, Chief Doctor, Department of Cardiovascular Surgery, China-Japan Friendship Hospital, No. 2 Yinghua East Street, Beijing 100029, China. [yezhiandong6618@yeah.net](mailto:yezhiandong6618@yeah.net)

### Abstract

#### BACKGROUND

Acute carotid stent thrombosis (ACST) is a rare but devastating complication in the carotid artery stenting (CAS) procedure. The aim of this article is to report a case and review cases of ACST reported in the literature, and investigate risk factors and management strategies for ACST.

#### CASE SUMMARY

We reviewed the treatment process of a patient with ACST after CAS. Then multiple databases were systematically searched to identify studies reporting ACST from 2005 to 2020. The demographic data, risk factors, treatment strategies, and prognosis were extracted and analyzed.

#### CONCLUSION

The reason for ACST is multifactorial. Proper patient selection, normative anti-platelet treatment, and perfect technical detail may decrease the incidence of ACST. Several treatment strategies such as thrombolysis, mechanical thrombectomy, and open surgery may be options for the treatment of ACST. Limited data have shown that carotid endarterectomy is effective with favorable results.

**Key Words:** Acute carotid stent thrombosis; Carotid artery stenosis; Carotid artery stenting; Treatment; Case report

©The Author(s) 2022. Published by Baishideng Publishing Group Inc. All rights reserved.

**Core Tip:** The reason for acute carotid stent thrombosis (ACST) is multifactorial. Proper patient selection, normative anti-platelet treatment, and perfect technical detail may decrease the incidence of ACST. Several treatment strategies such as thrombolysis, mechanical thrombectomy, and open surgery may be options for the treatment of ACST. Limited data have shown carotid endarterectomy is effective with favorable results.

**Citation:** Zhang JB, Fan XQ, Chen J, Liu P, Ye ZD. Acute carotid stent thrombosis: A case report and literature review. *World J Clin Cases* 2022; 10(26): 9310-9317

**URL:** <https://www.wjgnet.com/2307-8960/full/v10/i26/9310.htm>

**DOI:** <https://dx.doi.org/10.12998/wjcc.v10.i26.9310>

## INTRODUCTION

Carotid artery stenting (CAS) has emerged as an alternative to carotid endarterectomy (CEA) in treating carotid artery stenosis[1]. With the development of instruments and techniques, CAS has become increasingly used. The most common complications for CAS are thromboembolic events. Acute carotid stent thrombosis (ACST) refers to thrombus formation in the carotid artery during or after the CAS procedure, which is rare but can be devastating[2]. The etiology, treatment strategy, and prognosis are not well reported in the past.

In the current study, we reported the treatment process of a case with ACST caused by a stent cutting plaque. The patient gave consent to use his medical record for educational and publication purposes. Then we reviewed the current published literature reporting cases of ACST to investigate the etiologies, management strategies, and prognosis for ACST.

## CASE PRESENTATION

### **Chief complaints**

A 65-year-old man visited the cardiovascular surgery department of our hospital for dizziness and transient left limb weakness for 2 mo. The patient was also diagnosed with abdominal aortic aneurysm (AAA) for 1 mo.

### **History of present illness**

Two months prior, the patient began to experience dizziness and transient left limb weakness without obvious inducement, which subsided within hours. The patient went to the local hospital to seek medical advice. The doctors found that the patient had right carotid artery stenosis and AAA.

### **History of past illness**

The patient denied any history of hypertension, diabetes mellitus, or coronary atherosclerotic disease but had a history of smoking for more than 40 years (20 cigarettes/d).

### **Personal and family history**

The patient denied any history of genetic disease and familial aggregation disease history.

### **Physical examination**

Abdominal palpation showed the presence of pulsatile mass, and auscultation showed murmur in the right carotid artery.

### **Laboratory examinations**

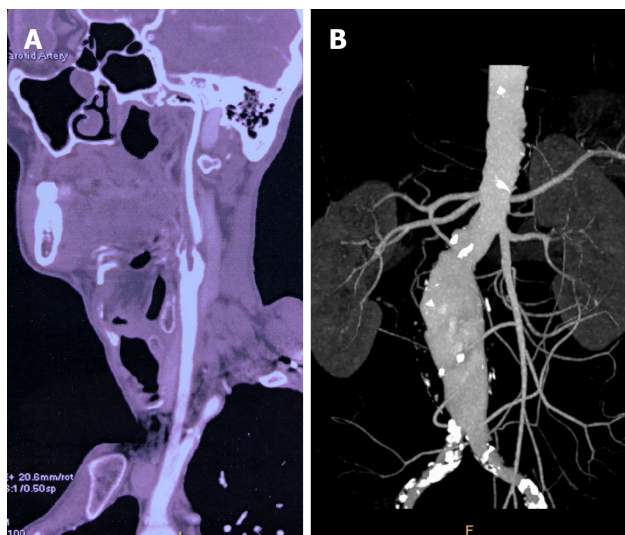
The blood routine test, liver function, renal function, coagulation function, and myocardial infarction index were all in normal range.

### **Imaging examinations**

Carotid ultrasonography and computed tomography angiography (CTA) showed 95% stenosis of the right internal carotid artery (ICA). Aortic CTA showed infrarenal AAA with a maximum diameter of 53 mm and mural thrombus formation (Figure 1).

## FINAL DIAGNOSIS

The patient was diagnosed with combined symptomatic ICA stenosis and infrarenal AAA.



DOI: 10.12998/wjcc.v10.i26.9310 Copyright ©The Author(s) 2022.

**Figure 1 Pre-operative imaging examination.** A: Pre-operative computed tomography angiography (CTA) showed severe stenosis of right internal carotid artery; B: Aortic CTA showed infrarenal abdominal aortic aneurysm with maximum diameter of 53 mm.

## TREATMENT

For ICA stenosis, pre-operative CTA showed that the plaque was relatively soft with less calcification. According to plaque morphology (the PLAC Scale) on CTA[3,4], soft plaque and lower grade of calcification were associated with a better stenting outcome. Due to transient ischemia attack (TIA) 2 mo prior, we preferred to carry out CAS in the patient. For the combined infrarenal AAA, it is uncomplicated with enough landing zone. The estimated time for endovascular aneurysm repair (EVAR) procedure is not long. So we planned to perform right CAS and standard EVAR simultaneously. Before the procedure, 100 mg aspirin and 75 mg clopidogrel daily were given for 5 d. The procedure was performed under general anesthesia. During the procedure, the activated clotting time was 302 s after administration of 6000 IU unfractionated heparin. CTA showed 95% stenosis at the proximal part of the right ICA. Then pre-dilatation with 4.0-20 mm and 5.0-20 mm balloons (AVIATOR; Abbott Laboratories, Chicago, IL, United States) was performed sequentially, under the protection of an embolism protection device (EPD, Emboshield NAV6; Abbott). A taper stent (9-7 mm 40 mm, XACT Carotid Stent System; Abbott) was implanted. Post-procedure angiography showed contrast agent retention in the stent, and the distal of ICA was obliterated. ICA spasm and plaque debris-occluded EPD were suspected. Then we gave the patient 30 mg papaverine and retrieved the EPD. Subsequent angiography showed the ICA was patent with 40% residual stenosis because of the spasm. After another 3000 IU unfractionated heparin was administered, standard EVAR was performed with a stent graft system (2316170, Endurant AAA Stent Graft System; Medtronic, Minneapolis, MN, United States) that was implanted smoothly. After EVAR, we performed another carotid angiography to evaluate whether the ICA spasm was alleviated. However, we found acute thrombus formation in the stent (Figure 2). Due to concerns about thrombus migration and distal embolization, we did not try to aspirate the thrombus through the catheter. Instead, we performed CEA immediately to remove the carotid stent and thrombus. Then we carried out the standard CEA procedure with a shunt (Braun; Aesculap, Inc., Kelaryes, PA, United States) implantation and patch (Edwards Lifesciences, Irvine, CA, United states) angioplasty. During the CEA procedure, we found that the stent was occluded by the plaque debris (Figure 3).

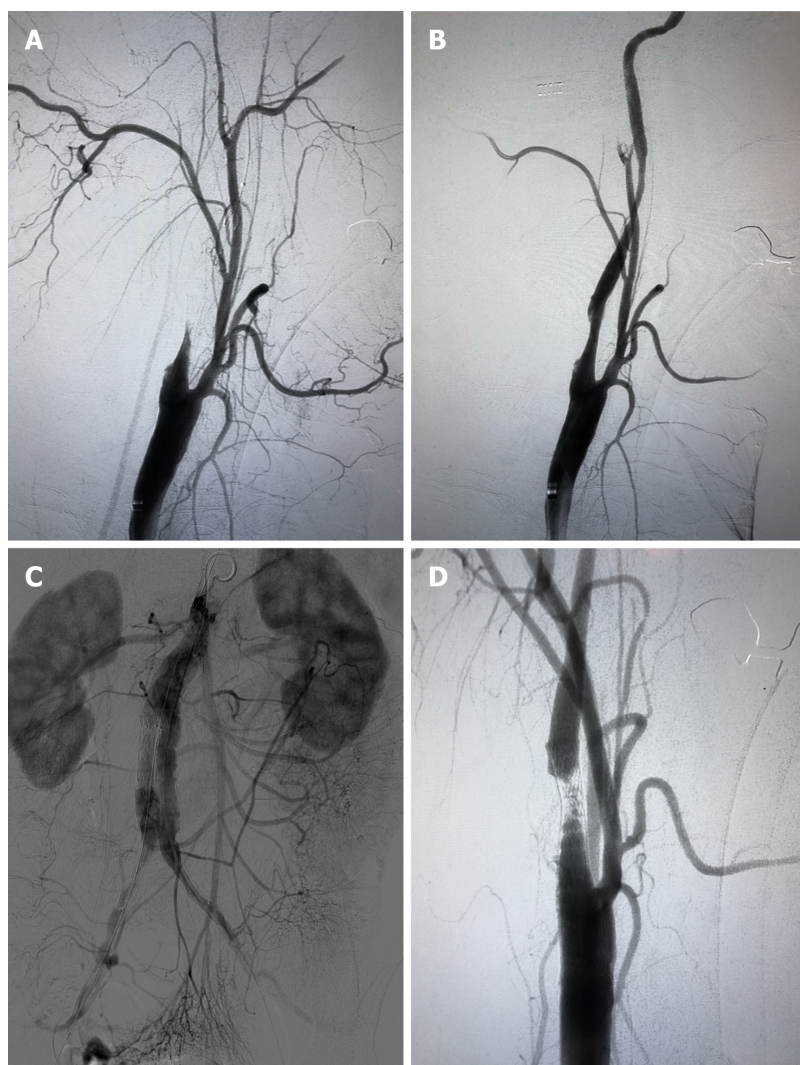
## OUTCOME AND FOLLOW-UP

The patient was conscious and his limbs moved freely after awaking from general anesthesia after CEA. The patient also had no neurological deficit at the 1-year follow-up (Figure 4).

## DISCUSSION

A systematic literature search using PubMed, MEDLINE, EMBASE, CNKI, Google Scholar, and Cochrane databases was conducted for all relevant published papers reporting cases of ACST. Finally,





DOI: 10.12998/wjcc.v10.i26.9310 Copyright ©The Author(s) 2022.

**Figure 2 The interventional procedure.** A: The distal of the internal carotid artery (ICA) was obliterated; B: The ICA was patent with about 40% residual stenosis after the embolism protection device was retrieved; C: Angiography after endovascular aortic repair (EVAR); D: After EVAR, carotid angiography showed acute thrombus formation in the stent.

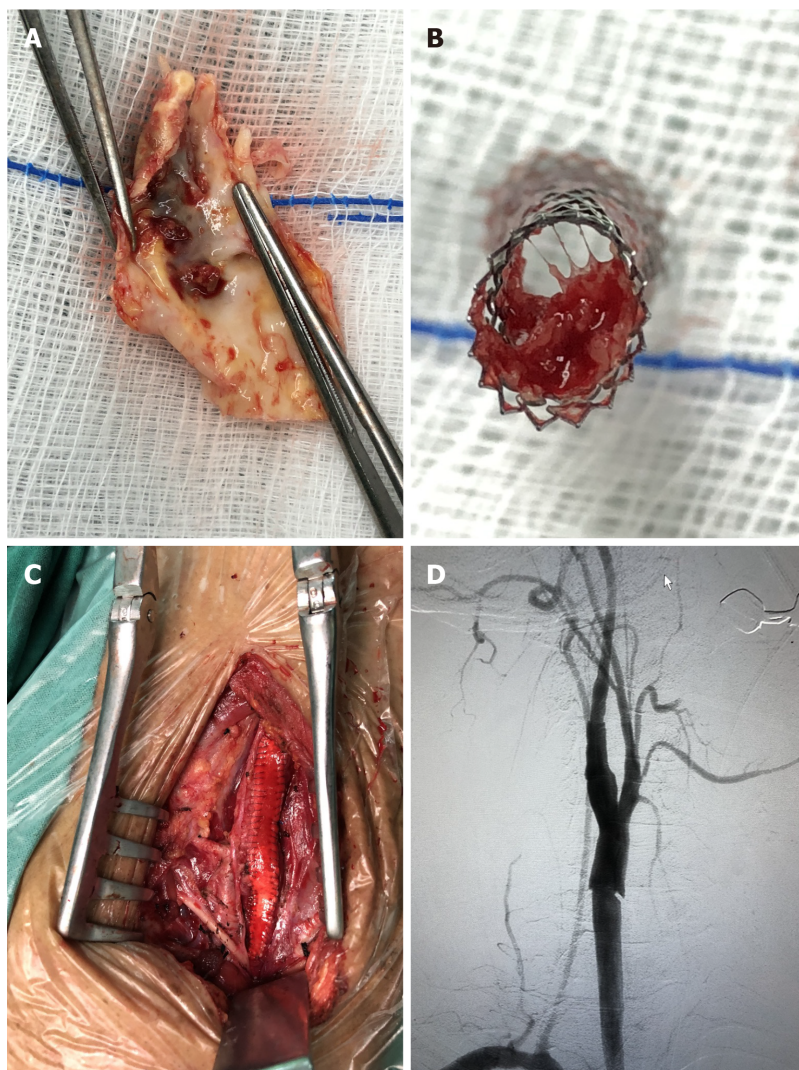
26 articles with 43 ACST met the inclusion criteria (Figure 5)[5-30].

CAS has become an alternative treatment to CEA for carotid artery stenosis. The most common complication for CAS is peri-procedure stroke[31]. The incidence of ACST is rare, which is reportedly 0.5%-2%[21]. Though rare, delayed recanalization of ICA or inappropriate management may lead to devastating consequences.

The etiology of ACST is multifactorial. Inadequate, cessation, or resistance of anti-platelet agent is an important reason. The incidence of acetylsalicylic acid resistance is 5.5%-45% and the incidence of clopidogrel resistance is 4%-44%[12]. Pre-operative evaluation of sensitivity to anti-platelet agent is helpful. Light transmittance aggregometry is the golden standard to measure platelet aggregation.

Hypercoagulable state including cancer history, protein C deficiency, taking oral contraceptives, heparin-induced thrombocytopenia, and thalassemia are also common. For these patients, additional anti-coagulative agent may be necessary. Local factors such as plaque protrusion in stent and debris occluding the EPD occur occasionally. Embolic events occurring in atrial fibrillation patients accidentally after CAS is rare[5]. Iatrogenic injury, such as balloon burst during the procedure, should be avoided [22].

In our patient, no evidence of a hypercoagulable state was discovered. Pre-operative dual anti-platelet agent was given for 5 d. During the CAS and EVAR procedure, we gave the patient sufficient unfractionated heparin and the activated clotting time was suitable for interventional therapy. Stent cutting plaque could be found during CEA. We believe the initiating factor of platelet aggregation was the exposure of thrombogenic material after plaque rupture[13] in our case. The presence of TIA indicated that the plaque was not stable, but we did not attach enough importance to it and underestimated the risk of CAS. From our present case, we want to emphasize again that pre-operative plaque evaluation is very important for decrease the rate of plaque rupture and subsequent ACST. Vulnerable



DOI: 10.12998/wjcc.v10.i26.9310 Copyright ©The Author(s) 2022.

**Figure 3 The carotid endarterectomy procedure.** A: Plaque rupture and thrombus formation; B: The stent was occluded by the plaque debris and thrombus; C: Patch angioplasty was carried out during carotid endarterectomy (CEA); D: Angiography after CEA showed the internal carotid artery was patent.

or ulcerated plaque is more suitable for CEA instead of CAS. We did not evaluate whether the patient was resistant to aspirin or clopidogrel.

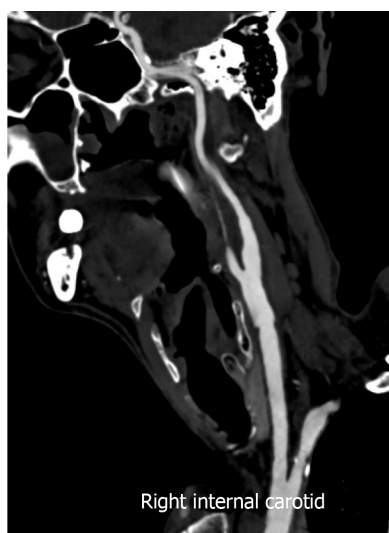
The present procedure was performed under general anesthesia for possible breath control during EVAR. This may decrease the patient's blood pressure and prolong operation time, which is another hidden reason for ACST. General anesthesia also made it impossible to perceive the patient's neurological deficit in time. For CAS procedure, local anesthesia with close intra-operative neurologic status monitoring is more suitable.

The best treatment strategy for ACST is controversial. Multiple methods have been reported, all without large series experience. Catheter-directed thrombolysis with alteplase, urokinase, and tenecteplase is mostly used. Most of the patients achieved successful complete or partial recanalization. Administration of abciximab intravenously or intra-arterially is also reportedly effective[18,28]. 'Facilitated thrombolysis' consisting of reduced dosage of de-thrombolysis (abciximab) and fibrinolysis (alteplase) may be beneficial with respect to both arterial recanalization and suppression of recurrent thrombosis[29].

Other endovascular management strategies include catheter thrombo-aspiration, balloon angioplasty, and subsequent stent implantation[5,10,13,16]. These methods are helpful for carotid revascularization, but balloon angioplasty and subsequent stent implantation may cause extra intima injury or damage stent structure.

The reported open surgical treatments include superficial temporal artery to middle cerebral artery (STA-MCA) bypass and CEA. STA-MCA bypass is considered second-line treatment, which may be beneficial to patients with ACST for whom intra-arterial thrombolysis is not available[14]. CEA with thorough stent removal and thrombus have shown favorable results[24]. We believe that urgent stent and thrombus removal should be performed for patients with plaque rupture and ACST to prevent thrombus extension and subsequent cerebral infarction. Unlike traditional CEA, extended exposure of





DOI: 10.12998/wjcc.v10.i26.9310 Copyright ©The Author(s) 2022.

Figure 4 Computed tomography angioplasty after 1 yr showed the internal carotid artery was patent without restenosis.

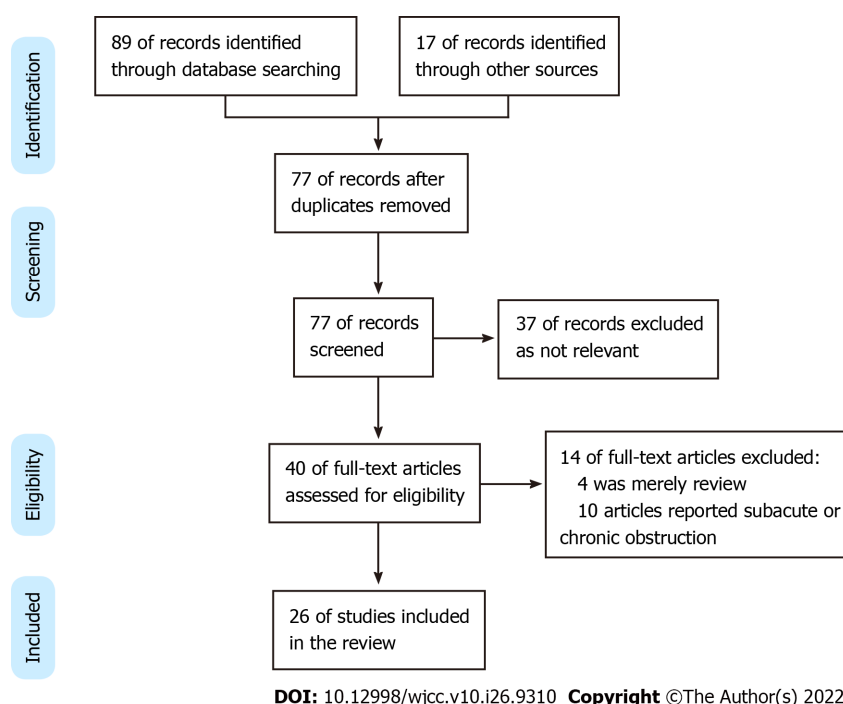


Figure 5 PRISMA flow chart for the study selection process.

carotid artery is required both proximally and distally in these situations. The ICA should be clamped first to prevent thrombosis dislocation when dissected the carotid artery. Fogarty catheter may be necessary to pull out the thrombus in distal ICA. Another reason that we chose CEA is that we did not have enough experience in endovascular treatment for ACST.

Mechanical thrombectomy using the Penumbra 4Max aspiration catheter and rheolytic thrombectomy system is also reportedly effective. Limited experience has shown that mechanical thrombectomy can effectively recanalize ICA with ACST, without the irritation of balloon angioplasty or stent deployment. The hemorrhagic risk is lower than thrombolysis. One advantage is that the patient can easily be switched to other treatment methods if necessary[21,28,30].

## CONCLUSION

The reason for ACST is multifactorial. Proper patient selection, normative anti-platelet treatment, and

perfect technical detail may decrease the incidence of ACST. Several treatment strategies such as thrombolysis, mechanical thrombectomy, and open surgery may be treatment options for ACST. Limited data have shown that carotid endarterectomy is effective with favorable results.

## FOOTNOTES

**Author contributions:** Zhang JB, Fan XQ, and Chen J contributed equally to this work; Zhang JB, Fan XQ, Chen J, and Ye ZD designed the study; Zhang JB, Fan XQ, Chen J, and Ye ZD conducted the study; Zhang JB, Fan XQ, and Liu P analyzed the data and wrote the manuscript; All authors have read and approved the final manuscript.

**Supported by** Elite Medical Professionals Project of China-Japan Friendship Hospital, No. ZRJY2021-QM13.

**Informed consent statement:** The patient gave consent to use his medical record for educational and publication purposes.

**Conflict-of-interest statement:** The authors have no conflicts to declare.

**CARE Checklist (2016) statement:** The authors have read the CARE Checklist (2016), and the manuscript was prepared and revised according to the CARE Checklist (2016).

**Open-Access:** This article is an open-access article that was selected by an in-house editor and fully peer-reviewed by external reviewers. It is distributed in accordance with the Creative Commons Attribution NonCommercial (CC BY-NC 4.0) license, which permits others to distribute, remix, adapt, build upon this work non-commercially, and license their derivative works on different terms, provided the original work is properly cited and the use is non-commercial. See: <https://creativecommons.org/licenses/by-nc/4.0/>

**Country/Territory of origin:** China

**ORCID number:** Jian-Bin Zhang 0000-0001-5586-5616; Xue-Qiang Fan 0000-0002-0208-4290; Jie Chen 0000-0003-4164-4526; Peng Liu 0000-0002-2653-0718; Zhi-Dong Ye 0000-0002-1282-3261.

**S-Editor:** Gong ZM

**L-Editor:** Filipodia

**P-Editor:** Gong ZM

## REFERENCES

- 1 **Brott TG**, Howard G, Roubin GS, Meschia JF, Mackey A, Brooks W, Moore WS, Hill MD, Mantese VA, Clark WM, Timaran CH, Heck D, Leimgruber PP, Sheffet AJ, Howard VJ, Chaturvedi S, Lal BK, Voeks JH, Hobson RW 2nd; CREST Investigators. Long-Term Results of Stenting versus Endarterectomy for Carotid-Artery Stenosis. *N Engl J Med* 2016; **374**: 1021-1031 [PMID: [26890472](#) DOI: [10.1056/NEJMoa1505215](#)]
- 2 **Nicosia A**, Nikas D, Castriota F, Biamino G, Cao P, Cremonesi A, Mathias K, Moussa I, Hopkins LN, Setacci C, Sievert H, Reimers B. Classification for carotid artery stenting complications: manifestation, management, and prevention. *J Endovasc Ther* 2010; **17**: 275-294 [PMID: [20557164](#) DOI: [10.1583/09-2943.1](#)]
- 3 **Pelz DM**, Lownie SP, Lee DH, Boulton MR. Plaque morphology (the PLAC Scale) on CT angiography: predicting long-term anatomical success of primary carotid stenting. *J Neurosurg* 2015; **123**: 856-861 [PMID: [25816084](#) DOI: [10.3171/2014.9.JNS14811](#)]
- 4 **Scullen T**, Mathkour M, Carr C, Wang A, Amenta PS, Nerva JD, Dumont AS. Anatomical Considerations for Endovascular Intervention for Extracranial Carotid Disease: A Review of the Literature and Recommended Guidelines. *J Clin Med* 2020; **9** [PMID: [33121192](#) DOI: [10.3390/jcm9113460](#)]
- 5 **Moulakakis KG**, Kakisis J, Tsiygoulis G, Zymvragoudakis V, Spiliopoulos S, Lazaris A, Sfyroeras GS, Mylonas SN, Vasdekis SN, Geroulakos G, Brountzos EN. Acute Early Carotid Stent Thrombosis: A Case Series. *Ann Vasc Surg* 2017; **45**: 69-78 [PMID: [28483628](#) DOI: [10.1016/j.avsg.2017.04.039](#)]
- 6 **Sorkin GC**, Dumont TM, Mokin M, Eller JL, Natarajan SK, Levy EI, Siddiqui AH. Hyperacute Carotid Stent Thrombosis During Emergent Revascularization Treated with Intraarterial Eptifibatide After Systemic Administration of Recombinant Tissue Plasminogen Activator. *J Vasc Interv Neurol* 2015; **8**: 50-55 [PMID: [26301032](#)]
- 7 **Setacci C**, de Donato G, Setacci F, Chisci E, Cappelli A, Pieraccini M, Castriota F, Cremonesi A. Surgical management of acute carotid thrombosis after carotid stenting: a report of three cases. *J Vasc Surg* 2005; **42**: 993-996 [PMID: [16275459](#) DOI: [10.1016/j.jvs.2005.06.031](#)]
- 8 **Hamann GF**, Liebetrau M, Pfefferkorn T, Heiss MM. Successful systemic thrombolysis for carotid stent thrombosis. *Eur Neurol* 2002; **48**: 37-39 [PMID: [12138309](#) DOI: [10.1159/000064956](#)]
- 9 **Chaturvedi S**, Sohrab S, Tselis A. Carotid stent thrombosis: report of 2 fatal cases. *Stroke* 2001; **32**: 2700-2702 [PMID: [11692038](#)]
- 10 **Murray NM**, Wolman DN, Marks M, Dodd R, Do HM, Lee JT, Heit JJ. Endovascular Treatment of Acute Carotid Stent Occlusion: Aspiration Thrombectomy and Angioplasty. *Cureus* 2020; **12**: e7997 [PMID: [32523851](#) DOI: [10.7755/cureus.7997](#)]

- 10.7759/cureus.7997]
- 11 **Toljan K**, Jovanović I, Starčević K, Ljevak J, Blažević N, Radoš M, Poljaković Z. Acute Carotid Stent Thrombosis in an Ultrarapid Clopidogrel Metabolizer: Case Report and Literature Review. *Vasc Endovascular Surg* 2019; **53**: 602-605 [PMID: 31272299 DOI: 10.1177/1538574419857965]
  - 12 **Köklü E**, Yüksel İÖ, Bayar N, Arslan Ş. Is Acute Carotid Artery Stent Thrombosis an Avoidable Complication? *J Stroke Cerebrovasc Dis* 2015; **24**: 2219-2222 [PMID: 26303788 DOI: 10.1016/j.jstrokecerebrovasdis.2015.05.029]
  - 13 **Köklü E**, Arslan Ş, Yüksel İÖ, Bayar N, Koç P. Acute Carotid Artery Stent Thrombosis Due to Dual Antiplatelet Resistance. *Cardiovasc Intervent Radiol* 2015; **38**: 1011-1014 [PMID: 25117620 DOI: 10.1007/s00270-014-0959-1]
  - 14 **Choi HJ**, Kim ST, Jeong YG, Jeong HW. Superficial temporal artery-middle cerebral artery anastomosis for internal carotid artery occlusion by subacute in-stent thrombosis after carotid artery stenting. *J Korean Neurosurg Soc* 2012; **52**: 551-554 [PMID: 23346328 DOI: 10.3340/jkns.2012.52.6.551]
  - 15 **Hu W**, Wang L, Wang G. Acute In-Stent Thrombosis after Carotid Angioplasty and Stenting: A Case Report and Literature Review. *Interv Neurol* 2018; **7**: 265-270 [PMID: 29765396 DOI: 10.1159/000486247]
  - 16 **Iwamoto Y**, Kitano T, Matsubara S, Uno M, Yagita Y. In-stent thrombosis after carotid artery stenting in a patient with protein C deficiency. *Neurol Sci* 2018; **39**: 2229-2230 [PMID: 30145678 DOI: 10.1007/s10072-018-3544-6]
  - 17 **Kanemaru K**, Nishiyama Y, Yoshioka H, Satoh K, Hashimoto K, Hanihara M, Horikoshi T, Ozaki Y, Kinouchi H. In-stent thrombosis after carotid artery stenting despite sufficient antiplatelet therapy in a bladder cancer patient. *J Stroke Cerebrovasc Dis* 2013; **22**: 1196-1200 [PMID: 23834849 DOI: 10.1016/j.jstrokecerebrovasdis.2012.12.015]
  - 18 **Stotts G**, Skinner C, Code C, Lawrie G, Lesiuk H, Lum C. Acute stent occlusion due to heparin induced thrombocytopenia and thrombosis during carotid artery stenting. *J Neurointerv Surg* 2012; **4**: e34 [PMID: 22131443 DOI: 10.1136/neurintsurg-2011-010121]
  - 19 **Moulakakis KG**, Lazaris AM. Emergent Carotid Stent Removal after Carotid Stent Thrombosis. *Ann Vasc Surg* 2018; **46**: 401-406 [PMID: 28887238 DOI: 10.1016/j.avsg.2017.08.014]
  - 20 **Masuo O**, Terada T, Matsuda Y, Ogura M, Tsumoto T, Yamaga H, Itakura T. Successful recanalization by in-stent percutaneous transluminal angioplasty with distal protection for acute carotid stent thrombosis. *Neurol Med Chir (Tokyo)* 2006; **46**: 495-499 [PMID: 17062989 DOI: 10.2176/nmc.46.495]
  - 21 **Kim YW**, Kang DH, Hwang JH, Park J, Hwang YH, Kim YS. Rescue strategy for acute carotid stent thrombosis during carotid stenting with distal filter protection using forced arterial suction thrombectomy with a reperfusion catheter of the Penumbra System: a technical note. *Acta Neurochir (Wien)* 2013; **155**: 1583-1588 [PMID: 23689967 DOI: 10.1007/s00701-013-1744-7]
  - 22 **Iancu A**, Grosz C, Lazar A. Acute carotid stent thrombosis: review of the literature and long-term follow-up. *Cardiovasc Revasc Med* 2010; **11**: 110-113 [PMID: 20347802 DOI: 10.1016/j.carrev.2009.02.008]
  - 23 **Tong FC**, Cloft HJ, Joseph GJ, Samuels OB, Dion JE. Abciximab rescue in acute carotid stent thrombosis. *AJNR Am J Neuroradiol* 2000; **21**: 1750-1752 [PMID: 11039360]
  - 24 **Staudt MD**, Mayich MS, Lownie SP. Emergent Carotid Endarterectomy with Open Thrombectomy for Acute Carotid Stent Occlusion. *World Neurosurg* 2020; **138**: 52 [PMID: 32142949 DOI: 10.1016/j.wneu.2020.02.123]
  - 25 **Cvjetko I**, Đaković Bacalja I, Cvjetko T. Acute Carotid Artery Stent Thrombosis. *Cardiovasc Intervent Radiol* 2018; **41**: 355-356 [PMID: 29038879 DOI: 10.1007/s00270-017-1808-9]
  - 26 **Markatis F**, Petrosyan A, Abdulamit T, Bergeron P. Acute carotid stent thrombosis: a case of surgical revascularization and review of treatment options. *Vascular* 2012; **20**: 217-220 [PMID: 22577161 DOI: 10.1258/vasc.2011.cr0303]
  - 27 **Seo KD**, Lee KO, Kim DJ, Lee KY. Rescue use of tirofiban for acute carotid in-stent thrombosis. *Yonsei Med J* 2008; **49**: 163-166 [PMID: 18306485 DOI: 10.3349/ymj.2008.49.1.163]
  - 28 **Munich S**, Moftakhar R, Lopes D. Recanalization of acute carotid stent occlusion using Penumbra 4Max aspiration catheter: technical report and review of rescue strategies for acute carotid stent occlusion. *J Neurointerv Surg* 2014; **6**: e42 [PMID: 24151116 DOI: 10.1136/neurintsurg-2013-010706.rep]
  - 29 **Steiner-Böker S**, Cejna M, Nasel C, Minar E, Kopp CW. Successful revascularization of acute carotid stent thrombosis by facilitated thrombolysis. *AJNR Am J Neuroradiol* 2004; **25**: 1411-1413 [PMID: 15466343]
  - 30 **Bush RL**, Bhama JK, Lin PH, Lumsden AB. Transient ischemic attack due to early carotid stent thrombosis: successful rescue with rheolytic thrombectomy and systemic abciximab. *J Endovasc Ther* 2003; **10**: 870-874 [PMID: 14656189 DOI: 10.1177/152660280301000504]
  - 31 **Lamanna A**, Maingard J, Barras CD, Kok HK, Handelman G, Chandra RV, Thijs V, Brooks DM, Asadi H. Carotid artery stenting: Current state of evidence and future directions. *Acta Neurol Scand* 2019; **139**: 318-333 [PMID: 30613950 DOI: 10.1111/ane.13062]



Published by **Baishideng Publishing Group Inc**  
7041 Koll Center Parkway, Suite 160, Pleasanton, CA 94566, USA

**Telephone:** +1-925-3991568

**E-mail:** [bpgoffice@wjgnet.com](mailto:bpgoffice@wjgnet.com)

**Help Desk:** <https://www.f6publishing.com/helpdesk>

<https://www.wjgnet.com>

