

World Journal of *Clinical Cases*

World J Clin Cases 2022 February 6; 10(4): 1140-1456



Contents

Thrice Monthly Volume 10 Number 4 February 6, 2022

REVIEW

- 1140** COVID-19: Gastrointestinal manifestations, liver injury and recommendations
Ozkurt Z, Çınar Tanrıverdi E

ORIGINAL ARTICLE

Retrospective Study

- 1164** Continuous intravenous infusion of recombinant human endostatin using infusion pump plus chemotherapy in non-small cell lung cancer
Qin ZQ, Yang SF, Chen Y, Hong CJ, Zhao TW, Yuan GR, Yang L, Gao L, Wang X, Lu LQ
- 1172** Sequential sagittal alignment changes in the cervical spine after occipitocervical fusion
Zhu C, Wang LN, Chen TY, Mao LL, Yang X, Feng GJ, Liu LM, Song YM
- 1182** Importance of the creation of a short musculofascial tunnel in peritoneal dialysis catheter placement
Lee CY, Tsai MK, Chen YT, Zhan YJ, Wang ML, Chen CC
- 1190** Clinical effect of methimazole combined with selenium in the treatment of toxic diffuse goiter in children
Zhang XH, Yuan GP, Chen TL
- 1198** Clinical study on the minimally invasive percutaneous nephrolithotomy treatment of upper urinary calculi
Xu XJ, Zhang J, Li M, Hou JQ

Observational Study

- 1206** Comparison of diagnostic validity of two autism rating scales for suspected autism in a large Chinese sample
Chu JH, Bian F, Yan RY, Li YL, Cui YH, Li Y
- 1217** Doctor-led intensive diet education on health-related quality of life in patients with chronic renal failure and hyperphosphatemia
Feng XD, Xie X, He R, Li F, Tang GZ

SYSTEMATIC REVIEWS

- 1226** What are the self-management experiences of the elderly with diabetes? A systematic review of qualitative research
Li TJ, Zhou J, Ma JJ, Luo HY, Ye XM

META-ANALYSIS

- 1242** Comparison of the clinical performance of i-gel and Ambu laryngeal masks in anaesthetised paediatric patients: A meta-analysis
Bao D, Yu Y, Xiong W, Wang YX, Liang Y, Li L, Liu B, Jin X

CASE REPORT

- 1255** Autogenous iliotibial band enhancement combined with tendon lengthening plasty to treat patella baja: A case report
Tang DZ, Liu Q, Pan JK, Chen YM, Zhu WH
- 1263** Sintilimab-induced autoimmune diabetes: A case report and review of the literature
Yang J, Wang Y, Tong XM
- 1278** Unicentric Castleman disease was misdiagnosed as pancreatic mass: A case report
Zhai HY, Zhu XY, Zhou GM, Zhu L, Guo DD, Zhang H
- 1286** Iguratimod in treatment of primary Sjögren's syndrome concomitant with autoimmune hemolytic anemia: A case report
Zhang J, Wang X, Tian JJ, Zhu R, Duo RX, Huang YC, Shen HL
- 1291** Primary central nervous system lymphoma presenting as a single choroidal lesion mimicking metastasis: A case report
Jang HR, Lim KH, Lee K
- 1296** Surgical treatment of acute cholecystitis in patients with confirmed COVID-19: Ten case reports and review of literature
Bozada-Gutiérrez K, Trejo-Avila M, Chávez-Hernández F, Parraguirre-Martínez S, Valenzuela-Salazar C, Herrera-Esquivel J, Moreno-Portillo M
- 1311** Hydrogen inhalation promotes recovery of a patient in persistent vegetative state from intracerebral hemorrhage: A case report and literature review
Huang Y, Xiao FM, Tang WJ, Qiao J, Wei HF, Xie YY, Wei YZ
- 1320** Ultrasound-guided needle release plus corticosteroid injection of superficial radial nerve: A case report
Zeng Z, Chen CX
- 1326** Inverted Y ureteral duplication with an ectopic ureter and multiple urinary calculi: A case report
Ye WX, Ren LG, Chen L
- 1333** Multiple miscarriages in a female patient with two-chambered heart and situs inversus totalis: A case report
Duan HZ, Liu JJ, Zhang XJ, Zhang J, Yu AY
- 1341** Chidamide combined with traditional chemotherapy for primary cutaneous aggressive epidermotropic CD8+ cytotoxic T-cell lymphoma: A case report
He ZD, Yang HY, Zhou SS, Wang M, Mo QL, Huang FX, Peng ZG
- 1349** Fatal rhabdomyolysis and disseminated intravascular coagulation after total knee arthroplasty under spinal anesthesia: A case report
Yun DH, Suk EH, Ju W, Seo EH, Kang H
- 1357** Left atrial appendage occlusion in a mirror-image dextrocardia: A case report and review of literature
Tian B, Ma C, Su JW, Luo J, Sun HX, Su J, Ning ZP

- 1366** Imaging presentation of biliary adenofibroma: A case report
Li SP, Wang P, Deng KX
- 1373** Multiple gouty tophi in the head and neck with normal serum uric acid: A case report and review of literatures
Song Y, Kang ZW, Liu Y
- 1381** Toxic epidermal necrolysis induced by ritodrine in pregnancy: A case report
Liu WY, Zhang JR, Xu XM, Ye TY
- 1388** Direct antiglobulin test-negative autoimmune hemolytic anemia in a patient with β -thalassemia minor during pregnancy: A case report
Zhou Y, Ding YL, Zhang LJ, Peng M, Huang J
- 1394** External penetrating laryngeal trauma caused by a metal fragment: A Case Report
Qiu ZH, Zeng J, Zuo Q, Liu ZQ
- 1401** Antegrade in situ laser fenestration of aortic stent graft during endovascular aortic repair: A case report
Wang ZW, Qiao ZT, Li MX, Bai HL, Liu YF, Bai T
- 1410** Hoffa's fracture in an adolescent treated with an innovative surgical procedure: A case report
Jiang ZX, Wang P, Ye SX, Xie XP, Wang CX, Wang Y
- 1417** Hemizygous deletion in the OTC gene results in ornithine transcarbamylase deficiency: A case report
Wang LP, Luo HZ, Song M, Yang ZZ, Yang F, Cao YT, Chen J
- 1423** Langerhans cell histiocytosis presenting as an isolated brain tumour: A case report
Liang HX, Yang YL, Zhang Q, Xie Z, Liu ET, Wang SX
- 1432** Inflammatory myofibroblastic tumor after breast prosthesis: A case report and literature review
Zhou P, Chen YH, Lu JH, Jin CC, Xu XH, Gong XH
- 1441** Eustachian tube involvement in a patient with relapsing polychondritis detected by magnetic resonance imaging: A case report
Yunaiyama D, Aoki A, Kobayashi H, Someya M, Okubo M, Saito K
- 1447** Endoscopic clipping for the secondary prophylaxis of bleeding gastric varices in a patient with cirrhosis: A case report
Yang GC, Mo YX, Zhang WH, Zhou LB, Huang XM, Cao LM

LETTER TO THE EDITOR

- 1454** Rituximab as a treatment for human immunodeficiency virus-associated nemaline myopathy: What does the literature have to tell us?
Gonçalves Júnior J, Shinjo SK

ABOUT COVER

Editorial Board Member of *World Journal of Clinical Cases*, Nicoleta-Monica Popa-Fotea, MD, PhD, Assistant Professor, Department of Cardio-thoracic, University of Medicine and Pharmacy, Bucharest 050474, Romania. nicoleta.popa-fotea@drd.umfcd.ro

AIMS AND SCOPE

The primary aim of *World Journal of Clinical Cases* (WJCC, *World J Clin Cases*) is to provide scholars and readers from various fields of clinical medicine with a platform to publish high-quality clinical research articles and communicate their research findings online.

WJCC mainly publishes articles reporting research results and findings obtained in the field of clinical medicine and covering a wide range of topics, including case control studies, retrospective cohort studies, retrospective studies, clinical trials studies, observational studies, prospective studies, randomized controlled trials, randomized clinical trials, systematic reviews, meta-analysis, and case reports.

INDEXING/ABSTRACTING

The WJCC is now indexed in Science Citation Index Expanded (also known as SciSearch®), Journal Citation Reports/Science Edition, Scopus, PubMed, and PubMed Central. The 2021 Edition of Journal Citation Reports® cites the 2020 impact factor (IF) for WJCC as 1.337; IF without journal self cites: 1.301; 5-year IF: 1.742; Journal Citation Indicator: 0.33; Ranking: 119 among 169 journals in medicine, general and internal; and Quartile category: Q3. The WJCC's CiteScore for 2020 is 0.8 and Scopus CiteScore rank 2020: General Medicine is 493/793.

RESPONSIBLE EDITORS FOR THIS ISSUE

Production Editor: Hua-Ge Yin; Production Department Director: Xu Guo; Editorial Office Director: Jin-Lei Wang.

NAME OF JOURNAL

World Journal of Clinical Cases

ISSN

ISSN 2307-8960 (online)

LAUNCH DATE

April 16, 2013

FREQUENCY

Thrice Monthly

EDITORS-IN-CHIEF

Bao-Gan Peng, Jerzy Tadeusz Chudek, George Kontogeorgos, Maurizio Serati, Ja Hyeon Ku

EDITORIAL BOARD MEMBERS

<https://www.wjgnet.com/2307-8960/editorialboard.htm>

PUBLICATION DATE

February 6, 2022

COPYRIGHT

© 2022 Baishideng Publishing Group Inc

INSTRUCTIONS TO AUTHORS

<https://www.wjgnet.com/bpg/gerinfo/204>

GUIDELINES FOR ETHICS DOCUMENTS

<https://www.wjgnet.com/bpg/GerInfo/287>

GUIDELINES FOR NON-NATIVE SPEAKERS OF ENGLISH

<https://www.wjgnet.com/bpg/gerinfo/240>

PUBLICATION ETHICS

<https://www.wjgnet.com/bpg/GerInfo/288>

PUBLICATION MISCONDUCT

<https://www.wjgnet.com/bpg/gerinfo/208>

ARTICLE PROCESSING CHARGE

<https://www.wjgnet.com/bpg/gerinfo/242>

STEPS FOR SUBMITTING MANUSCRIPTS

<https://www.wjgnet.com/bpg/GerInfo/239>

ONLINE SUBMISSION

<https://www.f6publishing.com>



Retrospective Study

Sequential sagittal alignment changes in the cervical spine after occipitocervical fusion

Ce Zhu, Lin-Nan Wang, Tai-Yong Chen, Li-Li Mao, Xi Yang, Gan-Jun Feng, Li-Min Liu, Yue-Ming Song

ORCID number: Ce Zhu 0000-0003-3072-853X; Lin-Nan Wang 0000-0003-1992-0838; Tai-Yong Chen 0000-0003-4243-0407; Li-Li Mao 0000-0003-1665-1193; Xi Yang 0000-0001-7925-3323; Gan-Jun Feng 0000-0002-9967-9249; Li-Min Liu 0000-0001-9760-617X; Yue-Ming Song 0000-0002-2377-0740.

Author contributions: Zhu C and Wang LN conceptualized and designed the study, and drafted the initial manuscript; Chen TY and Mao LL carried out the initial analyses, and reviewed and revised the manuscript; Yang X, Feng GJ, Liu LM, and Song YM coordinated and supervised the data collection, and critically reviewed and revised the manuscript for important intellectual content; Zhu C and Wang LN contributed equally to this work; all authors approved the final manuscript as submitted and agree to be accountable for all aspects of the work.

Institutional review board

statement: The study was reviewed and approved by the Ethics Committee of West China Hospital, Sichuan University (No. 2019762).

Informed consent statement:

Written informed consent was obtained from the patients for

Ce Zhu, Lin-Nan Wang, Xi Yang, Gan-Jun Feng, Li-Min Liu, Yue-Ming Song, Department of Orthopedics Surgery and Orthopedics Research Institute, West China Hospital of Sichuan University, Chengdu 610041, Sichuan Province, China

Tai-Yong Chen, Department of Orthopedics Surgery, The Second Affiliated Hospital of Zunyi Medical University, Zunyi 563000, Guizhou Province, China

Li-Li Mao, Department of Ultrasound, Hospital of Traditional Chinese Medicine Affiliated to Southwest Medical University, Luzhou 646000, Sichuan Province, China

Corresponding author: Xi Yang, MD, Associate Professor, Department of Orthopedics Surgery and Orthopedics Research Institute, West China Hospital of Sichuan University, No. 37 Guoxue Road, Chengdu 610041, Sichuan Province, China. formosa88@163.com

Abstract

BACKGROUND

There are few studies regarding sequential changes in the sagittal alignment of the upper and lower cervical regions of the spine after occipitocervical fusion (OCF). In addition, no comparisons of cervical sagittal alignment (CSA) between patients with craniocervical junction disorders (CJDs) and normal populations have been reported.

AIM

To compare the CSA of patients with CJDs with that of normal controls and investigate the sequential changes in the CSA of the upper and lower cervical spine after OCF.

METHODS

Eighty-four patients who underwent OCF (OCF group) and 42 asymptomatic volunteers (control group) were included. Radiographic parameters, including the occipital to C2 angle (O-C2a), occipital and external acoustic meatus to axis angle (O-EAa), C2-7 angle (C2-7a), and pharyngeal inlet angle (PIA), were measured and compared pre- and postoperatively. The correlations among the parameters were analyzed using Pearson's correlation test.

RESULTS

The O-C2a and PIA of the OCF group were smaller than those of the control group, while their O-EAa and C2-7a values were larger than those of the normal

publication of this case report and any accompanying images.

Conflict-of-interest statement: The authors declare they have no conflicts of interest to disclose.

Data sharing statement: No additional data are available.

Supported by The Key Research and Development Project of Science & Technology Department of Sichuan Province, No. 2017SZ0046, No. 2017SZDZX0021, and No. 2021YFG0240.

Country/Territory of origin: China

Specialty type: Medicine, research and experimental

Provenance and peer review: Unsolicited article; Externally peer reviewed.

Peer-review model: Single blind

Peer-review report's scientific quality classification

Grade A (Excellent): 0
Grade B (Very good): 0
Grade C (Good): C
Grade D (Fair): D
Grade E (Poor): 0

Open-Access: This article is an open-access article that was selected by an in-house editor and fully peer-reviewed by external reviewers. It is distributed in accordance with the Creative Commons Attribution NonCommercial (CC BY-NC 4.0) license, which permits others to distribute, remix, adapt, build upon this work non-commercially, and license their derivative works on different terms, provided the original work is properly cited and the use is non-commercial. See: <https://creativecommons.org/licenses/by-nc/4.0/>

Received: September 6, 2021

Peer-review started: September 6, 2021

First decision: October 29, 2021

Revised: November 13, 2021

Accepted: December 31, 2021

Article in press: December 31, 2021

Published online: February 6, 2022

controls. There were no significant differences in O-C2a, C2-7a, or PIA in the OCF group at baseline, 1 mo, or the final follow-up after surgery. The Pearson's correlation results showed that there were significant correlations between the O-C2a and C2Ta, C2-7a, C2-7 sagittal vertical axis (SVA), and PIA at 1 mo after OCF surgery and between O-C2a and O-EAa, C2Ta, C2-7a, C2-7 SVA, and PIA at the final follow-up.

CONCLUSION

Patients with CJDs have a more kyphotic upper CSA and a more lordotic lower CSA than normal controls. The effectiveness of OCF surgery in restoring CSA may be limited by the realignment of the craniocervical junction being neglected. The reduction in O-C2a after OCF surgery may increase C2-7a and decrease PIA.

Key Words: Sagittal alignment; Occipitocervical fusion; Craniocervical disorders; Cervical spine; Dysphagia

©The Author(s) 2022. Published by Baishideng Publishing Group Inc. All rights reserved.

Core Tip: Patients with craniocervical junction disorders had a more kyphotic upper cervical sagittal alignment (CSA) and a more lordotic lower CSA than normal controls: The decreased lordosis of the upper cervical spine caused by the weakness of paraspinal muscles and ligaments (OC2a↓) led to the gravity center of the cranium moving forward (C2Ta↑). To maintain horizontal gaze and normal C2-7 sagittal vertical axis, the lordosis of the lower cervical spine was increased (C2-7a↑). Moreover, the restoration of CSA after occipitocervical fusion (OCF) may be limited by neglecting the realignment of craniocervical junction. The reduction of the O-C2a after OCF would increase the C2-7a and decrease the pharyngeal inlet angle and lead to postoperative dysphagia.

Citation: Zhu C, Wang LN, Chen TY, Mao LL, Yang X, Feng GJ, Liu LM, Song YM. Sequential sagittal alignment changes in the cervical spine after occipitocervical fusion. *World J Clin Cases* 2022; 10(4): 1172-1181

URL: <https://www.wjgnet.com/2307-8960/full/v10/i4/1172.htm>

DOI: <https://dx.doi.org/10.12998/wjcc.v10.i4.1172>

INTRODUCTION

The cervical spine can be classified into two parts: The upper cervical spine (C0-C2) and lower cervical spine (C3-C7). The sagittal alignments of the two parts are closely interrelated[1]. An imbalance in the upper and lower cervical regions of the spine can lead to poor cervical sagittal alignment (CSA), which correlates with headache, neck pain, and poor health-related quality of life (HRQOL)[2].

Several studies have explored the interrelationship between upper and lower CSA. Nojiri *et al*[1] and Lee *et al*[3] observed a significant negative correlation between the C0-2 and C2-7 angles in asymptomatic individuals. Huang *et al*[4] found that postoperative kyphosis in the lower cervical spine is associated with hyperlordotic atlantoaxial fusion. Kim *et al*[5] reported that anterior cervical discectomy and fusion in the lower cervical spine can induce improvements in regional lordosis at the surgical level and can subsequently cause changes in the upper cervical segment including upward inclinations of the C1 slope and C2 slope.

Occipitocervical fusion (OCF) was first described in 1927 and was suggested to be an effective and safe procedure for the surgical treatment of craniocervical junction disorders (CJDs) caused by congenital deformities, trauma, rheumatoid arthritis (RA), and degenerative processes[6]. Matsubayashi *et al*[7] found that the occipital to C7 angle (O-C7a) is regulated by the T1 slope and that the corresponding O-C7a is divided into the occipital to C2 angle (O-C2a) and C2-C7 angle (C2-7a), which have negative correlations with each other and then maintain horizontal gaze. Korovessis *et al*[8] demonstrated that postoperative O-C2a, pharyngeal inlet angle (PIA), and T1-slope safely predict HRQOL outcomes following OCF for fresh trauma.

P-Reviewer: Byeon H, Chhabra HS**S-Editor:** Fan JR**L-Editor:** Wang TQ**P-Editor:** Fan JR

However, there are few studies regarding sequential changes in the sagittal alignment of the upper and lower cervical regions of the spine after OCF. In addition, to our knowledge, no comparisons of CSA between patients with CJDs and normal populations have been reported. Thus, this study had two purposes: (1) To compare the CSA of patients with craniocervical disorders with that of a normal control population; and (2) To investigate the sequential changes in and interrelationships of the sagittal alignment of the upper and lower cervical regions of the spine after OCF.

MATERIALS AND METHODS

This was a retrospective study that was approved by the ethics committee of West China Hospital of Sichuan University and informed consent was obtained from all the patients. All methods were carried out in accordance with relevant guidelines and regulations.

Patients with CJDs who underwent OCF (OCF group) between April 2010 and May 2019 were included in the study. The inclusion criteria were as follows: (1) Age ≥ 18 years; (2) Surgical treatment with OCF; (3) No history of spine surgery; and (4) At least 1 year of radiographic follow-up data with adequate visualization of the cervical spine on pre- and postoperative films. The exclusion criteria included a history of spine surgery or oropharyngeal surgery, and the presence of preoperative dysphagia, and dysphagia resulting from esophageal disease. For comparison, asymptomatic volunteers with no history of cervical disease or trauma and no neck, shoulder, or arm symptoms were also included in the study as a control group. These people were matched by age and sex with the patients in the OCF group.

All surgical procedures were performed by two senior surgeons from one medical team. We routinely used autologous iliac bones for fusion. The patients in the OCF group were divided into dysphagia and nondysphagia subgroups according to whether they had suffered postoperative dysphagia, as determined by face-to-face questioning or telephone interviews. Patients were defined as having dysphagia if they needed swallowing agents or pureed foods to avoid choking[9].

A lateral radiograph of the cervical spine was obtained at baseline, 1 mo, and the last follow-up after OCF surgery. The radiographic parameters assessed (Figure 1) were as follows based on previous studies[9-11]: O-C2a, which is the angle between the inferior end plate of C2 and the McGregor line that connects the hard palate and opisthion; the occipital and external acoustic meatus to axis angle (O-EAa), which is the angle formed by the McGregor line and the EA-line and connects the midpoint of the external acoustic meatuses and the midpoint of the inferior endplate of C2; the C2 tilting angle (C2Ta), which is the angle formed by the inferior endplate of C2 and the EA-line; C2-7a, which is the Cobb angle between the lower endplate of C2 and C7; the T1 slope, which is the angle between the horizontal and the T1 superior endplate; the C2-7 sagittal vertical axis (C2-7 SVA), which is the horizontal distance between the C2 plumb line and the posterior corner of C7; and the PIA[10], which is the angle between McGregor line and the line that links the center of the C1 anterior arch and the apex of the cervical sagittal curvature (or bottom when the cervical alignment is kyphotic). Positive values indicated lordosis, while negative values indicated kyphosis. The C2-7 SVA value was considered to be positive if the C2 plumb line was located in front of the posterior upper corner of the C7 vertebral body, and it was considered to be negative if the C2 plumb line was behind the posterior upper corner of the C7 vertebral body[12]. To avoid intraobserver bias, all radiological parameters were measured by two attending spinal surgeons who were not involved in the surgery, and the average value of their measurements was used for analysis.

Analyses were performed with SPSS software (version 22.0; IBM Corp., Armonk, NY, United States). Values are presented as the mean \pm SD. Quantitative data were analyzed using the Student's *t* test or Mann-Whitney *U* test, as appropriate. Categorical data were analyzed by the χ^2 test or Fisher's exact test. The relationships between variables were assessed using the Pearson's correlation test. *P* < 0.05 indicated statistical significance.

RESULTS

A total of 84 patients were included in the OCF group. The average patient age was 50.5 ± 15.0 years, and 45.2% (38/84) of patients were male. CJDs were caused by deformities (*n* = 63), trauma (*n* = 12), and RA (*n* = 9). The fusion levels were O-C2 (*n* =

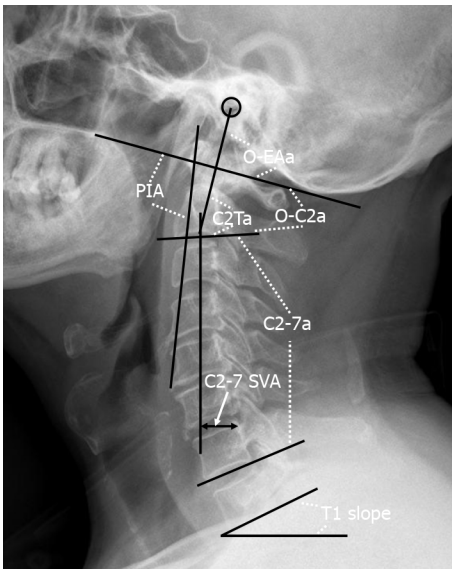


Figure 1 Representation of the radiographic measurements. O-C2a: The angle between the inferior endplate of C2 and the McGregor line; O-EAa: The angle formed by the McGregor line and the EA-line; C2Ta: The angle formed by the inferior endplate of C2 and the EA-line; C2-7a: The Cobb angle between the lower endplate of C2 and C7; T1 slope: The angle between the horizontal and the T1 superior endplate; C2-7 SVA: The horizontal distance between the C2 plumb line and the posterior corner of C7; PIA: The angle between McGregor line and the line that links the center of the C1 anterior arch and the apex of cervical sagittal curvature. O-C2a: O-C2 angle; O-EAa: Occipital and external acoustic meatus to axis angle; C2Ta: C2 tilting angle; C2-7a: C2-7 angle; SVA: Sagittal vertical axis; PIA: Pharyngeal inlet angle.

28), O-C3 ($n = 31$), O-C4 ($n = 18$), and O-C5 ($n = 7$). The postoperative follow-up period in the OCF group ranged from 12 to 78 mo (mean, 22.8 ± 16.6 mo).

For comparison, 42 asymptomatic volunteers were enrolled in the control group. The average age was 51.4 ± 12.4 years, and 47.6% (20/42) of patients were male. The differences in age and sex between the OCF group and control group were not significant ($P = 0.738$ and $P = 0.851$, respectively). The radiographic parameters in these two groups are listed in Table 1. The O-C2a and PIA of patients in the OCF group were significantly smaller than those of the patients in the control group ($P < 0.05$), while the O-EAa, C2Ta, and C2-7a of the OCF patients were significantly larger than those of the normal controls ($P < 0.05$). Significant correlations were found between O-C2a and C2Ta ($r = -0.872$), C2-7a ($r = -0.585$), and PIA ($r = 0.757$) in the OCF group and between O-C2a and O-EAa ($r = 0.309$), C2Ta ($r = -0.802$), C2-7a ($r = -0.385$), C2-7 SVA ($r = 0.331$), and PIA ($r = 0.579$) in the control group (Table 2).

The radiological parameters of patients in the OCF group before surgery, 1 mo after surgery, and at the last follow-up after OCF surgery are reported in Table 1. There were no significant differences in O-C2a, C2-7a, or PIA at baseline, 1 mo after surgery, or the final follow-up after surgery ($P > 0.05$). Compared with the asymptomatic volunteers in the control group, the patients in the OCF group had significantly smaller O-C2a and PIA values after OCF surgery ($P < 0.05$) and significantly larger O-EAa, C2Ta, and C2-7a values ($P < 0.05$). The results of the Pearson's correlation analysis of O-C2a and the other parameters showed that there were significant correlations between O-C2a and C2Ta ($r = -0.840$, $P = 0.000$), C2-7a ($r = -0.333$, $P = 0.002$), C2-7 SVA ($r = 0.218$, $P = 0.046$), and PIA ($r = 0.744$, $P = 0.000$) at 1 mo after OCF surgery and between O-C2a and -EAa ($r = 0.346$, $P = 0.001$), C2Ta ($r = -0.764$, $P = 0.000$), C2-7a ($r = -0.314$, $P = 0.004$), C2-7 SVA ($r = 0.293$, $P = 0.007$), and PIA ($r = 0.495$, $P = 0.000$) at the final follow-up.

There were 20 patients with dysphagia and 64 patients without dysphagia in the OCF group. No significant intergroup differences were found in terms of age (52.2 ± 12.8 vs 49.9 ± 15.7 , $P = 0.555$), fusion level ($\leq C3$ / $> C3$: 16/4 vs 44/20, $P = 0.405$), the proportion of patients with RA (4/20 vs 6/64, $P = 0.185$), or the proportion of patients with AS (13/20 vs 40/60, $P = 0.840$). However, the proportion of female patients was significantly higher in the patients with dysphagia (16/20) than in the patients without (30/64) ($P = 0.019$). The details of the radiological parameters of the patients with and without dysphagia at baseline, 1 mo after the surgery, and the final follow-up after OCF surgery are shown in Table 3.

Table 1 Radiological parameters of patients in the occipitocervical fusion and control groups

	OCF (n = 84)			Control (n = 42)
	Pre-op	Post-op	Final follow-up	
O-C2a (°)	4.7 ± 15.3	4.6 ± 12.6	4.7 ± 13.3	12.0 ± 8.2 ^{a,b,c}
O-EAa (°)	101.1 ± 8.5	99.4 ± 7.7	99.0 ± 9.1	92.2 ± 5.4 ^{a,b,c}
C2Ta (°)	96.5 ± 17.3	94.8 ± 13.5	94.2 ± 13.2	80.0 ± 8.6 ^{a,b,c}
C2-7a (°)	24.8 ± 18.1	21.7 ± 16.1	21.6 ± 15.8	16.2 ± 9.6 ^{a,b,c}
T1 slope (°)	23.2 ± 9.5	23.4 ± 8.2	21.5 ± 8.2	21.9 ± 7.2
C2-7 SVA (cm)	1.4 ± 1.1 ^c	1.5 ± 1.1 ^c	1.0 ± 1.0 ^{a,b}	1.5 ± 0.8 ^c
PIA (°)	91.6 ± 10.3	89.3 ± 10.1	88.8 ± 12.5	97.3 ± 7.5 ^{a,b,c}

^aP < 0.05 compared with pre-op.^bP < 0.05 compared with post-op.^cP < 0.05 compared with final follow-up.

OCF: Occipitocervical fusion; Pre-op: Preoperative; Post-op: Postoperative; O-C2a: O-C2 angle; O-EAa: Occipital and external acoustic meatus to axis angle; C2Ta: C2 tilting angle; C2-7a: C2-7 angle; SVA: Sagittal vertical axis; PIA: Pharyngeal inlet angle.

Table 2 Pearson product moment coefficient (Pearson's *r* value) between O-C2 angle and C2-7 angle and other parameters in the occipitocervical fusion and control groups

OCF (n = 84)	<i>r</i> value	<i>P</i> value	Control (n = 42)	<i>r</i> value	<i>P</i> value
O-C2a			O-C2a		
O-EAa	0.039	0.728	O-EAa	0.309	0.046
C2Ta	-0.872	0.000	C2Ta	-0.802	0.000
C2-7a	-0.585	0.000	C2-7a	-0.385	0.012
T1 slope	-0.174	0.214	T1 slope	-0.080	0.615
C2-7 SVA	0.067	0.545	C2-7 SVA	0.331	0.032
PIA	0.757	0.000	PIA	0.579	0.000
C2-7a			C2-7a		
O-C2a	-0.585	0.000	O-C2a	-0.385	0.012
O-EAa	0.023	0.837	O-EAa	-0.100	0.530
C2Ta	0.540	0.000	C2Ta	0.326	0.035
T1 slope	0.490	0.000	T1 slope	0.523	0.000
C2-7 SVA	-0.013	0.909	C2-7 SVA	-0.239	0.127
PIA	-0.546	0.000	PIA	-0.156	0.324

O-C2a: O-C2 angle; O-EAa: Occipital and external acoustic meatus to axis angle; C2Ta: C2 tilting angle; C2-7a: C2-7 angle; SVA: Sagittal vertical axis; PIA: Pharyngeal inlet angle.

DISCUSSION

Previous studies have explored the relations between the alignments of the upper and subaxial cervical regions of the spine in asymptomatic volunteers[1,13,14]. Nojiri *et al* [1] enrolled 313 asymptomatic individuals in their study and investigated the relationships between the alignments of the upper and lower cervical regions of the spine. They observed significant negative correlations between O-C2a and C2-7a and between C1-2a and C2-7a. The correlation coefficient between O-C2a and C2-7a was larger than that between C1-2a and C2-7a. Sherekar *et al*[13] also reported that O-C2a was negatively correlated with C2-7a. Guo *et al*[14] found that O-C2a was larger in females than in males, whereas C2-7a was significantly larger in males. Both C2-7a and O-C2a correlated significantly with age. In our study, the mean values of O-C2a

Table 3 Radiological parameters of patients with dysphagia and without dysphagia

		Dysphagia (n = 20)	Without dysphagia (n = 64)	P value
O-C2a (°)	Pre-op	9.7 ± 10.7	3.2 ± 16.2	0.046
	Post-op	0.9 ± 9.3 ^a	5.8 ± 13.3	0.128
	Final follow-up	1.3 ± 9.6 ^a	5.8 ± 14.1	0.182
O-EAa (°)	Pre-op	104.2 ± 7.8	100.2 ± 8.6	0.070
	Post-op	95.1 ± 8.3 ^a	100.8 ± 6.6	0.003
	Final follow-up	96.9 ± 6.5 ^a	99.7 ± 9.7	0.240
C2Ta (°)	Pre-op	94.5 ± 13.1	97.1 ± 18.5	0.478
	Post-op	94.3 ± 14.1	94.9 ± 13.4	0.851
	Final follow-up	95.6 ± 10.6	93.8 ± 14.0	0.598
C2-7a (°)	Pre-op	19.5 ± 14.3	26.4 ± 19.0	0.136
	Post-op	26.9 ± 13.5 ^a	20.0 ± 16.6	0.100
	Final follow-up	27.9 ± 12.6 ^a	19.6 ± 16.2	0.041
T1 slope (°)	Pre-op	21.5 ± 5.7	21.2 ± 11.1	0.340
	Post-op	21.5 ± 6.8	24.4 ± 8.9	0.226
	Final follow-up	22.7 ± 6.5	20.9 ± 9.1	0.436
C2-7 SVA (cm)	Pre-op	0.9 ± 0.9	1.6 ± 1.1	0.028
	Post-op	1.1 ± 1.3	1.6 ± 1.1	0.088
	Final follow-up	0.4 ± 1.1 ^b	1.2 ± 0.9	0.002
PIA (°)	Pre-op	95.0 ± 6.7	90.6 ± 11.0	0.035
	Post-op	82.0 ± 5.7 ^a	91.6 ± 10.2	0.000
	Final follow-up	86.3 ± 6.8 ^{a,b}	89.5 ± 13.7	0.321

^aP < 0.05 compared with pre-op.^bP < 0.05 compared with post-op.

Pre: Preoperative; Post: Postoperative; O-C2a: O-C2 angle; O-EAa: Occipital and external acoustic meatus to axis angle; C2Ta: C2 tilting angle; C2-7a: C2-7 angle; SVA: Sagittal vertical axis; PIA: Pharyngeal inlet angle.

and C2-7a in the asymptomatic volunteers were 12.0° and 16.2°, respectively, which were comparable with the results of previous studies[1,13,14]. A statistically significant negative correlation was also observed between O-C2a and C2-7a in the control group ($r = -0.385$, $P < 0.05$). In addition, the average value of O-EAa in the normal controls in this study was comparable to that in the healthy volunteers included in the study by Morizane *et al*[15] (92.2° vs 90.0°), who introduced the concept of O-EAa[15].

Compared to the patients with CJDs, the normal controls had a larger OC2a (12.0° vs 4.7°), while the O-EAa, C2Ta, and C2-7a were smaller (92.2° vs 101.1°, 80.0° vs 96.5°, 16.2° vs 24.8°, respectively). Based on these results, we speculated that the degree of lordosis of the upper cervical spine was markedly lower in the patients with these disorders because of weaknesses in vertebrae, muscles, and ligaments caused by craniocervical lesions (OC2a↓). Hypolordosis in the upper cervical spine caused the center of gravity of the cranium to move forward (C2Ta↑). Finally, the degree of lordosis of the lower cervical spine increased to compensate for this change (C2-7a↑) so that the individuals could maintain a horizontal gaze and normal C2-7 SVA.

OCF can provide immediate rigidity and fusion in the treatment of CJDs. Although the best result that surgeons expect from OCF surgery is the restoration of normal physiologic occipitocervical alignment in patients, optimal craniocervical alignment has not been confirmed until now. Matsunaga *et al*[16] suggested that the position of fixation of the occipital bone and the axis should be within the range of 0-30° according to the O-C2a measurements of 240 healthy volunteers. Inada *et al*[17] indicated that excessive O-C2a lordotic correction should be avoided because it might induce a mid-to-lower cervical compensatory decrease in lordosis. Bagley *et al*[18] suggested that preoperative halo immobilization before OCF can guarantee

physiologic craniocervical neutrality and prevent related complications. This method allows patients to be in a comfortable position when they are awake and allows surgeons to adjust the craniocervical alignment before final fixation and fusion.

However, the results of our study showed that there were no significant changes in O-C2a or C2-7a from before to after OCF surgery. The O-C2a of the patients with craniocervical disorders at the last follow-up was still significantly smaller than that of the asymptomatic volunteers, while the C2-7a of those patients was larger. We considered the main reason to be that we focused on decompression, reduction, and fusion for the treatment of craniocervical disorders but neglected the importance of restoring craniocervical sagittal alignment.

Dysphagia was reported to be one of the most common complications caused by cervical sagittal malalignment after OCF, with an incidence ranging from 9.4% to 26.6% [9,10,19,20]. The mechanisms of postoperative dysphagia after OCF remain unclear and are speculated to be multifactorial. In the present study, O-C2a and PIA decreased significantly in the patients with dysphagia from before surgery to 1 mo after surgery, and the effect remained at the final follow-up, while C2-7a increased 1 mo postoperatively and remained the same at the last follow-up. However, the O-C2a, C2-7a, and PIA of the patients without dysphagia were comparable pre- and postoperatively. Pearson's correlation test showed that postoperative O-C2a values correlated significantly with C2-7a and PIA values. Our results were consistent with those of previous reports describing the relationship between CSA and postoperative dysphagia after OCF [10,19,20]. Based on these results, we assume that the mechanism by which postoperative dysphagia is caused by a reduction in O-C2a is as follows: When O-C2a decreases after OCF surgery, the degree of subaxial lordosis (C2-7a) increases to compensate for the decrease in occipitocervical lordosis so that the individual can maintain a horizontal gaze. Then, the apex of cervical spine lordosis protrudes anteriorly (PIA↓), which can compress and narrow the oropharyngeal space directly and lead to dysphagia (Figure 2).

Previous studies evaluated many factors that might lead to postoperative dysphagia, such as O-C2a, fused segments, age, pathologies, and subaxial cervical positioning [19,21]. However, O-C2a was the only significant independent variable correlated with dysphagia. Consequently, operative positioning of O-C2 is the most effective way to avoid postoperative dysphagia. Bagley *et al* [18] advocated that preoperative halo immobilization might allow patients to have their head fixed in a particular position and prevent dysphagia. Wang *et al* [9] and Meng *et al* [11] recommended that surgeons avoid O-C2a reductions greater than 5° during OCF surgery to prevent postoperative dysphagia. Huang and Gonda *et al* [21,22] attempted to maintain patients' head and neck neutrality by an algorithm based on the comparison of pre- and intraoperative X-rays and CT scans.

Our study has limitations. Although we found that the O-C2a, C2-7a, and PIA could not be corrected to the normal range by OCF while neglecting craniocervical realignment, we did not find a good method of restoring physiologic occipitocervical alignment in patients with CJDs. To date, there is no consensus on the best method to reestablish occipitocervical sagittal alignment because of its complexity. Many factors should be taken into account to restore optimal alignment, such as the duration of the craniocervical disease, cervical motions in different directions, the influence of the intraoperative position, variations across different techniques, and the impact on adjacent segments [19]. Therefore, more studies focusing on the basic biomechanics of the occipitocervical junction, the development of new instrumentations and techniques, and individualized treatment to restore ideal occipitocervical alignment are needed in the future. Moreover, our study was also limited by the retrospective nature and short follow-up period. Therefore, additional prospective studies with more patients and longer follow-up periods are needed to investigate both the clinical and radiographic outcomes of OCF patients.

CONCLUSION

Compared to a normal age-matched control population, patients with CJDs have a more kyphotic upper CSA and a more lordotic lower CSA. The effectiveness of the restoration of CSA provided by OCF surgery may be limited by the realignment of the craniocervical junction being neglected. The reduction in O-C2a after OCF surgery may increase C2-7a and decrease PIA.

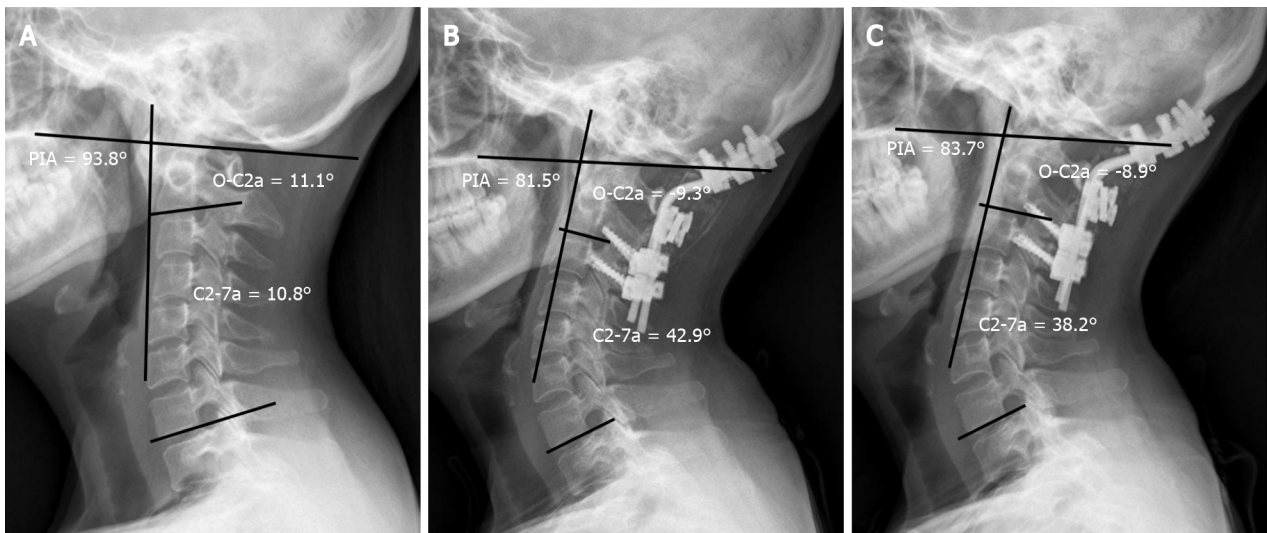


Figure 2 A 43-year-old woman developed dysphagia after occipitocervical fusion surgery. A: The preoperative O-C2 angle (O-C2a), C2-7 angle (C2-7a) and pharyngeal inlet angle (PIA) were 11.1°, 10.8°, and 93.8°, respectively; B: The OC2a and PIA decreased to -9.3° and 81.5°, respectively, while the C2-7a increased to 42.9° 1 mo postoperatively; C: At the 1-year follow-up, the O-C2a, C2-7a, and PIA were -8.9°, 38.2°, and 83.7°, respectively. O-C2a: O-C2 angle; C2-7a: C2-7 angle; PIA: Pharyngeal inlet angle.

ARTICLE HIGHLIGHTS

Research background

The studies regarding sequential changes of cervical sagittal alignment (CSA) after occipitocervical fusion (OCF) were limited.

Research motivation

The comprehension of sequential changes of CSA after OCF can help surgeons prevent postoperative complications after OCF.

Research objectives

To compare the CSA of patients with craniocervical junction disorders (CJDs) with that of normal controls and investigate the sequential changes in the CSA of the upper and lower cervical spine after OCF.

Research methods

Radiographic parameters including the occipital to C2 angle (O-C2a), occipital and external acoustic meatus to axis angle (O-EAa), C2-7 angle (C2-7a), and pharyngeal inlet angle (PIA) of the selected patients were measured and compared pre- and postoperatively.

Research results

The O-C2a and PIA of the OCF group were smaller than those of the control group, while their O-EAa and C2-7a values were larger than those of the normal controls. There were significant correlations between the O-C2a and C2Ta, C2-7a, C2-7 sagittal vertical axis (SVA), and PIA at 1 mo after OCF surgery and between O-C2a and O-EAa, C2Ta, C2-7a, C2-7 SVA, and PIA at the final follow-up.

Research conclusions

Patients with CJDs have a more kyphotic upper CSA and a more lordotic lower CSA than normal controls. The effectiveness of OCF surgery in restoring CSA may be limited by the realignment of the craniocervical junction being neglected. The reduction in O-C2a after OCF surgery may increase C2-7a and decrease PIA.

Research perspectives

This study provides novel insights for sequential changes of CSA after OCF.

ACKNOWLEDGEMENTS

We are grateful to Yi Zhu from McMaster University for his kind help in editing the language in this paper.

REFERENCES

- 1 Nojiri K, Matsumoto M, Chiba K, Maruiwa H, Nakamura M, Nishizawa T, Toyama Y. Relationship between alignment of upper and lower cervical spine in asymptomatic individuals. *J Neurosurg* 2003; **99**: 80-83 [PMID: 12859065 DOI: 10.3171/spi.2003.99.1.0080]
- 2 Patwardhan AG, Khayatadeh S, Havey RM, Voronov LI, Smith ZA, Kalmanson O, Ghanayem AJ, Sears W. Cervical sagittal balance: a biomechanical perspective can help clinical practice. *Eur Spine J* 2018; **27**: 25-38 [PMID: 29110218 DOI: 10.1007/s00586-017-5367-1]
- 3 Lee SH, Kim KT, Seo EM, Suk KS, Kwack YH, Son ES. The influence of thoracic inlet alignment on the craniocervical sagittal balance in asymptomatic adults. *J Spinal Disord Tech* 2012; **25**: E41-E47 [PMID: 22037167 DOI: 10.1097/BSD.0b013e3182396301]
- 4 Huang JC, Qian BP, Qiu Y, Yu Y, Ni HB. Surgical overreduction and hyperlordotic fusion of C1-C2 joint are associated with cervical sagittal malalignment. *Arch Orthop Trauma Surg* 2017; **137**: 1631-1639 [PMID: 28986674 DOI: 10.1007/s00402-017-2814-8]
- 5 Kim JT, Lee HJ, Choi DY, Shin MH, Hong JT. Sequential alignment change of the cervical spine after anterior cervical discectomy and fusion in the lower cervical spine. *Eur Spine J* 2016; **25**: 2223-2232 [PMID: 26821140 DOI: 10.1007/s00586-016-4401-z]
- 6 Kunakornsawat S, Pluemvitayaporn T, Pruttikul P, Punpichet S, Piyasakulkaew C, Arirachakaran A, Kongtharvonskul J. A new method for measurement of occipitocervical angle by occiput-C3 angle. *Eur J Orthop Surg Traumatol* 2017; **27**: 1051-1056 [PMID: 27832335 DOI: 10.1007/s00590-016-1881-9]
- 7 Matsubayashi Y, Shimizu T, Chikuda H, Takeshita K, Oshima Y, Tanaka S. Correlations of Cervical Sagittal Alignment before and after Occipitocervical Fusion. *Global Spine J* 2016; **6**: 362-369 [PMID: 27190739 DOI: 10.1055/s-0035-1563725]
- 8 Korovessis P, Mpountogianni E, Papaioannou I. Predictive value of sagittal craniocervical roentgenographic parameters for HRQOL after craniocervical fusion. *Eur J Orthop Surg Traumatol* 2021 [PMID: 34324031 DOI: 10.1007/s00590-021-03078-x]
- 9 Wang LN, Hu BW, Song YM, Liu LM, Zhou CG, Wang L, Zhou ZJ, Xiu P, Chen TY, Yang X. Predictive abilities of O-C2a and O-EAa for the development of postoperative dysphagia in patients undergoing occipitocervical fusion. *Spine J* 2020; **20**: 745-753 [PMID: 31778822 DOI: 10.1016/j.spinee.2019.11.013]
- 10 Kaneyama S, Sumi M, Takabatake M, Kasahara K, Kanemura A, Hirata H, Darden BV. The Prediction and Prevention of Dysphagia After Occipitospinal Fusion by Use of the S-line (Swallowing Line). *Spine (Phila Pa 1976)* 2017; **42**: 718-725 [PMID: 27779604 DOI: 10.1097/BRS.0000000000001963]
- 11 Meng Y, Wu T, Liu Z, Wen D, Rong X, Chen H, Lou J, Liu H. The impact of the difference in O-C2 angle in the development of dysphagia after occipitocervical fusion: a simulation study in normal volunteers combined with a case-control study. *Spine J* 2018; **18**: 1388-1397 [PMID: 29410299 DOI: 10.1016/j.spinee.2018.01.005]
- 12 Kong W, Yang X, Li Z, Hu B, Song Y. Analysis of the Cervical Sagittal Alignment in Patients with Unstable Hangman Fracture Under C2-3 Anterior Discectomy and Fusion. *World Neurosurg* 2020; **137**: e1-e8 [PMID: 31476470 DOI: 10.1016/j.wneu.2019.08.147]
- 13 Sherekar SK, Yadav YR, Basoor AS, Baghel A, Adam N. Clinical implications of alignment of upper and lower cervical spine. *Neurol India* 2006; **54**: 264-267 [PMID: 16936385 DOI: 10.4103/0028-3886.27149]
- 14 Guo Q, Ni B, Yang J, Liu K, Sun Z, Zhou F, Zhang J. Relation between alignments of upper and subaxial cervical spine: a radiological study. *Arch Orthop Trauma Surg* 2011; **131**: 857-862 [PMID: 21274548 DOI: 10.1007/s00402-011-1265-x]
- 15 Morizane K, Takemoto M, Neo M, Fujibayashi S, Otsuki B, Kawata T, Matsuda S. Occipital and external acoustic meatus to axis angle as a predictor of the oropharyngeal space in healthy volunteers: a novel parameter for craniocervical junction alignment. *Spine J* 2018; **18**: 811-817 [PMID: 28962910 DOI: 10.1016/j.spinee.2017.09.007]
- 16 Matsunaga S, Onishi T, Sakou T. Significance of occipitoaxial angle in subaxial lesion after occipitocervical fusion. *Spine (Phila Pa 1976)* 2001; **26**: 161-165 [PMID: 11154536 DOI: 10.1097/00007632-200101150-00010]
- 17 Inada T, Furuya T, Kamiya K, Ota M, Maki S, Suzuki T, Takahashi K, Yamazaki M, Aramomi M, Mannoji C, Koda M. Postoperative Increase in Occiput-C2 Angle Negatively Impacts Subaxial Lordosis after Occipito-Upper Cervical Posterior Fusion Surgery. *Asian Spine J* 2016; **10**: 744-747 [PMID: 27559456 DOI: 10.4184/asj.2016.10.4.744]
- 18 Bagley CA, Witham TF, Pindrik JA, Davis RF, Bydon A, Gokaslan ZL, Wolinsky JP. Assuring optimal physiologic craniocervical alignment and avoidance of swallowing-related complications after occipitocervical fusion by preoperative halo vest placement. *J Spinal Disord Tech* 2009; **22**: 170-

- 176 [PMID: [19412018](#) DOI: [10.1097/BSD.0b013e318168be6f](#)]
- 19 **Miyata M**, Neo M, Fujibayashi S, Ito H, Takemoto M, Nakamura T. O-C2 angle as a predictor of dyspnea and/or dysphagia after occipitocervical fusion. *Spine (Phila Pa 1976)* 2009; **34**: 184-188 [PMID: [19139669](#) DOI: [10.1097/BRS.0b013e31818ff64e](#)]
- 20 **Tian W**, Yu J. The Role of C2-C7 Angle in the Development of Dysphagia After Anterior and Posterior Cervical Spine Surgery. *Clin Spine Surg* 2017; **30**: E1306-E1314 [PMID: [27930391](#) DOI: [10.1097/BSD.0000000000000493](#)]
- 21 **Gonda DD**, Huang M, Briceño V, Lam SK, Luerssen TG, Jea A. Protecting Against Postoperative Dyspnea and Dysphagia After Occipitocervical Fusion. *Oper Neurosurg (Hagerstown)* 2020; **18**: 254-260 [PMID: [31214708](#) DOI: [10.1093/ons/oz122](#)]
- 22 **Huang M**, Gonda DD, Briceño V, Lam SK, Luerssen TG, Jea A. Dyspnea and dysphagia from upper airway obstruction after occipitocervical fusion in the pediatric age group. *Neurosurg Focus* 2015; **38**: E13 [PMID: [25828489](#) DOI: [10.3171/2015.1.FOCUS14810](#)]



Published by **Baishideng Publishing Group Inc**
7041 Koll Center Parkway, Suite 160, Pleasanton, CA 94566, USA

Telephone: +1-925-3991568

E-mail: bpgoffice@wjgnet.com

Help Desk: <https://www.f6publishing.com/helpdesk>

<https://www.wjgnet.com>

