

# World Journal of *Clinical Cases*

*World J Clin Cases* 2022 March 26; 10(9): 2660-2975



## Contents

Thrice Monthly Volume 10 Number 9 March 26, 2022

### REVIEW

- 2660** Role of metabolites derived from gut microbiota in inflammatory bowel disease  
*Zheng L, Wen XL, Duan SL*

### MINIREVIEWS

- 2678** Roles of Wnt/ $\beta$ -catenin signaling pathway related microRNAs in esophageal cancer  
*Chu CY, Wang R, Liu XL*
- 2687** Animal models applied to acute-on-chronic liver failure: Are new models required to understand the human condition?  
*Gama JFG, Cardoso LMDF, Lagrota-Candido JM, Alves LA*

### ORIGINAL ARTICLE

#### Case Control Study

- 2700** Associations between coagulation factor XII, coagulation factor XI, and stability of venous thromboembolism: A case-control study  
*Meng Y, Li Y, Ye YJ, Ma Q, Zhang JB, Qin H, Deng YY, Tian HY*

#### Retrospective Cohort Study

- 2710** Nomogram to predict the risk of endoscopic removal failure with forceps/baskets for treating submandibular stones  
*Huang Y, Liang PS, Yang YC, Cai WX, Tao Q*
- 2721** Association between anesthesia technique and complications after hip surgery in the elderly population  
*Guo LS, Wang LN, Xiao JB, Zhong M, Zhao GF*

#### Retrospective Study

- 2733** Perforating and nonperforating indications in repeated surgeries for Crohn's disease  
*Shen WS, Huang XH, Liu RQ, Li CY, Li Y, Zhu WM*
- 2743** Treatment of *Pneumocystis jirovecii* pneumonia in non-human immunodeficiency virus-infected patients using a combination of trimethoprim-sulfamethoxazole and caspofungin  
*Wu HH, Fang SY, Chen YX, Feng LF*
- 2751** Acute kidney injury in traumatic brain injury intensive care unit patients  
*Huang ZY, Liu Y, Huang HF, Huang SH, Wang JX, Tian JF, Zeng WX, Lv RG, Jiang S, Gao JL, Gao Y, Yu XX*
- 2764** Enucleation combined with guided bone regeneration in small and medium-sized odontogenic jaw cysts  
*Cao YT, Gu QH, Wang YW, Jiang Q*

**Clinical Trials Study**

- 2773 Determination of the ED<sub>95</sub> of intranasal sufentanil combined with intranasal dexmedetomidine for moderate sedation during endoscopic ultrasonography

*Zou Y, Li N, Shao LJZ, Liu FK, Xue FS, Tao X*

**Observational Study**

- 2783 Overexpression of Ubiquilin4 is associated with poor prognosis in patients with cervical cancer

*Wang LN, Huang KJ, Wang L, Cheng HY*

**Randomized Clinical Trial**

- 2792 Peplau's interpersonal relationship theory combined with bladder function training on patients with prostate cancer

*Yang XH, Wu LF, Yan XY, Zhou Y, Liu X*

**SYSTEMATIC REVIEWS**

- 2801 Efficacy of bone grafts in jaw cystic lesions: A systematic review

*Wang J, Yao QY, Zhu HY*

**CASE REPORT**

- 2811 Short stature associated with a novel mutation in the aggrecan gene: A case report and literature review

*Yin LP, Zheng HX, Zhu H*

- 2818 Treatment with sorafenib plus camrelizumab after splenectomy for primary splenic angiosarcoma with liver metastasis: A case report and literature review

*Pan D, Li TP, Xiong JH, Wang SB, Chen YX, Li JF, Xiao Q*

- 2829 Sarcomatoid intrahepatic cholangiocarcinoma with good patient prognosis after treatment with Huaier granules following hepatectomy: A case report

*Feng JY, Li XP, Wu ZY, Ying LP, Xin C, Dai ZZ, Shen Y, Wu YF*

- 2836 Sequential occurrence of T790M mutation and small cell lung cancer transformation in EGFR-positive lung adenocarcinoma: A case report

*Hong E, Chen XE, Mao J, Zhou JJ, Chen L, Xu JY, Tao W*

- 2844 Early diagnosis of Gitelman syndrome in a young child: A case report

*Wu CY, Tsai MH, Chen CC, Kao CH*

- 2851 Congenital intestinal malrotation with gastric wall defects causing extensive gut necrosis and short gut syndrome: A case report

*Wang Y, Gu Y, Ma D, Guo WX, Zhang YF*

- 2858 Delusional parasitosis as premotor symptom of parkinson's disease: A case report

*Oh M, Kim JW, Lee SM*

- 2864** Laninamivir-induced ischemic enterocolitis: A case report  
*Suzuki C, Kenzaka T*
- 2871** Intramural pregnancy after *in vitro* fertilization and embryo transfer: A case report  
*Xie QJ, Li X, Ni DY, Ji H, Zhao C, Ling XF*
- 2878** Bilateral ureteral reimplantation in a patient with an intraperitoneal ectopic bipenis: A case report  
*Jia YT, Shi BL, Zhang J, Li YY, Zhu J*
- 2883** Lumbar disc sequestration mimicking a tumor: Report of four cases and a literature review  
*Li ST, Zhang T, Shi XW, Liu H, Yang CW, Zhen P, Li SK*
- 2895** Parasitic leiomyoma in the trocar site after laparoscopic myomectomy: A case report  
*Roh CK, Kwon HJ, Jung MJ*
- 2901** Giant nontraumatic myositis ossificans in a child: A case report  
*Xia AN, Wang JS*
- 2908** Paradoxical carbon dioxide embolism during laparoscopic hepatectomy without intracardiac shunt: A case report  
*Jeon S, Hong JM, Lee HJ, Kim Y, Kang H, Hwang BY, Lee D, Jung YH*
- 2916** Local hyperthermia combined with chemotherapy for the treatment of multiple recurrences of *undifferentiated pleomorphic sarcoma*: A case report  
*Zhou YT, Wang RY, Zhang Y, Li DY, Yu J*
- 2923** Acute coronary artery stent thrombosis caused by a spasm: A case report  
*Meng LP, Wang P, Peng F*
- 2931** Turner syndrome with primary myelofibrosis, cirrhosis and ovarian cystic mass: A case report  
*Xu LW, Su YZ, Tao HF*
- 2938** Esophageal myoepithelial carcinoma: Four case reports  
*Lu H, Zhao HP, Liu YY, Yu J, Wang R, Gao JB*
- 2948** Ipsilateral hemifacial microsomia with dextrocardia and pulmonary hypoplasia: A case report  
*Guo R, Chang SH, Wang BQ, Zhang QG*
- 2954** Upper gastrointestinal bleeding from a Mallory-Weiss tear associated with transesophageal echocardiography during successful cardiopulmonary resuscitation: A case report  
*Tang MM, Fang DF, Liu B*
- 2961** Malignant struma ovarii with papillary carcinoma combined with retroperitoneal lymph node metastasis: A case report  
*Xiao W, Zhou JR, Chen D*

- 2969** Occult colon cancer with sepsis as the primary manifestation identified by bone marrow puncture: A case report

*Wang HJ, Zhou CJ*

**ABOUT COVER**

Editorial Board Member of *World Journal of Clinical Cases*, Arunchai Chang, MD, Assistant Professor, Lecturer, Staff Physician, Division of Gastroenterology, Department of Internal Medicine, Hatyai Hospital, Hatyai 90110, Songkhla, Thailand. busmdcu58@gmail.com

**AIMS AND SCOPE**

The primary aim of *World Journal of Clinical Cases* (WJCC, *World J Clin Cases*) is to provide scholars and readers from various fields of clinical medicine with a platform to publish high-quality clinical research articles and communicate their research findings online.

WJCC mainly publishes articles reporting research results and findings obtained in the field of clinical medicine and covering a wide range of topics, including case control studies, retrospective cohort studies, retrospective studies, clinical trials studies, observational studies, prospective studies, randomized controlled trials, randomized clinical trials, systematic reviews, meta-analysis, and case reports.

**INDEXING/ABSTRACTING**

The WJCC is now indexed in Science Citation Index Expanded (also known as SciSearch®), Journal Citation Reports/Science Edition, Scopus, PubMed, and PubMed Central. The 2021 Edition of Journal Citation Reports® cites the 2020 impact factor (IF) for WJCC as 1.337; IF without journal self cites: 1.301; 5-year IF: 1.742; Journal Citation Indicator: 0.33; Ranking: 119 among 169 journals in medicine, general and internal; and Quartile category: Q3. The WJCC's CiteScore for 2020 is 0.8 and Scopus CiteScore rank 2020: General Medicine is 493/793.

**RESPONSIBLE EDITORS FOR THIS ISSUE**

Production Editor: *Ying-Yi Yuan*, Production Department Director: *Xiang Li*, Editorial Office Director: *Jin-Lei Wang*.

**NAME OF JOURNAL**

*World Journal of Clinical Cases*

**ISSN**

ISSN 2307-8960 (online)

**LAUNCH DATE**

April 16, 2013

**FREQUENCY**

Thrice Monthly

**EDITORS-IN-CHIEF**

Bao-Gan Peng, Jerzy Tadeusz Chudek, George Kontogeorgos, Maurizio Serati, Ja Hyeon Ku

**EDITORIAL BOARD MEMBERS**

<https://www.wjgnet.com/2307-8960/editorialboard.htm>

**PUBLICATION DATE**

March 26, 2022

**COPYRIGHT**

© 2022 Baishideng Publishing Group Inc

**INSTRUCTIONS TO AUTHORS**

<https://www.wjgnet.com/bpg/gerinfo/204>

**GUIDELINES FOR ETHICS DOCUMENTS**

<https://www.wjgnet.com/bpg/GerInfo/287>

**GUIDELINES FOR NON-NATIVE SPEAKERS OF ENGLISH**

<https://www.wjgnet.com/bpg/gerinfo/240>

**PUBLICATION ETHICS**

<https://www.wjgnet.com/bpg/GerInfo/288>

**PUBLICATION MISCONDUCT**

<https://www.wjgnet.com/bpg/gerinfo/208>

**ARTICLE PROCESSING CHARGE**

<https://www.wjgnet.com/bpg/gerinfo/242>

**STEPS FOR SUBMITTING MANUSCRIPTS**

<https://www.wjgnet.com/bpg/GerInfo/239>

**ONLINE SUBMISSION**

<https://www.f6publishing.com>



# Intramural pregnancy after *in vitro* fertilization and embryo transfer: A case report

Qi-Jun Xie, Xin Li, Dan-Yu Ni, Hui Ji, Chun Zhao, Xiu-Feng Ling

**Specialty type:** Obstetrics and gynecology

**Provenance and peer review:**

Unsolicited article; Externally peer reviewed.

**Peer-review model:** Single blind

**Peer-review report's scientific quality classification**

Grade A (Excellent): A  
Grade B (Very good): B  
Grade C (Good): 0  
Grade D (Fair): 0  
Grade E (Poor): 0

**P-Reviewer:** Hegazy AA, Tolunay HE

**Received:** September 18, 2021

**Peer-review started:** September 18, 2021

**First decision:** January 10, 2022

**Revised:** January 19, 2022

**Accepted:** February 20, 2022

**Article in press:** February 20, 2022

**Published online:** March 26, 2022



Qi-Jun Xie, Xin Li, Dan-Yu Ni, Hui Ji, Chun Zhao, Xiu-Feng Ling, Department of Reproductive Medicine, Nanjing Maternity and Child Health Care Hospital, Nanjing 210004, Jiangsu Province, China

**Corresponding author:** Xiu-Feng Ling, MD, PhD, Doctor, Department of Reproductive Medicine, Nanjing Maternity and Child Health Care Hospital, Road 123 Tianfeixiang, Mochou, Nanjing 210004, Jiangsu Province, China. [lingxiufeng\\_njfy@163.com](mailto:lingxiufeng_njfy@163.com)

## Abstract

### BACKGROUND

Intramural pregnancy is a rare type of ectopic pregnancy, which is diagnosed by transvaginal ultrasound and magnetic resonance imaging. Management strategies vary depending on the site of the pregnancy, the gestational age and the desire to maintain fertility. The incidence of intramural pregnancy in assisted reproductive technology is higher than that in natural pregnancy.

### CASE SUMMARY

We present a case of intramural pregnancy after *in vitro* fertilization and elective single embryo transfer following salpingectomy. The patient was completely asymptomatic and her serum  $\beta$ -human chorionic gonadotropin level increased from 290 mIU/mL to 1759 mIU/mL. Three-dimensional transvaginal ultrasound indicated a heterogeneous echogenic mass arising from the uterine fundus which was surrounded by myometrium and a slender and extremely hypoechoic area stretching to the uterine cavity which was thought to be a fistulous tract. Therefore, we considered a diagnosis of intramural pregnancy and laparoscopic surgery was conducted at 7 wk gestation.

### CONCLUSION

Early diagnosis and treatment of intramural pregnancy is significant for maintaining fertility.

**Key Words:** Intramural pregnancy; *In vitro* fertilization; Embryo transfer; Transvaginal ultrasound; Laparoscopic surgery; Case report

©The Author(s) 2022. Published by Baishideng Publishing Group Inc. All rights reserved.

**Core Tip:** We present a case of intramural pregnancy after *in vitro* fertilization and elective single embryo transfer following bilateral salpingectomy. The patient was diagnosed with intramural pregnancy by transvaginal ultrasound and then underwent laparoscopic surgery at 7 wk' gestation. The patient recovered well at discharge and her serum  $\beta$ -hCG levels were negative after 4 wk.

**Citation:** Xie QJ, Li X, Ni DY, Ji H, Zhao C, Ling XF. Intramural pregnancy after *in vitro* fertilization and embryo transfer: A case report. *World J Clin Cases* 2022; 10(9): 2871-2877

**URL:** <https://www.wjgnet.com/2307-8960/full/v10/i9/2871.htm>

**DOI:** <https://dx.doi.org/10.12998/wjcc.v10.i9.2871>

## INTRODUCTION

Intramural pregnancy is a rare type of ectopic pregnancy, which is characterized by a gestational sac implanted within the myometrium and not connected to the uterine cavity[1]. Uterine rupture and massive bleeding are potential life-threatening complications of severe ectopic pregnancy. The risk factors for intramural pregnancy remain elusive, but may include uterine trauma, adenomyosis, inflammation of the uterine serosa and *in vitro* fertilization and embryo transfer (IVF-ET)[1-3]. Transvaginal ultrasound and magnetic resonance imaging (MRI) are useful for diagnosis in early pregnancy. There is no consensus regarding the treatment of intramural pregnancy, including expectant management, surgical evacuation, uterine artery embolization (UAE) and methotrexate administration[4-7]. The incidence of ectopic pregnancy in assisted reproductive technology (ART) is about 2-5 times higher than that in natural pregnancy[8]. Timely and accurate diagnosis and treatment of intramural pregnancy is crucial in ART especially in patients who wish to preserve their fertility.

We report a case of intramural pregnancy following IVF and elective single ET, which was managed with laparoscopy.

## CASE PRESENTATION

### Chief complaints

A 31-year-old woman, gravidity three, parity zero, was admitted because of a suspected intramural pregnancy after IVF-ET.

### History of present illness

The patient was completely asymptomatic. She had regular menstruation, a moderate amount of menstruation and no dysmenorrhea. Her last menstrual period was November 17, 2020. The endometrium was prepared using hormone replacement therapy following 1.875 mg of subcutaneous gonadotropin-releasing hormone agonist (Leuprorelin Acetate, Livzon Pharmaceuticals, China) on day 3 of the menstrual cycle. In addition, 90 mg of vaginal progesterone (Crinone, Merck Serono, United Kingdom) once a day and 10 mg of dydrogesterone three times daily were administered (P + 0). A frozen day 6 embryo which had undergone preimplantation genetic screening was transferred on the 7<sup>th</sup> day of progesterone exposure (P + 6) under sonographic guidance.

### History of past illness

She received laparoscopic salpingotomy in 2014 due to a right tubal pregnancy. She had suffered secondary infertility since December 2015 and her hysterosalpingography results showed an obstruction in the right fallopian tube and adhesion of the distal end of the left fallopian tube in June 2016. As spontaneous pregnancy did not subsequently occur, she was referred to the reproductive center of our hospital for IVF-ET in June 2018. The patient underwent laparoscopic bilateral salpingectomy for bilateral tubal pregnancy after two frozen day 3 embryos were transferred in December 2018. Of the other three frozen-thawed embryo transfer cycles, a total of 5 embryos were transferred, but pregnancy was not achieved. In addition, the patient had a history of hysteroscopy three times to remove endometrial polyps and separate uterine adhesions.

### Personal and family history

Her personal history and family history were unremarkable.

### Physical examination

The patient's vital signs were normal. Physical examination revealed a 7-week sized uterus with no tenderness and no abnormalities in the uterine cervix and abdomen. There was no vaginal bleeding or



fluid.

### Laboratory examinations

At day 14 after ET, her serum  $\beta$ -human chorionic gonadotropin ( $\beta$ -hCG) level was 111.54 mIU/mL and then increased from 290 mIU/mL to 1759 mIU/mL. On day 32 after ET, her serum  $\beta$ -hCG level was 3819 mIU/mL.

### Imaging examinations

A transvaginal ultrasound examination revealed a suspected intramural pregnancy. When admitted on day 33 after ET, three-dimensional transvaginal ultrasound indicated a heterogeneous echogenic area measuring 1.40 cm  $\times$  1.26 cm in size arising from the uterine fundus which had a 0.48 cm  $\times$  0.37 cm anechoic region inside and was surrounded by myometrium (Figure 1A). Color Doppler ultrasound showed abundant blood flow. This region seemed to have a slender and extremely hypoechoic area stretching to the uterine cavity (Figure 1B). In addition, a hypoechoic structure with an indistinct boundary measuring 2.74 cm  $\times$  1.61 cm in size was observed in the anterior myometrium near the uterine fundus, which was thought to be a uterine adenomyoma.

## FINAL DIAGNOSIS

The final diagnosis in this case was intramural pregnancy after IVF-ET, and adenomyoma.

## TREATMENT

Considering the suspected diagnosis of intramural pregnancy with a possible fistulous tract communicated with the uterine cavity and the patient's desire to maintain fertility, the decision was made to perform laparoscopic exploration. Laparoscopic surgery was performed on day 34 after ET. Laparoscopy showed a bulging and unruptured mass measuring approximately 2 cm in the left side of the anterior uterus with a purplish-blue-colored surface (Figure 2A). The fallopian tubes were absent on both sides and the ovaries appeared normal. The intramural ectopic pregnancy was dissected from the uterus which had chorionic villous tissues bulging out (Figure 2B). The wound was sutured continuously and methotrexate [Pfizer (Perth) Pty Limited, United States] was injected into the myometrium around the wound to eliminate the activity of possible residual trophoblast cells. The tumor-like bulging mass measuring 2 cm in the posterior wall of the uterus was resected and lysis of pelvic adhesions was carried out (Figure 2C).

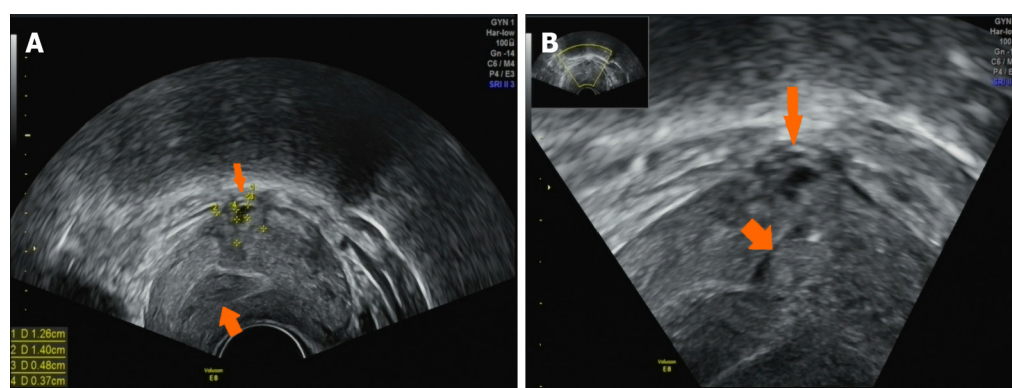
## OUTCOME AND FOLLOW-UP

Histological examination confirmed the presence of trophoblast cells and chorionic villi in the uterine smooth muscle. Her serum  $\beta$ -hCG levels declined to 837.37 mIU/mL 2 days after surgery. The patient was well at discharge and her serum  $\beta$ -hCG levels were negative after 4 wk.

## DISCUSSION

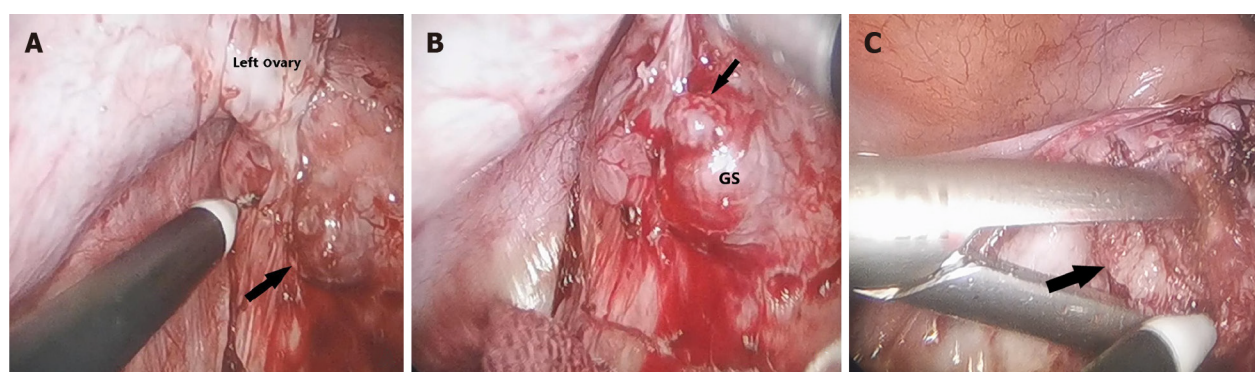
The incidence of ectopic pregnancy after ART is 1.6%-8.6% higher than that in natural pregnancy. The incidence of intramural pregnancy is less than 1% of all ectopic pregnancies[9,10]. Intramural pregnancy is a rare type of ectopic pregnancy and refers to a gestational sac completely surrounded by the myometrium which is not connected to the endometrial cavity and the fallopian tubes. To date, very few cases of intramural pregnancy after IVF-ET have been reported in the literature[11-13].

Intramural pregnancy may present with a wide variety of symptoms and the clinical course is determined by its exact location, extent of myometrial involvement and gestational age. The exact cause of intramural pregnancy is unknown, but several hypotheses have been suggested including uterine surgical procedures (such as cesarean section, myomectomy, hysteroscopy, uterine curettage and a history of uterine perforation)[9,14,15], inflammation of the uterine serosa, IVF-ET[11-13] and adenomyosis[1,3]. Color Doppler ultrasound may show a suspected fistulous tract connecting the intramural pregnancy foci to the uterine cavity. In our case, the patient had a history of hysteroscopy three times and the presence of an adenomyoma in the posterior wall of the uterus confirmed by surgery and histological examination, which may have contributed to the implantation in a focus of adenomyosis or uterine trauma. Hegazy *et al*[16] have reported that in the natural implantation, the trophoblast forms a cytotrophoblast shell to surround the gestational sac, preventing further invasion



DOI: 10.12998/wjcc.v10.i9.2871 Copyright ©The Author(s) 2022.

**Figure 1** Transvaginal ultrasound image of intrauterine pregnancy at day 33 after embryo transfer. A: The transvaginal ultrasound showed a heterogeneous echogenic mass measuring 1.40 cm × 1.26 cm in size slightly arising from the left corner of the uterus, which had a 0.48 cm × 0.37 cm anechoic region inside (thin arrow). The endometrial–myometrial junction was displayed (coarse arrow); B: The transvaginal ultrasound showed a slender and extremely hypoechoic area stretching to the uterine cavity (coarse arrow) and the serosal surface of the heterogeneous echogenic mass was covered by feeble myometrial tissue (thin arrow).



DOI: 10.12998/wjcc.v10.i9.2871 Copyright ©The Author(s) 2022.

**Figure 2** Findings of laparoscopy at day 34 after embryo transfer. A: Laparoscopic view showed that a bulging mass measuring approximate 2 cm was in the left horn of the uterus with a purplish-blue-colored surface (black arrow); B: The ectopic gestational sac was found in the uterine myometrium and removed (black arrow); C: Laparoscopic view showed that a tumor-like bulging mass measuring 2 cm in the posterior wall of the uterus was removed (black arrow). GS: Gestational sac.

into myometrium. Intramural pregnancy is more likely to occur in frozen-thawed embryo transfer cycles, which may be related to the procedure of embryo thawing and the depth of embryo transfer. However, the ET process in this patient was recorded as uneventful each time. ET is routinely performed and monitored by transabdominal ultrasound in our center, and the tip of the ET tube is soft. Thus, the formation of a fistulous tract is unlikely to be related to ET in this case but cannot be excluded.

Intramural pregnancy is difficult to detect due to mild clinical symptoms and the anatomical location of the mass. In the past, intramural pregnancy was not diagnosed until uterine rupture. In recent years, the development of modern transvaginal ultrasound and MRI have been very helpful in visualization of the endometrial–myometrial junction and delineating the association between endometrial and uterine myometrium, which has led to a more accurate diagnosis of intramural pregnancy at an early stage. In a prospective study, Lyu *et al* [17] demonstrated that 85.5% of women with ectopic pregnancies following IVF-ET were identified by their first pre-surgical transvaginal sonography. It has been reported that MRI has a diagnostic accuracy of 96% [18]. However, the presence of uterine leiomyoma and adenomyosis may affect the diagnosis of intramural pregnancy, and it is difficult to distinguish an intramural pregnancy from gestational trophoblastic disease and interstitial pregnancy [1,19–21]. In our patient, her three-dimensional transvaginal ultrasound clearly showed that the mass in the myometrium had a dark area and was surrounded by abundant blood flow signals. In addition, a microscopic sinus tract connected the mass to the uterine cavity. We did not perform MRI to confirm the diagnosis as experienced ultrasound physicians are usually able to make a correct diagnosis using three-dimensional transvaginal ultrasound.

Although two women with intramural pregnancy gave birth to live newborn after 30 wk gestation [22, 23], the management of patients with intramural pregnancy who wish to maintain pregnancy is extremely difficult and risky. Women who conceive by IVF-ET should be informed of the risk of

intramural pregnancy, including uterine rupture, abnormal adherent placenta, hypovolemic shock and hysterectomy, which may have a negative impact on their future fertility. Treatment of intramural pregnancy should be individualized, and depends on its exact location, extent of myometrial involvement, the desire to maintain fertility and when it is diagnosed. It has been reported that uterine rupture and massive hemoperitoneum in intramural pregnancy often occur at 11-30 wk gestation, and hysterectomy is inevitable in most cases[24]. At present, treatment methods mainly include expectant management, surgical enucleation, topical or systemic administration of methotrexate and UAE. One patient with posterior wall intramural pregnancy who had mild symptoms and a  $\beta$ -hCG level of 9.5 mIU/mL opted for expectant management due to her requirement for future fertility[4]. Methotrexate can be administered topically or systemically with or without intracardiac potassium chloride, which can be used alone for expectant treatment or in combination with minimally invasive surgery. Mylene *et al*[5] suggested that asymptomatic patients with serum  $\beta$ -hCG < 2000 mIU/mL, and a mass diameter < 3 cm should be treated with methotrexate. Wu *et al*[25] found that patients treated with UAE had a faster recovery of serum  $\beta$ -hCG level, compared to patients treated with methotrexate injection. UAE has the advantages of short operation time, less trauma and quick recovery, but has a high risk of bleeding[6]. Laparoscopic excision surgery has been widely used in the treatment of unruptured intramural pregnancy, but it should be determined whether the mass protrudes outside the uterine cavity. It was reported that a patient underwent hysteroscopic removal of an intramural pregnancy with a sinus tract diagnosed by ultrasound examination[26]. As in the case presented here, the increase in serum  $\beta$ -hCG level should be monitored frequently and this patient underwent an early transvaginal ultrasound examination which resulted in the diagnosis of ectopic pregnancy at 7 wk gestation. Although a fistulous tract communicating between the endometrial cavity and the mass was observed in our case, we carried out laparoscopic excision as soon as possible as the lesion was protruding from the surface of the uterus and the patient had a desire for future fertility.

## CONCLUSION

We report a case of intramural pregnancy with a microscopic fistula after IVF-ET. Due to the higher incidence of ectopic pregnancy after IVF-ET, we suggest that physicians should be aware of the risk factors for intramural pregnancy and achieve an early diagnosis by closely monitoring serum  $\beta$ -hCG level, and performing transvaginal ultrasound and MRI. For patients with suspected fistulous tract formation in the myometrium diagnosed by three-dimensional ultrasound, more attention should be paid to the depth of the ET tube using transabdominal ultrasound during this process. Appropriate and early selection of treatment is vital to preserve future fertility.

## ACKNOWLEDGEMENTS

We want to express our thanks to the patient and nurses, doctors, and other medical staff in the Reproductive Center of Women's Hospital of Nanjing Medical University for agreeing to participate in this study.

## FOOTNOTES

**Author contributions:** Xie QJ was involved in protocol/project development, data collection and management, data analysis and manuscript writing; Li X was involved in project development, images collection and manuscript writing; Ni DY was involved in project development, manuscript review and editing; Ji H, Zhao C and Ling XF was involved in data collection and analysis, manuscript review and editing. Xie QJ and Li X contributed equally to this work.

**Supported by** National Natural Science Foundation of China, No. 81971386 and No. 81871210.

**Informed consent statement:** All procedures performed in studies involving human participants were in accordance with the ethical standards of the institutional research committee and with the Helsinki declaration. Informed consent was obtained from the patient for publication of this case report and any accompanying images.

**Conflict-of-interest statement:** All authors have no conflicts of interest to declare.

**CARE Checklist (2016) statement:** The authors have read the CARE Checklist (2016), and the manuscript was prepared and revised according to the CARE Checklist (2016).

**Open-Access:** This article is an open-access article that was selected by an in-house editor and fully peer-reviewed by external reviewers. It is distributed in accordance with the Creative Commons Attribution NonCommercial (CC BY-

NC 4.0) license, which permits others to distribute, remix, adapt, build upon this work non-commercially, and license their derivative works on different terms, provided the original work is properly cited and the use is non-commercial. See: <https://creativecommons.org/licenses/by-nc/4.0/>

**Country/Territory of origin:** China

**ORCID number:** Qi-Jun Xie 0000-0003-3189-3262; Xin Li 0000-0001-6432-3966; Dan-Yu Ni 0000-0003-3192-5885; Hui Ji 0000-0002-1470-1794; Chun Zhao 0000-0001-9295-8037; Xiu-Feng Ling 0000-0001-7820-9152.

**S-Editor:** Ma YJ

**L-Editor:** A

**P-Editor:** Ma YJ

## REFERENCES

- Ginsburg KA, Quereshi F, Thomas M, Snowman B. Intramural ectopic pregnancy implanting in adenomyosis. *Fertil Steril* 1989; **51**: 354-356 [PMID: 2912784 DOI: 10.1016/s0015-0282(16)60506-x]
- Boulet SL, Kirby RS, Reefhuis J, Zhang Y, Sunderam S, Cohen B, Bernson D, Copeland G, Bailey MA, Jamieson DJ, Kissin DM; States Monitoring Assisted Reproductive Technology (SMART) Collaborative. Assisted Reproductive Technology and Birth Defects Among Liveborn Infants in Florida, Massachusetts, and Michigan, 2000-2010. *JAMA Pediatr* 2016; **170**: e154934 [PMID: 27043648 DOI: 10.1001/jamapediatrics.2015.4934]
- Lu HF, Sheu BC, Shih JC, Chang YL, Tornig PL, Huang SC. Intramural ectopic pregnancy. Sonographic picture and its relation with adenomyosis. *Acta Obstet Gynecol Scand* 1997; **76**: 886-889 [PMID: 9351419 DOI: 10.3109/00016349709024372]
- Bernstein HB, Thrall MM, Clark WB. Expectant management of intramural ectopic pregnancy. *Obstet Gynecol* 2001; **97**: 826-827 [PMID: 11336768 DOI: 10.1016/s0029-7844(01)01126-7]
- Yao M, Tulandi T. Current status of surgical and nonsurgical management of ectopic pregnancy. *Fertil Steril* 1997; **67**: 421-433 [PMID: 9091325 DOI: 10.1016/s0015-0282(97)80064-7]
- Wang S, Dong Y, Meng X. Intramural ectopic pregnancy: treatment using uterine artery embolization. *J Minim Invasive Gynecol* 2013; **20**: 241-243 [PMID: 23465260 DOI: 10.1016/j.jmig.2012.10.005]
- Shen Z, Liu C, Zhao L, Xu L, Peng B, Chen Z, Li X, Zhou J. Minimally-invasive management of intramural ectopic pregnancy: an eight-case series and literature review. *Eur J Obstet Gynecol Reprod Biol* 2020; **253**: 180-186 [PMID: 32871441 DOI: 10.1016/j.ejogrb.2020.08.021]
- Hilbert SM, Gunderson S. Complications of Assisted Reproductive Technology. *Emerg Med Clin North Am* 2019; **37**: 239-249 [PMID: 30940369 DOI: 10.1016/j.emc.2019.01.005]
- Ko HS, Lee Y, Lee HJ, Park IY, Chung DY, Kim SP, Park TC, Shin JC. Sonographic and MR findings in 2 cases of intramural pregnancy treated conservatively. *J Clin Ultrasound* 2006; **34**: 356-360 [PMID: 16869015 DOI: 10.1002/jcu.20245]
- Ong C, Su LL, Chia D, Choolani M, Biswas A. Sonographic diagnosis and successful medical management of an intramural ectopic pregnancy. *J Clin Ultrasound* 2010; **38**: 320-324 [PMID: 20544869 DOI: 10.1002/jcu.20703]
- Hamilton CJ, Legarth J, Jaroudi KA. Intramural pregnancy after *in vitro* fertilization and embryo transfer. *Fertil Steril* 1992; **57**: 215-217 [PMID: 1730320 DOI: 10.1016/s0015-0282(16)54804-3]
- Lyu J, Sun W, Lin Y. Successful Management of Heterotopic Intramural Pregnancy Leading to a Live Birth of the Intrauterine Pregnancy. *J Minim Invasive Gynecol* 2018; **25**: 1126-1127 [PMID: 29337212 DOI: 10.1016/j.jmig.2018.01.003]
- Ishiguro T, Yamawaki K, Chihara M, Nishikawa N, Enomoto T. Myomectomy scar ectopic pregnancy following a cryopreserved embryo transfer. *Reprod Med Biol* 2018; **17**: 509-513 [PMID: 30377408 DOI: 10.1002/rmb2.12212]
- Park WI, Jeon YM, Lee JY, Shin SY. Subserosal pregnancy in a previous myomectomy site: a variant of intramural pregnancy. *J Minim Invasive Gynecol* 2006; **13**: 242-244 [PMID: 16698534 DOI: 10.1016/j.jmig.2006.01.013]
- Ko JKY, Wan HL, Ngu SF, Cheung VYT, Ng EHY. Cesarean scar molar pregnancy. *Obstet Gynecol* 2012; **119**: 449-451 [PMID: 22270435 DOI: 10.1097/AOG.0b013e3182322f31]
- Hegazy A A. Clinical Embryology for medical students and postgraduate doctors[M]. Little, Brown, 2014
- Lyu J, Ye H, Wang W, Lin Y, Sun W, Lei L, Hao L. Diagnosis and management of heterotopic pregnancy following embryo transfer: clinical analysis of 55 cases from a single institution. *Arch Gynecol Obstet* 2017; **296**: 85-92 [PMID: 28540574 DOI: 10.1007/s00404-017-4384-y]
- Ramkrishna J, Kan GR, Reidy KL, Ang WC, Palma-Dias R. Comparison of management regimens following ultrasound diagnosis of nontubal ectopic pregnancies: a retrospective cohort study. *BJOG* 2018; **125**: 567-575 [PMID: 28626980 DOI: 10.1111/1471-0528.14752]
- Liu Y, Nan F, Liu Z, Wei S, Liu Y, Zhao G, Guan D. Intramural pregnancy: a case report. *Eur J Obstet Gynecol Reprod Biol* 2014; **176**: 197-198 [PMID: 24642196 DOI: 10.1016/j.ejogrb.2014.02.027]
- Su S, Chavan D, Song K, Chi D, Zhang G, Deng X, Li L, Kong B. Distinguishing between intramural pregnancy and choriocarcinoma: A case report. *Oncol Lett* 2017; **13**: 2129-2132 [PMID: 28454372 DOI: 10.3892/ol.2017.5737]
- Hafner T, Aslam N, Ross JA, Zosmer N, Jurkovic D. The effectiveness of non-surgical management of early interstitial pregnancy: a report of ten cases and review of the literature. *Ultrasound Obstet Gynecol* 1999; **13**: 131-136 [PMID: 10079493 DOI: 10.1046/j.1469-0705.1999.13020131.x]
- Petit L, Lecointre C, Ducarme G. Intramural ectopic pregnancy with live birth at 37 wk of gestation. *Arch Gynecol Obstet*



- 2013; **287**: 613-614 [PMID: [22948806](#) DOI: [10.1007/s00404-012-2549-2](#)]
- 23 **Fait G**, Goyert G, Sundareson A, Pickens A Jr. Intramural pregnancy with fetal survival: case history and discussion of etiologic factors. *Obstet Gynecol* 1987; **70**: 472-474 [PMID: [3627606](#)]
- 24 **Jin H**, Zhou J, Yu Y, Dong M. Intramural pregnancy: a report of 2 cases. *J Reprod Med* 2004; **49**: 569-572 [PMID: [15305831](#)]
- 25 **Wu X**, Zhang X, Zhu J, Di W. Cesarean scar pregnancy: comparative efficacy and safety of treatment by uterine artery chemoembolization and systemic methotrexate injection. *Eur J Obstet Gynecol Reprod Biol* 2012; **161**: 75-79 [PMID: [22153905](#) DOI: [10.1016/j.ejogrb.2011.11.026](#)]
- 26 **Wang J**, Xie X. Sonographic diagnosis of intramural pregnancy. *J Ultrasound Med* 2013; **32**: 2215-2217 [PMID: [24277907](#) DOI: [10.7863/ultra.32.12.2215](#)]



Published by **Baishideng Publishing Group Inc**  
7041 Koll Center Parkway, Suite 160, Pleasanton, CA 94566, USA

**Telephone:** +1-925-3991568

**E-mail:** [bpgoffice@wjgnet.com](mailto:bpgoffice@wjgnet.com)

**Help Desk:** <https://www.f6publishing.com/helpdesk>

<https://www.wjgnet.com>

