

World Journal of *Clinical Cases*

World J Clin Cases 2022 May 6; 10(13): 3969-4326



Contents

Thrice Monthly Volume 10 Number 13 May 6, 2022

REVIEW

- 3969 COVID-19 and liver diseases, what we know so far
Elnaggar M, Abomhaya A, Elkhattib I, Dawoud N, Doshi R

MINIREVIEWS

- 3981 Amputation stump management: A narrative review
Choo YJ, Kim DH, Chang MC

ORIGINAL ARTICLE

Clinical and Translational Research

- 3989 Solute carrier family 2 members 1 and 2 as prognostic biomarkers in hepatocellular carcinoma associated with immune infiltration
Peng Q, Hao LY, Guo YL, Zhang ZQ, Ji JM, Xue Y, Liu YW, Lu JL, Li CG, Shi XL

Retrospective Cohort Study

- 4020 Role of clinical data and multidetector computed tomography findings in acute superior mesenteric artery embolism
Yang JS, Xu ZY, Chen FX, Wang MR, Cong RC, Fan XL, He BS, Xing W

Retrospective Study

- 4033 Effect of calcium supplementation on severe hypocalcemia in patients with secondary hyperparathyroidism after total parathyroidectomy
Liu J, Fan XF, Yang M, Huang LP, Zhang L
- 4042 Comparison of clinical efficacy and postoperative inflammatory response between laparoscopic and open radical resection of colorectal cancer
He LH, Yang B, Su XQ, Zhou Y, Zhang Z
- 4050 Three-dimensional echocardiographic assessment of left ventricular volume in different heart diseases using a fully automated quantification software
Pan CK, Zhao BW, Zhang XX, Pan M, Mao YK, Yang Y
- 4064 Clinical effect of ultrasound-guided nerve block and dexmedetomidine anesthesia on lower extremity operative fracture reduction
Ao CB, Wu PL, Shao L, Yu JY, Wu WG
- 4072 Correlation between thrombopoietin and inflammatory factors, platelet indices, and thrombosis in patients with sepsis: A retrospective study
Xu WH, Mo LC, Shi MH, Rao H, Zhan XY, Yang M

Observational Study

- 4084** High plasma CD40 ligand level is associated with more advanced stages and worse prognosis in colorectal cancer

Herold Z, Herold M, Herczeg G, Fodor A, Szasz AM, Dank M, Somogyi A

- 4097** Metabolic dysfunction is associated with steatosis but no other histologic features in nonalcoholic fatty liver disease

Dai YN, Xu CF, Pan HY, Huang HJ, Chen MJ, Li YM, Yu CH

Randomized Controlled Trial

- 4110** Effect of Xuebijing injection on myocardium during cardiopulmonary bypass: A prospective, randomized, double blind trial

Jin ZH, Zhao XQ, Sun HB, Zhu JL, Gao W

META-ANALYSIS

- 4119** Perioperative respiratory muscle training improves respiratory muscle strength and physical activity of patients receiving lung surgery: A meta-analysis

Yang MX, Wang J, Zhang X, Luo ZR, Yu PM

CASE REPORT

- 4131** Delayed diffuse lamellar keratitis after small-incision lenticule extraction related to immunoglobulin A nephropathy: A case report

Dan TT, Liu TX, Liao YL, Li ZZ

- 4137** Large vessel vasculitis with rare presentation of acute rhabdomyolysis: A case report and review of literature

Fu LJ, Hu SC, Zhang W, Ye LQ, Chen HB, Xiang XJ

- 4145** Primitive neuroectodermal tumor of the prostate in a 58-year-old man: A case report

Tian DW, Wang XC, Zhang H, Tan Y

- 4153** Bilateral superficial cervical plexus block for parathyroidectomy during pregnancy: A case report

Chung JY, Lee YS, Pyeon SY, Han SA, Huh H

- 4161** Primary myelofibrosis with thrombophilia as first symptom combined with thalassemia and Gilbert syndrome: A case report

Wufuer G, Wufuer K, Ba T, Cui T, Tao L, Fu L, Mao M, Duan MH

- 4171** Late contralateral recurrence of retinal detachment in incontinentia pigmenti: A case report

Cai YR, Liang Y, Zhong X

- 4177** Pregnancy and delivery after augmentation cystoplasty: A case report and review of literature

Ruan J, Zhang L, Duan MF, Luo DY

- 4185** Acute pancreatitis as a rare complication of gastrointestinal endoscopy: A case report

Dai MG, Li LF, Cheng HY, Wang JB, Ye B, He FY

- 4190** Paraneoplastic neurological syndrome with positive anti-Hu and anti-Yo antibodies: A case report
Li ZC, Cai HB, Fan ZZ, Zhai XB, Ge ZM
- 4196** Primary pulmonary meningioma: A case report and review of the literature
Zhang DB, Chen T
- 4207** Anesthesia of a patient with congenital cataract, facial dysmorphism, and neuropathy syndrome for posterior scoliosis: A case report
Hudec J, Kosinova M, Prokopova T, Filipovic M, Repko M, Stourac P
- 4214** Extensive myocardial calcification in critically ill patients receiving extracorporeal membrane oxygenation: A case report
Sui ML, Wu CJ, Yang YD, Xia DM, Xu TJ, Tang WB
- 4220** Trigeminal extracranial thermocoagulation along with patient-controlled analgesia with esketamine for refractory postherpetic neuralgia after herpes zoster ophthalmicus: A case report
Tao JC, Huang B, Luo G, Zhang ZQ, Xin BY, Yao M
- 4226** Thrombotic pulmonary embolism of inferior vena cava during caesarean section: A case report and review of the literature
Jiang L, Liang WX, Yan Y, Wang SP, Dai L, Chen DJ
- 4236** EchoNavigator virtual marker and Agilis NxT steerable introducer facilitate transseptal transcatheter closure of mitral paravalvular leak
Hsu JC, Khoi CS, Huang SH, Chang YY, Chen SL, Wu YW
- 4242** Primary isolated central nervous system acute lymphoblastic leukemia with *BCR-ABL1* rearrangement: A case report
Chen Y, Lu QY, Lu JY, Hong XL
- 4249** Coexistence of meningioma and other intracranial benign tumors in non-neurofibromatosis type 2 patients: A case report and review of literature
Hu TH, Wang R, Wang HY, Song YF, Yu JH, Wang ZX, Duan YZ, Liu T, Han S
- 4264** Treatment of condylar osteophyte in temporomandibular joint osteoarthritis with muscle balance occlusal splint and long-term follow-up: A case report
Lan KW, Chen JM, Jiang LL, Feng YF, Yan Y
- 4273** Hepatic perivascular epithelioid cell tumor: A case report
Li YF, Wang L, Xie YJ
- 4280** Multiple stress fractures of unilateral femur: A case report
Tang MT, Liu CF, Liu JL, Saijilafu, Wang Z
- 4288** Enigmatic rapid organization of subdural hematoma in a patient with epilepsy: A case report
Lv HT, Zhang LY, Wang XT

- 4294** Spinal canal decompression for hypertrophic neuropathy of the cauda equina with chronic inflammatory demyelinating polyradiculoneuropathy: A case report
Ye L, Yu W, Liang NZ, Sun Y, Duan LF
- 4301** Primary intracranial extraskeletal myxoid chondrosarcoma: A case report and review of literature
Zhu ZY, Wang YB, Li HY, Wu XM
- 4314** Mass brain tissue lost after decompressive craniectomy: A case report
Li GG, Zhang ZQ, Mi YH

LETTER TO THE EDITOR

- 4321** Improving outcomes in geriatric surgery: Is there more to the equation?
Goh SSN, Chia CL
- 4324** Capillary leak syndrome: A rare cause of acute respiratory distress syndrome
Juneja D, Kataria S

ABOUT COVER

Editorial Board Member of *World Journal of Clinical Cases*, Kai Zhang, PhD, Professor, Department of Psychiatry, Chaohu Hospital of Anhui Medical University, Hefei 238000, Anhui Province, China. zhangkai@ahmu.edu.cn

AIMS AND SCOPE

The primary aim of *World Journal of Clinical Cases* (WJCC, *World J Clin Cases*) is to provide scholars and readers from various fields of clinical medicine with a platform to publish high-quality clinical research articles and communicate their research findings online.

WJCC mainly publishes articles reporting research results and findings obtained in the field of clinical medicine and covering a wide range of topics, including case control studies, retrospective cohort studies, retrospective studies, clinical trials studies, observational studies, prospective studies, randomized controlled trials, randomized clinical trials, systematic reviews, meta-analysis, and case reports.

INDEXING/ABSTRACTING

The WJCC is now indexed in Science Citation Index Expanded (also known as SciSearch®), Journal Citation Reports/Science Edition, Scopus, PubMed, and PubMed Central. The 2021 Edition of Journal Citation Reports® cites the 2020 impact factor (IF) for WJCC as 1.337; IF without journal self cites: 1.301; 5-year IF: 1.742; Journal Citation Indicator: 0.33; Ranking: 119 among 169 journals in medicine, general and internal; and Quartile category: Q3. The WJCC's CiteScore for 2020 is 0.8 and Scopus CiteScore rank 2020: General Medicine is 493/793.

RESPONSIBLE EDITORS FOR THIS ISSUE

Production Editor: Xu Guo; Production Department Director: Xiang Li; Editorial Office Director: Jin-Lei Wang.

NAME OF JOURNAL

World Journal of Clinical Cases

ISSN

ISSN 2307-8960 (online)

LAUNCH DATE

April 16, 2013

FREQUENCY

Thrice Monthly

EDITORS-IN-CHIEF

Bao-Gan Peng, Jerzy Tadeusz Chudek, George Kontogeorgos, Maurizio Serati, Ja Hyeon Ku

EDITORIAL BOARD MEMBERS

<https://www.wjgnet.com/2307-8960/editorialboard.htm>

PUBLICATION DATE

May 6, 2022

COPYRIGHT

© 2022 Baishideng Publishing Group Inc

INSTRUCTIONS TO AUTHORS

<https://www.wjgnet.com/bpg/gerinfo/204>

GUIDELINES FOR ETHICS DOCUMENTS

<https://www.wjgnet.com/bpg/GerInfo/287>

GUIDELINES FOR NON-NATIVE SPEAKERS OF ENGLISH

<https://www.wjgnet.com/bpg/gerinfo/240>

PUBLICATION ETHICS

<https://www.wjgnet.com/bpg/GerInfo/288>

PUBLICATION MISCONDUCT

<https://www.wjgnet.com/bpg/gerinfo/208>

ARTICLE PROCESSING CHARGE

<https://www.wjgnet.com/bpg/gerinfo/242>

STEPS FOR SUBMITTING MANUSCRIPTS

<https://www.wjgnet.com/bpg/GerInfo/239>

ONLINE SUBMISSION

<https://www.f6publishing.com>



Treatment of condylar osteophyte in temporomandibular joint osteoarthritis with muscle balance occlusal splint and long-term follow-up: A case report

Kai-Wen Lan, Jia-Min Chen, Liu-Lin Jiang, Yi-Fan Feng, Ying Yan

Specialty type: Dentistry, oral surgery and medicine

Provenance and peer review:

Unsolicited article; Externally peer reviewed.

Peer-review model: Single blind

Peer-review report's scientific quality classification

Grade A (Excellent): A, A

Grade B (Very good): B

Grade C (Good): 0

Grade D (Fair): 0

Grade E (Poor): 0

P-Reviewer: Morozov S, Russia; Oura S, Japan; Zhang Y, China

Received: October 8, 2021

Peer-review started: October 8, 2021

First decision: December 10, 2021

Revised: December 16, 2021

Accepted: March 16, 2021

Article in press: March 16, 2022

Published online: May 6, 2022



Kai-Wen Lan, Liu-Lin Jiang, Yi-Fan Feng, Ying Yan, Hospital of Stomatology, Sun Yat-sen University, Guangdong Provincial Key Laboratory of Stomatology, Guanghua School of Stomatology, Guangzhou 510080, Guangdong Province, China

Jia-Min Chen, Department of Prosthodontics, Affiliated Stomatology Hospital of Guangzhou Medical University, Guangdong Engineering Research Center of Restoration and Reconstruction, Guangzhou Key Laboratory of Basic and Applied Research of Oral Regenerative Medicine, Guangzhou 510182, Guangdong Province, China

Corresponding author: Ying Yan, MSc, Chief Doctor, Hospital of Stomatology, Sun Yat-sen University, Guangdong Provincial Key Laboratory of Stomatology, Guanghua School of Stomatology, Guangzhou 510080, Guangdong Province, China. yanying2@mail.sysu.edu.cn

Abstract

BACKGROUND

Condylar osteophytes, a remodeling form of temporomandibular joint osteoarthritis (TMJ OA), mainly manifest as marginal angular outgrowths of the condyle. Previous researchers have advocated surgical removal of condylar osteophytes. Reports on the effect of occlusal splint on TMJ OA patients' joints have mostly focused on treatment with this splint, which can reduce the absorption of the affected condyle and promote repair and regeneration. However, the effect of the splint on the dissolution of condylar osteophytes has not yet been reported.

CASE SUMMARY

A 68-year-old female patient suffered from occlusal discomfort with left facial pain for 2 years. Cone beam computed tomography showed a rare osteophyte on top of her left condyle. She was finally diagnosed with TMJ OA. The patient refused surgical treatment and received conservative treatment with a muscle balance occlusal splint. The pain experienced by the patient on the left side of her face was relieved, and her chewing ability recovered after treatment. The osteophyte dissolved, and the condylar cortex remained stable during long-term follow-up observations.

CONCLUSION

The muscle balance occlusal splint could be a noninvasive means of treating condylar osteophytes in TMJ OA patients.

Key Words: Condylar osteophyte; Temporomandibular joint osteoarthritis; Mechanical environment; Muscle balance occlusal splint; Treatment; Case report

©The Author(s) 2022. Published by Baishideng Publishing Group Inc. All rights reserved.

Core Tip: Cylindrical osteophytes on the top of the condyle are rare. This is the first report to describe the treatment of condylar osteophyte with an occlusal splint, which may pose a challenge to the traditional application of surgical intervention in the treatment of osteophytes. The effect of occlusal splints on osteophytes is unclear.

Citation: Lan KW, Chen JM, Jiang LL, Feng YF, Yan Y. Treatment of condylar osteophyte in temporomandibular joint osteoarthritis with muscle balance occlusal splint and long-term follow-up: A case report. *World J Clin Cases* 2022; 10(13): 4264-4272

URL: <https://www.wjgnet.com/2307-8960/full/v10/i13/4264.htm>

DOI: <https://dx.doi.org/10.12998/wjcc.v10.i13.4264>

INTRODUCTION

Temporomandibular joint osteoarthritis (TMJ OA) is a non-/low-inflammatory, progressive form of arthritis characterized by degenerative changes to the articular cartilage and the underlying bone, which can lead to pain, masticatory dysfunction, and maxillofacial deformity[1]. Although its exact cause is still unclear, TMJ OA is usually associated with joint trauma and overload; when the stress and functional requirements of the joint area are not balanced with the normal adaptability of the host TMJ, dysfunctional remodeling can occur[2-5]. The first choice of treatment for TMJ OA is usually non-surgical, such as lifestyle/diet adjustments, splint therapy, systemic or intra-articular drug therapy, or physical therapy[1,6]. Only when non-surgical treatment is ineffective and dysfunction and/or pain are moderate to severe is surgical treatment indicated[7].

Osteophytes are a dysfunctional-remodeling form of condyles in TMJ OA patients[8]. Most researchers have observed that condylar osteophytes usually present as marginal angular outgrowths with sclerotic borders and a volume of usually < 1 mm³[8-11]. Researchers have advocated surgical removal of condylar osteophytes. Dingman *et al*[12] noted the recovery of bone physiological morphology in the joint area and advocated the use of arthroplasty to remove irregular osteophytes from the joint surface and remodel its shape. This case report describes a 68-year-old female TMJ OA patient with a rare osteophyte about 2 mm high on the top of the condyle. The patient refused surgical treatment and received conservative treatment with a muscle balance occlusal splint. The patient said that the pain on the left side of her face was relieved, and her ability to chew returned after treatment. The osteophytes dissolved, and the condylar cortex remained stable during long-term follow-up observations. Herein, we discuss the effect of the splint on condylar osteophytes in patients with TMJ OA and provide reference for clinical intervention into these osteophytes.

CASE PRESENTATION

Chief complaints

The patient was a 68-year-old woman who suffered from occlusal discomfort with left facial pain for 2 years.

History of present illness

The patient received splint treatment for left TMJ clicking 2 years ago. She complained that the clicking did not disappear, and she subsequently began to feel weakness in chewing, accompanied by left facial pain and difficulty in opening her mouth.

History of past illness

The patient had no history of systemic disease.

Personal and family history

The patient had no previous personal or familial history of TMJ OA.

Physical examination

The patient was anxious and depressed. Her maxillofacial region was symmetrical. We found no tenderness on palpation of the bilateral external auditory canal and condyle region; the same was true of bilateral TMJ mobility. There was a rebound clicking sound at the left TMJ at the beginning of mouth opening and the end of mouth closing. The mandible deflected vertically when opening; the opening range was about 30 mm. There was no limitation of mandibular protrusive or lateral movement. Local pain was evoked by palpation of the left anterior and middle temporal muscles, the middle and posterior masseter muscles, the upper and middle sternocleidomastoid muscles, the trapezius muscles, and the medial pterygoid muscles. After the splint was placed in her mouth, the patient could not close her mouth while at rest. During centric occlusion, only the premolars were in point contact, and the remaining anterior and posterior teeth did not contact one another (Figure 1).

Laboratory examinations

The patient did not undergo laboratory examination.

Imaging examinations

Cone beam computed tomography (CBCT) performed in March 2017 showed that osteophytes had formed at the anterior margin of the bilateral condyles. A central cylindrical osteophyte 4 mm in diameter and 2 mm in height can be seen on top of the left condyle (Figure 2).

FINAL DIAGNOSIS

Clinical diagnoses were: (1) TMJ disorder (TMD; masticatory-muscle dysfunction); and (2) Bilateral TMJ OA.

TREATMENT

The patient refused surgical treatment and began conservative treatment with a muscle balance occlusal splint (Figure 3) in June 2017. The splint was fixed to the maxillary dentition with clasps; its thickness was about 1.5 mm–2.0 mm at the central fossa of the maxillary first molar and about 3 mm–4 mm in the area of the anterior teeth. The occlusal surface of the splint was designed as a shallow concave structure that formed loose contact with the buccal and lingual cusps of the opposite teeth. The patient was asked to wear the splint all the time, except when eating, and followed every 1–3 mo for evaluation of symptoms and signs. At follow-ups, the clinician adjusted the occlusal surface of the splint so that it once again contacted both sides of the opposite dentition evenly during centric occlusion.

OUTCOME AND FOLLOW-UP

One month later, the patient reported that her left facial pain had disappeared. At 3 mo, the patient's mouth-opening range was improved (to about 35 mm). At 6 mo, the patient reported that her weakness in chewing had reduced and the pain had significantly relieved. She could chew both soft and crisp food.

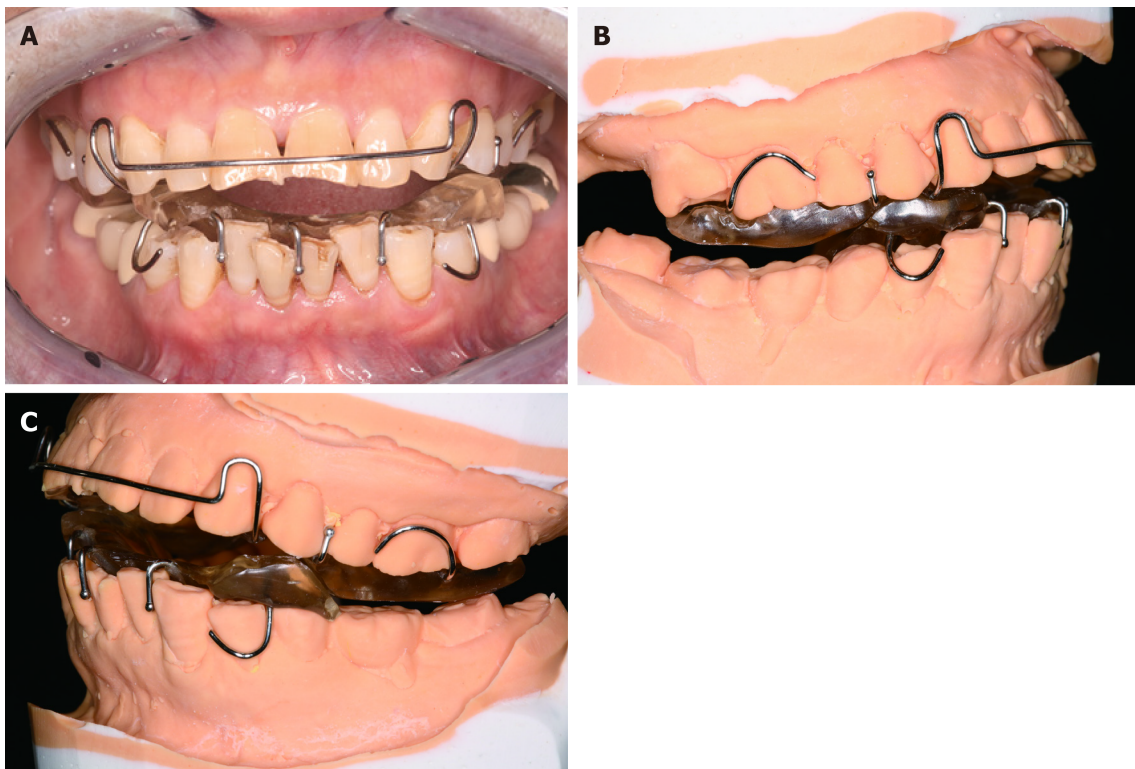
At 9 mo, the patient's rebound clicking sound was reduced and weakened, and she had no discomfort from chewing or facial pain. CBCT re-examination of the TMJ showed that the left condylar top bone had become smooth and the cylindrical osteophyte had disappeared (Figure 4E–H). Three-dimensional reconstruction and alignment of CBCT images before and after treatment can allow visualization of osteophyte dissolution (Figure 5). At 12 mo, the patient's bilateral TMJ CBCT images (Figure 4I–L) were basically the same as those from the previous imaging session.

At 18 mo, the patient had no discomfort when chewing or speaking. Her bilateral TMJ CBCT images (Figure 4M–P) were basically the same as those from the previous imaging session. As the patient's symptoms disappeared and the condylar cortex remained stable, we asked the patient to stop wearing the splint and be followed after 1 year.

At 3 years, the patient has not worn the splint for 1 year. We found no abnormality or discomfort in her TMJ or masticatory muscles. Bilateral TMJ CBCT showed that the bone conditions were basically the same as those from the previous imaging session (Figure 4Q–T).

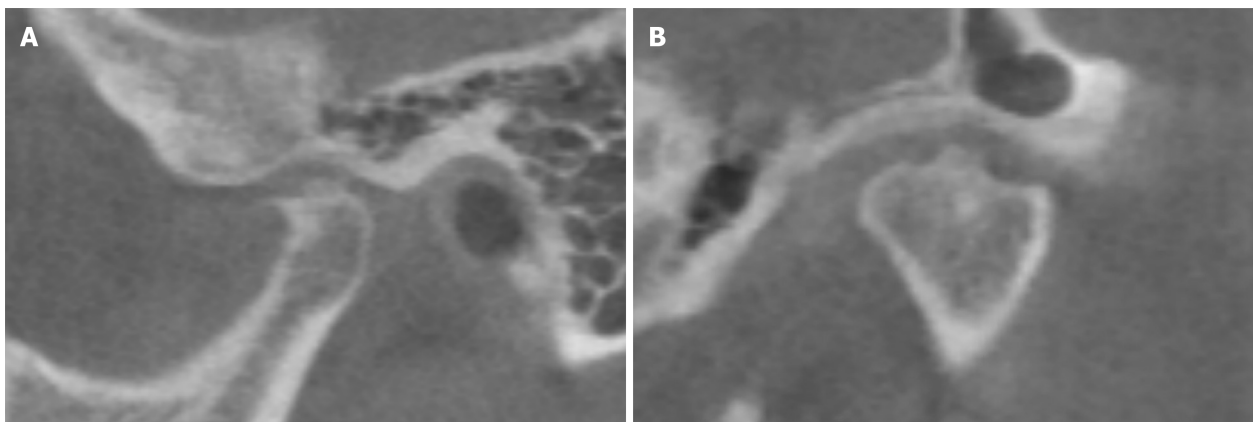
DISCUSSION

Large condylar osteophytes are relatively infrequent in TMJ OA patients. Alexiou *et al*[8] studied the



DOI: 10.12998/wjcc.v10.i13.4264 Copyright ©The Author(s) 2022.

Figure 1 Clinical presentation of the patient wearing the original splint. A: Intraoral photo of the patient; B: Right side of stone cast; C: Left side of stone cast.

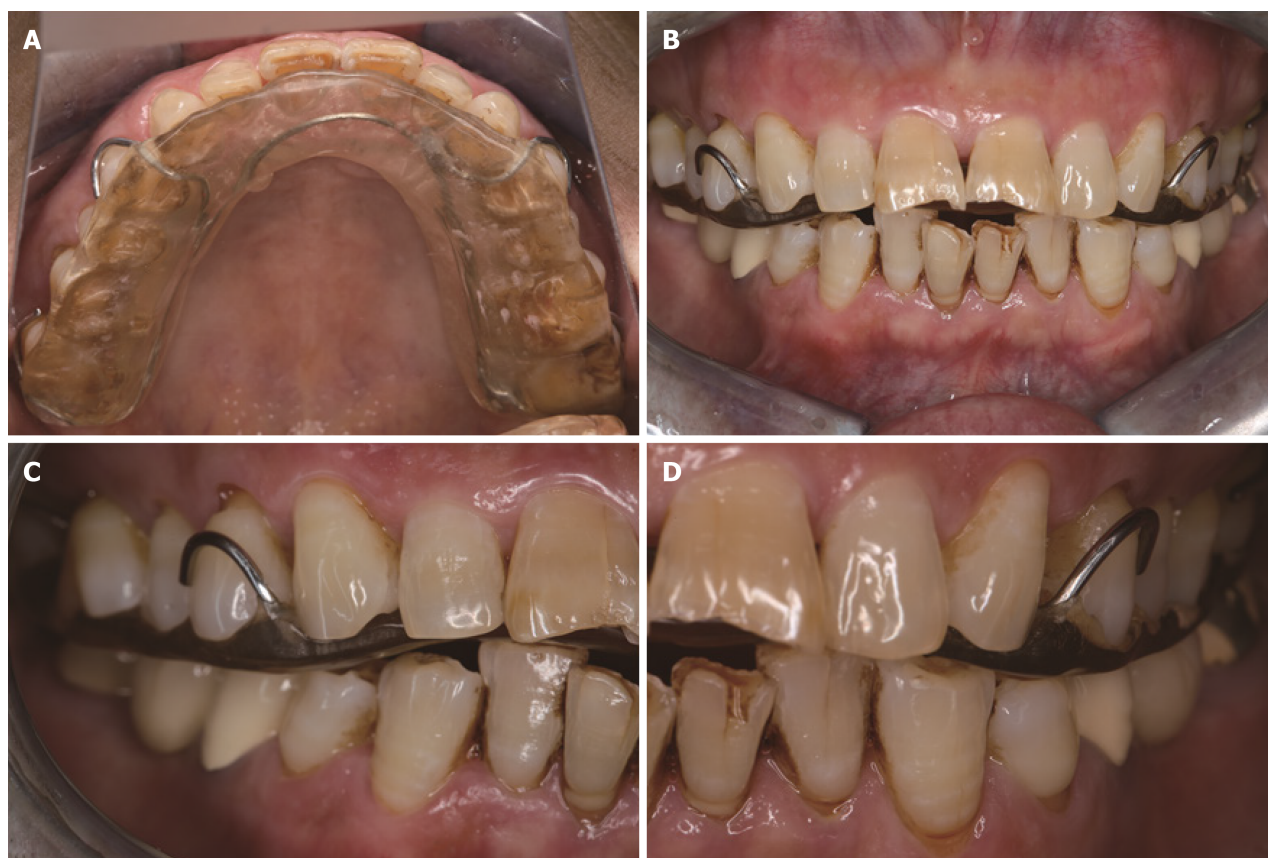

DOI: 10.12998/wjcc.v10.i13.4264 Copyright ©The Author(s) 2022.

Figure 2 Cone beam computed tomography radiographs of the left temporomandibular joint (March 2017). A: Sagittal projection; B: Coronal projection.

imaging features of 142 TMJs with OA and found that 26% of condyles had mild osteophytes < 1 mm, 18% had moderate osteophytes 1 mm–2 mm, and only 12% had severe osteophytes > 2 mm. In this case, CBCT showed the formation of a 1 mm–2 mm, beak-like osteophyte at the front edge of the condyle. These imaging findings corresponded to the size of a moderate osteophyte reported in the literature[8]. However, we could also observe a cylindrical osteophyte about 2 mm high at top center of the left condyle. Although Dingman *et al*[12] have reported the existence of exostosis on the condylar surface, the location and morphology of condylar osteophytes in this situation have not been reported in the literature.

The effect of osteophytes on the TMJ is still controversial. According to Krisjane *et al*[11], the establishment of marginal osteophytes enlarges and stabilizes the articular surface and helps support the loading forces. However, Lee *et al*[13] believed that the extensive formation of osteophytes might lead to condylar deformity. Kirk *et al*[14] analyzed the biomechanical principles of the TMJ and pointed out that osteophytes on the condylar surface and the lateral pole increase the shear force, which can



DOI: 10.12998/wjcc.v10.i13.4264 Copyright ©The Author(s) 2022.

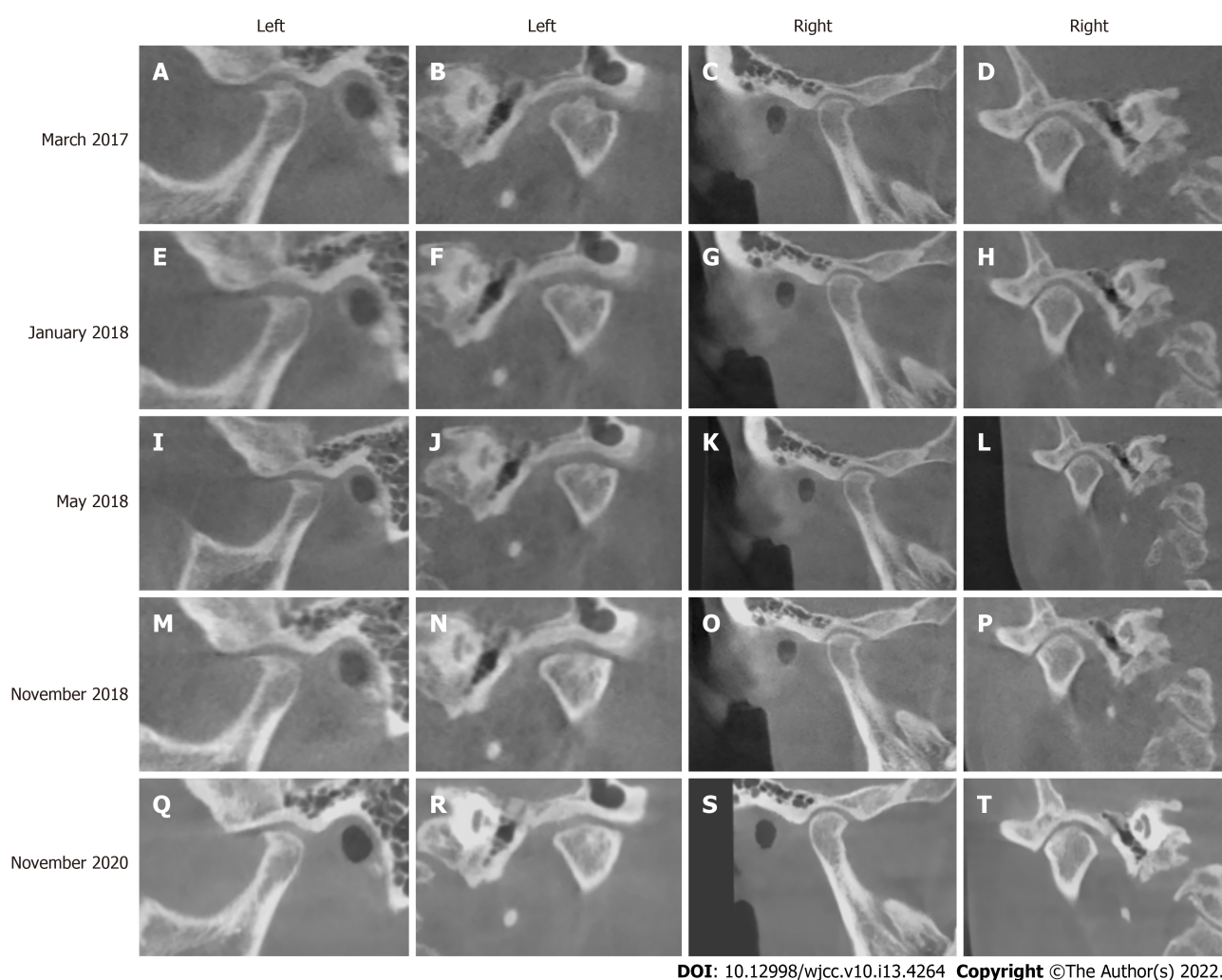
Figure 3 Clinical presentation of wearing the muscle balance occlusal splint. A: The splint was fixed to the maxillary dentition with clasps; B: Centric occlusion; C: Right posterior occlusion; D: Left posterior occlusion.

damage the disc or capsule attachment. Li *et al*[15] found that the higher the degree of osteophytic formation, the more serious the articular-cartilage destruction. We speculate that the cylindrical osteophyte in this case might have been the main disruptor of the disc-condylar relationship, thereby interfering with the mandibular functional movement. However, because we did not perform arthrography or magnetic resonance imaging (MRI) on this patient's TMJ, we could not know the condition of the disc and capsule.

Surgical treatment is the traditional intervention for condylar osteophyte. Kirk *et al*[14] pointed out that the use of arthroplasty to remove osteophyte can reduce disc-condylar relationship disorder and tissue damage in the articular cavity. Although arthroplasty may relieve symptoms, the long-term effects of surgical changes on TMJ remodeling and the function of stomatognathic system are still unclear[1]. In this case, the patient refused surgical treatment. We used a muscle balance occlusal splint for noninvasive treatment. TMJ is a bilaterally linked joint and needs to be balanced bilaterally to achieve a healthy state. Muscle coordination and balance are also concerns. Clinically, the balance of the muscles in patients with masticatory muscle dysfunction is disrupted. The muscles are considered to have reached a balanced state when clinical symptoms, such as pain, disappear. The muscle balance occlusal splint treatment is designed to guarantee stability of occlusion and jaw position, to avoid restricting the jaw position without affecting muscle memory and to allow the masticatory muscle to gradually achieve a balanced state at follow-up visits.

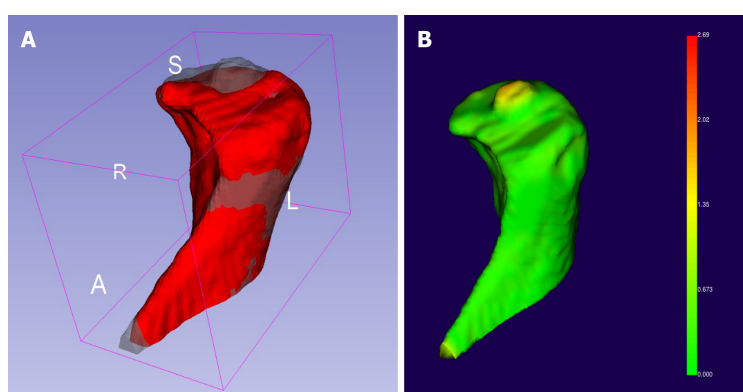
The patient's compliance was good, and no adverse events occurred at any point during the treatment. The patient was satisfied with the therapeutic effect of the muscle balance occlusal splint. After splint treatment began, she felt that her facial-muscle pain was gradually relieved, her masticatory function recovered, and her anxiety relieved.

Osteophytic remodeling is affected by mechanical factors, biochemical factors, and the synergy of their actions. The biomechanical load exerted on the TMJ affects the internal and external shapes of the joint [11]. Overload is generally considered to be one of the main causes of TMJ OA[16,17]. Based on the theory of quantitative bone remodeling, He G and Xinghua Z[18] simulated the formation of osteophytes and found that the change to the joint mechanical environment led to the formation of an osteophyte at the edge of the joint. Osteophytic formation is a process in which the joint adapts to the changing mechanical environment, although it can be pathological. Animal studies have shown that the biochemical factors such as inflammation and metabolic imbalance of articular chondrocytes led to the changes in the microenvironment, which promotes osteophytic formation. The use of drugs such as



DOI: 10.12998/wjcc.v10.i13.4264 Copyright ©The Author(s) 2022.

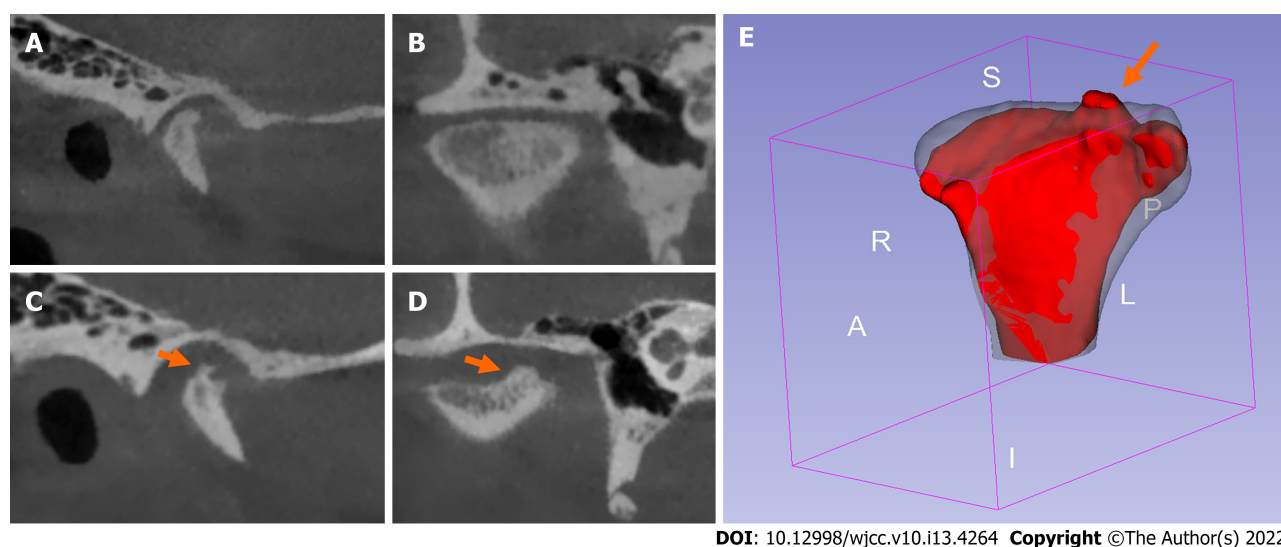
Figure 4 Cone beam computed tomography radiographs of the bilateral temporomandibular joint. A–D: Computed tomography (CBCT) radiographs obtained in March 2017; E–H: CBCT radiographs obtained in January 2018; I–L: CBCT radiographs obtained in May 2018; M–P: CBCT radiographs in obtained November 2018; Q–T: CBCT radiographs obtained in November 2020.



DOI: 10.12998/wjcc.v10.i13.4264 Copyright ©The Author(s) 2022.

Figure 5 Three-dimensional reconstruction of cone beam computed tomography radiographs. A: The reconstruction models of the left condyle before treatment (gray model) and 9 mo after treatment (red model) were compared using 3D Slicer version 4.10.2 (<https://download.slicer.org>); B: We calculated the facial distance of the registration model and found that the 2-mm-high cylindrical osteophyte on top of the condyle had dissolved.

high-molecular-weight hyaluronic acid[15] and corticosteroids[19] has been proven to reduce osteophytic formation in experimental OA in animals. Li *et al*[20] have published images of condylar osteophytic dissolution in patients with TMJ OA after injection of hyaluronic acid, which suggests that the formed osteophyte can still remodel after drug intervention. In this case, we used only the muscle balance occlusal splint and still observed dissolution of the osteophyte, indicating that occlusal-splint



DOI: 10.12998/wjcc.v10.i13.4264 Copyright ©The Author(s) 2022.

Figure 6 Right condylar changes in a 24-year-old female patient with bilateral condylar resorption before and after treatment with the twin-block occlusal splint. A: Cone beam computed tomography (CBCT) sagittal radiograph before treatment; B: CBCT coronal radiograph before treatment; C: CBCT sagittal radiograph after treatment; D: CBCT coronal radiograph after treatment; E: Comparison of the condylar three-dimensional model before (gray model) and after (red model) treatment as viewed using 3D Slicer software. Osteophyte (orange arrow) formed on the medial part of the top of the condyle after treatment.

treatment might potentially affect condylar osteophytic remodeling.

The effect of the splint on condylar osteophytes might be due to changes to the mechanical environment of the joint. An anterior repositioning splint (ARS) has been reported to promote condylar osteogenesis. The reason might be that the ARS guides mandibular advancement and joint disc repositioning; the condylar cartilage is subject to tensile stress, leading to adaptive condylar remodeling[21]. The change to the bone mechanical environment is accompanied by changes to the bone structure and shape, which force the bone to adapt to the new mechanical environment[18]. Previous reports on the effect of occlusal splint on TMJ OA patients' joint bone mostly focused on treatment with this splint, which can reduce absorption of the affected condyle and promote repair and regeneration[6,22-24]. The advantage of the occlusal splint (especially the stable occlusal splint) lies in the stability of occlusion and the uniform distribution of TMJ overload[25]. In patients with TMJ OA, overload to the TMJ is reduced, thereby reducing bone resorption of the joint[6]. However, the splint's effect on the dissolution of condylar osteophytes has not yet been reported.

We cannot explain certain aspects of this case. The cause of osteophytic formation on top of the condyle was unclear. The patient had received treatment with a splint similar to the twin-block (TB) splint (Figure 1), but due to the lack of CBCT image comparisons before and after the splint treatment, we could not determine the relationship between such treatment and the osteophyte on top of her condyle. However, we have observed another case in which an adult patient with condylar resorption was treated with the TB splint and an osteophyte appeared on top of the condyle after treatment (Figure 6). In addition, the splint had different effects on the osteophyte in different condylar positions. Although the osteophyte on top of the condyle dissolved, the marginal osteophyte did not change significantly. Differences in stress in different areas of the joint might have caused the differences in bone remodeling. In future, the mechanical effect of the muscle balance occlusal splint on the joint should be explored in both basic and clinical research, so as to determine the effect of this splint therapy on condylar osteophytic remodeling.

CONCLUSION

This case report suggests that the muscle balance occlusal splint could be a noninvasive means of treating condylar osteophytes in TMJ OA patients. The specific mechanism of the splint treatment on osteophytic remodeling is still unclear, and further basic and clinical research is needed.

FOOTNOTES

Author contributions: Yan Y, Lan KW, Chen JM, Jiang LL, and Feng YF examined the patient and collected the clinical data; Lan KW, Chen JM, Jiang LL, and Feng YF wrote the manuscript; Yan Y edited the manuscript and approved the final version.

Informed consent statement: Informed consent was obtained from the patient for publication of this report and any accompanying images.

Conflict-of-interest statement: All authors own a patent (No. ZL 202120549626.3, CN) describing the design of the muscle balance occlusal splint, as well as its treatment application for temporomandibular joint disorder and bruxism. The patent is licensed to Hospital of Stomatology, Sun Yat-sen University.

CARE Checklist (2016) statement: The authors have read the CARE Checklist (2016), and the manuscript was prepared and revised according to the CARE Checklist (2016).

Open-Access: This article is an open-access article that was selected by an in-house editor and fully peer-reviewed by external reviewers. It is distributed in accordance with the Creative Commons Attribution NonCommercial (CC BY-NC 4.0) license, which permits others to distribute, remix, adapt, build upon this work non-commercially, and license their derivative works on different terms, provided the original work is properly cited and the use is non-commercial. See: <https://creativecommons.org/licenses/by-nc/4.0/>

Country/Territory of origin: China

ORCID number: Kai-Wen Lan 0000-0002-2239-4130; Jia-Min Chen 0000-0001-6059-4881; Liu-Lin Jiang 0000-0001-9570-995X; Yi-Fan Feng 0000-0003-3070-1492; Ying Yan 0000-0002-3134-2463.

S-Editor: Xing YX

L-Editor: Wang TQ

P-Editor: Xing YX

REFERENCES

- 1 Renapurkar SK. Surgical Versus Nonsurgical Management of Degenerative Joint Disease. *Oral Maxillofac Surg Clin North Am* 2018; **30**: 291-297 [PMID: 30008342 DOI: 10.1016/j.coms.2018.04.005]
- 2 Tanaka E, Detamore MS, Mercuri LG. Degenerative disorders of the temporomandibular joint: etiology, diagnosis, and treatment. *J Dent Res* 2008; **87**: 296-307 [PMID: 18362309 DOI: 10.1177/154405910808700406]
- 3 Milam SB. Pathogenesis of degenerative temporomandibular joint arthritides. *Odontology* 2005; **93**: 7-15 [PMID: 16170470 DOI: 10.1007/s10266-005-0056-7]
- 4 Arnett GW, Milam SB, Gottesman L. Progressive mandibular retrusion--idiopathic condylar resorption. Part I. *Am J Orthod Dentofacial Orthop* 1996; **110**: 8-15 [PMID: 8686682 DOI: 10.1016/S0889-5406(96)70081-1]
- 5 Arnett GW, Milam SB, Gottesman L. Progressive mandibular retrusion-idiopathic condylar resorption. Part II. *Am J Orthod Dentofacial Orthop* 1996; **110**: 117-127 [PMID: 8760837 DOI: 10.1016/S0889-5406(96)70099-9]
- 6 Ok S, Jeong S, Ahn Y, Kim Y. Effect of stabilization splint therapy on glenoid fossa remodeling in temporomandibular joint osteoarthritis. *J Prosthodont Res* 2016; **60**: 301-307 [PMID: 27026211 DOI: 10.1016/j.jpor.2016.03.001]
- 7 Bouloux G, Koslin MG, Ness G, Shafer D. Temporomandibular Joint Surgery. *J Oral Maxillofac Surg* 2017; **75**: e195-e223 [PMID: 28728730 DOI: 10.1016/j.joms.2017.04.027]
- 8 Alexiou K, Stamatakis H, Tsiklakis K. Evaluation of the severity of temporomandibular joint osteoarthritic changes related to age using cone beam computed tomography. *Dentomaxillofac Radiol* 2009; **38**: 141-147 [PMID: 19225084 DOI: 10.1259/dmfr/59263880]
- 9 Massilla Mani F, Sivasubramanian SS. A study of temporomandibular joint osteoarthritis using computed tomographic imaging. *Biomed J* 2016; **39**: 201-206 [PMID: 27621122 DOI: 10.1016/j.bj.2016.06.003]
- 10 Lim MJ, Lee JY. Computed tomographic study of the patterns of osteoarthritic change which occur on the mandibular condyle. *J Craniomaxillofac Surg* 2014; **42**: 1897-1902 [PMID: 25240743 DOI: 10.1016/j.jcms.2014.07.009]
- 11 Krisjane Z, Urtane I, Krumina G, Neimane L, Ragovska I. The prevalence of TMJ osteoarthritis in asymptomatic patients with dentofacial deformities: a cone-beam CT study. *Int J Oral Maxillofac Surg* 2012; **41**: 690-695 [PMID: 22464854 DOI: 10.1016/j.ijom.2012.03.006]
- 12 Dingman RO, Grabb WC. Intra-capsular temporomandibular joint arthroplasty. *Plast Reconstr Surg* 1966; **38**: 179-185 [PMID: 5919600 DOI: 10.1097/00006534-196609000-00001]
- 13 Lee PP, Stanton AR, Hollender LG. Greater mandibular horizontal condylar angle is associated with temporomandibular joint osteoarthritis. *Oral Surg Oral Med Oral Pathol Oral Radiol* 2017; **123**: 502-507 [PMID: 28189528 DOI: 10.1016/j.oooo.2016.12.008]
- 14 Kirk WS Jr, Kirk BS. A biomechanical basis for primary arthroplasty of the temporomandibular joint. *Oral Maxillofac Surg Clin North Am* 2006; **18**: 345-368, vi [PMID: 18088837 DOI: 10.1016/j.coms.2006.03.006]
- 15 Li P, Raitcheva D, Hawes M, Moran N, Yu X, Wang F, Matthews GL, Hylan G-F 20. maintains cartilage integrity and decreases osteophyte formation in osteoarthritis through both anabolic and anti-catabolic mechanisms. *Osteoarthritis Cartilage* 2012; **20**: 1336-1346 [PMID: 22809835 DOI: 10.1016/j.joca.2012.07.004]
- 16 Lin YY, Tanaka N, Ohkuma S, Iwabuchi Y, Tanne Y, Kamiya T, Kunitatsu R, Huang YC, Yoshioka M, Mitsuyoshi T, Tanimoto K, Tanaka E, Tanne K. Applying an excessive mechanical stress alters the effect of subchondral osteoblasts on chondrocytes in a co-culture system. *Eur J Oral Sci* 2010; **118**: 151-158 [PMID: 20487004 DOI: 10.1111/j.1600-0722.2010.00710.x]

- 17 **Nishioka M**, Ioi H, Matsumoto R, Goto TK, Nakata S, Nakasima A, Counts AL, Davidovitch Z. TMJ osteoarthritis/osteoarthrosis and immune system factors in a Japanese sample. *Angle Orthod* 2008; **78**: 793-798 [PMID: 18298222 DOI: 10.2319/091407-438]
- 18 **He G**, Xinghua Z. The numerical simulation of osteophyte formation on the edge of the vertebral body using quantitative bone remodeling theory. *Joint Bone Spine* 2006; **73**: 95-101 [PMID: 16253537 DOI: 10.1016/j.jbspin.2005.03.019]
- 19 **Pelletier JP**, Martel-Pelletier J. Protective effects of corticosteroids on cartilage lesions and osteophyte formation in the Pond-Nuki dog model of osteoarthritis. *Arthritis Rheum* 1989; **32**: 181-193 [PMID: 2920053 DOI: 10.1002/anr.1780320211]
- 20 **Li C**, Long X, Deng M, Li J, Cai H, Meng Q. Osteoarthritic changes after superior and inferior joint space injection of hyaluronic acid for the treatment of temporomandibular joint osteoarthritis with anterior disc displacement without reduction: a cone-beam computed tomographic evaluation. *J Oral Maxillofac Surg* 2015; **73**: 232-244 [PMID: 25579006 DOI: 10.1016/j.joms.2014.08.034]
- 21 **Ma Z**, Xie Q, Yang C, Zhang S, Shen Y, Abdelrehem A. Can anterior repositioning splint effectively treat temporomandibular joint disc displacement? *Sci Rep* 2019; **9**: 534 [PMID: 30679602 DOI: 10.1038/s41598-018-36988-8]
- 22 **Lei J**, Yap AU, Liu MQ, Fu KY. Condylar repair and regeneration in adolescents/young adults with early-stage degenerative temporomandibular joint disease: A randomised controlled study. *J Oral Rehabil* 2019; **46**: 704-714 [PMID: 31009097 DOI: 10.1111/joor.12805]
- 23 **Ok S**, Lee J, Kim Y, Kim K B, Jeong S. Anterior condylar remodeling observed in stabilization splint therapy for temporomandibular joint osteoarthritis. *Oral Surg Oral Med Oral Pathol Oral Radiol* 2014; **118**: 363-370 [PMID: 25151591 DOI: 10.1016/j.oooo.2014.05.022]
- 24 **Cuccia AM**, Caradonna C. Condylar growth after non-surgical advancement in adult subject: a case report. *Head Face Med* 2009; **5**: 15 [PMID: 19619334 DOI: 10.1186/1746-160X-5-15]
- 25 **Hasegawa Y**, Kakimoto N, Tomita S, Fujiwara M, Ishikura R, Kishimoto H, Honda K. Evaluation of the role of splint therapy in the treatment of temporomandibular joint pain on the basis of MRI evidence of altered disc position. *J Craniomaxillofac Surg* 2017; **45**: 455-460 [PMID: 28238557 DOI: 10.1016/j.jcms.2017.01.011]



Published by **Baishideng Publishing Group Inc**
7041 Koll Center Parkway, Suite 160, Pleasanton, CA 94566, USA

Telephone: +1-925-3991568

E-mail: bpgoffice@wjgnet.com

Help Desk: <https://www.f6publishing.com/helpdesk>

<https://www.wjgnet.com>

