

World Journal of *Clinical Cases*

World J Clin Cases 2022 July 6; 10(19): 6341-6758



Contents

Thrice Monthly Volume 10 Number 19 July 6, 2022

MINIREVIEWS

- 6341** Review of clinical characteristics, immune responses and regulatory mechanisms of hepatitis E-associated liver failure
Chen C, Zhang SY, Chen L
- 6349** Current guidelines for *Helicobacter pylori* treatment in East Asia 2022: Differences among China, Japan, and South Korea
Cho JH, Jin SY
- 6360** Review of epidermal growth factor receptor-tyrosine kinase inhibitors administration to non-small-cell lung cancer patients undergoing hemodialysis
Lan CC, Hsieh PC, Huang CY, Yang MC, Su WL, Wu CW, Wu YK

ORIGINAL ARTICLE

Case Control Study

- 6370** Pregnancy-related psychopathology: A comparison between pre-COVID-19 and COVID-19-related social restriction periods
Chieffo D, Avallone C, Serio A, Kotzalidis GD, Balocchi M, De Luca I, Hirsch D, Gonzalez del Castillo A, Lanzotti P, Marano G, Rinaldi L, Lanzone A, Mercuri E, Mazza M, Sani G
- 6385** Intestinal mucosal barrier in functional constipation: Does it change?
Wang JK, Wei W, Zhao DY, Wang HF, Zhang YL, Lei JP, Yao SK

Retrospective Cohort Study

- 6399** Identification of risk factors for surgical site infection after type II and type III tibial pilon fracture surgery
Hu H, Zhang J, Xie XG, Dai YK, Huang X

Retrospective Study

- 6406** Total knee arthroplasty in Ranawat II valgus deformity with enlarged femoral valgus cut angle: A new technique to achieve balanced gap
Lv SJ, Wang XJ, Huang JF, Mao Q, He BJ, Tong PJ
- 6417** Preliminary evidence in treatment of eosinophilic gastroenteritis in children: A case series
Chen Y, Sun M
- 6428** Self-made wire loop snare successfully treats gastric persimmon stone under endoscopy
Xu W, Liu XB, Li SB, Deng WP, Tong Q
- 6437** Neoadjuvant transcatheter arterial chemoembolization and systemic chemotherapy for the treatment of undifferentiated embryonal sarcoma of the liver in children
He M, Cai JB, Lai C, Mao JQ, Xiong JN, Guan ZH, Li LJ, Shu Q, Ying MD, Wang JH

- 6446** Effect of cold snare polypectomy for small colorectal polyps

Meng QQ, Rao M, Gao PJ

- 6456** Field evaluation of COVID-19 rapid antigen test: Are rapid antigen tests less reliable among the elderly?

Tabain I, Cucevic D, Skreb N, Mrzljak A, Ferencak I, Hruskar Z, Misic A, Kuzle J, Skoda AM, Jankovic H, Vilibic-Cavlek T

Observational Study

- 6464** Tracheobronchial intubation using flexible bronchoscopy in children with Pierre Robin sequence: Nursing considerations for complications

Ye YL, Zhang CF, Xu LZ, Fan HF, Peng JZ, Lu G, Hu XY

- 6472** Family relationship of nurses in COVID-19 pandemic: A qualitative study

Çelik MY, Kiliç M

META-ANALYSIS

- 6483** Diagnostic accuracy of ≥ 16 -slice spiral computed tomography for local staging of colon cancer: A systematic review and meta-analysis

Liu D, Sun LM, Liang JH, Song L, Liu XP

CASE REPORT

- 6496** Delayed-onset endophthalmitis associated with *Achromobacter* species developed in acute form several months after cataract surgery: Three case reports

Kim TH, Lee SJ, Nam KY

- 6501** Sustained dialysis with misplaced peritoneal dialysis catheter outside peritoneum: A case report

Shen QQ, Behera TR, Chen LL, Attia D, Han F

- 6507** Arteriovenous thrombotic events in a patient with advanced lung cancer following bevacizumab plus chemotherapy: A case report

Kong Y, Xu XC, Hong L

- 6514** Endoscopic ultrasound radiofrequency ablation of pancreatic insulinoma in elderly patients: Three case reports

Rossi G, Petrone MC, Capurso G, Partelli S, Falconi M, Arcidiacono PG

- 6520** Acute choroidal involvement in lupus nephritis: A case report and review of literature

Yao Y, Wang HX, Liu LW, Ding YL, Sheng JE, Deng XH, Liu B

- 6529** Triple A syndrome-related achalasia treated by per-oral endoscopic myotomy: Three case reports

Liu FC, Feng YL, Yang AM, Guo T

- 6536** Choroidal thickening with serous retinal detachment in BRAF/MEK inhibitor-induced uveitis: A case report

Kiraly P, Groznik AL, Valentinčič NV, Mekjavić PJ, Urbančič M, Ocvirk J, Mesti T

- 6543** Esophageal granular cell tumor: A case report

Chen YL, Zhou J, Yu HL

- 6548** Hem-o-lok clip migration to the common bile duct after laparoscopic common bile duct exploration: A case report
Liu DR, Wu JH, Shi JT, Zhu HB, Li C
- 6555** Chidamide and sintilimab combination in diffuse large B-cell lymphoma progressing after chimeric antigen receptor T therapy
Hao YY, Chen PP, Yuan XG, Zhao AQ, Liang Y, Liu H, Qian WB
- 6563** Relapsing polychondritis with isolated tracheobronchial involvement complicated with Sjogren's syndrome: A case report
Chen JY, Li XY, Zong C
- 6571** Acute methanol poisoning with bilateral diffuse cerebral hemorrhage: A case report
Li J, Feng ZJ, Liu L, Ma YJ
- 6580** Immunoabsorption therapy for Klinefelter syndrome with antiphospholipid syndrome in a patient: A case report
Song Y, Xiao YZ, Wang C, Du R
- 6587** Roxadustat for treatment of anemia in a cancer patient with end-stage renal disease: A case report
Zhou QQ, Li J, Liu B, Wang CL
- 6595** Imaging-based diagnosis for extraskeletal Ewing sarcoma in pediatrics: A case report
Chen ZH, Guo HQ, Chen JJ, Zhang Y, Zhao L
- 6602** Unusual course of congenital complete heart block in an adult: A case report
Su LN, Wu MY, Cui YX, Lee CY, Song JX, Chen H
- 6609** Penile metastasis from rectal carcinoma: A case report
Sun JJ, Zhang SY, Tian JJ, Jin BY
- 6617** Isolated cryptococcal osteomyelitis of the ulna in an immunocompetent patient: A case report
Ma JL, Liao L, Wan T, Yang FC
- 6626** Magnetic resonance imaging features of intrahepatic extramedullary hematopoiesis: Three case reports
Luo M, Chen JW, Xie CM
- 6636** Giant retroperitoneal liposarcoma treated with radical conservative surgery: A case report and review of literature
Lieto E, Cardella F, Erario S, Del Sorbo G, Reginelli A, Galizia G, Urraro F, Panarese I, Auricchio A
- 6647** Transplanted kidney loss during colorectal cancer chemotherapy: A case report
Pośpiech M, Kolonko A, Nieszporek T, Kozak S, Kozaczka A, Karkoszka H, Winder M, Chudek J
- 6656** Massive gastrointestinal bleeding after endoscopic rubber band ligation of internal hemorrhoids: A case report
Jiang YD, Liu Y, Wu JD, Li GP, Liu J, Hou XH, Song J

- 6664** Mills' syndrome is a unique entity of upper motor neuron disease with N-shaped progression: Three case reports
Zhang ZY, Ouyang ZY, Zhao GH, Fang JJ
- 6672** Entire process of electrocardiogram recording of Wellens syndrome: A case report
Tang N, Li YH, Kang L, Li R, Chu QM
- 6679** Retroperitoneal tumor finally diagnosed as a bronchogenic cyst: A case report and review of literature
Gong YY, Qian X, Liang B, Jiang MD, Liu J, Tao X, Luo J, Liu HJ, Feng YG
- 6688** Successful treatment of Morbihan disease with total glucosides of paeony: A case report
Zhou LF, Lu R
- 6695** Ant sting-induced whole-body pustules in an inebriated male: A case report
Chen SQ, Yang T, Lan LF, Chen XM, Huang DB, Zeng ZL, Ye XY, Wan CL, Li LN
- 6702** Plastic surgery for giant metastatic endometrioid adenocarcinoma in the abdominal wall: A case report and review of literature
Wang JY, Wang ZQ, Liang SC, Li GX, Shi JL, Wang JL
- 6710** Delayed-release oral mesalamine tablet mimicking a small jejunal gastrointestinal stromal tumor: A case report
Frosio F, Rausa E, Marra P, Boutron-Ruault MC, Lucianetti A
- 6716** Concurrent alcoholic cirrhosis and malignant peritoneal mesothelioma in a patient: A case report
Liu L, Zhu XY, Zong WJ, Chu CL, Zhu JY, Shen XJ
- 6722** Two smoking-related lesions in the same pulmonary lobe of squamous cell carcinoma and pulmonary Langerhans cell histiocytosis: A case report
Gencer A, Ozcibik G, Karakas FG, Sarbay I, Batur S, Borekci S, Turna A
- 6728** Proprotein convertase subtilisin/kexin type 9 inhibitor non responses in an adult with a history of coronary revascularization: A case report
Yang L, Xiao YY, Shao L, Ouyang CS, Hu Y, Li B, Lei LF, Wang H
- 6736** Multimodal imaging study of lipemia retinalis with diabetic retinopathy: A case report
Zhang SJ, Yan ZY, Yuan LF, Wang YH, Wang LF
- 6744** Primary squamous cell carcinoma of the liver: A case report
Kang LM, Yu DP, Zheng Y, Zhou YH
- 6750** Tumor-to-tumor metastasis of clear cell renal cell carcinoma to contralateral synchronous pheochromocytoma: A case report
Wen HY, Hou J, Zeng H, Zhou Q, Chen N

ABOUT COVER

Editorial Board Member of *World Journal of Clinical Cases*, Abdulqadir Jeprel Naswhan, MSc, RN, Director, Research Scientist, Senior Lecturer, Senior Researcher, Nursing for Education and Practice Development, Hamad Medical Corporation, Doha 576214, Qatar. anashwan@hamad.qa

AIMS AND SCOPE

The primary aim of *World Journal of Clinical Cases* (WJCC, *World J Clin Cases*) is to provide scholars and readers from various fields of clinical medicine with a platform to publish high-quality clinical research articles and communicate their research findings online.

WJCC mainly publishes articles reporting research results and findings obtained in the field of clinical medicine and covering a wide range of topics, including case control studies, retrospective cohort studies, retrospective studies, clinical trials studies, observational studies, prospective studies, randomized controlled trials, randomized clinical trials, systematic reviews, meta-analysis, and case reports.

INDEXING/ABSTRACTING

The WJCC is now indexed in Science Citation Index Expanded (also known as SciSearch®), Journal Citation Reports/Science Edition, Scopus, PubMed, and PubMed Central. The 2021 Edition of Journal Citation Reports® cites the 2020 impact factor (IF) for WJCC as 1.337; IF without journal self cites: 1.301; 5-year IF: 1.742; Journal Citation Indicator: 0.33; Ranking: 119 among 169 journals in medicine, general and internal; and Quartile category: Q3. The WJCC's CiteScore for 2020 is 0.8 and Scopus CiteScore rank 2020: General Medicine is 493/793.

RESPONSIBLE EDITORS FOR THIS ISSUE

Production Editor: Xu Guo; Production Department Director: Xiang Li; Editorial Office Director: Jin-Lai Wang.

NAME OF JOURNAL

World Journal of Clinical Cases

ISSN

ISSN 2307-8960 (online)

LAUNCH DATE

April 16, 2013

FREQUENCY

Thrice Monthly

EDITORS-IN-CHIEF

Bao-Gan Peng, Jerzy Tadeusz Chudek, George Kontogeorgos, Maurizio Serati, Ja Hyeon Ku

EDITORIAL BOARD MEMBERS

<https://www.wjgnet.com/2307-8960/editorialboard.htm>

PUBLICATION DATE

July 6, 2022

COPYRIGHT

© 2022 Baishideng Publishing Group Inc

INSTRUCTIONS TO AUTHORS

<https://www.wjgnet.com/bpg/gerinfo/204>

GUIDELINES FOR ETHICS DOCUMENTS

<https://www.wjgnet.com/bpg/GerInfo/287>

GUIDELINES FOR NON-NATIVE SPEAKERS OF ENGLISH

<https://www.wjgnet.com/bpg/gerinfo/240>

PUBLICATION ETHICS

<https://www.wjgnet.com/bpg/GerInfo/288>

PUBLICATION MISCONDUCT

<https://www.wjgnet.com/bpg/gerinfo/208>

ARTICLE PROCESSING CHARGE

<https://www.wjgnet.com/bpg/gerinfo/242>

STEPS FOR SUBMITTING MANUSCRIPTS

<https://www.wjgnet.com/bpg/GerInfo/239>

ONLINE SUBMISSION

<https://www.f6publishing.com>



Retrospective Study

Neoadjuvant transcatheter arterial chemoembolization and systemic chemotherapy for the treatment of undifferentiated embryonal sarcoma of the liver in children

Min He, Jia-Bin Cai, Can Lai, Jun-Qing Mao, Jie-Ni Xiong, Zhong-Hai Guan, Lin-Jie Li, Qiang Shu, Mei-Dan Ying, Jin-Hu Wang

Specialty type: Medicine, research and experimental

Provenance and peer review:

Unsolicited article; Externally peer reviewed.

Peer-review model: Single blind

Peer-review report's scientific quality classification

Grade A (Excellent): 0
Grade B (Very good): 0
Grade C (Good): C, C
Grade D (Fair): D
Grade E (Poor): 0

P-Reviewer: Marra P, Italy;
Zimmitti G, Italy

A-Editor: Liu X

Received: November 11, 2021

Peer-review started: November 11, 2021

First decision: March 3, 2022

Revised: March 23, 2022

Accepted: May 16, 2022

Article in press: May 16, 2022

Published online: July 6, 2022



Min He, Jia-Bin Cai, Jun-Qing Mao, Jie-Ni Xiong, Zhong-Hai Guan, Lin-Jie Li, Qiang Shu, Jin-Hu Wang, Department of Surgical Oncology, The Children's Hospital, Zhejiang University School of Medicine, National Clinical Research Center for Child Health, Hangzhou 310052, Zhejiang Province, China

Can Lai, Department of Radiology, The Children's Hospital, Zhejiang University School of Medicine, National Clinical Research Center for Child Health, Hangzhou 310052, Zhejiang Province, China

Mei-Dan Ying, Cancer Center, Zhejiang University, Hangzhou 310058, Zhejiang Province, China

Corresponding author: Jin-Hu Wang, MD, PhD, Chief Doctor, Director, Surgical Oncologist, Department of Surgical Oncology, The Children's Hospital, Zhejiang University School of Medicine, National Clinical Research Center for Child Health, No. 3333 Binsheng Road, Hangzhou 310052, Zhejiang Province, China. wjh@zju.edu.cn

Abstract

BACKGROUND

Undifferentiated embryonal sarcoma of the liver (UESL) is a rare and aggressive mesenchymal tumor in children. Herein, we describe our experience in neoadjuvant therapy (NAT) and subsequent surgery for the treatment of UESL in children.

AIM

To evaluate the efficacy of NAT and explore a new choice for successful operation of UESL in children.

METHODS

We retrospectively analyzed six patients newly diagnosed with unresectable UESL who received NAT and then surgery at our center between January 2004 and December 2019. The tumor was considered unresectable if it involved a large part of both lobes of the liver or had invaded the main hepatic vessels or inferior vena cava. The NAT included preoperative transcatheter arterial chemoembol-

ization (TACE) and systemic chemotherapy. The patients were 4 boys and 2 girls with a mean age of 7 years. The longest tumor at presentation ranged from 8.6 to 14.8 cm (mean, 12 cm). Extrahepatic metastases were present in 2 cases. Preoperative systemic chemotherapy was administered 3 wk after TACE. Tumor resection was performed 3 wk after one or two cycles of NAT. The patients received systemic chemotherapy after surgery.

RESULTS

All patients successfully underwent NAT and complete resection. The tumor volumes decreased by 18.2%–68.7%, with a mean decrease of 36% after 1 cycle of NAT ($t = 3.524$, $P = 0.017$). According to the Response Evaluation Criteria In Solid Tumors criteria, 4 patients had a partial response and underwent surgery, while 2 had stable disease and received another cycle of NAT before surgery. Massive tumor necrosis was seen on pathological examination of the surgical specimen: > 90% necrosis in two, > 50% necrosis in three, and 25% necrosis in 1, with an average of 71.8%. Post-NAT complications included fever, nausea and vomiting, and mild bone marrow suppression. Elevated alanine transaminase levels occurred in all patients, which returned to normal within 7–10 d after treatment. No cardiac or renal toxicity, severe hepatic dysfunction, bleeding and non-target embolization were observed in the patients. The median follow-up period was 8 years with an overall survival of 100%.

CONCLUSION

NAT effectively reduced tumor volume, cleared the tumor margin, and caused massive tumor necrosis. This may be a promising choice for successful surgery of UESL in children.

Key Words: Undifferentiated embryonal sarcoma of the liver; Unresectable; Neoadjuvant therapy; Transcatheter arterial chemoembolization; Systemic chemotherapy

©The Author(s) 2022. Published by Baishideng Publishing Group Inc. All rights reserved.

Core Tip: Undifferentiated embryonal sarcoma of the liver (UESL) is a rare and aggressive mesenchymal tumor in children. The prognosis of UESL has previously been considered poor. Modern multimodal treatment and supportive therapy have improved survival. Complete tumor excision plays the central role in the treatment of UESL. In this study, we analyzed our single-center data of children with UESL who received neoadjuvant therapy (NAT) between January 2004 and December 2019, and found that NAT effectively reduced tumor volume, cleared tumor margin, and caused massive tumor necrosis. It may provide a promising choice for successful operation of UESL in children.

Citation: He M, Cai JB, Lai C, Mao JQ, Xiong JN, Guan ZH, Li LJ, Shu Q, Ying MD, Wang JH. Neoadjuvant transcatheter arterial chemoembolization and systemic chemotherapy for the treatment of undifferentiated embryonal sarcoma of the liver in children. *World J Clin Cases* 2022; 10(19): 6437-6445

URL: <https://www.wjgnet.com/2307-8960/full/v10/i19/6437.htm>

DOI: <https://dx.doi.org/10.12998/wjcc.v10.i19.6437>

INTRODUCTION

Undifferentiated embryonal sarcoma of the liver (UESL) is a rare and aggressive mesenchymal tumor that occurs mainly between the ages of 6 and 10 years, without gender predominance[1]. The prognosis of UESL has previously been considered poor[2]. Modern multimodal treatment and supportive therapy have improved survival[3]. Complete tumor excision plays the central role in the treatment of UESL[4]. Transcatheter arterial chemoembolization (TACE) is an effective therapeutic method and has been widely used in the treatment of patients with hepatic malignancy[5,6]. In an attempt to increase resection rate and improve the outcome of UESL, we performed preoperative TACE combined with systematic chemotherapy for the treatment of unresectable UESL in children and evaluated its feasibility and effectiveness.

MATERIALS AND METHODS

Patient characteristics

All the procedures in this study conformed to the ethical requirements of the Ethics Committee of the Children's Hospital, Zhejiang University School of Medicine and have been approved. The children's families provided signed informed consent. Six patients with UESL received neoadjuvant therapy (NAT) at our hospital between January 2004 and December 2019. The patients were 4 boys and 2 girls with a mean age of 7 years (range, 3–11 years). The symptoms at admission included abdominal pain, abdominal mass and jaundice. The longest tumor ranged from 8.6 to 14.8 cm (mean, 12 cm). One patient presented with pulmonary metastasis and another with retroperitoneal lymph node metastases. The details of the six patients are summarized in [Table 1](#).

NAT

Pathological diagnosis was obtained by percutaneous needle biopsy before treatment in all patients. NAT included preoperative TACE and systemic chemotherapy. TACE was performed under general and sacral block anesthesia. With continuous monitoring, including electrocardiography, blood pressure and oxygen saturation measurements, the femoral artery was catheterized using the Seldinger technique. A 5-F Pigtail catheter was introduced into the abdominal aorta to perform aortography and define the main feeding artery of the tumor, and then a 4-F or 5-F Cobra catheter was advanced toward the tumor-feeding arteries for chemoembolization. The chemoembolic emulsion consisted of pirarubicin 40 mg/m², vindesine 3 mg/m², cisplatin 90 mg/m² and iodized oil 0.5 mL *per* maximum tumor diameter (cm), which has been proved to have good efficacy and safety in the treatment of UESL and other tumors in our center[5,7]. The drugs were mixed and diluted in 120–180 mL of normal saline, and infused into the feeding artery at a rate of 120 mL/h. After perfusion, the outline of the entire tumor was revealed ([Figure 1](#)).

Intravenous chemotherapy was administered 3 wk after TACE if the blood parameters were at normal levels. The chemotherapy regimen consisted of vindesine 3 mg/m² on day 1, carboplatin 150 mg/m² and pirarubicin 20 mg/m² on days 2 and 3. Vindesine was injected every 7 d.

Tumor response was evaluated by enhanced computed tomography (CT) scan or magnetic resonance imaging after every cycle of NAT according to the revised Response Evaluation Criteria In Solid Tumors (RECIST) version 1.1[8]. Surgical resection was carried out after one or two cycles depending on the patient's response. Postoperative intravenous chemotherapy was given every 3 wk, and the drugs administered were those listed above.

Toxicity evaluation

Toxicity was evaluated after each session of NAT. Cardiac function was monitored by echocardiography and ECG; renal function by serum electrolytes, urea, creatinine, and creatinine clearance; and liver function by aspartate aminotransferase and alanine aminotransferase (ALT). Complete blood cell count was repeated weekly to assess bone marrow suppression.

Follow-up

All patients were followed every 2 mo during the first year after comprehensive treatment, every 3 mo during the second and third years, every 6 mo during the fourth and fifth years and annually after 5 years. Follow-up examinations included physical check-up, imaging (abdominal ultrasound and CT, chest X-ray or CT), and laboratory testing (blood and urine analysis, and liver and renal function tests).

RESULTS

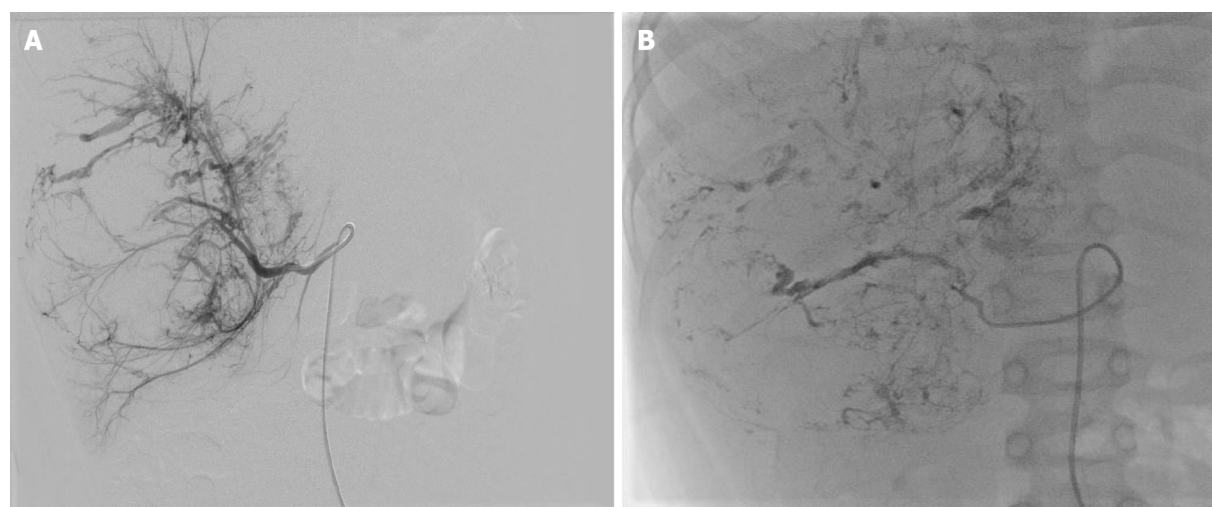
TACE was successfully performed in all patients. The tumor volumes decreased by 18.2%–68.7%, with a mean decrease of 36% after 1 cycle of NAT ($t = 3.524$, $P = 0.017$). According to the RECIST criteria, 4 patients had a partial response (PR) and underwent surgery, while 2 had stable disease (SD) and received another cycle of NAT before surgery. Retroperitoneal lymph node metastasis and pulmonary metastasis observed in one patient, respectively, were slightly reduced after TACE, and no regrow or other lesions appeared before surgery. Total tumor resection was performed in all patients without positive surgical margins and major postoperative complications. Retroperitoneal lymph node dissection was performed in the patient with lymph node metastasis. The patient with lung metastasis was not treated surgically as the lesions were no longer obvious after chemotherapy. Massive tumor necrosis was seen on pathological examination of the surgical specimen: > 90% necrosis in 2, > 50% necrosis in 3, and 25% necrosis in 1, with an average of 71.8%. Six to 10 courses of regular venous chemotherapy were administered after surgery in patients without metastasis, and 12 courses in the 2 patients with metastases.

The toxic side effects included fever (37.8–39.9 °C) in 5 cases, nausea and vomiting in 3, and mild bone marrow suppression in 3, all these symptoms recovered within 1–2 wk following symptomatic

Table 1 Clinicpathological data, treatment, follow-up and outcome of 6 patients with undifferentiated embryonal sarcoma of the liver

No.	Age	Sex	Tumor size on admission (mm)	Symptoms	Metastasis	Treatment	Tumor shrunk after NAT	Response after one cycle of NAT	Outcome (follow-up years)
1	10 years old	F	120	Abdominal mass	None	Neoadjuvant therapy/surgery/chemotherapy	33%	SD	Alive and event-free at 15
2	3 years and 7 months old	M	86	Abdominal pain	Lung metastases	Neoadjuvant therapy/surgery/chemotherapy	68.70%	PR	Alive and event-free at 11
3	7 years old	F	96	Abdominal pain	None	Neoadjuvant therapy/surgery/chemotherapy	31%	PR	Alive and event-free at 10
4	11 years and 8 months old	M	137	Abdominal pain	None	Two cycles of neoadjuvant therapy/surgery/chemotherapy	18.2% after one cycle; 43.2% after two cycles	SD	Alive and event-free at 7
5	6 years and 8 months old	M	136	Abdominal mass	Retroperitoneal lymph node metastasis	Two cycles of neoadjuvant therapy/surgery/chemotherapy	17.6% after one cycle; 47.3% after two cycles	SD	Alive and event-free at 3
6	5 years and 3 months old	M	148	Jaundice	None	Neoadjuvant therapy/surgery/chemotherapy	48.80%	PR	Alive and event-free at 2

PR: Partial response; SD: Stable disease; NAT: Neoadjuvant therapy.



DOI: 10.12998/wjcc.v10.i19.6437 Copyright ©The Author(s) 2022.

Figure 1 Transcatheter arterial chemoembolization procedure of case 6. A: The catheter was introduced into the tumor-feeding artery and performed angiography, showing the stereoscopic configuration of "holding ball"; B: After injection of anticarcinogen and lipiodol, the outline of the entire tumor was revealed.

treatment. All patients showed varying degrees of ALT elevation, which returned to normal within 7–10 d after treatment with hepatoprotective drugs. No cardiac or renal toxicity, bleeding or nontarget embolization occurred.

The follow-up duration ranged from 2 to 15 years (median 8 years), and the follow-up rate was 100%. At the last follow-up on February 1, 2021, all patients were alive and disease-free.

DISCUSSION

Early detection of UESL is difficult, and it is usually found when the tumor becomes larger or metastasizes. It metastasizes in up to 15% of children, usually to the lungs, pleura and peritoneum[9]. Preoperative chemotherapy is currently recommended if a huge unresectable tumor or metastases are present. Although intravenous chemotherapy, as the mainstay of adjuvant treatment for UESL, has improved survival rates, the toxicity induced by systemic chemotherapy may result in early death or potential long-term and late effects[10,11]. In addition, the therapeutic effects in UESL with incomplete resection or distant metastases are still unsatisfactory[12].

TACE was first introduced in the treatment of adult liver tumor in the late 1970s and yielded good results[13]. Since then, reports of TACE in pediatric cases of hepatoblastoma have gradually increased[6, 14,15]. In previous studies at our center, preoperative TACE was effective in the treatment of UESL in two cases[5]. Also, neoadjuvant TACE and systemic chemotherapy have been administered in patients with Wilms tumor and clear cell sarcoma of the kidney and achieved satisfactory results[7,16].

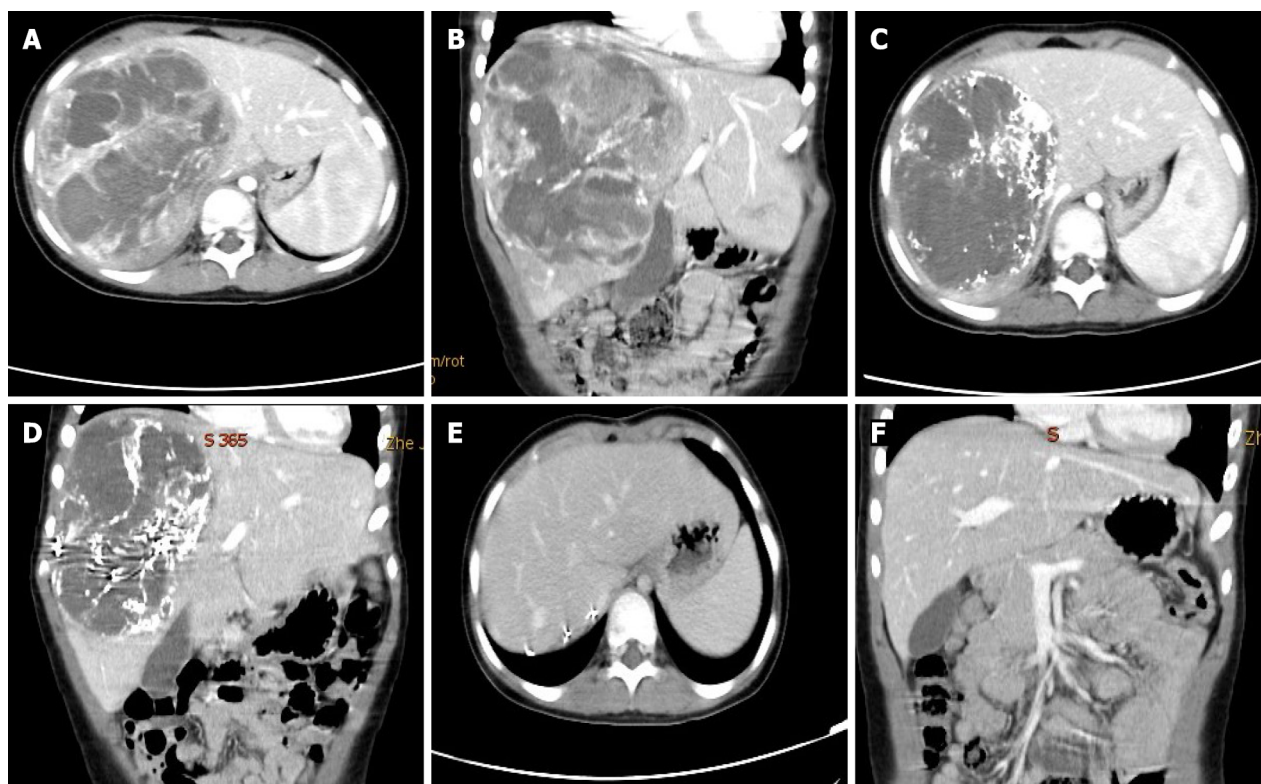
Complete tumor excision plays a central role in the treatment of UESL[4]. TACE can increase the total resection rate in several ways. TACE can deliver a higher concentration of anticancer drugs into the tumor *via* direct perfusion through the tumor-feeding artery, which reduces the dose of drugs and systemic toxicity[5,6,16]. Lipiodol embolization can reduce the blood supply of tumor and accelerate necrosis. High concentrations of chemotherapeutic drugs and internal ischemia cause the tumor to gradually shrink. After TACE, a pseudo-capsule can be seen around the tumor and a boundary exists between the tumor and normal liver tissue during the operation (Figure 2). These are conducive to complete resection, reducing the rate of positive surgical margins, and diminishing intraoperative bleeding (Figure 3). In this study, all the patients achieved total resection without positive surgical margins and severe bleeding.

TACE plays an important role in the primary lesion but has little effect on distal metastasis[15,17]. In this series, two patients had pulmonary and retroperitoneal lymph node metastasis on admission, respectively. Fortunately, after TACE and before systemic chemotherapy, we found that the metastasis was slightly reduced and no other lesions appeared. Following infusion into the hepatic artery, chemotherapy drugs will still flow through the hepatic vein to the heart and the entire body; thus, the extrahepatic lesions can also be suppressed. However, intravenous chemotherapy is still essential, as the dose of chemotherapy drugs flowing into the body following TACE is limited, and do not achieve an effective concentration. Preoperative intravenous chemotherapy can effectively inhibit primary hepatic and extrahepatic lesions, while postoperative intravenous chemotherapy can reduce the risk of recurrence and improve the survival rate[18,19]. Therefore, systemic chemotherapy can complement TACE. In our series, prolonged postoperative chemotherapy was performed in the two patients who are presently recurrence-free. However, the prognosis is poor, even if the patient receives intravenous chemotherapy, when complete excision of the tumor cannot be achieved[4]. The patient with lung metastases who is currently event-free still requires long-term follow-up.

In recent years drug-eluting beads (DEBs) have been introduced as novel drug-delivery agents for TACE, which can deliver higher concentrations of drugs to the tumor and lower systemic concentrations [20]. Studies have shown a lower incidence of systemic toxicity and improved tolerance with DEB-TACE, but overall survival did not differ from conventional lipiodol-TACE[21,22]. DEB-TACE has been widely used for the treatment of hepatocellular carcinoma in adults, but has not been reported in pediatric liver malignancies, and its clinical safety needs to be confirmed by further clinical trials in children. In addition, DEB-TACE reduces systemic complications by lowering extrahepatic drug concentrations, but it also decreases the inhibition of extrahepatic lesions. Therefore, DEB-TACE was not used in this study. In the near future, DEB-TACE is expected to be applied in the treatment of unresectable intrahepatic malignancy in pediatric patients.

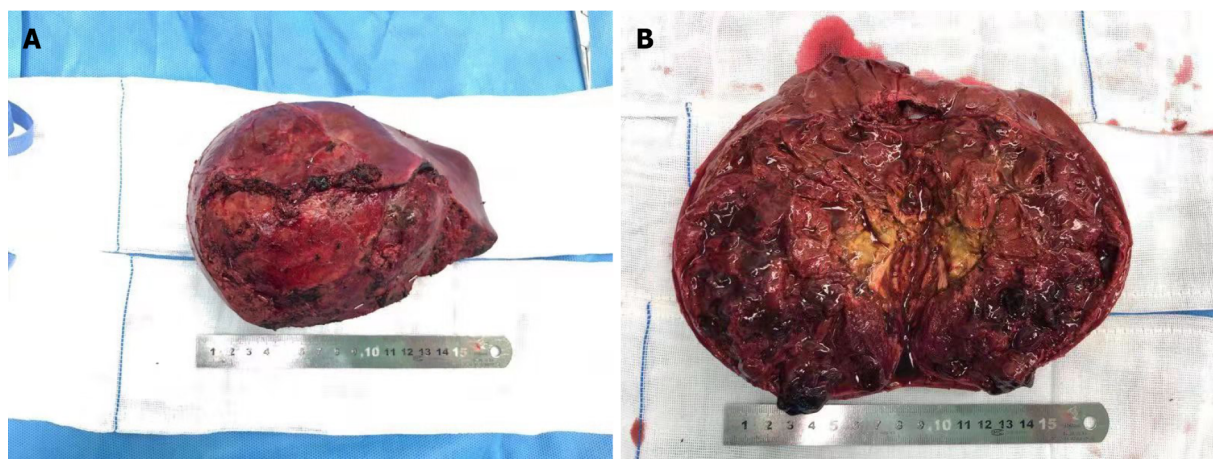
No technical complications including bleeding, vascular injury, or nontarget embolization were noted in this study. Nontarget embolization must be viewed as a critical situation during the TACE procedure, as its appearance may lead to serious consequences[23]. The incidence of nontargeted organ embolization, such as pulmonary embolism, splenic infarction, and gallbladder infarction, was found to be approximately 5%[23,24]. The main risk factors for the development of these complications include: (1) Non-selective placement of the catheter; (2) High doses of cytostatics and iodized oil used in TACE; and (3) Use of small-diameter embolic agents[24]. A case of paraplegia after TACE in a patient with clear cell sarcoma of the kidney was reported in our center, which was caused by injection of chemotherapeutic drugs and lipiodol into the spinal cord through the lumbar artery. Hence, angiography must be performed repeatedly to confirm the location of the catheter during the TACE procedure especially before injection of the embolic agent.

Postembolization syndrome and drug toxicity mainly include fever, abdominal pain, gastrointestinal reaction (nausea and vomiting), myelosuppression and organ damage (cardiotoxicity, renal insufficiency, and hepatic dysfunction)[25]. In our cases, fever was the most common symptom after TACE, possibly due to massive necrosis of the large tumor, which lasted a long time and did not respond to antibiotics. Under such circumstances, short-term small doses of hormones can be used to suppress inflammation and lower prolonged fever. Elevated ALT levels occurred in all of our patients, which returned to normal within 7–10 d after treatment without affecting follow-up treatment. Renal failure,



DOI: 10.12998/wjcc.v10.i19.6437 Copyright ©The Author(s) 2022.

Figure 2 The imaging manifestation of case 6. A and B: Computed tomography scans showed a giant mass of the right liver (diameter 14.8 cm); C and D: One month after neoadjuvant therapy: The tumor volumes shrunk by 48.8%, lipiodol deposits in the tumor with a clear boundary; E and F: One month after tumor resection.



DOI: 10.12998/wjcc.v10.i19.6437 Copyright ©The Author(s) 2022.

Figure 3 These are conducive to complete resection, reducing the rate of positive surgical margins, and diminishing intraoperative bleeding. A: The gross of tumor appears as border clear with about 10 cm in diameter; B: The cut surface is red, brown or yellow and has soft qualitative with focal necrosis.

cardiac damage, and severe myelosuppression did not occur. Hence, NAT may be considered a safe preoperative treatment for UESL.

It is noteworthy that two of our patients underwent 2 cycles of NAT before surgery. They achieved SD (tumor shrinkage was approximately 20%) after one cycle of NAT, and still had large tumors with PRETEXT stage III on radiography[26]. After another cycle of NAT, PRs (tumor shrinkage of approximately 35%) were achieved. Therefore, it is suggested that patients who are insensitive to the initial response should be considered for a second round of NAT, which can yield better results. However, unlimited chemotherapy is not desirable. Generally, surgery should be performed after two cycles of NAT, and liver transplantation should be considered if a limited response occurs in a patient with an

unresectable tumor.

There were some limitations in this study. Firstly, the data were from a single institution and based on a retrospective analysis. In addition, there was no control group due to the small number of cases, and the assessment of disease response cannot definitely be attributed to TACE or systemic chemotherapy. Further prospective and controlled studies with a larger cohort are needed to compare the efficacy of TACE, systemic chemotherapy and NAT for UESL, respectively.

CONCLUSION

The present study indicated that the use of NAT effectively reduced tumor volume, cleared tumor margins, and caused massive tumor necrosis. This chemotherapy regimen may be a promising choice for successful surgery of UESL in children.

ARTICLE HIGHLIGHTS

Research background

Undifferentiated embryonal sarcoma of the liver (UESL) is a rare and aggressive mesenchymal tumor in children. Modern multimodal treatment and supportive therapy have improved survival. Complete tumor excision plays the central role in the treatment of UESL.

Research motivation

The prognosis is poor when complete excision of tumor with UESL cannot be achieved. It is imperative to explore new choices for successful operation of UESL in children.

Research objectives

This report aimed to evaluate the efficacy of neoadjuvant therapy (NAT) for UESL and explore a new choice for successful operation of UESL in children.

Research methods

Six patients who were newly diagnosed and unresectable with UESL received NAT and surgery at our center between January 2004 and December 2019 were retrospectively analyzed. The NAT included preoperative transcatheter arterial chemoembolization (TACE) and systemic chemotherapy. Surgical and survival data would be recorded and analyzed.

Research results

The tumor volumes decreased by 18.2%–68.7%, with a mean value of 36% after 1 cycle of NAT ($t = 3.524$, $P = 0.017$). Massive tumor necrosis was seen in the pathological examination of the specimen: > 90% necrosis in two, > 50% necrosis in three, and 25% necrosis in 1, with an average percentage of 71.8%. Complete tumor resection was successfully performed in all patients. Preoperative NAT may help complete removal of unresectable UESLs. However, there was no control group due to the small number of cases.

Research conclusions

The present study indicated that the use of NAT effectively reduced tumor volume, cleared tumor margin, and caused massive tumor necrosis. It may provide a promising choice for successful operation of UESL in children.

Research perspectives

Further investigations with a larger cohort and prospective study are needed to compare the efficacy of TACE, systemic chemotherapy and NAT for UESL.

FOOTNOTES

Author contributions: All authors contributed equally to this work; Wang JH was the guarantor and designed the study; He M drafted the initial manuscript; Wang JH and Ying MD helped to review the literature; Lai C and Wang JH conducted the TACE process; Mao JQ and Li LJ were the oncologists who treated the patient; Wang JH, He M, Cai JB, Xiong JN, Guan ZH and Shu Q were the surgeons who treated the patient; all authors issued final approval for the version to be submitted.

Supported by Youth Program of Natural Science Foundation of Zhejiang Province, No. LQ20H160027; and National

Natural Science Foundation of China, No. U20A20137.

Institutional review board statement: The study was reviewed and approved by the Children's Hospital, Zhejiang University School of Medicine Institutional Review Board, No. 2021-IRB-252.

Informed consent statement: All study participants, or their legal guardian, provided informed written consent prior to study enrollment.

Conflict-of-interest statement: All the authors report no relevant conflicts of interest for this article.

Data sharing statement: No additional data are available.

Open-Access: This article is an open-access article that was selected by an in-house editor and fully peer-reviewed by external reviewers. It is distributed in accordance with the Creative Commons Attribution NonCommercial (CC BY-NC 4.0) license, which permits others to distribute, remix, adapt, build upon this work non-commercially, and license their derivative works on different terms, provided the original work is properly cited and the use is non-commercial. See: <https://creativecommons.org/licenses/by-nc/4.0/>

Country/Territory of origin: China

ORCID number: Min He 0000-0003-0178-097X; Jia-Bin Cai 0000-0002-2233-0022; Can Lai 0000-0002-4474-3987; Jun-Qing Mao 0000-0002-3162-9106; Jie-Ni Xiong 0000-0003-1603-1728; Zhong-Hai Guan 0000-0002-8397-4585; Lin-Jie Li 0000-0001-7311-7283; Qiang Shu 0000-0002-4106-6255; Mei-Dan Ying 0000-0003-0039-9683; Jin-Hu Wang 0000-0002-7749-2475.

S-Editor: Fan JR

L-Editor: A

P-Editor: Fan JR

REFERENCES

- 1 **Plant AS**, Busuttill RW, Rana A, Nelson SD, Auerbach M, Federman NC. A single-institution retrospective cases series of childhood undifferentiated embryonal liver sarcoma (UELS): success of combined therapy and the use of orthotopic liver transplant. *J Pediatr Hematol Oncol* 2013; **35**: 451-455 [PMID: 23138115 DOI: 10.1097/MPH.0b013e318271c948]
- 2 **Stocker JT**, Ishak KG. Undifferentiated (embryonal) sarcoma of the liver: report of 31 cases. *Cancer* 1978; **42**: 336-348 [PMID: 208754 DOI: 10.1002/1097-0142(197807)42:1<336::aid-cnrcr2820420151>3.0.co;2-v]
- 3 **Bisogno G**, Pilz T, Perilongo G, Ferrari A, Harms D, Ninfo V, Treuner J, Carli M. Undifferentiated sarcoma of the liver in childhood: a curable disease. *Cancer* 2002; **94**: 252-257 [PMID: 11815984 DOI: 10.1002/cncr.10191]
- 4 **Murawski M**, Scheer M, Leuschner I, Stefanowicz J, Bonar J, Dembowska-Bagińska B, Kaliciński P, Koscielniak E, Czauderna P, Fuchs J. Undifferentiated sarcoma of the liver: Multicenter international experience of the Cooperative Soft-Tissue Sarcoma Group and Polish Paediatric Solid Tumor Group. *Pediatr Blood Cancer* 2020; **67**: e28598 [PMID: 32706511 DOI: 10.1002/pbc.28598]
- 5 **Zhao X**, Xiong Q, Wang J, Li MJ, Qin Q, Huang S, Gu W, Shu Q, Tou J. Preoperative Interventional Therapy for Childhood Undifferentiated Embryonal Liver Sarcoma: Two Retrospective Cases from a Single Center. *European J Pediatr Surg Rep* 2015; **3**: 90-93 [PMID: 26788456 DOI: 10.1055/s-0035-1566219]
- 6 **Zhang J**, Xu F, Chen K, Zhou S, Li H, Niu C, Tan X. An effective approach for treating unresectable hepatoblastoma in infants and children: Pre-operative transcatheter arterial chemoembolization. *Oncol Lett* 2013; **6**: 850-854 [PMID: 24137424 DOI: 10.3892/ol.2013.1444]
- 7 **Li MJ**, Zhou YB, Huang Y, Tang DX, Xu S, Wu DH, Zhang YY, Tang HF. A retrospective study of the preoperative treatment of advanced Wilms tumor in children with chemotherapy vs transcatheter arterial chemoembolization alone or combined with short-term systemic chemotherapy. *J Vasc Interv Radiol* 2011; **22**: 279-286 [PMID: 21353980 DOI: 10.1016/j.jvir.2010.11.025]
- 8 **Eisenhauer EA**, Therasse P, Bogaerts J, Schwartz LH, Sargent D, Ford R, Dancey J, Arbuck S, Gwyther S, Mooney M, Rubinstein L, Shankar L, Dodd L, Kaplan R, Lacombe D, Verweij J. New response evaluation criteria in solid tumours: revised RECIST guideline (version 1.1). *Eur J Cancer* 2009; **45**: 228-247 [PMID: 19097774 DOI: 10.1016/j.ejca.2008.10.026]
- 9 **Shi Y**, Rojas Y, Zhang W, Beierle EA, Doski JJ, Goldfarb M, Goldin AB, Gow KW, Langer M, Meyers RL, Nuchtern JG, Vasudevan SA. Characteristics and outcomes in children with undifferentiated embryonal sarcoma of the liver: A report from the National Cancer Database. *Pediatr Blood Cancer* 2017; **64** [PMID: 27781381 DOI: 10.1002/pbc.26272]
- 10 **Tao JJ**, Visvanathan K, Wolff AC. Long term side effects of adjuvant chemotherapy in patients with early breast cancer. *Breast* 2015; **24** Suppl 2: S149-S153 [PMID: 26299406 DOI: 10.1016/j.breast.2015.07.035]
- 11 **Israels T**, Chagaluka G, Pidini D, Caron H, de Kraker J, Kamiza S, Borgstein E, Molyneux L. The efficacy and toxicity of SIOP preoperative chemotherapy in Malawian children with a Wilms tumour. *Pediatr Blood Cancer* 2012; **59**: 636-641 [PMID: 22271712 DOI: 10.1002/pbc.24088]
- 12 **Zhang C**, Jia CJ, Xu C, Sheng QJ, Dou XG, Ding Y. Undifferentiated embryonal sarcoma of the liver: Clinical characteristics and outcomes. *World J Clin Cases* 2020; **8**: 4763-4772 [PMID: 33195644 DOI: 10.12998/wjcc.v8.i20.4763]
- 13 **Wheeler PG**, Melia W, Dubbins P, Jones B, Nunnerley H, Johnson P, Williams R. Non-operative arterial embolisation in

- primary liver tumours. *Br Med J* 1979; **2**: 242-244 [PMID: 89883 DOI: 10.1136/bmj.2.6184.242]
- 14 **Oue T**, Fukuzawa M, Kusafuka T, Kohmoto Y, Okada A, Imura K. Transcatheter arterial chemoembolization in the treatment of hepatoblastoma. *J Pediatr Surg* 1998; **33**: 1771-1775 [PMID: 9869048 DOI: 10.1016/s0022-3468(98)90282-2]
 - 15 **Tan X**, Zhang J, Wen Z, Zou Y, Shen G, Zhou S, Li H, Jiang H. Preoperative transcatheter arterial chemoembolization of hepatoblastoma in infants. *J Vasc Interv Radiol* 2014; **25**: 1029-1035 [PMID: 24840125 DOI: 10.1016/j.jvir.2014.03.032]
 - 16 **Wang JH**, Li MJ, Tang DX, Xu S, Mao JQ, Cai JB, He M, Shu Q, Lai C. Neoadjuvant transcatheter arterial chemoembolization and systemic chemotherapy for treatment of clear cell sarcoma of the kidney in children. *J Pediatr Surg* 2019; **54**: 550-556 [PMID: 30318310 DOI: 10.1016/j.jpedsurg.2018.09.012]
 - 17 **Li JP**, Chu JP, Yang JY, Chen W, Wang Y, Huang YH. Preoperative transcatheter selective arterial chemoembolization in treatment of unresectable hepatoblastoma in infants and children. *Cardiovasc Intervent Radiol* 2008; **31**: 1117-1123 [PMID: 18560935 DOI: 10.1007/s00270-008-9373-x]
 - 18 **Wu Z**, Wei Y, Cai Z, Zhou Y. Long-term survival outcomes of undifferentiated embryonal sarcoma of the liver: a pooled analysis of 308 patients. *ANZ J Surg* 2020; **90**: 1615-1620 [PMID: 31957153 DOI: 10.1111/ans.15684]
 - 19 **Putra J**, Ornvold K. Undifferentiated embryonal sarcoma of the liver: a concise review. *Arch Pathol Lab Med* 2015; **139**: 269-273 [PMID: 25611111 DOI: 10.5858/arpa.2013-0463-RS]
 - 20 **Song JE**, Kim DY. Conventional vs drug-eluting beads transarterial chemoembolization for hepatocellular carcinoma. *World J Hepatol* 2017; **9**: 808-814 [PMID: 28706579 DOI: 10.4254/wjh.v9.i18.808]
 - 21 **Bzeizi KI**, Arabi M, Jamshidi N, Albenmoussa A, Sanai FM, Al-Hamoudi W, Alghamdi S, Broering D, Alqahtani SA. Conventional Transarterial Chemoembolization Versus Drug-Eluting Beads in Patients with Hepatocellular Carcinoma: A Systematic Review and Meta-Analysis. *Cancers (Basel)* 2021; **13** [PMID: 34944792 DOI: 10.3390/cancers13246172]
 - 22 **Karalli A**, Teiler J, Haji M, Seth E, Brismar TB, Wahlin S, Axelsson R, Stål P. Comparison of lipiodol infusion and drug-eluting beads transarterial chemoembolization of hepatocellular carcinoma in a real-life setting. *Scand J Gastroenterol* 2019; **54**: 905-912 [PMID: 31287338 DOI: 10.1080/00365521.2019.1632925]
 - 23 **Nakada S**, Allard MA, Lewin M, Awad S, Dahbi N, Nitta H, Cunha AS, Castaing D, Vibert E, Cherqui D, Miyazaki M, Ohtsuka M, Adam R. Ischemic Cholangiopathy Following Transcatheter Arterial Chemoembolization for Recurrent Hepatocellular Carcinoma After Hepatectomy: an Underestimated and Devastating Complication. *J Gastrointest Surg* 2020; **24**: 2517-2525 [PMID: 31754989 DOI: 10.1007/s11605-019-04409-4]
 - 24 **Tarazov PG**, Polysalov VN, Prozorovskij KV, Grishchenkova IV, Rozengauz EV. Ischemic complications of transcatheter arterial chemoembolization in liver malignancies. *Acta Radiol* 2000; **41**: 156-160 [PMID: 10741789 DOI: 10.1080/028418500127344966]
 - 25 **Wagnetz U**, Jaskolka J, Yang P, Jhaveri KS. Acute ischemic cholecystitis after transarterial chemoembolization of hepatocellular carcinoma: incidence and clinical outcome. *J Comput Assist Tomogr* 2010; **34**: 348-353 [PMID: 20498534 DOI: 10.1097/RCT.0b013e3181caaea3]
 - 26 **Towbin AJ**, Meyers RL, Woodley H, Miyazaki O, Weldon CB, Morland B, Hiyama E, Czauderna P, Roebuck DJ, Tiao GM. 2017 PRETEXT: radiologic staging system for primary hepatic malignancies of childhood revised for the Paediatric Hepatic International Tumour Trial (PHITT). *Pediatr Radiol* 2018; **48**: 536-554 [PMID: 29427028 DOI: 10.1007/s00247-018-4078-z]



Published by **Baishideng Publishing Group Inc**
7041 Koll Center Parkway, Suite 160, Pleasanton, CA 94566, USA

Telephone: +1-925-3991568

E-mail: bpgoffice@wjgnet.com

Help Desk: <https://www.f6publishing.com/helpdesk>

<https://www.wjgnet.com>

