

# World Journal of *Clinical Cases*

*World J Clin Cases* 2022 June 16; 10(17): 5518-5933



### MINIREVIEWS

- 5518** Occult hepatitis B — the result of the host immune response interaction with different genomic expressions of the virus  
*Gherlan GS*
- 5531** Pulmonary complications of portal hypertension: The overlooked decompensation  
*Craciun R, Mocan T, Procopet B, Nemes A, Tefas C, Sparchez M, Mocan LP, Sparchez Z*
- 5541** Ethical review of off-label drugs during the COVID-19 pandemic  
*Li QY, Lv Y, An ZY, Dai NN, Hong X, Zhang Y, Liang LJ*

### ORIGINAL ARTICLE

#### Case Control Study

- 5551** Gut peptide changes in patients with obstructive jaundice undergoing biliary drainage: A prospective case control study  
*Pavić T, Pelajić S, Blažević N, Kralj D, Milošević M, Mikolasevic I, Lerotic I, Hrabar D*

#### Retrospective Cohort Study

- 5566** Longitudinal assessment of liver stiffness by transient elastography for chronic hepatitis C patients  
*Mezina A, Krishnan A, Woreta TA, Rubenstein KB, Watson E, Chen PH, Rodriguez-Watson C*

#### Retrospective Study

- 5577** Clinical evaluation of prone position ventilation in the treatment of acute respiratory distress syndrome induced by sepsis  
*Xia WH, Yang CL, Chen Z, Ouyang CH, Ouyang GQ, Li QG*
- 5586** Three-dimensional arterial spin labeling and diffusion kurtosis imaging in evaluating perfusion and infarct area size in acute cerebral ischemia  
*Jiang YY, Zhong ZL, Zuo M*
- 5595** Intrathecal methotrexate in combination with systemic chemotherapy in glioblastoma patients with leptomeningeal dissemination: A retrospective analysis  
*Kang X, Chen F, Yang SB, Wang YL, Qian ZH, Li Y, Lin H, Li P, Peng YC, Wang XM, Li WB*
- 5606** Hepatic epithelioid hemangioendothelioma: Clinical characteristics, diagnosis, treatment, and prognosis  
*Zhao M, Yin F*
- 5620** Difference between type 2 gastroesophageal varices and isolated fundic varices in clinical profiles and portosystemic collaterals  
*Song YH, Xiang HY, Si KK, Wang ZH, Zhang Y, Liu C, Xu KS, Li X*

- 5634** Assessment of incidental focal colorectal uptake by analysis of fluorine-18 fluorodeoxyglucose positron emission tomography parameters

*Lee H, Hwang KH, Kwon KA*

### Observational Study

- 5646** "Zero ischemia" laparoscopic partial nephrectomy by high-power GreenLight laser enucleation for renal carcinoma: A single-center experience

*Zhang XM, Xu JD, Lv JM, Pan XW, Cao JW, Chu J, Cui XG*

- 5655** High Eckardt score and previous treatment were associated with poor postperoral endoscopic myotomy pain control: A retrospective study

*Chen WN, Xu YL, Zhang XG*

- 5667** Higher volume growth rate is associated with development of worrisome features in patients with branch duct-intraductal papillary mucinous neoplasms

*Innocenti T, Danti G, Lynch EN, Dragoni G, Gottin M, Fedeli F, Palatresi D, Biagini MR, Milani S, Miele V, Galli A*

### Prospective Study

- 5680** Application of a new anatomic hook-rod-pedicle screw system in young patients with lumbar spondylolysis: A pilot study

*Li DM, Li YC, Jiang W, Peng BG*

### META-ANALYSIS

- 5690** Systematic review of Yougui pills combined with levothyroxine sodium in the treatment of hypothyroidism

*Liu XP, Zhou YN, Tan CE*

### CASE REPORT

- 5702** Allogeneic stem cell transplantation-A curative treatment for paroxysmal nocturnal hemoglobinuria with PIGT mutation: A case report

*Schenone L, Notarantonio AB, Latger-Cannard V, Fremeaux-Bacchi V, De Carvalho-Bittencourt M, Rubio MT, Muller M, D'Aveni M*

- 5708** Gray zone lymphoma effectively treated with cyclophosphamide, doxorubicin, vincristine, prednisolone, and rituximab chemotherapy: A case report

*Hojo N, Nagasaki M, Mihara Y*

- 5717** Diagnosis of spontaneous isolated superior mesenteric artery dissection with ultrasound: A case report

*Zhang Y, Zhou JY, Liu J, Bai C*

- 5723** Adrenocorticotrophic hormone-secreting pancreatic neuroendocrine carcinoma with multiple organ infections and widespread thrombosis: A case report

*Yoshihara A, Nishihama K, Inoue C, Okano Y, Eguchi K, Tanaka S, Maki K, Fridman D'Alessandro V, Takeshita A, Yasuma T, Uemura M, Suzuki T, Gabazza EC, Yano Y*

- 5732** Management of the palato-radicular groove with a periodontal regenerative procedure and prosthodontic treatment: A case report

*Ling DH, Shi WP, Wang YH, Lai DP, Zhang YZ*

- 5741** Combined thoracic paravertebral block and interscalene brachial plexus block for modified radical mastectomy: A case report  
*Hu ZT, Sun G, Wang ST, Li K*
- 5748** Chondromyxoid fibroma of the cervical spine: A case report  
*Li C, Li S, Hu W*
- 5756** Preterm neonate with a large congenital hemangioma on maxillofacial site causing thrombocytopenia and heart failure: A case report  
*Ren N, Jin CS, Zhao XQ, Gao WH, Gao YX, Wang Y, Zhang YF*
- 5764** Simultaneous multiple primary malignancies diagnosed by endoscopic ultrasound-guided fine-needle aspiration: A case report  
*Yang J, Zeng Y, Zhang JW*
- 5770** Neuroendocrine tumour of the descending part of the duodenum complicated with schwannoma: A case report  
*Zhang L, Zhang C, Feng SY, Ma PP, Zhang S, Wang QQ*
- 5776** Massive hemothorax following internal jugular vein catheterization under ultrasound guidance: A case report  
*Kang H, Cho SY, Suk EH, Ju W, Choi JY*
- 5783** Unilateral adrenal tuberculosis whose computed tomography imaging characteristics mimic a malignant tumor: A case report  
*Liu H, Tang TJ, An ZM, Yu YR*
- 5789** Modified membrane fixation technique in a severe continuous horizontal bone defect: A case report  
*Wang LH, Ruan Y, Zhao WY, Chen JP, Yang F*
- 5798** Surgical repair of an emergent giant hepatic aneurysm with an abdominal aortic dissection: A case report  
*Wen X, Yao ZY, Zhang Q, Wei W, Chen XY, Huang B*
- 5805** Heterotopic ossification beneath the upper abdominal incision after radical gastrectomy: Two case reports  
*Zhang X, Xia PT, Ma YC, Dai Y, Wang YL*
- 5810** Non-alcoholic Wernicke encephalopathy in an esophageal cancer patient receiving radiotherapy: A case report  
*Zhang Y, Wang L, Jiang J, Chen WY*
- 5816** New approach for the treatment of vertical root fracture of teeth: A case report and review of literature  
*Zhong X, Yan P, Fan W*
- 5825** Ultrasound-guided microwave ablation as a palliative treatment for mycosis fungoides eyelid involvement: A case report  
*Chen YW, Yang HZ, Zhao SS, Zhang Z, Chen ZM, Feng HH, An MH, Wang KK, Duan R, Chen BD*
- 5833** Pulp revascularization on an adult mandibular right second premolar: A case report  
*Yang YQ, Wu BL, Zeng JK, Jiang C, Chen M*

- 5841** Barrett's esophagus in a patient with bulimia nervosa: A case report  
*Gouda A, El-Kassas M*
- 5846** Spontaneous gallbladder perforation and colon fistula in hypertriglyceridemia-related severe acute pancreatitis: A case report  
*Wang QP, Chen YJ, Sun MX, Dai JY, Cao J, Xu Q, Zhang GN, Zhang SY*
- 5854** Beware of gastric tube in esophagectomy after gastric radiotherapy: A case report  
*Yurttas C, Wichmann D, Gani C, Bongers MN, Singer S, Thiel C, Koenigsrainer A, Thiel K*
- 5861** Transition from minimal change disease to focal segmental glomerulosclerosis related to occupational exposure: A case report  
*Tang L, Cai Z, Wang SX, Zhao WJ*
- 5869** Lung adenocarcinoma metastasis to paranasal sinus: A case report  
*Li WJ, Xue HX, You JQ, Chao CJ*
- 5877** Follicular lymphoma presenting like marginal zone lymphoma: A case report  
*Peng HY, Xiu YJ, Chen WH, Gu QL, Du X*
- 5884** Primary renal small cell carcinoma: A case report  
*Xie K, Li XY, Liao BJ, Wu SC, Chen WM*
- 5893** Gitelman syndrome: A case report  
*Chen SY, Jie N*
- 5899** High-frame-rate contrast-enhanced ultrasound findings of liver metastasis of duodenal gastrointestinal stromal tumor: A case report and literature review  
*Chen JH, Huang Y*
- 5910** Tumor-like disorder of the brachial plexus region in a patient with hemophilia: A case report  
*Guo EQ, Yang XD, Lu HR*
- 5916** Response to dacomitinib in advanced non-small-cell lung cancer harboring the rare delE709\_T710insD mutation: A case report  
*Xu F, Xia ML, Pan HY, Pan JW, Shen YH*
- 5923** Loss of human epidermal receptor-2 in human epidermal receptor-2+ breast cancer after neoadjuvant treatment: A case report  
*Yu J, Li NL*

**LETTER TO THE EDITOR**

- 5929** Repetitive transcranial magnetic stimulation for post-traumatic stress disorder: Lights and shadows  
*Concerto C, Lanza G, Fisticaro F, Pennisi M, Rodolico A, Torrisi G, Bella R, Aguglia E*

**ABOUT COVER**

Editorial Board Member of *World Journal of Clinical Cases*, Raden Andri Primadhi, MD, PhD, Assistant Professor, Surgeon, Department of Orthopaedics and Traumatology, Universitas Padjadjaran Medical School, Hasan Sadikin Hospital, Bandung 40161, Indonesia. randri@unpad.ac.id

**AIMS AND SCOPE**

The primary aim of *World Journal of Clinical Cases* (WJCC, *World J Clin Cases*) is to provide scholars and readers from various fields of clinical medicine with a platform to publish high-quality clinical research articles and communicate their research findings online.

WJCC mainly publishes articles reporting research results and findings obtained in the field of clinical medicine and covering a wide range of topics, including case control studies, retrospective cohort studies, retrospective studies, clinical trials studies, observational studies, prospective studies, randomized controlled trials, randomized clinical trials, systematic reviews, meta-analysis, and case reports.

**INDEXING/ABSTRACTING**

The WJCC is now indexed in Science Citation Index Expanded (also known as SciSearch®), Journal Citation Reports/Science Edition, Scopus, PubMed, and PubMed Central. The 2021 Edition of Journal Citation Reports® cites the 2020 impact factor (IF) for WJCC as 1.337; IF without journal self cites: 1.301; 5-year IF: 1.742; Journal Citation Indicator: 0.33; Ranking: 119 among 169 journals in medicine, general and internal; and Quartile category: Q3. The WJCC's CiteScore for 2020 is 0.8 and Scopus CiteScore rank 2020: General Medicine is 493/793.

**RESPONSIBLE EDITORS FOR THIS ISSUE**

Production Editor: Hua-Ge Yin, Production Department Director: Xiang Li, Editorial Office Director: Jin-Lai Wang.

**NAME OF JOURNAL**

*World Journal of Clinical Cases*

**ISSN**

ISSN 2307-8960 (online)

**LAUNCH DATE**

April 16, 2013

**FREQUENCY**

Thrice Monthly

**EDITORS-IN-CHIEF**

Bao-Gan Peng, Jerzy Tadeusz Chudek, George Kontogeorgos, Maurizio Serati, Ja Hyeon Ku

**EDITORIAL BOARD MEMBERS**

<https://www.wjnet.com/2307-8960/editorialboard.htm>

**PUBLICATION DATE**

June 16, 2022

**COPYRIGHT**

© 2022 Baishideng Publishing Group Inc

**INSTRUCTIONS TO AUTHORS**

<https://www.wjnet.com/bpg/gerinfo/204>

**GUIDELINES FOR ETHICS DOCUMENTS**

<https://www.wjnet.com/bpg/GerInfo/287>

**GUIDELINES FOR NON-NATIVE SPEAKERS OF ENGLISH**

<https://www.wjnet.com/bpg/gerinfo/240>

**PUBLICATION ETHICS**

<https://www.wjnet.com/bpg/GerInfo/288>

**PUBLICATION MISCONDUCT**

<https://www.wjnet.com/bpg/gerinfo/208>

**ARTICLE PROCESSING CHARGE**

<https://www.wjnet.com/bpg/gerinfo/242>

**STEPS FOR SUBMITTING MANUSCRIPTS**

<https://www.wjnet.com/bpg/GerInfo/239>

**ONLINE SUBMISSION**

<https://www.f6publishing.com>

# Combined thoracic paravertebral block and interscalene brachial plexus block for modified radical mastectomy: A case report

Zhou-Ting Hu, Guang Sun, Shen-Tong Wang, Kai Li

**Specialty type:** Anesthesiology

**Provenance and peer review:**

Unsolicited article; Externally peer reviewed.

**Peer-review model:** Single blind

**Peer-review report's scientific quality classification**

Grade A (Excellent): 0

Grade B (Very good): 0

Grade C (Good): C

Grade D (Fair): D

Grade E (Poor): 0

**P-Reviewer:** Amornytin S, Thailand; Spataru A, Canada

**Received:** October 28, 2021

**Peer-review started:** October 28, 2021

**First decision:** December 27, 2021

**Revised:** January 14, 2022

**Accepted:** April 4, 2022

**Article in press:** April 4, 2022

**Published online:** June 16, 2022



**Zhou-Ting Hu, Shen-Tong Wang, Kai Li,** Department of Anesthesia, China-Japan Union Hospital of Jilin University, Changchun 130033, Jilin Province, China

**Guang Sun,** Department of Breast Surgery, China-Japan Union Hospital of Jilin University, Changchun 130033, Jilin Province, China

**Corresponding author:** Kai Li, MD, Assistant Professor, Doctor, Department of Anesthesia, China-Japan Union Hospital of Jilin University, No. 126 Xiantai Avenue, Changchun 130033, Jilin Province, China. [likai@jlu.edu.cn](mailto:likai@jlu.edu.cn)

## Abstract

### BACKGROUND

Modified radical mastectomy (MRM) is the most common surgical treatment for breast cancer. General anesthesia poses a challenge in fragile MRM patients, including cardiovascular instability, insufficient postoperative pain control, nausea and vomiting. Thoracic paravertebral block (TPVB) is adequate for simple mastectomy, but its combination with interscalene brachial plexus block (IBPB) has not yet been proved to be an effective anesthesia method for MRM.

### CASE SUMMARY

We describe our experience of anesthesia and pain management in 10 patients with multiple comorbidities. An ultrasound-guided TPVB was placed at T2-T3 and T5-T6, and combined with IBPB, with administration of 10, 15 and 5 mL of 0.5% ropivacaine, respectively. A satisfactory anesthetic effect was proved by the absence of ipsilateral tactile sensation within 30 min. Propofol 3 mg/kg/h and oxygen supplementation *via* a nasal cannula were administered during surgery. None of the patients required additional narcotics, vasopressors, or conversion to general anesthesia. The maximum pain score was 2 on an 11-point numerical rating scale. Two patients required one dose of celecoxib 8 h postoperatively and none reported nausea or emesis.

### CONCLUSION

This case series demonstrated that combined two-site TPVB and small-volume IBPB with sedation can be used as an alternative anesthetic modality for MRM, providing good postoperative analgesia.

**Key Words:** Modified radical mastectomy; Paravertebral block; Brachial plexus block; Sedation; Case report



**Core Tip:** Thoracic paravertebral block (TPVB) has been proved to be adequate for simple mastectomy. However, TPVB combined with interscalene brachial plexus block (IBPB) has not yet been proved to be an effective anesthesia method for modified radical mastectomy (MRM). This case series demonstrated that combined two-site TPVB and small-volume IBPB with sedation can be used as an alternative anesthetic modality for MRM, which avoids the potential risks of general anesthesia and phrenic nerve paralysis especially in frail patients with multiple comorbidities, and provides extended postoperative analgesia.

**Citation:** Hu ZT, Sun G, Wang ST, Li K. Combined thoracic paravertebral block and interscalene brachial plexus block for modified radical mastectomy: A case report. *World J Clin Cases* 2022; 10(17): 5741-5747

**URL:** <https://www.wjgnet.com/2307-8960/full/v10/i17/5741.htm>

**DOI:** <https://dx.doi.org/10.12998/wjcc.v10.i17.5741>

## INTRODUCTION

The National Breast Cancer Foundation has confirmed that breast cancer is the second most common cancer in women, with 3.8 million women diagnosed in the United States as of January 1, 2019[1]. Modified radical mastectomy (MRM) is the most common surgical treatment for breast cancer[2]. Modified radical mastectomy is frequently performed under general anesthesia. However, general anesthesia may pose challenges especially in elderly and frail patients with comorbidities. Furthermore, some components of general anesthesia are associated with chronic pain, vomiting and impaired respiratory function[3,4]. On the other hand, regional anesthesia is commonly believed to decrease cardiovascular, respiratory and gastrointestinal adverse events in high-risk patients[5,6], and attenuate immune suppression[7]. Accordingly, there is growing interest in loco-regional anesthesia as an alternative to general anesthesia for MRM.

Thoracic epidural anesthesia combined with interscalene brachial plexus block (IBPB) has been reported to be an adequate anesthesia technique for MRM[8]. Thoracic paravertebral block (TPVB) is efficacious for simple mastectomy surgery[9], but the efficacy of TPVB combined with IBPB has not yet been studied for MRM.

In this case series, we describe our experience of intraoperative anesthesia and postoperative pain management in ten elderly and fragile MRM patients who underwent ultrasound-guided two-site TPVB and small-volume IBPB combined with sedation.

## CASE PRESENTATION

### Chief complaints

Ten patients scheduled for elective MRM were anesthetized by the same expert in ultrasound-guided loco-regional anesthesia in our facility between January 2019 and March 2019.

### History of present illness

All patients were identified as suitable candidates for loco-regional anesthesia using current anticoagulation recommendations.

### History of past illness

Patient characteristics are shown in Table 1.

### Imaging examinations

All of the ten cases were diagnosed as breast neoplasm by preoperative imaging examinations either by ultrasound or computerized tomography, suspected to be malignant.

## FINAL DIAGNOSIS

All patients were identified as suitable candidates for loco-regional anesthesia using current anticoagulation recommendations.



Table 1 Patients' characteristics

| Case       | Sex    | Age | BMI, kg/m <sup>2</sup> | Comorbidities | Surgical procedure | Oncology state |
|------------|--------|-----|------------------------|---------------|--------------------|----------------|
| Patient 1  | Female | 65  | 21.1                   | HT, COPD      | M + LND            | T1N1M0         |
| Patient 2  | Female | 72  | 21.4                   | HT            | M + SNB            | T2N1M0         |
| Patient 3  | Female | 65  | 24.4                   | HT, COPD      | M + LND            | T2N3M0         |
| Patient 4  | Female | 78  | 24.2                   | DM, AS        | M                  | -              |
| Patient 5  | Female | 73  | 20.2                   | HT, DM, CI    | M + LND            | T2N1M0         |
| Patient 6  | Female | 73  | 30.4                   | HT, DM, MI    | M                  | -              |
| Patient 7  | Female | 65  | 24.2                   | HT, AS, MI    | M                  | -              |
| Patient 8  | Female | 68  | 21.9                   | HT, MI        | M + SNB            | T1N0M0         |
| Patient 9  | Female | 65  | 33.6                   | HT, DM        | M + SNB            | T2N0M0         |
| Patient 10 | Female | 79  | 24.5                   | DM, MI, CI    | M + SNB            | T1N1M0         |

AS: Arteriosclerosis; CI: Cerebral infarction; COPD: Chronic obstructive pulmonary disease; DM: Diabetes mellitus; HT: Hypertension; MI: Myocardial infarction; M: Mastectomy; SNB: Sentinel lymph node biopsy; LND: Lymph node dissection.

## TREATMENT

On arrival in the preoperative area, standard monitoring was conducted and the patients were placed in the lateral decubitus position and received intravenous sedation with midazolam. TPVB was then initiated. A 10 MHz linear array transducer was vertically placed in the sagittal, paramedian plane, approximately 2-2.5 cm lateral to the spinous process at the predetermined level, and the following structures were identified: transverse process, parietal pleura, superior costotransverse ligament and the desired paravertebral space. Following infiltration of the skin with 2% lidocaine, a 22-G × 50-mm needle was advanced using the out-of-plane technique. Eventually, a “pop” was felt as the needle tip penetrated the anterior border of the superior costotransverse ligament. Hydro dissection with normal saline was used to confirm correct placement of the needle tip by anterior displacement of the parietal pleura (Figure 1). Ten and 15 mL of 0.5% ropivacaine were injected at two thoracic (T) levels: T2-T3 and T5-T6, respectively[10,11]. TPVB was supplemented with ipsilateral IBPB using the in-plane technique at C6 Level with an injection of 5 mL ropivacaine (0.5%). Sensory blockade was assessed by pin prick testing using a 22-G short bevel needle. A satisfactory anesthetic effect was defined as the absence of ipsilateral tactile sensation covering the region between the clavicle and T7 dermatome, and from the ipsilateral parasternal area to the axilla within 30 min after local anesthetic administration. The time required to perform the blocks ranged from 5 to 10 min.

Patients were sedated with a continuous infusion of propofol 3 mg/kg/h, and oxygen supplementation *via* a nasal cannula during surgery. A bolus of 1 µg/kg fentanyl was available for intraoperative breakthrough pain. Conversion to general anesthesia was considered if required. The patients were offered 200 mg celecoxib orally as needed for moderate postoperative pain, and an intravenous bolus of 3 mg morphine for severe pain.

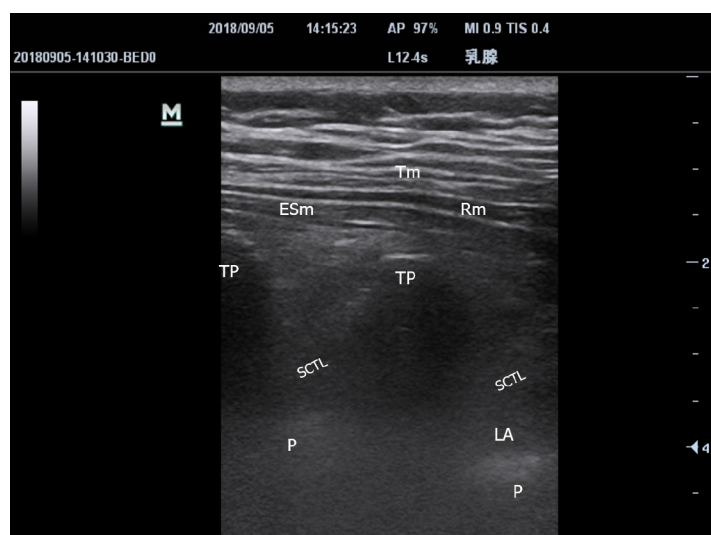
## OUTCOME AND FOLLOW-UP

The average duration of surgery was 115 (± 21.7) min. None of the patients required intraoperative narcotics, or conversion to general anesthesia. The patients were hemodynamically stable and did not require vasopressors. No complications due to local anesthesia, such as allergic reaction, paresthesia, vascular injury and toxicity were observed. All patients were transferred to a regular nursing ward shortly after surgery.

Postoperative pain was well controlled. Eight patients reported a maximum pain score of 2 out of 10 points and did not require additional analgesics during a 12-h-interval follow-up in the first three postoperative days. Two patients needed one dose of celecoxib 8 h after surgery. None of the patients required morphine. All patients were satisfied with their anesthesia and pain management. All patients resumed normal food intake within 4 h and were able to use the surgical-side hand within 24 h. The recovery period was uneventful, with no reports of postoperative nausea and vomiting (PONV). Timeline of all cases are shown in Table 2.

**Table 2 Timeline of the case series**

|               |   |
|---------------|---|
| Case series   | Ten elderly and fragile patients with multiple comorbidities scheduled for modified radical mastectomy  |
| Interventions | Standard monitoring and sedation with midazolam in lateral decubitus position before regional anesthesia. 10 and 15 mL of 0.5% ropivacaine injected at T2-T3 and T5-T6 as thoracic paravertebral block by ultrasound-guided using the out-of-plane technique. 5 mL of 0.5% ropivacaine injected as interscalene brachial plexus block using the in-plane technique        |
| Results       | Sensory blockade assessed by pin prick testing, covering the region between the clavicle and T7 dermatome, and from the ipsilateral parasternal area to the axilla. Only sedated with propofol and oxygen supplementation <i>via</i> a nasal cannula during surgery. Vasopressors, narcotics or general anesthesia was not applied but considered if required for surgery |
| Follow-up     | Postoperative pain was well controlled as a 2 out of 10 points pain score without celecoxib or morphine. Normal food intake was resumed within 4 h and surgical-side hand were able to use within 24 h. Recovery period was uneventful, without complications or postoperative nausea and vomiting  |



DOI: 10.12998/wjcc.v10.i17.5741 Copyright ©The Author(s) 2022.

**Figure 1** Ultrasound image of the paravertebral block. Tm: Trapezius muscle; Rm: Rhomboid muscle; ESm: Erector spinal muscle; TP: Transverse process; SCTL: Superior costotransverse ligament; LA: Local anesthesia agency; P: Pleura.

## DISCUSSION

To the best of our knowledge, compared to single cases using TPVB for awake mastectomy[9], there are no previous reports on the combination of two-sites TPVB with IBPB as the sole anesthetic technique for MRM. In our 10 elderly patients with multiple comorbidities, this technique provided potent alternative anesthesia with extended postoperative analgesia, and avoided the use of opioids, vasopressors, neuromuscular blocking agents and mechanical ventilation. In addition, PONV, cardiovascular and pulmonary complications were not observed. A similar observation was confirmed by a single case report[12]. Also, thoracic epidural anesthesia combined with IBPB[8] provided similar anesthesia and analgesia compared to ultrasound-guided TPVB; however, the latter is a safer option. Although our technique requires expertise in ultrasound-guided loco-regional blocks and might not replace general anesthesia as routine for MRM, it remains a reliable alternative when general anesthesia is deemed undesirable or poses unacceptable risks.

With the assistance of real-time ultrasound, many high-risk regional blocks, such as TPVB, have become more popular and are safer. TPVB involves the injection of local anesthetics in the vicinity of spinal nerves emerging from the intervertebral foramina resulting in ipsilateral somatic and sympathetic nerve blockade in multiple contiguous dermatomes above and below the site of injection [13]. Although four or five site blocks provide reliable analgesia[14], this is not practical for MRM. One study showed that contrast dye spread to 4.5 dermatome segments vertically after a single paravertebral injection compared to 6 segments after double-level injections[13]. An improved analgesic effect was demonstrated with double-level TPVB compared to single-level[11]. Based on these previous reports, we decided to use two-level TPVB. Effective anesthesia of the axilla and pectoral major muscle are essential for MRM, and is not achieved by TPVB alone. This area is innervated by the lateral and medial pectoral nerves, long thoracic nerve and thoracodorsal nerve, all originating from the brachial plexus [15]. Accordingly, IBPB is an essential complement for TPVB in MRM.

Vigilance and continuous monitoring are mandatory, regarding potential complications such as inadvertent vascular puncture, epidural or intrathecal spread, pneumothorax, serious bradycardia, contralateral Harlequin syndrome and Horner's syndrome[16]. Even though there is less possibility of spreading to the intervertebral foramen and phrenic nerve and extensive intramuscular deposition with 5 mL IBPB than with 20 mL[17], it is also much better to administer nasal oxygen for 12 h. Despite the aforementioned potential complications, regional anesthesia and analgesia enhance postoperative oral intake, ambulation and rehabilitation[5], and potentially increase patient tolerance to early chemotherapy as compared with general anesthesia.

Other superficial facial blocks have been reported in case reports of MRM despite the uncertainty of local anesthetic diffusion and patchy coverage. In order to ensure the anesthesia effect, serratus anterior plane block was often combined with remifentanyl infusion and 3 supplementary subcutaneous infiltrations of the intercostobrachial nerve, medial branches of the intercostal nerve and superficial cervical plexus[18], or 30 mg ketamine[19]. It was confirmed that the erector spinae plane at T4 was feasible for MRM, however fentanyl supplementation was required in all cases[20]. The Pecs II nerve block with high volume and perfect diffusion may be an alternative to the combination of two-site TPVB and small-volume IBPB for further avoidance of respiratory depression[21]. Pecs II nerve block is aimed to block at least the pectoral nerves, the intercostobrachial, intercostals III-IV-V-VI and the long thoracic nerve. These nerves need to be blocked to provide complete analgesia during breast surgery, and it is an alternative or a rescue block if paravertebral blocks and thoracic epidurals failed, with the indications such as tumorectomies, extensive excisions, and axillary clearances.

The reliable impeccable anesthesia effect and simple and convenient operation associated with ultrasound-guided two-spot TPVB combined with small-volume IBPB has been highlighted and initially proved by the present ten cases. Regarding the thoracic dermatome and breast MRM, ultrasound-guided TPVB provide thorough anesthetic effect similar to thoracic epidural anesthesia, with better visualization and higher successful rate. Two-sites TPVB guarantee more extensive anesthesia scope than single-site, especially for intercostobrachial nerve, avoiding neither tedious process nor puncture-related pain required by 3-5 sites injection. Because axillary dermatome, pectoral major and minor muscles are dominated by nerve roots of bronchial plexus, IBPB is more straightforward, impeccable and efficient than terminal branch block and superficial plane block, such as serratus anterior plane block, Pecs II nerve block, medial bronchial cutaneous nerve block, which facilitate puncture operation and local anesthetics dosing. The fearful anxiety of phrenic nerve paralysis associated with IBPB, is also evitable when using 5 mL rather than routine volume of 20 mL, with equivalent effect. With the better visualization and higher successful rate provided by ultrasound-guided intervention technique, the method might be also feasible in the morbid obesity population.

Our observation was performed in a single site and restricted to 10 Chinese patients. Both efficacy and safety outcomes were highly related with anesthetist's manipulation capability of ultrasound-guided regional anesthesia. Further multi-center randomized control trial with enough sample size is needed to finally determine the feasibility, efficiency and safety of the novel combinations. For further improvement, subcutaneous infiltration of the supraclavicular nerve might be supplemented for the dermatomal area around the clavicle, pectoralis major, and deltoid[12]. Further decrease of either concentration or volume of ropivacaine is worth of investigation with regard to the equivalent and safe alternative approach. Diaphragmatic activity monitoring by ultrasound, or pulmonary function test should be performed during perioperative period to provide authentic proof in terms of pulmonary function.

## CONCLUSION

Two-spot TPVB combined with small-volume IBPB is considered a reliable and safe alternative anesthetic technique for MRM, which avoids the potential risks of general anesthesia especially in frail patients with multiple comorbidities, and provides extended postoperative analgesia.

## FOOTNOTES

**Author contributions:** Li K was the patients' anesthetist; Sun G was the patients' surgeon; Li K reviewed the literature and contributed to study conception and design, acquisition, analysis and interpretation of data, drafting the article, revising it critically for important intellectual content; Hu ZT and Wang ST were contributed to follow-up, acquisition, revising the article critically for important intellectual content; all authors have read and approved the final manuscript, and agreed to be accountable for all aspects of the work.

**Informed consent statement:** Informed written consent was obtained from the patient for publication of this report and any accompanying images.

**Conflict-of-interest statement:** The authors declare that they have no conflict of interest.

**CARE Checklist (2016) statement:** The authors have read the CARE Checklist (2016), and the manuscript was prepared and revised according to the CARE Checklist (2016).

**Open-Access:** This article is an open-access article that was selected by an in-house editor and fully peer-reviewed by external reviewers. It is distributed in accordance with the Creative Commons Attribution NonCommercial (CC BY-NC 4.0) license, which permits others to distribute, remix, adapt, build upon this work non-commercially, and license their derivative works on different terms, provided the original work is properly cited and the use is non-commercial. See: <https://creativecommons.org/licenses/by-nc/4.0/>

**Country/Territory of origin:** China

**ORCID number:** Zhou-Ting Hu 0000-0002-3440-7621; Guang Sun 0000-0001-5174-9829; Shen-Tong Wang 0000-0003-0296-2636; Kai Li 0000-0002-9342-8836.

**S-Editor:** Liu JH

**L-Editor:** A

**P-Editor:** Liu JH

## REFERENCES

- 1 DeSantis CE, Ma J, Gaudet MM, Newman LA, Miller KD, Goding Sauer A, Jemal A, Siegel RL. Breast cancer statistics, 2019. *CA Cancer J Clin* 2019; **69**: 438-451 [PMID: 31577379 DOI: 10.3322/caac.21583]
- 2 Jones C, Lancaster R. Evolution of Operative Technique for Mastectomy. *Surg Clin North Am* 2018; **98**: 835-844 [PMID: 30005777 DOI: 10.1016/j.suc.2018.04.003]
- 3 Shirakami G, Teratani Y, Segawa H, Matsuura S, Shichino T, Fukuda K. Omission of fentanyl during sevoflurane anesthesia decreases the incidences of postoperative nausea and vomiting and accelerates postanesthesia recovery in major breast cancer surgery. *J Anesth* 2006; **20**: 188-195 [PMID: 16897238 DOI: 10.1007/s00540-006-0413-x]
- 4 Sessler DI, Pei L, Huang Y, Fleischmann E, Marhofer P, Kurz A, Mayers DB, Meyer-Treschan TA, Grady M, Tan EY, Ayad S, Mascha EJ, Buggy DJ; Breast Cancer Recurrence Collaboration. Recurrence of breast cancer after regional or general anaesthesia: a randomised controlled trial. *Lancet* 2019; **394**: 1807-1815 [PMID: 31645288 DOI: 10.1016/S0140-6736(19)32313-X]
- 5 Malik OS, Brovman EY, Urman RD. The Use of Regional or Local Anesthesia for Carotid Endarterectomies May Reduce Blood Loss and Pulmonary Complications. *J Cardiothorac Vasc Anesth* 2019; **33**: 935-942 [PMID: 30243870 DOI: 10.1053/j.jvca.2018.08.195]
- 6 Ahn EJ, Kim HJ, Kim KW, Choi HR, Kang H, Bang SR. Comparison of general anaesthesia and regional anaesthesia in terms of mortality and complications in elderly patients with hip fracture: a nationwide population-based study. *BMJ Open* 2019; **9**: e029245 [PMID: 31501111 DOI: 10.1136/bmjopen-2019-029245]
- 7 Wall T, Sherwin A, Ma D, Buggy DJ. Influence of perioperative anaesthetic and analgesic interventions on oncological outcomes: a narrative review. *Br J Anaesth* 2019; **123**: 135-150 [PMID: 31255291 DOI: 10.1016/j.bja.2019.04.062]
- 8 Sundarathiti P, Pasutharnchat K, Kongdan Y, Suranutkarin PE. Thoracic epidural anesthesia (TEA) with 0.2% ropivacaine in combination with ipsilateral brachial plexus block (BPB) for modified radical mastectomy (MRM). *J Med Assoc Thai* 2005; **88**: 513-520 [PMID: 16146257]
- 9 Santonastaso DP, de Chiara A, Piccioni F, Tognù A, Agnoletti V. Awake mastectomy under ultrasound guided thoracic paravertebral block in elderly patients. *J Clin Anesth* 2018; **47**: 50-51 [PMID: 29574286 DOI: 10.1016/j.jclinane.2018.03.014]
- 10 Abdallah FW, Morgan PJ, Cil T, McNaught A, Escallon JM, Semple JL, Wu W, Chan VW. Ultrasound-guided multilevel paravertebral blocks and total intravenous anesthesia improve the quality of recovery after ambulatory breast tumor resection. *Anesthesiology* 2014; **120**: 703-713 [PMID: 24071616 DOI: 10.1097/ALN.0000436117.52143.bc]
- 11 Kasimahanti R, Arora S, Bhatia N, Singh G. Ultrasound-guided single- vs double-level thoracic paravertebral block for postoperative analgesia in total mastectomy with axillary clearance. *J Clin Anesth* 2016; **33**: 414-421 [PMID: 27555203 DOI: 10.1016/j.jclinane.2016.01.027]
- 12 Nirmal CP, Gowrishankar C. Thoracic Paravertebral Block and Interscalene Brachial Plexus Block Superficial Cervical Plexus Block for Breast Surgery in A Patient with Ischemic Heart Disease. *BLOOD PRESSURE* 2019; **130**: 80
- 13 Hara K, Sakura S, Nomura T, Saito Y. Ultrasound guided thoracic paravertebral block in breast surgery. *Anaesthesia* 2009; **64**: 223-225 [PMID: 19143711 DOI: 10.1111/j.1365-2044.2008.05843.x]
- 14 Naja ZM, El-Rajab M, Al-Tannir MA, Ziade FM, Tayara K, Younes F, Lönnqvist PA. Thoracic paravertebral block: influence of the number of injections. *Reg Anesth Pain Med* 2006; **31**: 196-201 [PMID: 16701182 DOI: 10.1016/j.rapm.2005.12.004]
- 15 Kaya M, Oğuz G, Şenel G, Kadioğulları N. Postoperative analgesia after modified radical mastectomy: the efficacy of interscalene brachial plexus block. *J Anesth* 2013; **27**: 862-867 [PMID: 23736824 DOI: 10.1007/s00540-013-1647-z]
- 16 Batra RK, Krishnan K, Agarwal A. Paravertebral block. *J Anaesthesiol Clin Pharmacol* 2011; **27**: 5-11 [PMID: 21804697]
- 17 Stundner O, Meissnitzer M, Brummett CM, Moser S, Forstner R, Koköfer A, Danninger T, Gerner P, Kirchmair L, Fritsch G. Comparison of tissue distribution, phrenic nerve involvement, and epidural spread in standard- vs low-volume ultrasound-guided interscalene plexus block using contrast magnetic resonance imaging: a randomized, controlled trial. *Br J Anaesth* 2016; **116**: 405-412 [PMID: 26865133 DOI: 10.1093/bja/aev550]

- 18 **Sanllorente-Sebastián R**, de Vicente-Lorenzo JM, Mediavilla-Herrera FJ, Gutiérrez-García S, Alario-Poza IS, Bustinza-Beaskoetxea Z. Case report: serratus intercostal plane block/BRILMA and sedation for mastectomy in a high risk patient. *Rev Esp Anesthesiol Reanim (Engl Ed)* 2019; **66**: 46-48 [PMID: [30115502](#) DOI: [10.1016/j.redar.2018.06.009](#)]
- 19 **Pedrosa FP**, Cravo H. Serratus Anterior Plane Block for Awake Breast Surgery: A Case Report. *AA Pract* 2020; **14**: e01354 [PMID: [33295745](#) DOI: [10.1213/XAA.0000000000001354](#)]
- 20 **Malawat A**, Verma K, Jethava D, Jethava DD. Erector spinae plane block for complete surgical anaesthesia and postoperative analgesia for breast surgeries: A prospective feasibility study of 30 cases. *Indian J Anaesth* 2020; **64**: 118-124 [PMID: [32139929](#) DOI: [10.4103/ija.IJA\\_639\\_19](#)]
- 21 **Blanco R**, Fajardo M, Parras Maldonado T. Ultrasound description of Pecs II (modified Pecs I): a novel approach to breast surgery. *Rev Esp Anesthesiol Reanim* 2012; **59**: 470-475 [PMID: [22939099](#) DOI: [10.1016/j.redar.2012.07.003](#)]



Published by **Baishideng Publishing Group Inc**  
7041 Koll Center Parkway, Suite 160, Pleasanton, CA 94566, USA

**Telephone:** +1-925-3991568

**E-mail:** [bpgoffice@wjgnet.com](mailto:bpgoffice@wjgnet.com)

**Help Desk:** <https://www.f6publishing.com/helpdesk>

<https://www.wjgnet.com>

