

World Journal of *Clinical Cases*

World J Clin Cases 2022 May 26; 10(15): 4713-5123



Contents

Thrice Monthly Volume 10 Number 15 May 26, 2022

EDITORIAL

- 4713 Diet and intestinal bacterial overgrowth: Is there evidence?
Souza C, Rocha R, Cotrim HP

MINIREVIEWS

- 4717 Definition and classification of acute-on-chronic liver diseases
Zhang YY, Meng ZJ
- 4726 Management of neurosurgical patients during coronavirus disease 2019 pandemics: The Ljubljana, Slovenia experience
Velmar T, Bosnjak R

ORIGINAL ARTICLE

Clinical and Translational Research

- 4737 Glycolytic and fatty acid oxidation genes affect the treatment and prognosis of liver cancer
Zou JY, Huang YJ, He J, Tang ZX, Qin L
- 4761 Detection of a novel panel of 24 genes with high frequencies of mutation in gastric cancer based on next-generation sequencing
Zeng HH, Yang Z, Qiu YB, Bashir S, Li Y, Xu M

Case Control Study

- 4776 Outcomes of cervical degenerative disc disease treated by anterior cervical discectomy and fusion with self-locking fusion cage
Zhang B, Jiang YZ, Song QP, An Y
- 4785 Impact of COVID-19 pandemic on clinicopathological features of transplant recipients with hepatocellular carcinoma: A case-control study
Akbulut S, Sahin TT, Ince V, Yilmaz S

Retrospective Study

- 4799 Risk factors and optimal predictive scoring system of mortality for children with acute paraquat poisoning
Song Y, Wang H, Tao YH
- 4810 Application effect of thoracoscopic tricuspid valvuloplasty in geriatric patients with tricuspid valve disease
Jiang W, Long XM, Wei KQ, Li SC, Zhang Z, He BF, Li H
- 4818 Endoscopic ultrasonography in the evaluation of condition and prognosis of ulcerative colitis
Jin RF, Chen YM, Chen RP, Ye HJ

- 4827** Dynamic interaction nursing intervention on functional rehabilitation and self-care ability of patients after aneurysm surgery

Xie YE, Huang WC, Li YP, Deng JH, Huang JT

Clinical Trials Study

- 4836** Validations of new cut-offs for surgical drains management and use of computerized tomography scan after pancreatoduodenectomy: The DALCUT trial

Caputo D, Coppola A, La Vaccara V, Passa R, Carbone L, Ciccozzi M, Angeletti S, Coppola R

Observational Study

- 4843** Psychosocial adaptation and influencing factors among patients with chemotherapy-induced peripheral neuropathy

Zhou X, Wang DY, Ding CY, Liu H, Sun ZQ

META-ANALYSIS

- 4856** Outcome of the efficacy of Chinese herbal medicine for functional constipation: A systematic review and meta-analysis

Lyu Z, Fan Y, Bai Y, Liu T, Zhong LL, Liang HF

CASE REPORT

- 4878** Familial gastrointestinal stromal tumors with *KIT* germline mutation in a Chinese family: A case report

Yuan W, Huang W, Ren L, Xu C, Luan LJ, Huang J, Xue AW, Fang Y, Gao XD, Shen KT, Lv JH, Hou YY

- 4886** Nonfunctional pancreatic neuroendocrine tumours misdiagnosed as autoimmune pancreatitis: A case report and review of literature

Lin ZQ, Li X, Yang Y, Wang Y, Zhang XY, Zhang XX, Guo J

- 4895** Sudden deafness as a prodrome of cerebellar artery infarction: Three case reports

Li BL, Xu JY, Lin S

- 4904** Importance of abdominal X-ray to confirm the position of levonorgestrel-releasing intrauterine system: A case report

Maebayashi A, Kato K, Hayashi N, Nagaishi M, Kawana K

- 4911** Bedside ultrasonic localization of the nasogastric tube in a patient with severe COVID-19: A case report

Zhu XJ, Liu SX, Li QT, Jiang YJ

- 4917** Paradoxical herniation after decompressive craniectomy provoked by mannitol: A case report

Du C, Tang HJ, Fan SM

- 4923** Targeted next-generation sequencing identifies a novel nonsense mutation in ANK1 for hereditary spherocytosis: A case report

Fu P, Jiao YY, Chen K, Shao JB, Liao XL, Yang JW, Jiang SY

- 4929** Nonfunctional bladder paraganglioma misdiagnosed as hemangioma: A case report

Chen J, Yang HF

- 4935** Special type of Wernekink syndrome in midbrain infarction: Four case reports
Yang YZ, Hu WX, Zhai HJ
- 4942** Primary extraskeletal Ewing's sarcoma of the lumbar nerve root: A case report
Lei LH, Li F, Wu T
- 4949** Yellow nail syndrome accompanied by minimal-change nephrotic syndrome: A case report
Zhang YN, Wang MH, Yu WC, Cheng W, Cong JP, Huang XP, Wang FF
- 4957** Total femur replacement with 18 years of follow-up: A case report
Yang YH, Chen JX, Chen QY, Wang Y, Zhou YB, Wang HW, Yuan T, Sun HP, Xie L, Yao ZH, Yang ZZ
- 4964** Male metaplastic breast cancer with poor prognosis: A case report
Kim HY, Lee S, Kim DI, Jung CS, Kim JY, Nam KJ, Choo KS, Jung YJ
- 4971** CD8-positive indolent T-Cell lymphoproliferative disorder of the gastrointestinal tract: A case report and review of literature
Weng CY, Ye C, Fan YH, Lv B, Zhang CL, Li M
- 4985** Bone flare after initiation of novel hormonal therapy in patients with metastatic hormone-sensitive prostate cancer: A case report
Li KH, Du YC, Yang DY, Yu XY, Zhang XP, Li YX, Qiao L
- 4991** Postoperative infection of the skull base surgical site due to suppurative parotitis: A case report
Zhao Y, Zhao Y, Zhang LQ, Feng GD
- 4998** Blunt aortic injury-traumatic aortic isthmus pseudoaneurysm with right iliac artery dissection aneurysm: A case report
Fang XX, Wu XH, Chen XF
- 5005** Extensive complex thoracoabdominal aortic aneurysm salvaged by surgical graft providing landing zone for endovascular graft: A case report
Jang AY, Oh PC, Kang JM, Park CH, Kang WC
- 5012** Gastric heterotopia of colon found cancer workup in liver abscess: A case report
Park JG, Suh JI, Kim YU
- 5018** Clinical manifestations and gene analysis of Hutchinson-Gilford progeria syndrome: A case report
Zhang SL, Lin SZ, Zhou YQ, Wang WQ, Li JY, Wang C, Pang QM
- 5025** Neurocutaneous melanosis with an intracranial cystic-solid meningeal melanoma in an adult: A case report and review of literature
Liu BC, Wang YB, Liu Z, Jiao Y, Zhang XF
- 5036** Metastasis of liver cancer to the thyroid after surgery: A case report
Zhong HC, Sun ZW, Cao GH, Zhao W, Ma K, Zhang BY, Feng YJ

- 5042** Spontaneous liver rupture following SARS-CoV-2 infection in late pregnancy: A case report
Ambrož R, Stašek M, Molnár J, Špička P, Klos D, Hambálek J, Skanderová D
- 5051** Carotid blowout syndrome caused by chronic infection: A case report
Xie TH, Zhao WJ, Li XL, Hou Y, Wang X, Zhang J, An XH, Liu LT
- 5057** Is repeat wide excision plus radiotherapy of localized rectal melanoma another choice before abdominoperineal resection? A case report
Chiu HT, Pu TW, Yen H, Liu T, Wen CC
- 5064** Metaplastic breast cancer with chondrosarcomatous differentiation combined with concurrent bilateral breast cancer: A case report
Yang SY, Li Y, Nie JY, Yang ST, Yang XJ, Wang MH, Zhang J
- 5072** Rare solitary splenic metastasis from a thymic carcinoma detected on fluorodeoxyglucose-positron emission tomography: A case report
Tsai YH, Lin KH, Huang TW
- 5077** Type A aortic dissection following heart transplantation: A case report
Zeng Z, Yang LJ, Zhang C, Xu F
- 5082** Catheter-related infections caused by *Mycobacterium abscessus* in a patient with motor neurone disease: A case report
Pan SF, Zhang YY, Wang XZ, Sun JJ, Song SL, Tang YR, Wang JL
- 5088** Clear aligner treatment for a four-year-old patient with anterior cross-bite and facial asymmetry: A case report
Zou YR, Gan ZQ, Zhao LX
- 5097** Knot impingement after arthroscopic rotator cuff repair mimicking infection: A case report
Kim DH, Jeon JH, Choi BC, Cho CH
- 5103** Solitary primary pulmonary synovial sarcoma: A case report
He WW, Huang ZX, Wang WJ, Li YL, Xia QY, Qiu YB, Shi Y, Sun HM
- 5111** Anesthetic management for intraoperative acute pulmonary embolism during inferior vena cava tumor thrombus surgery: A case report
Hsu PY, Wu EB
- 5119** Delayed diagnosis of arytenoid cartilage dislocation after tracheal intubation in the intensive care unit: A case report
Yan WQ, Li C, Chen Z

ABOUT COVER

Editorial Board Member of *World Journal of Clinical Cases*, Jing Yang, MD, Associate Professor, Department of the First General Surgery, Gansu Provincial Hospital, Lanzhou 730000, Gansu Province, China. 21634604@qq.com

AIMS AND SCOPE

The primary aim of *World Journal of Clinical Cases* (WJCC, *World J Clin Cases*) is to provide scholars and readers from various fields of clinical medicine with a platform to publish high-quality clinical research articles and communicate their research findings online.

WJCC mainly publishes articles reporting research results and findings obtained in the field of clinical medicine and covering a wide range of topics, including case control studies, retrospective cohort studies, retrospective studies, clinical trials studies, observational studies, prospective studies, randomized controlled trials, randomized clinical trials, systematic reviews, meta-analysis, and case reports.

INDEXING/ABSTRACTING

The WJCC is now indexed in Science Citation Index Expanded (also known as SciSearch®), Journal Citation Reports/Science Edition, Scopus, PubMed, and PubMed Central. The 2021 Edition of Journal Citation Reports® cites the 2020 impact factor (IF) for WJCC as 1.337; IF without journal self cites: 1.301; 5-year IF: 1.742; Journal Citation Indicator: 0.33; Ranking: 119 among 169 journals in medicine, general and internal; and Quartile category: Q3. The WJCC's CiteScore for 2020 is 0.8 and Scopus CiteScore rank 2020: General Medicine is 493/793.

RESPONSIBLE EDITORS FOR THIS ISSUE

Production Editor: Ying-Yi Yuan; Production Department Director: Xiang Li; Editorial Office Director: Jin-Lei Wang.

NAME OF JOURNAL

World Journal of Clinical Cases

ISSN

ISSN 2307-8960 (online)

LAUNCH DATE

April 16, 2013

FREQUENCY

Thrice Monthly

EDITORS-IN-CHIEF

Bao-Gan Peng, Jerzy Tadeusz Chudek, George Kontogeorgos, Maurizio Serati, Ja Hyeon Ku

EDITORIAL BOARD MEMBERS

<https://www.wjgnet.com/2307-8960/editorialboard.htm>

PUBLICATION DATE

May 26, 2022

COPYRIGHT

© 2022 Baishideng Publishing Group Inc

INSTRUCTIONS TO AUTHORS

<https://www.wjgnet.com/bpg/gerinfo/204>

GUIDELINES FOR ETHICS DOCUMENTS

<https://www.wjgnet.com/bpg/GerInfo/287>

GUIDELINES FOR NON-NATIVE SPEAKERS OF ENGLISH

<https://www.wjgnet.com/bpg/gerinfo/240>

PUBLICATION ETHICS

<https://www.wjgnet.com/bpg/GerInfo/288>

PUBLICATION MISCONDUCT

<https://www.wjgnet.com/bpg/gerinfo/208>

ARTICLE PROCESSING CHARGE

<https://www.wjgnet.com/bpg/gerinfo/242>

STEPS FOR SUBMITTING MANUSCRIPTS

<https://www.wjgnet.com/bpg/GerInfo/239>

ONLINE SUBMISSION

<https://www.f6publishing.com>

Clinical manifestations and gene analysis of Hutchinson-Gilford progeria syndrome: A case report

Su-Li Zhang, Shuang-Zhu Lin, Yan-Qiu Zhou, Wan-Qi Wang, Jia-Yi Li, Cui Wang, Qi-Ming Pang

Specialty type: Medicine, research and experimental

Provenance and peer review: Unsolicited article; Externally peer reviewed.

Peer-review model: Single blind

Peer-review report's scientific quality classification

Grade A (Excellent): 0

Grade B (Very good): 0

Grade C (Good): C, C

Grade D (Fair): 0

Grade E (Poor): 0

P-Reviewer: Ortega-Gutiérrez S, Spain; Rodrigues AT, Brazil

Received: November 19, 2021

Peer-review started: November 19, 2021

First decision: December 27, 2021

Revised: January 10, 2022

Accepted: March 26, 2022

Article in press: March 26, 2022

Published online: May 26, 2022



Su-Li Zhang, Cui Wang, Qi-Ming Pang, Department of Neuroscience, Hainan Women and Children's Medical Center, Haikou 570100, Hainan Province, China

Shuang-Zhu Lin, Yan-Qiu Zhou, Diagnosis and Treatment Center for Children, First Affiliated Hospital to Changchun University of Chinese Medicine, Changchun 130021, Jilin Province, China

Wan-Qi Wang, Jia-Yi Li, Changchun University of Chinese Medicine, Changchun 130000, Jilin Province, China

Corresponding author: Qi-Ming Pang, MD, Associate Chief Physician, Department of Neuroscience, Hainan Women and Children's Medical Center, No. 15 Longkun Nan Lu, Haikou 570100, Hainan Province, China. 69704936@qq.com

Abstract

BACKGROUND

This case report describes a child with Hutchinson-Gilford progeria syndrome (HGPS, OMIM: 176670) caused by *LMNA* (OMIM: 150330) gene mutation, and we have previously analyzed the clinical manifestations and imaging characteristics of this case. After 1-year treatment and follow-up, we focus on analyzing the changes in the clinical manifestations and genetic diagnosis of the patient.

CASE SUMMARY

In April 2020, a 2-year-old boy with HGPS was found to have an abnormal appearance, and growth and development lagged behind those of children of the same age. The child's weight did not increase normally, the veins of the head were clearly visible, and he had shallow skin color and sparse yellow hair. Peripheral blood DNA samples obtained from the patient and his parents were sequenced using high-throughput whole-exome sequencing, which was verified by Sanger sequencing. The results showed that there was a synonymous heterozygous mutation of C.1824 C>T (P. G608G) in the *LMNA* gene.

CONCLUSION

Mutation of the *LMNA* gene provides a molecular basis for diagnosis of HGPS and genetic counseling of the family.

Key Words: Hutchinson-Gilford progeria syndrome; *LMNA*; Children; Physiological function; Organ aging; Case report

Core Tip: The main clinical manifestations of Hutchinson-Gilford progeria syndrome (HGPS) in this 2-year-old boy were abnormal appearance, and growth and development lag behind children of the same age. DNA sequencing showed that there was a synonymous heterozygous mutation in the *LMNA* gene. This study provides a molecular basis for the etiological diagnosis of HGPS and genetic counseling for the family.

Citation: Zhang SL, Lin SZ, Zhou YQ, Wang WQ, Li JY, Wang C, Pang QM. Clinical manifestations and gene analysis of Hutchinson-Gilford progeria syndrome: A case report. *World J Clin Cases* 2022; 10(15): 5018-5024

URL: <https://www.wjgnet.com/2307-8960/full/v10/i15/5018.htm>

DOI: <https://dx.doi.org/10.12998/wjcc.v10.i15.5018>

INTRODUCTION

Hutchinson-Gilford progeria syndrome (HGPS) is a well-characterized premature aging disorder caused by mutations in *LMNA*, the gene encoding the nuclear scaffold proteins lamins A and C[1,2]. We have previously analyzed the clinical manifestations and imaging characteristics of this case[3]. HGPS is characterized by the presence of aging-associated symptoms, including lack of subcutaneous fat, alopecia, swollen veins, growth retardation, age spots, joint contractures, osteoporosis, cardiovascular pathology, and death due to heart attacks and strokes in childhood[4]. In this study, a heterozygous mutation of the *LMNA* gene was found by high-throughput whole-exosome sequencing in a 2-year-old patient with an abnormal appearance, and growth and development lag behind those of children of the same age.

CASE PRESENTATION

Chief complaints

A boy was aged 2 years and 5 mo at the time of diagnosis of HGPS, by which time, he had an abnormal appearance and his growth and development lagged behind those of children of his age.

History of present illness

In the past 6 mo, the weight of the child did not increase and remained at about 8 kg. The veins in the head of the child were clearly visible, his skin was lighter, and his hair was yellow and sparse, which were the main clinical manifestations of the disease. Peripheral blood DNA samples obtained from the patient and his parents were sequenced using high-throughput whole-exosome sequencing, which was verified by Sanger sequencing.

History of past illness

At birth, the parents found that the veins and blood vessels at the trunk of the child were obvious. At the age of 6 mo, the head and trunk veins were more apparent, and the skin pigment in the trunk was partially lost, presenting as spots. Around the age of 1 year, the scalp vein and skin had lost pigment, and his hair was relatively sparse. After 1 year of age, the increase in body weight was not obvious, and he was immediately taken to a local hospital. A diagnosis of rickets was considered, but the relevant treatment seemed useless.

Personal and family history

The child was born at 40 wk by cesarean section. He weighed 2650 g at birth and had no history of asphyxia rescue. After birth, he received artificial feeding. Milk and porridge were added as supplementary foods. He could raise up his head at 3 mo, turn over at 4-5 mo, and walk steadily at 11 mo. At the age of 1 year, he could shout "YeYe" and "NaNa", and at 18 mo, continuous sentences could be spoken. He could express his needs. His neurological and mental development was the same as that of children of the same age. His parents were not consanguineous. There was no family history of familial genetic disease or infectious diseases.

Physical examination

The child's weight was 8 kg, head circumference 46.5 cm, and body length 81 cm, which were lower than those of children at the same age. There was no abnormal mental reaction. The skin was thin and

had poor elasticity. The skin of the trunk showed spot-like depigmentation, and some superficial lymph nodes were swollen. It could also be seen that the hair was sparse and yellow, the veins of the scalp were clearly visible, and the anterior fontanel was not closed. His eyeballs were slightly prominent, the bridge of the nose was lower, and the face showed mandibuloacral dysplasia. The ear position was not low, and there was no penetrating palm. The chest circumference was 44 cm and the chest showed changes consistent with pigeon breast. There were no abnormalities in the auscultation of his heart and lungs. His knee and ankle joints were stiff, with poor mobility, his fingers and toes were slender, and his joints showed slight swelling, with clubbing fingers. Bilateral Babinski signs were positive.

Laboratory examinations

We carried out tests on the patient's blood: Leukocyte count $7.9 \times 10^9/L$, hemoglobin 130 g/L, platelet count $339 \times 10^9/L$, neutrophils 32.4%, lymphocytes 58.3%, and calcitonin 0.00 mg/L. The results of thyroid function tests were: Serum total triiodothyronine (T3) 3.29 nmol/L, total serum thyroxine 86.00 nmol/L, free T3 7.03 pmol/L, thyroid-stimulating hormone 1.93 mIU/L, and parathyroid hormone 0.21 pmol/L. Liver and kidney function tests, electrolytes, blood gas analysis, copper blue analysis, urine and feces analysis, coagulation function tests, and erythrocyte sedimentation rate showed no obvious abnormalities.

Imaging examinations

The results of electroencephalography and blood/urine tandem mass spectrometry were normal. Color Doppler echocardiography showed mild tricuspid regurgitation. The liver, bile, pancreas, and spleen were examined by color Doppler ultrasonography, and the results showed no abnormalities. The testicular color ultrasound examination showed a fluid dark area around the right testicle, which could be considered as a testicular hydrocele. No abnormal acoustic images were found in the testicle and epididymis on both sides. Chest radiographs showed normal cardiopulmonary septum. Spina bifida of the second sacral vertebral body was possible. Three-dimensional cranial reconstruction showed a low-density lesion in the white matter space of the right parietal lobe. On November 29, 2019, nuclear magnetic resonance imaging of the head revealed a partial perivascular space, with localized keratinosis in bilateral parietal lobes, accompanied by thickening of the maxillary sinus mucosa on the right side, suggesting irregular tooth arrangement.

High throughput whole-exome sequencing and mitochondrial sequencing

Whole-exome sequencing (WES) and whole-genome sequencing analyses of copy number variants were performed to seek for genetic counseling and clarify the etiology of the child's condition. Informed consent was obtained from the parents on behalf of the proband for WES and mitochondrial sequencing and for publication of photographs. DNA was obtained from peripheral blood samples from the patient and his parents. Statistical analysis of the data on single nucleotide polymorphisms (SNPs) and insertion deletion mutations (indels) was conducted. The SNPs and indels were screened using the Database of Single Nucleotide Polymorphisms (dbSNP), 1000 Genomes, and ExAC database. Application of the human Online Mendelian Genetic Database (OMIM) confirmed the reported pathogenic gene locus. The American College of Medical Genetics and Genomics (ACMG) sequence variation interpretation standards and guidelines were used for a comprehensive evaluation of the pathogenicity of mutation sites.

Gene detection results and pathogenicity analysis

WES showed that there was a synonymous heterozygous variation of the *LMNA* gene in this patient, one of which was a spontaneous and synonymous mutation C.1824 C>T (P. G608G), which may lead to a change of gene function (Figure 1). No anomalies were found in the child's father and mother as revealed by WES (Figures 2 and 3). The frequency of the variation in the normal population is unknown, it is a low-frequency variation, and the results of protein function prediction are unknown. According to Sanger sequencing, there was no variation in this locus of parental genes, and the inheritance mode was autosomal dominant inheritance. According to ACMG guidelines, the mutation was suspected to be pathogenic.

FINAL DIAGNOSIS

Sanger sequencing showed that there was a spontaneous and synonymous heterozygous mutation of C.1824 C>T (P. G608G) in the *LMNA* gene. Due to the mutation of this gene, the child was diagnosed with HGPS.

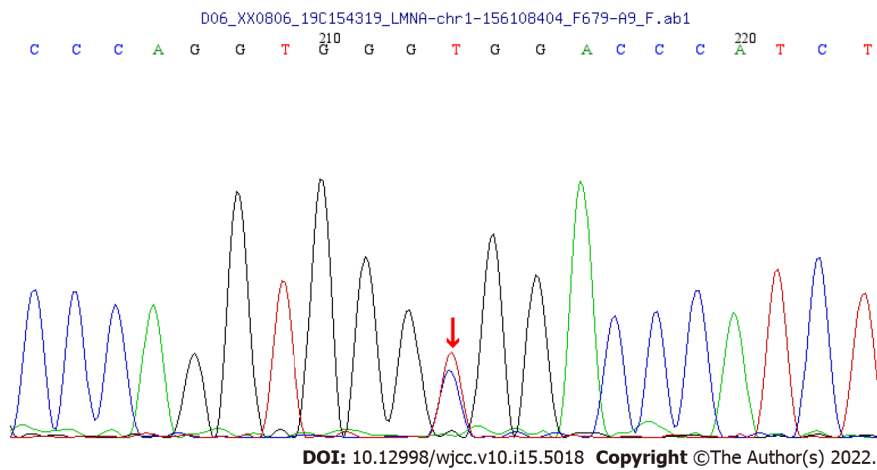


Figure 1 A synonymous spontaneous heterozygous mutations found in the *LMNA* gene in the patient.

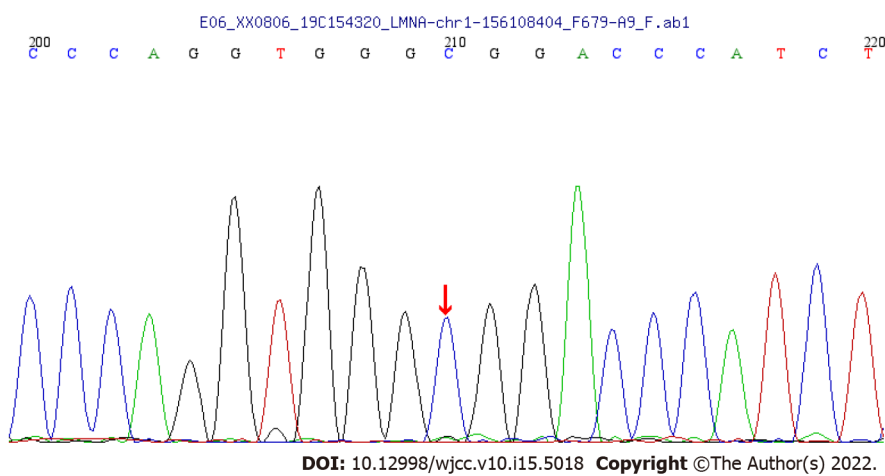


Figure 2 No anomalies were found in the *LMNA* gene in the child's father as revealed by whole-exome sequencing.

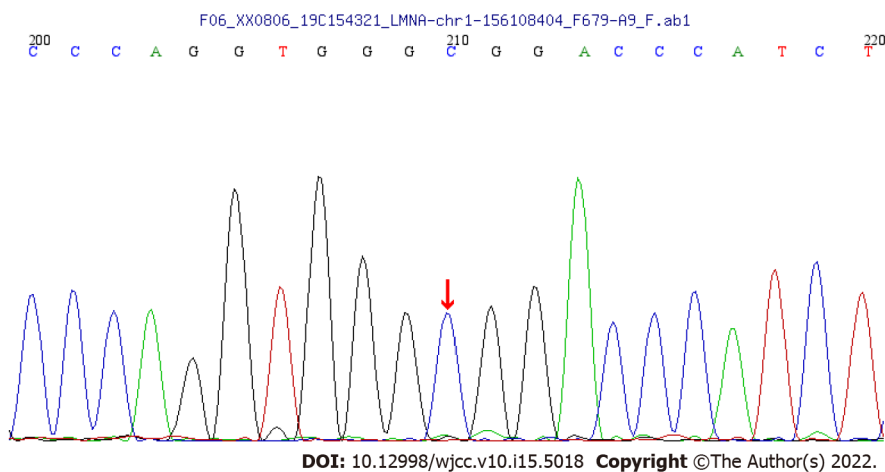


Figure 3 No anomalies were found in the *LMNA* gene in the child's mother as revealed by whole-exome sequencing.

TREATMENT

According to the clinical manifestations, laboratory tests, and gene sequencing results, the clinical phenotype of the patient was HGPS. The patient was treated with vitamin A/D, calcium supplement, and other drugs.

OUTCOME AND FOLLOW-UP

After 18 mo of treatment, the symptoms did not improve. Neither height nor weight have changed significantly since the age of 2 years.

DISCUSSION

HGPS (OMIM: 176670) is an autosomal dominant genetic disease that causes a remarkable phenotype resembling many aspects of aging[1,5]. The disease was first reported by general practitioner Jonathan Hutchinson in 1886, and was subsequently refined and supplemented[6]. The main first symptoms in typical childhood-onset phenotype include postnatal growth retardation (55%), alopecia (40%), absence of subcutaneous fat (28%), and lipodystrophy (20%)[1,7]. The following symptoms also exist: Midface hypoplasia, micrognathia, osteoporosis, low body weight, decreased joint mobility, and premature aging.

Children affected with HGPS typically appear normal at birth, but within a year the characteristic features of failure to thrive, delayed dentition, alopecia, and sclerodermatous skin changes begin to appear. Mean age at diagnosis is 2.9 years[8,9]. Median life expectancy is about 13 years, with most dying from complications associated with atherosclerosis. The most common mutation in HGPS, C.1824 C>T (P. G608G), is a synonymous substitution.

The *LMNA* (OMIM: 150330) gene is located on chromosome 1q22, and different sets of mutations in the *LMNA* and genes coding for interacting proteins, give rise to a variety of genetic disorders collectively called laminopathies[10]. *LMNA* codes for two major, alternatively spliced transcripts that give rise to lamin A and lamin C proteins, which are generated by use of an alternative 50 splice site in exon 10. Unlike lamin C, lamin A is translated as prelamin A and undergoes post-translational processing steps at the C-terminal CaaX motif[9,11].

We report a case of synonymous heterozygous mutation in the *LMNA* gene (C.1824 C>T; P.G608G). This variant belongs to a spontaneous mutation, whose parent gene has no variation at this locus, and the genetic mode belongs to the autosomal dominant inheritance[4,5]. As for the function of the mutation, the observed mutations improve the match to a consensus splice donor, suggesting that it activates a cryptic splice site. It shows that 150 nucleotides within exon 11 are missing. This abnormal transcript would be expected to code for a protein with an internal deletion of 50 amino acids near the C terminus of lamin A[10-13].

In the present case, obvious veins and blood vessels at the trunk were found. At the age of 6 mo, these were more apparent, and more typical symptoms appeared: Postnatal growth retardation, lipodystrophy, beak-like nose, micrognathia, and spotty skin pigment loss. Around the age of 1 year, his hair volume was sparse and he had a tendency to alopecia. The joints of the whole body, including the fingers and toes, were stiff, but there was no abnormal function of the circulation and digestive system. The child had normal intelligence and was born with low body weight, but had no history of feeding difficulties. Growth and development before 1 year were basically normal. Initially, the patient's clinical manifestations were squared skull, pigeon breast, and alopecia, in line with the clinically typical phenotype of rickets, so vitamin A/D and calcium treatment were given, but the ideal treatment effect was not obtained. In order to determine the cause of the disease, after obtaining informed consent from the patients, we used high-throughput WES and identified a synonymous heterozygous mutation of the *LMNA* gene[2].

We followed this patient for 18 mo, and found that his height and weight did not improve. This shows that most of the disease manifestations are determined by genetic mutations, so the support therapy does not improve quality of life[4,9,14].

People's cognition of the disease has been gradually deepened, prompting further exploration of the treatment for progeria. The main treatment strategies include gene therapy, biological therapy, and small molecule treatment[15,16]. Gene therapy can directly repair pathogenic mutations; although this therapy still has many limitations and is not commonly used currently, it is anticipated to be a valuable treatment in the future.

Modern studies suggest that lonafarnib, although unable to cure the disease, is able to improve some clinical symptoms of the disease and, therefore, can be a target for further research. Kang *et al*[17] reported that progerin may be an efficient, stable, and safe treatment.

With respect to the small molecule treatment, significant progress has been made in the enzyme isoprenylcysteine carboxylmethyltransferase inhibitors and the interaction between progerin and lamin A[18]. Regarding the biological therapy, antisense oligonucleotides have shown encouraging results in progeria.

ABE variants were reported to have higher editing activity than ABE7.10max by Koblan *et al*[19]. They suggest that ABE editing has the potential to cooperate with emerging premature treatments, including farnesyltransferase inhibitors, other small molecule drugs, or antisense oligonucleotides targeting the mutant *LMNA* allele.

CONCLUSION

We report a case of synonymous heterozygous mutation in the *LMNA* gene (C.1824 C>T; P.G608G). This variant belongs to a spontaneous mutation, whose parent gene has no variation at this locus, and the genetic mode belongs to the autosomal dominant inheritance. After 18 mo of treatment, the symptoms did not improve. Neither height nor weight have changed significantly. Up to now, the gene therapy is still in the developmental stage, so there are many unknown areas of the disease to be further investigated.

Taken together, although there are multiple obstacles to overcome before HGPS can be cured, effective treatments are only a matter of time as the molecular mechanisms of the disease are continuously understood and the exploration of therapeutic strategies continues[20].

ACKNOWLEDGEMENTS

We would like to thank the child and his family members for agreeing to participate in this study.

FOOTNOTES

Author contributions: Zhang SL and Lin SZ collected and analyzed all clinical data and wrote the manuscript; Zhou YQ and Wang C participated in the collation of the literature and the chart research; Pang QM was involved in the genetic diagnosis and treatment of the patient; Lin SZ, Zhou YQ, Wang WQ, and Li JY substantially participated in drafting and revising the important intellectual content of the manuscript; all authors involved have read and approved the final manuscript.

Supported by Hainan Province Clinical Medical Center, No. (2021)75 and No. (2021)276.

Informed consent statement: Informed consent was obtained from the patient's parents for the publication of this article.

Conflict-of-interest statement: All the authors of this article have no conflict of interest to disclose.

CARE Checklist (2016) statement: The authors have read the CARE Checklist (2016), and the manuscript was prepared and revised according to the CARE Checklist (2016).

Open-Access: This article is an open-access article that was selected by an in-house editor and fully peer-reviewed by external reviewers. It is distributed in accordance with the Creative Commons Attribution NonCommercial (CC BY-NC 4.0) license, which permits others to distribute, remix, adapt, build upon this work non-commercially, and license their derivative works on different terms, provided the original work is properly cited and the use is non-commercial. See: <https://creativecommons.org/licenses/by-nc/4.0/>

Country/Territory of origin: China

ORCID number: Su-Li Zhang 0000-0001-5887-1026; Shuang-Zhu Lin 0000-0001-5333-2138; Yan-Qiu Zhou 0000-0001-6834-1723; Wan-Qi Wang 0000-0002-8247-7616; Jia-Yi Li 0000-0002-7729-4479; Cui Wang 0000-0003-2723-5929; Qi-Ming Pang 0000-0002-9501-1700.

S-Editor: Gao CC

L-Editor: Wang TQ

P-Editor: Gao CC

REFERENCES

- 1 **Hennekam RC.** Hutchinson-Gilford progeria syndrome: review of the phenotype. *Am J Med Genet A* 2006; **140**: 2603-2624 [PMID: 16838330 DOI: 10.1002/ajmg.a.31346]
- 2 **Piekarczyk K,** Machowska M, Dzianisava V, Rzepecki R. Hutchinson-Gilford Progeria Syndrome-Current Status and Prospects for Gene Therapy Treatment. *Cells* 2019; **8** [PMID: 30691039 DOI: 10.3390/cells8020088]
- 3 **Zhang SL,** Pang QM, Wu SL. Clinical Manifestation and Imaging Analysis of One Case of Infantile Progeria. *Zhongguo Quanke Yixue* 2021; **24**(S1): 153-155
- 4 **Beyret E,** Liao HK, Yamamoto M, Hernandez-Benitez R, Fu Y, Erikson G, Reddy P, Izpisua Belmonte JC. Single-dose CRISPR-Cas9 therapy extends lifespan of mice with Hutchinson-Gilford progeria syndrome. *Nat Med* 2019; **25**: 419-422 [PMID: 30778240 DOI: 10.1038/s41591-019-0343-4]
- 5 **McCord RP,** Nazario-Toole A, Zhang H, Chines PS, Zhan Y, Erdos MR, Collins FS, Dekker J, Cao K. Correlated

- alterations in genome organization, histone methylation, and DNA-lamin A/C interactions in Hutchinson-Gilford progeria syndrome. *Genome Res* 2013; **23**: 260-269 [PMID: [23152449](#) DOI: [10.1101/gr.138032.112](#)]
- 6 **Hutchinson J.** Congenital Absence of Hair and Mammary Glands with Atrophic Condition of the Skin and its Appendages, in a Boy whose Mother had been almost wholly Bald from Alopecia Areata from the age of Six. *Med Chir Trans* 1886; **69**: 473-477 [PMID: [20896687](#) DOI: [10.1177/095952878606900127](#)]
 - 7 **Aguado J,** Sola-Carvajal A, Cancila V, Revêchon G, Ong PF, Jones-Weinert CW, Wallén Arzt E, Lattanzi G, Dreesen O, Tripodo C, Rossiello F, Eriksson M, d'Adda di Fagagna F. Inhibition of DNA damage response at telomeres improves the detrimental phenotypes of Hutchinson-Gilford Progeria Syndrome. *Nat Commun* 2019; **10**: 4990 [PMID: [31740672](#) DOI: [10.1038/s41467-019-13018-3](#)]
 - 8 **Ahmed MS,** Ikram S, Bibi N, Mir A. Hutchinson-Gilford Progeria Syndrome: A Premature Aging Disease. *Mol Neurobiol* 2018; **55**: 4417-4427 [PMID: [28660486](#) DOI: [10.1007/s12035-017-0610-7](#)]
 - 9 **Sun S,** Qin W, Tang X, Meng Y, Hu W, Zhang S, Qian M, Liu Z, Cao X, Pang Q, Zhao B, Wang Z, Zhou Z, Liu B. Vascular endothelium-targeted *Sirt7* gene therapy rejuvenates blood vessels and extends life span in a Hutchinson-Gilford progeria model. *Sci Adv* 2020; **6**: eaay5556 [PMID: [32128409](#) DOI: [10.1126/sciadv.aay5556](#)]
 - 10 **Maraldi NM,** Capanni C, Cenni V, Fini M, Lattanzi G. Laminopathies and lamin-associated signaling pathways. *J Cell Biochem* 2011; **112**: 979-992 [PMID: [21400569](#) DOI: [10.1002/jcb.22992](#)]
 - 11 **Eriksson M,** Brown WT, Gordon LB, Glynn MW, Singer J, Scott L, Erdos MR, Robbins CM, Moses TY, Berglund P, Dutra A, Pak E, Durkin S, Csoka AB, Boehnke M, Glover TW, Collins FS. Recurrent de novo point mutations in lamin A cause Hutchinson-Gilford progeria syndrome. *Nature* 2003; **423**: 293-298 [PMID: [12714972](#) DOI: [10.1038/nature01629](#)]
 - 12 **Zaremba-Czogalla M,** Dubińska-Magiera M, Rzepecki R. Laminopathies: the molecular background of the disease and the prospects for its treatment. *Cell Mol Biol Lett* 2011; **16**: 114-148 [PMID: [21225470](#) DOI: [10.2478/s11658-010-0038-9](#)]
 - 13 **Navarro CL,** De Sandre-Giovannoli A, Bernard R, Bocaccio I, Boyer A, Geneviève D, Hadj-Rabia S, Gaudy-Marqueste C, Smitt HS, Vabres P, Faivre L, Verloes A, Van Essen T, Flori E, Hennekam R, Beemer FA, Laurent N, Le Merrer M, Cau P, Lévy N. Lamin A and ZMPSTE24 (FACE-1) defects cause nuclear disorganization and identify restrictive dermopathy as a lethal neonatal laminopathy. *Hum Mol Genet* 2004; **13**: 2493-2503 [PMID: [15317753](#) DOI: [10.1093/hmg/ddh265](#)]
 - 14 **Kodachi T,** Matsumoto S, Mizuguchi M, Osaka H, Kanai N, Nanba E, Ohno K, Yamagata T. Severe demyelination in a patient with a late infantile form of Niemann-Pick disease type C. *Neuropathology* 2017; **37**: 426-430 [PMID: [28387450](#) DOI: [10.1111/neup.12380](#)]
 - 15 **Macicior J,** Marcos-Ramiro B, Ortega-Gutiérrez S. Small-Molecule Therapeutic Perspectives for the Treatment of Progeria. *Int J Mol Sci* 2021; **22** [PMID: [34281245](#) DOI: [10.3390/ijms22137190](#)]
 - 16 **Rahman MM,** Ferdous KS, Ahmed M, Islam MT, Khan MR, Perveen A, Ashraf GM, Uddin MS. Hutchinson-Gilford Progeria Syndrome: An Overview of the Molecular Mechanism, Pathophysiology and Therapeutic Approach. *Curr Gene Ther* 2021; **21**: 216-229 [PMID: [33655857](#) DOI: [10.2174/1566523221666210303100805](#)]
 - 17 **Kang SM,** Yoon MH, Ahn J, Kim JE, Kim SY, Kang SY, Joo J, Park S, Cho JH, Woo TG, Oh AY, Chung KJ, An SY, Hwang TS, Lee SY, Kim JS, Ha NC, Song GY, Park BJ. Progerinin, an optimized progerin-lamin A binding inhibitor, ameliorates premature senescence phenotypes of Hutchinson-Gilford progeria syndrome. *Commun Biol* 2021; **4**: 5 [PMID: [33398110](#) DOI: [10.1038/s42003-020-01540-w](#)]
 - 18 **Marcos-Ramiro B,** Gil-Ordóñez A, Marín-Ramos NI, Ortega-Nogales FJ, Balabasquer M, Gonzalo P, Khiar-Fernández N, Rolas L, Barkaway A, Nourshargh S, Andrés V, Martín-Fontecha M, López-Rodríguez ML, Ortega-Gutiérrez S. Isoprenylcysteine Carboxylmethyltransferase-Based Therapy for Hutchinson-Gilford Progeria Syndrome. *ACS Cent Sci* 2021; **7**: 1300-1310 [PMID: [34471675](#) DOI: [10.1021/acscentsci.0c01698](#)]
 - 19 **Koblan LW,** Erdos MR, Wilson C, Cabral WA, Levy JM, Xiong ZM, Tavaréz UL, Davison LM, Gete YG, Mao X, Newby GA, Doherty SP, Narisu N, Sheng Q, Krilow C, Lin CY, Gordon LB, Cao K, Collins FS, Brown JD, Liu DR. In vivo base editing rescues Hutchinson-Gilford progeria syndrome in mice. *Nature* 2021; **589**: 608-614 [PMID: [33408413](#) DOI: [10.1038/s41586-020-03086-7](#)]
 - 20 **Lai WF,** Wong WT. Progress and trends in the development of therapies for Hutchinson-Gilford progeria syndrome. *Aging Cell* 2020; **19**: e13175 [PMID: [32596971](#) DOI: [10.1111/ace1.13175](#)]



Published by **Baishideng Publishing Group Inc**
7041 Koll Center Parkway, Suite 160, Pleasanton, CA 94566, USA

Telephone: +1-925-3991568

E-mail: bpgoffice@wjgnet.com

Help Desk: <https://www.f6publishing.com/helpdesk>

<https://www.wjgnet.com>

