

# World Journal of *Gastrointestinal Surgery*

*World J Gastrointest Surg* 2022 June 27; 14(6): 528-631



## Contents

Monthly Volume 14 Number 6 June 27, 2022

## MINIREVIEWS

- 528 Transarterial chemoembolization failure/refractoriness: A scientific concept or pseudo-proposition  
*Zhang S, Zhong BY, Zhang L, Wang WS, Ni CF*
- 538 Indications for the surgical management of pancreatic trauma: An update  
*Pavlidis ET, Psarras K, Symeonidis NG, Geropoulos G, Pavlidis TE*
- 544 Clinical application and research progress of extracellular slow wave recording in the gastrointestinal tract  
*Ding F, Guo R, Cui ZY, Hu H, Zhao G*

## ORIGINAL ARTICLE

## Retrospective Cohort Study

- 556 Predicting the outcome of closed-loop small bowel obstruction by preoperative characteristics  
*Toneman MK, de Kok BM, Zijta FM, Oei S, van Acker GJD, Westerterp M, van der Pool AEM*
- 567 Transjugular intrahepatic portosystemic shunt with radioactive seed strand for main portal vein tumor thrombosis with cirrhotic portal hypertension  
*Yan XH, Yue ZD, Zhao HW, Wang L, Fan ZH, Wu YF, Meng MM, Zhang K, Jiang L, Ding HG, Zhang YN, Yang YP, Liu FQ*

## Retrospective Study

- 580 Prognostic significance of the preoperative hemoglobin to albumin ratio for the short-term survival of gastric cancer patients  
*Hu CG, Hu BE, Zhu JF, Zhu ZM, Huang C*

## META-ANALYSIS

- 594 Comparison between laparoscopic uncut Roux-en-Y and Billroth II with Braun anastomosis after distal gastrectomy: A meta-analysis  
*Jiao YJ, Lu TT, Liu DM, Xiang X, Wang LL, Ma SX, Wang YF, Chen YQ, Yang KH, Cai H*

## CASE REPORT

- 611 Intestinal perforation with abdominal abscess caused by extramedullary plasmacytoma of small intestine: A case report and literature review  
*Wang KW, Xiao N*
- 621 Bowel intussusception caused by a percutaneously placed endoscopic gastrojejunostomy catheter: A case report  
*Winters MW, Kramer S, Mazairac AH, Jutte EH, van Putten PG*

**LETTER TO THE EDITOR**

- 626** Important role of acute care surgery during pandemic time  
*Yang M, Zhang CY*
- 629** Advances and effectiveness of the immunotherapy after liver transplantation  
*Vulasala SSR, Onteddu NK, Kumar SP, Lall C, Bhosale P, Virarkar MK*

### ABOUT COVER

Editorial Board Member of *World Journal of Gastrointestinal Surgery*, Arun Prasad, FACS, FRCS (Ed), FRCS (Gen Surg), MBBS, Adjunct Professor, Doctor, Professor, Surgeon, Department of Minimal Access, Thoracoscopic, Bariatric and Robotic Surgery, Apollo Hospital, New Delhi 110044, India. surgerytimes@gmail.com

### AIMS AND SCOPE

The primary aim of *World Journal of Gastrointestinal Surgery* (WJGS, *World J Gastrointest Surg*) is to provide scholars and readers from various fields of gastrointestinal surgery with a platform to publish high-quality basic and clinical research articles and communicate their research findings online.

WJGS mainly publishes articles reporting research results and findings obtained in the field of gastrointestinal surgery and covering a wide range of topics including biliary tract surgical procedures, biliopancreatic diversion, colectomy, esophagectomy, esophagostomy, pancreas transplantation, and pancreatectomy, etc.

### INDEXING/ABSTRACTING

The WJGS is now abstracted and indexed in Science Citation Index Expanded (SCIE, also known as SciSearch®), Current Contents/Clinical Medicine, Journal Citation Reports/Science Edition, PubMed, PubMed Central, Reference Citation Analysis, China National Knowledge Infrastructure, China Science and Technology Journal Database, and Superstar Journals Database. The 2022 Edition of Journal Citation Reports® cites the 2021 impact factor (IF) for WJGS as 2.505; IF without journal self cites: 2.473; 5-year IF: 3.099; Journal Citation Indicator: 0.49; Ranking: 104 among 211 journals in surgery; Quartile category: Q2; Ranking: 81 among 93 journals in gastroenterology and hepatology; and Quartile category: Q4.

### RESPONSIBLE EDITORS FOR THIS ISSUE

**Production Editor:** Rui-Rui Wu; **Production Department Director:** Xiang Li; **Editorial Office Director:** Ya-Juan Ma.

#### NAME OF JOURNAL

*World Journal of Gastrointestinal Surgery*

#### ISSN

ISSN 1948-9366 (online)

#### LAUNCH DATE

November 30, 2009

#### FREQUENCY

Monthly

#### EDITORS-IN-CHIEF

Peter Schemmer

#### EDITORIAL BOARD MEMBERS

<https://www.wjgnet.com/1948-9366/editorialboard.htm>

#### PUBLICATION DATE

June 27, 2022

#### COPYRIGHT

© 2022 Baishideng Publishing Group Inc

#### INSTRUCTIONS TO AUTHORS

<https://www.wjgnet.com/bpg/gerinfo/204>

#### GUIDELINES FOR ETHICS DOCUMENTS

<https://www.wjgnet.com/bpg/GerInfo/287>

#### GUIDELINES FOR NON-NATIVE SPEAKERS OF ENGLISH

<https://www.wjgnet.com/bpg/gerinfo/240>

#### PUBLICATION ETHICS

<https://www.wjgnet.com/bpg/GerInfo/288>

#### PUBLICATION MISCONDUCT

<https://www.wjgnet.com/bpg/gerinfo/208>

#### ARTICLE PROCESSING CHARGE

<https://www.wjgnet.com/bpg/gerinfo/242>

#### STEPS FOR SUBMITTING MANUSCRIPTS

<https://www.wjgnet.com/bpg/GerInfo/239>

#### ONLINE SUBMISSION

<https://www.f6publishing.com>



Retrospective Cohort Study

# Transjugular intrahepatic portosystemic shunt with radioactive seed strand for main portal vein tumor thrombosis with cirrhotic portal hypertension

Xuan-Hui Yan, Zhen-Dong Yue, Hong-Wei Zhao, Lei Wang, Zhen-Hua Fan, Yi-Fan Wu, Ming-Ming Meng, Ke Zhang, Li Jiang, Hui-Guo Ding, Yue-Ning Zhang, Yong-Ping Yang, Fu-Quan Liu

**Specialty type:** Gastroenterology and hepatology

**Provenance and peer review:**

Unsolicited article; Externally peer reviewed.

**Peer-review model:** Single blind

**Peer-review report's scientific quality classification**

Grade A (Excellent): A  
Grade B (Very good): 0  
Grade C (Good): C, C, C  
Grade D (Fair): 0  
Grade E (Poor): 0

**P-Reviewer:** Lidofsky S, United States; Maslennikov R, Russia  
**A-Editor:** Yao QG, China

**Received:** December 1, 2021

**Peer-review started:** December 1, 2021

**First decision:** April 16, 2022

**Revised:** April 21, 2022

**Accepted:** May 21, 2022

**Article in press:** May 21, 2022

**Published online:** June 27, 2022



**Xuan-Hui Yan, Fu-Quan Liu,** Department of Interventional Therapy, Peking University Ninth School of Clinical Medicine, Beijing Shijitan Hospital, Beijing 100038, China

**Zhen-Dong Yue, Lei Wang, Zhen-Hua Fan, Yi-Fan Wu, Fu-Quan Liu,** Department of Interventional Therapy, Beijing Shijitan Hospital, Capital Medical University, Beijing 100038, China

**Hong-Wei Zhao,** Department of Interventional Therapy, Beijing Tongren Hospital, Capital Medical University, Beijing 100005, China

**Ming-Ming Meng,** Department of Gastroenterology, Beijing Shijitan Hospital, Capital Medical University, Beijing 100038, China

**Ke Zhang, Li Jiang,** Department of General Surgery, Beijing Ditan Hospital, Capital Medical University, Beijing 100102, China

**Hui-Guo Ding,** Department of Gastroenterology, Beijing You'an Hospital, Capital Medical University, Beijing 100069, China

**Yue-Ning Zhang,** Department of Liver Disease Digestion Center, Beijing You'an Hospital, Capital Medical University, Beijing 100069, China

**Yong-Ping Yang,** Department of Liver Disease, The Fifth Medical Center of Chinese PLA General Hospital, Beijing 100039, China

**Corresponding author:** Fu-Quan Liu, BCPS, MD, Director, Professor, Department of Interventional Therapy, Peking University Ninth School of Clinical Medicine, Beijing Shijitan Hospital, No. 10 Tie Yi Road, Yangfangdian, Haidian District, Beijing 100038, China.

[lfuquan@aliyun.com](mailto:lfuquan@aliyun.com)

## Abstract

### BACKGROUND

Patients with hepatocellular carcinoma complicated with main portal vein tumor thrombosis (mpVTT) and cirrhotic portal hypertension (CPH) have an extremely poor prognosis, and there is a lack of a clinically effective treatment paradigm.

### AIM



To evaluate the efficacy and safety of transjugular intrahepatic portosystemic shunt (TIPS) combined with radioactive seed strand for the treatment of mPVTT patients with CPH.

## METHODS

The clinical data of 83 consecutive patients who underwent TIPS combined with  $^{125}\text{I}$  seed strand placement for mPVTT and CPH from January 2015 to December 2018 were retrospectively reviewed. Procedure-related data (success rate, relief of portal vein pressure and CPH symptoms, and adverse events), PVTT response, and patient survival were assessed through a 2-year follow-up.

## RESULTS

The success rate was 100.0% without perioperative death or procedure-related severe adverse events. The mean portal vein pressure was significantly decreased after the procedure ( $22.25 \pm 7.33$  mmHg *vs*  $35.12 \pm 7.94$  mmHg,  $t = 20.61$ ,  $P < 0.001$ ). The symptoms of CPH were all effectively relieved within 1 mo. The objective response rate of PVTT was 67.5%. During a mean follow-up of  $14.5 \pm 9.4$  mo (range 1-37 mo), the cumulative survival rates at 6, 12 and 24 mo were 83.1%, 49.7%, and 21.8%, respectively. The median survival time was  $12.0 \pm 1.3$  mo (95% confidence interval: 9.5-14.5). In multivariate Cox regression analysis, body mass index, Child-Pugh grade, cTNM stage, and PVTT response were independent prognostic factors ( $P < 0.05$ ).

## CONCLUSION

TIPS combined with radioactive seed strand might be effective and safe in treating mPVTT patients with CPH.

**Key Words:** Transjugular intrahepatic portosystemic shunt; Radioactive seed strand; Portal vein tumor thrombosis; Hepatocellular carcinoma; Cirrhotic portal hypertension; Cirrhosis

©The Author(s) 2022. Published by Baishideng Publishing Group Inc. All rights reserved.

**Core Tip:** We adequately evaluated whether transjugular intrahepatic portosystemic shunt combined with radioactive seed strand placement was safe in adverse events and effective in portal vein tumor thrombosis response and prolonging survival time for the treatment of patients with main portal vein tumor thrombosis and cirrhotic portal hypertension through a retrospective cohort study with 2 years of follow-up.

**Citation:** Yan XH, Yue ZD, Zhao HW, Wang L, Fan ZH, Wu YF, Meng MM, Zhang K, Jiang L, Ding HG, Zhang YN, Yang YP, Liu FQ. Transjugular intrahepatic portosystemic shunt with radioactive seed strand for main portal vein tumor thrombosis with cirrhotic portal hypertension. *World J Gastrointest Surg* 2022; 14(6): 567-579

**URL:** <https://www.wjgnet.com/1948-9366/full/v14/i6/567.htm>

**DOI:** <https://dx.doi.org/10.4240/wjgs.v14.i6.567>

## INTRODUCTION

Portal vein tumor thrombosis (PVTT) is common in patients with hepatocellular carcinoma (HCC), with an incidence of 44.0%-62.2%[1]. Main PVTT (mPVTT) is defined as PVTT invading the main trunk of the portal vein, accounting for approximately 19.5%-35.2% of PVTT[2-4]. The prognosis of patients with PVTT is poor and the median overall survival is only 2.7-4.0 mo without treatment[5].

HCC is mostly based on cirrhosis, and is usually complicated with cirrhotic portal hypertension (CPH). The decompensated stage of CPH is often accompanied by high-mortality events, *e.g.*, esophago-gastric variceal bleeding (EGVB) and refractory ascites/hydrothorax. EGVB is associated with a mortality of 10%-20% at 6 wk[6], and refractory ascites is associated with a reduction in the survival rate to 50% at 6 mo[7]. Once PVTT is combined with cirrhosis-related decompensated events, it would worsen the disease and accelerate the death of patients.

The treatment strategies for PVTT include palliative surgical resection, transarterial chemoembolization (TACE), external radiotherapy, chemotherapy, and targeted therapy[2,8,9], but these treatments are usually infeasible and unsatisfactory in patients with decompensated CPH. Transjugular intrahepatic portosystemic shunt (TIPS) is an effective treatment for CPH[10,11] and eliminates pylephraxis with the covered stent, but the stent has no substantial therapeutic effect on mPVTT and results in PVTT progression and stent stenosis.

In recent years, the application of radioactive seed placement, such as the low-energy radionuclide  $^{125}\text{I}$  [12-14], has attracted attention and achieved promising efficacy when combined with portal vein stents. Radioactive seed strand placement is one method of endovascular brachytherapy. The purpose of this study was to retrospectively analyze the clinical efficacy of TIPS combined with radioactive seed strand placement for mPVTT patients with CPH from January 2015 to December 2018.

## MATERIALS AND METHODS

### Participants

The study was approved by the Ethics Committee and Institutional Review Board of Peking University Ninth School of Clinical Medicine. A consecutive cohort of 83 patients with HCC who underwent TIPS combined with  $^{125}\text{I}$  seed strand placement for mPVTT and CPH from January 2015 to December 2018 was retrospectively reviewed. Patients with incomplete clinical data or loss to follow-up were excluded from the analysis. Among 81 patients, 70 (84.3%) were males and 13 (15.7%) were females, aged 35-79 years (mean 56.46 years). There were 62 (74.7%) cases of EGVB, 14 (16.9%) cases of refractory ascites/hydrothorax, and 7 (8.4%) cases of both. Child-Pugh grading included 23 (27.7%) cases with grade A, 52 (62.7%) cases with grade B, and 8 (9.6%) cases with grade C. According to cTNM staging, 55 (66.3%) cases were stage IIIB, 19 (22.9%) cases were stage IVA, and 9 (10.8%) cases were stage IVB. The baseline characteristics of the patients are presented in Table 1.

### Study design

Procedure-related data [success rate, relief of portal vein pressure (PVP) and CPH symptoms, and adverse events], mPVTT response, and patient survival were assessed through a 2-year follow-up. The success rate was defined by the planned stent and seed successfully placed. PVTT response was determined according to the modified Response Evaluation Criteria in Solid Tumors (mRECIST)[15] by experienced radiologists: (1) Complete response (CR) was defined as disappearance of PVTT; (2) Partial response (PR) was a  $\geq 30\%$  reduction of the PVTT lesion compared with baseline; (3) Progressive disease (PD) was defined as  $\geq 20\%$  enlargement of the PVTT lesion than baseline; (4) Stable disease (SD) referred to the PVTT lesion that did not reach the standard of PR and PD. The objective response rate (ORR) of PVTT was the sum of CR and PR. Patient survival was defined as the period from the day of operation to patient death from any cause or to the last follow-up time point.

Adverse events were classified as shunt-related adverse events and radiation-related adverse events. Shunt-related adverse events consisted of post-TIPS hepatic encephalopathy (HE), the recurrence of CPH, shunt stenosis, and shunt-induced potential distant metastasis. The recurrence of CPH was determined as recurrent EGVB or hepatic ascites/hydrothorax, which principally resulted from shunt or intra-stent stenosis. Shunt stenosis was indicated by the recurrence of CPH events and confirmed by imaging [e.g., enhanced computed tomography (CT) or portal venography]. Shunt-induced potential distant metastasis was defined as new-onset hematogenous metastasis after shunt opening of TIPS, which was diagnosed by systemic imaging or pathology. Radiation-related adverse events included radiation injury and seed strand or  $^{125}\text{I}$  seed translocation.

### TIPS combined with transcatheter radioactive seed strand placement

All patients were fully evaluated before the procedure: (1) The severity of esophagogastric varices (EGV) was graded by gastroscopy; (2) The degree of ascites was graded by ultrasound examination[16]; (3) Child-Pugh was used for evaluation of liver function; (4) Tumors were staged according to both the international Barcelona Clinic Liver Cancer (BCLC) staging system[17] and cTNM staging system[18]; and (5) intrahepatic tumor size was determined as the sum of the longest viable tumor diameters of typical intrahepatic target lesions according to mRECIST[15], measured by experienced radiologists.

The indications for the procedure were as follows: (1) mPVTT secondary to HCC, as confirmed by percutaneous biopsy or enhanced CT/magnetic resonance imaging /positron emission tomography imaging; (2) Intrahepatic CPH confirmed by imaging examinations and hepatic venous pressure gradient (HVPG) measurement; (3) Failure of prior conservative treatment for cirrhosis-related decompensated events such as EGVB or refractory ascites/hydrothorax; and (4) Life expectancy > 2 mo. The contraindications were any one of the following: (1) Uncomplicated prehepatic portal hypertension; (2) Severe cardiac, cerebral, respiratory, renal insufficiency or other systemic malignancy; (3) Rapid progression in hepatic insufficiency; (4) Intrahepatic tumor hampering the procedure; (5) Allergy to contrast agent; and (6) Pregnancy or lactation. The operation was performed by interventional physicians with more than 15 years of experience. The benefits and potential risks of the procedure were explained thoroughly to all patients and their families, and then, written informed consent was signed.

During the procedure, the right internal jugular vein was punctured routinely under local anesthesia. After intubation to the inferior vena cava and hepatic vein, HVPG was measured, and then RUPS-100 (Cook Inc., United States) was inserted. According to preoperative imaging and angiography, the appropriate position and angle were determined to puncture the intrahepatic portal vein from the hepatic vein or inferior vena cava of the hepatic segment. After successful puncture, an angiographic

**Table 1** Baseline characteristics of patients

Characteristics	n (%) / mean $\pm$ SD / M (P <sub>25</sub> -P <sub>75</sub> )
Gender (male/female)	70/13 (84.3/15.7)
Age (yr)	56.46 $\pm$ 8.97
BMI	22.83 $\pm$ 2.99
Etiology of cirrhosis (HBV/HCV/alcoholic/other)	66/8/4/5 (79.5/9.6/4.8/6.0)
Cirrhosis-related decompensated events (EGVB/Refractory ascites or hydrothorax/Both)	62/14/7 (74.7/16.9/8.4)
EGV degree (mild/moderate/severe)	7/36/40 (8.4/43.4/48.2)
Ascites degree (no/mild/moderate-severe)	8/24/51 (9.6/28.9/61.4)
Preoperative HVPG (mmHg)	19.96 $\pm$ 9.01
Child-Pugh grade (A/B/C)	23/52/8 (27.7/62.7/9.6)
Intrahepatic HCC morphology (unifocal/multifocal)	47/36 (56.6/43.4)
Sum of longest viable tumor diameters (cm)	6.62 $\pm$ 2.77
$\leq 5$ /5-8/ $> 8$	23/44/16 (27.7/53.0/19.3)
BCLC stage (C/D)	75/8 (90.4/9.6)
cTNM stage (IIIB/IVA/IVB)	55/19/9 (66.3/22.9/10.8)
PLT (10 <sup>9</sup> /L)	108.24 $\pm$ 86.09
PT (s)	14.89 $\pm$ 3.89
ALT (U/L)	31.40 $\pm$ 29.29
AST (U/L)	49.63 $\pm$ 45.00
TBil ( $\mu$ mol/L)	31.74 $\pm$ 17.68
Albumin (g/L)	35.08 $\pm$ 4.85
AFP (ng/mL) <sup>1</sup>	769.49 (16.69-2345.11)
Log <sub>10</sub> (AFP)	2.40 $\pm$ 1.26
Combined TACE/RFA/targeted therapy	83/52/41 (100/62.7/49.4)

<sup>1</sup>Skewness distribution. The upper limit of AFP detection is 20000 ng/mL. BMI: Body mass index; HBV: Hepatitis B virus; HCV: Hepatitis C virus; EGVB: Esophagogastric variceal bleeding; EGV: Esophagogastric varices; HVPG: Hepatic venous pressure gradient; HCC: Hepatocellular carcinoma; PLT: Platelet; PT: Prothrombin time; ALT: Alanine aminotransferase; AST: Aspartate aminotransferase; TBil: Total bilirubin; AFP: Alpha-fetoprotein; TACE: Transarterial chemoembolization; RFA: Radiofrequency ablation.

catheter was inserted for portal venography, and the puncture set was placed into the intrahepatic portal vein.


Before shunting, PVP was measured, and then PVTT was grabbed and aspirated as much as possible. Two ultrasheath guidewires were inserted through the outer sheath of RUPS-100, one of which was retained in the splenic vein, and the other introduced a 4-5F single-bend or cobra catheter that was selected to the distal end of branch PVTT. Then, a 6F guiding catheter was replaced, and a radioactive seed strand was implanted *via* the guiding catheter. Next, a 6-8 mm balloon was introduced through the outer sheath to dilate the shunt, and then a 7-8 mm Fluency covered stent (Bard Inc., United States) was placed. According to the extent of mPVTT, a distal 10-12 mm covered stent was placed for the entire coverage of mPVTT.

The radioactive seed (Isotope & Radiation Corp., China) was fully loaded into a 4F catheter in vitro, creating the radioactive seed strand (Figure 1). Then, the radioactive seed strand was placed outside the stents *via* a 6F guiding catheter (by the guidewire retained in the splenic vein). The radioactive seed strand was compressed and fixed to the portal vein by the stents. The length of the radioactive seed strand was usually more than 10 mm at both ends of the PVTT. Finally, PVP after shunting was measured, and portal venography was performed again (Figure 2).

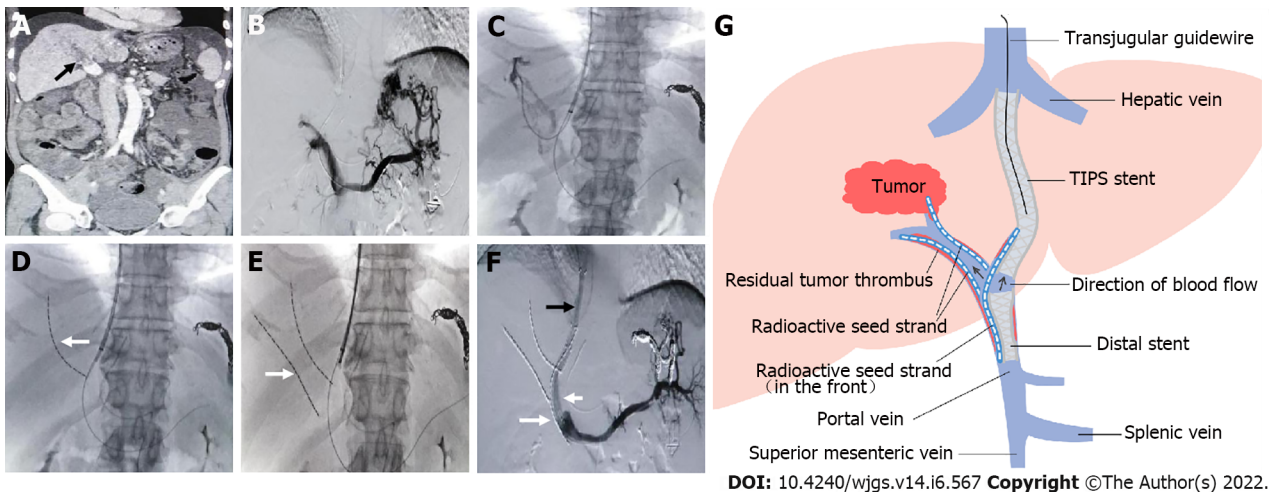
### Treatment for HCC

TACE was used for intrahepatic tumors and PVTT lesions every 1-3 mo by using an embolic agent (lipiodol 3-30 mL) and chemotherapy drugs (epirubicin 10-20 mg and hydroxycamptothecine 5-15 mg).





DOI: 10.4240/wjgs.v14.i6.567 Copyright ©The Author(s) 2022.

Figure 1 Assembly of a radioactive seed strand *in vitro*.

DOI: 10.4240/wjgs.v14.i6.567 Copyright ©The Author(s) 2022.

**Figure 2 Representative case.** A: Filling defect in the main portal vein (black arrow), suggesting main portal vein tumor thrombosis; B: Most of the intrahepatic branches did not develop under contrast, and several short gastric veins were obviously varicose; C and D: A guidewire was retained in the splenic vein, a catheter was directed into the secondary branch of the right portal vein, and then a radioactive seed strand (white arrow) was implanted; E: Another radioactive seed strand (white arrow) was implanted into another secondary branch of the right portal vein; F: A shunt of transjugular intrahepatic portosystemic shunt (black arrow) was established, a distal stent (short white arrow) was placed, and then a radioactive seed strand (long white arrow) was implanted. Portal venography showed unobstructed blood flow in the shunt and obvious reduction in the varicose veins; G: Schematic diagram. TIPS: Transjugular intrahepatic portosystemic shunt.

TACE was performed in all patients (ranging from 1-12 times per patient and an average of 4.2 times).

Radiofrequency ablation (RFA) was also carried out for intrahepatic tumors in patients with good coagulation function and platelet count and the inability to sequentially undergo TACE due to arterial occlusion after repeated arterial intervention. The RFA equipment was WHK-IB, Beijing Welfare Electronics Co., China. 52 of 83 patients underwent RFA (ranging from 1-3 times per patient and an average of 1.6 times).

According to patients' specific conditions and wishes, 41 patients received targeted therapy such as sorafenib or lenvatinib.

### Follow-up

All patients were followed up by telephone at a 4-6-wk interval postoperatively until death or their last follow-up. At 3, 6, 12, and 24 mo after the operation, patients were required to undergo a hospital revisit to assess PVTT response and adverse events. Sequential TACE or RFA was performed on the intrahepatic primary lesions. In addition, positive and timely management was given for adverse events such as post-TIPS HE, shunt stenosis, and recurrence of CPH.

### Statistical analysis

Continuous variables conforming to a normal distribution are presented as the mean  $\pm$  SD and median (interquartile range) [M (P<sub>25</sub>-P<sub>75</sub>)] for those with a nonnormal distribution. Categorical variables are presented as percentages (%). The mean values of two related samples were compared by using the paired samples *t* test. In survival analysis, the Kaplan-Meier curve was performed for description, the log-rank test was utilized for comparison, and Cox regression was carried out for correlated factor analysis. Variables satisfying the proportional hazards assumption were included in the multivariate analysis using Cox regression. *P* < 0.05 was considered a statistically significant difference. IBM SPSS software version 26.0 was used for statistical analysis.

## RESULTS

### Procedure-related data

The success rate of the procedure was 100.0% (83/83), without perioperative death or procedure-related serious adverse events. The number of implanted seeds ranged from 29 to 95, with an average of 47 per patient. The mean PVP was significantly decreased after the procedure ( $22.25 \pm 7.33$  mmHg *vs*  $35.12 \pm 7.94$  mmHg, *t* = 20.61, *P* < 0.001). The symptoms of CPH, including EGV and/or refractory ascites/hydrothorax, were all effectively relieved within 1 mo.

The mean follow-up period was  $14.5 \pm 9.4$  mo (range 1-37 mo). HE developed in a total of 16 patients (19.3%) after the procedure, most of whom had mild HE in clinical stages 1-2. The cumulative recurrence rates of CPH at 6, 12, and 24 mo were 9.6% (8/83), 22.9% (19/83), and 33.7% (28/83), respectively. The cumulative rates of shunt stenosis at 6, 12, and 24 mo were 13.3% (11/83), 28.9% (24/83), and 38.6% (32/83), respectively (Table 2). During follow-up, no seed strand shift or <sup>125</sup>I seed fall-off and translocation occurred, and no radiation injury (such as radiation-induced liver disease or gastrointestinal ulceration) was observed.

### PVTT response

Four patients failed to be assessed on account of death within 2 mo. The ORR of PVTT was 67.5% (Table 3). Among patients who presented PD, all 6 cases related to PVTT exceeded the distal portal system, *e.g.*, the mesenteric vein or splenic vein.

### Patient survival

The Kaplan-Meier survival curve is shown in Figure 3. The median survival time was  $12.0 \pm 1.3$  mo [95% confidence interval (CI): 9.5-14.5]. The cumulative survival rates at 6, 12, and 24 mo were 83.1%, 49.7%, and 21.8%, respectively.

In the stratification analysis using the survival curves and log-rank test, patients with age < 60, Child-Pugh grade A or B, BCLC stage C, cTNM stage IIIB or IVA, and PVTT response had significant survival benefits (*P* < 0.05) in the comparison of their respective groups (Figure 4 and Table 4). Notably, cTNM staging showed a more detailed stratification capability than BCLC staging.

In Cox regression analysis, the relevant parameters including body mass index (BMI), Child-Pugh grade, cTNM stage, and PVTT response, were independent prognostic factors as indicated in the multivariate Cox regression model (Table 5).

## DISCUSSION

With the development of multidisciplinary teamwork, HCC complicated with PVTT has attracted increasing interest and research. Owing to the biological characteristics of HCC and anatomical features of the liver, HCC cells tend to invade the intrahepatic vasculature, especially the portal venous system [19]. In the past few years, the application of <sup>125</sup>I seeds [12-14] has provided a new therapy for advanced HCC. In our study, the ORR of PVTT reached 67.5% after <sup>125</sup>I seed strand placement. In multivariate survival analysis, PVTT response had a significant effect on patient survival, which could reduce the risk of death [hazard ratio (HR) = 0.472]. Additionally, no radiation injury was observed during postoperative follow-up. In short, radioactive seed strand placement may be an effective approach for the local treatment of PVTT.

It is a biological effect of ionizing radiation that <sup>125</sup>I relies on by continuously releasing low-energy  $\gamma$  rays to kill tumor cells and then achieve the purpose of treatment. With a half-value layer of only 17 mm in equivalent tissue, <sup>125</sup>I rarely involves adjacent tissues or organs. Thus, radioactive seed strand placement has the advantages of a high local dose to the tumor thrombus and less damage to normal tissues.

In addition, radioactive seed strands also have the following advantages: first, the length of the seed strand can be determined according to the length of the tumor thrombus, and the seeds in the catheter are arranged neatly; second, the seed strand implanted in the portal vein branch does not shift, nor does

**Table 2 Summary of long-term efficacy and safety**

Items	6 mo	12 mo	24 mo
Cumulative survival rate (%)	83.1	49.7	21.8
Cumulative rate of shunt stenosis (%)	13.3	28.9	38.6
Cumulative recurrence rate of CPH (%)	9.6	22.9	33.7

CPH: Cirrhotic portal hypertension.

**Table 3 Summary of portal vein tumor thrombosis response in short-term efficacy**

PVTT response	CR	PR	SD	PD	Response (ORR)
Number (%)	15 (18.1)	41 (49.4)	17 (20.5)	6 (7.2)	56 (67.5)

PVTT: Portal vein tumor thrombosis; CR: Complete response; PR: Partial response; SD: Stable disease; PD: Progressive disease; ORR: Objective response rate.

**Table 4 Summary of survival comparison of different stratification factors**

Stratification indicator	Log-rank $\chi^2$	P value
Gender	0.448	0.503
Age group	5.311	0.021
EGV degree	0.448	0.600
Ascites degree	1.308	0.520
Child-Pugh grade	15.810	< 0.001
Intrahepatic HCC morphology	0.174	0.677
Group of tumor diameters	1.685	0.431
BCLC stage	10.883	< 0.001
cTNM stage	51.774	< 0.001
Combined with RFA	0.275	0.600
Combined with targeted therapy	0.001	0.978
PVTT response	22.617	< 0.001
Post-TIPS HE	0.255	0.613
Shunt stenosis	0.027	0.868
Recurrence of CPH	0.235	0.628

EGV: Esophagogastric varices; HCC: Hepatocellular carcinoma; BCLC: Barcelona Clinic Liver Cancer; RFA: Radiofrequency ablation; PVTT: Portal vein tumor thrombosis; TIPS: Transjugular intrahepatic portosystemic shunt; HE: Hepatic encephalopathy; CPH: Cirrhotic portal hypertension.

the seed strand that is fixed in the main portal vein by stents; and finally, radioactive seed have antitumor and anti-intimal hyperplasia effects, which can prevent stent stenosis. However, as a drawback of this approach, when the diameter of the tumor thrombus is large, the effective radiation dose may not be achieved.

In clinical practice, the management of HCC patients with PVTT often neglects the effective diagnosis and treatment of CPH. PVTT patients complicated with CPH usually have an extremely poor prognosis. TIPS is an established treatment for CPH and its decompensated events by establishing a shunt between the intrahepatic portal vein and the hepatic vein or inferior vena cava. In our study, PVP was significantly reduced, and the symptoms of CPH were efficaciously relieved in mPVT patients with CPH after combined TIPS. Moreover, survival analysis showed that the severity of EGV and the degree of ascites had no significant impact on survival, which indirectly indicated the therapeutic effect of TIPS on decompensated CPH.

Table 5 Correlative factors for survival in univariate and multivariate analyses

Variable	Univariate analysis			Multivariate analysis		
	HR	95%CI	P value	HR	95%CI	P value
Gender (female/male)	1.237	0.650-2.355	0.518			
Age (years)	1.039	1.011-1.068	0.006			
BMI	0.781	0.701-0.871	< 0.001	0.861	0.768-0.965	0.010
EGV degree (mild/moderate/severe)	1.130	0.796-1.605	0.493			
Ascites degree (no/mild/moderate-severe)	1.055	0.760-1.464	0.748			
Preoperative HVPG (mmHg)	1.006	0.979-1.034	0.668			
Child-Pugh grade			< 0.001			
A/B	1.856	1.068-3.225	0.028	2.243	1.270-3.961	0.005
A/C	4.999	2.099-11.907	< 0.001	7.308	2.898-18.425	< 0.001
Intrahepatic HCC morphology (unifocal/multifocal)	0.909	0.570-1.447	0.687			
Sum of longest viable tumor diameters (cm)	1.070	0.988-1.158	0.097			
BCLC stage (C/D)	3.216	1.509-6.851	0.002			
cTNM stage (IIIB/IVA/IVB)	3.269	2.228-4.795	< 0.001	2.745	1.726-4.366	< 0.001
PLT (10 <sup>9</sup> /L)	1.000	0.997-1.003	0.917			
PT (s)	1.006	0.959-1.056	0.802			
ALT (U/L)	1.004	0.994-1.013	0.465			
AST (U/L)	1.003	0.998-1.008	0.173			
TBil (μmol/L)	1.022	1.008-1.035	0.001			
Albumin (g/L)	0.929	0.886-0.974	0.002			
Log <sub>10</sub> (AFP) (ng/mL)	1.341	1.097-1.639	0.004			
Combined RFA (no/yes)	0.885	0.552-1.419	0.612			
Combined targeted therapy (no/yes)	0.994	0.627-1.574	0.978			
Reduction of PVP (mmHg)	1.025	0.983-1.069	0.247			
PVTT response (nonresponse/response)	0.302	0.176-0.516	< 0.001	0.472	0.259-0.859	0.014
Post-TIPS HE (no/yes)	0.864	0.482-1.551	0.625			
Shunt stenosis (no/yes)	1.039	0.650-1.662	0.873			
Recurrence of CPH (no/yes)	1.122	0.694-1.814	0.639			

BMI: Body mass index; EGV: Esophagogastric varices; HVPG: Hepatic venous pressure gradient; HCC: Hepatocellular carcinoma; PLT: Platelet; PT: Prothrombin time; ALT: Alanine aminotransferase; AST: Aspartate aminotransferase; TBil: Total bilirubin; AFP: Alpha-fetoprotein; RFA: Radiofrequency ablation; PVP: Portal vein pressure; PVTT: Portal vein tumor thrombosis; TIPS: Transjugular intrahepatic portosystemic shunt; HE: Hepatic encephalopathy; CPH: Cirrhotic portal hypertension.

In addition, TIPS still has the following effects: first, it can improve liver functional reserve by improving portal blood supply to normal liver tissue and then prevent fatal liver failure caused by PVTT and provide favorable conditions for the subsequent treatment of intrahepatic primary lesions; next, the covered stent of TIPS plays a part in covering and compressing PVTT; and last, TIPS is able to resolve portal hypertension not only caused by cirrhosis but also due to the combination of intrahepatic cirrhosis and prehepatic PVTT[20,21].

TIPS combined with radioactive seed strand placement and sequential TACE/RFA for mPVTT with CPH may reduce the mortality risk from decompensated events of CPH (*i.e.*, nonneoplastic mortality risk) as well as reduce neoplastic mortality risk by controlling PVTT and primary lesions, prolonging survival. In our study, the median survival time of patients was 12.0 ± 1.3 mo (95%CI: 9.5-14.5), and the cumulative survival rates at 6, 12 and 24 mo were 83.1%, 49.7% and 21.8%, respectively. In a systematic



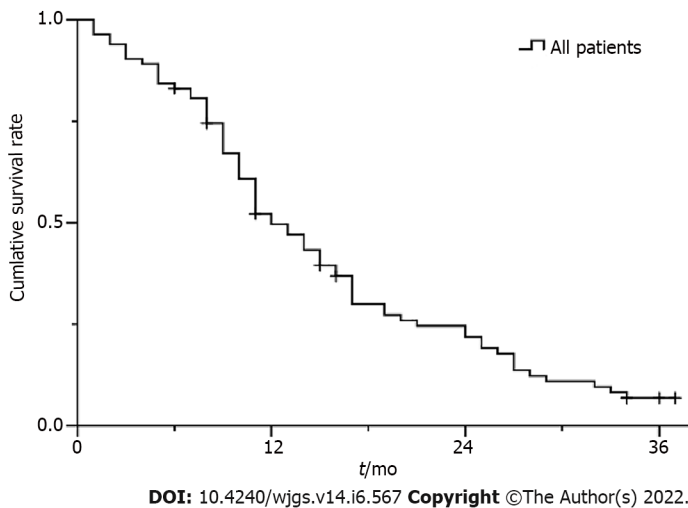


Figure 3 Kaplan-Meier survival curve for all patients.

review[13] of 6 retrospective studies involving mPVTT patients whose CPH was unclear, after percutaneous transhepatic  $^{125}\text{I}$  seed strand with stent placement combined with TACE, the median survival time was 10.3 mo (range 4.9-12.5 mo), and the cumulative survival rates at 6, 12 and 24 mo were 74.5% (range 61.8%-88.9%), 48.7% (range 32.4%-54.5%) and 20.1% (range 14.1%-26.1%), respectively. Huo *et al*[22] reported that in mPVTT patients partly mixed with CPH, the 2-year cumulative survival rate after palliative resection was 17.1%. Our results were similar to theirs. Despite similar survival results, it is necessary to differentiate and treat CPH in the management of PVTT or mPVTT patients.

In regard to postoperative long-term complications, our results showed that the cumulative rates of shunt stenosis at 6, 12 and 24 mo were 13.3%, 28.9% and 38.6%, respectively. Luo *et al*[23] and Yu *et al* [24] reported that after  $^{125}\text{I}$  seed strand with stent placement combined with TACE, the cumulative stent patency rates were 43.2% and 46.5% at 12 mo and 26.1% and 25.7% at 24 mo, respectively. Our results were clearly superior to theirs, which might be related to the following reasons: TIPS dredging the blood flow of the portal vein, full use of covered stents, and our postoperative anticoagulation treatment.

Furthermore, by survival analysis, shunt-related adverse events, including post-TIPS HE, shunt stenosis and recurrence of CPH, had no significant influence on survival, which might be related to the timely management of these complications, such as removal of HE inducements, balloon dilatation and/or stent reimplantation for shunt stenosis.

Regarding shunt-induced potential distant metastasis, 5 new cases of pulmonary metastasis and 1 new case of adrenal metastasis were observed. This small number of cases observed might be related to the censoring of death and the nonadherence of patients to the revisit and systematic examination. Further study is needed to expand the sample. However, it cannot be ignored that distant metastasis may be reduced to some extent by PVTT grab and aspiration before shunting, the entire coverage of mPVTT using covered stents, the PVTT response obtained by radioactive seed strand, and active intervention for intrahepatic lesions.

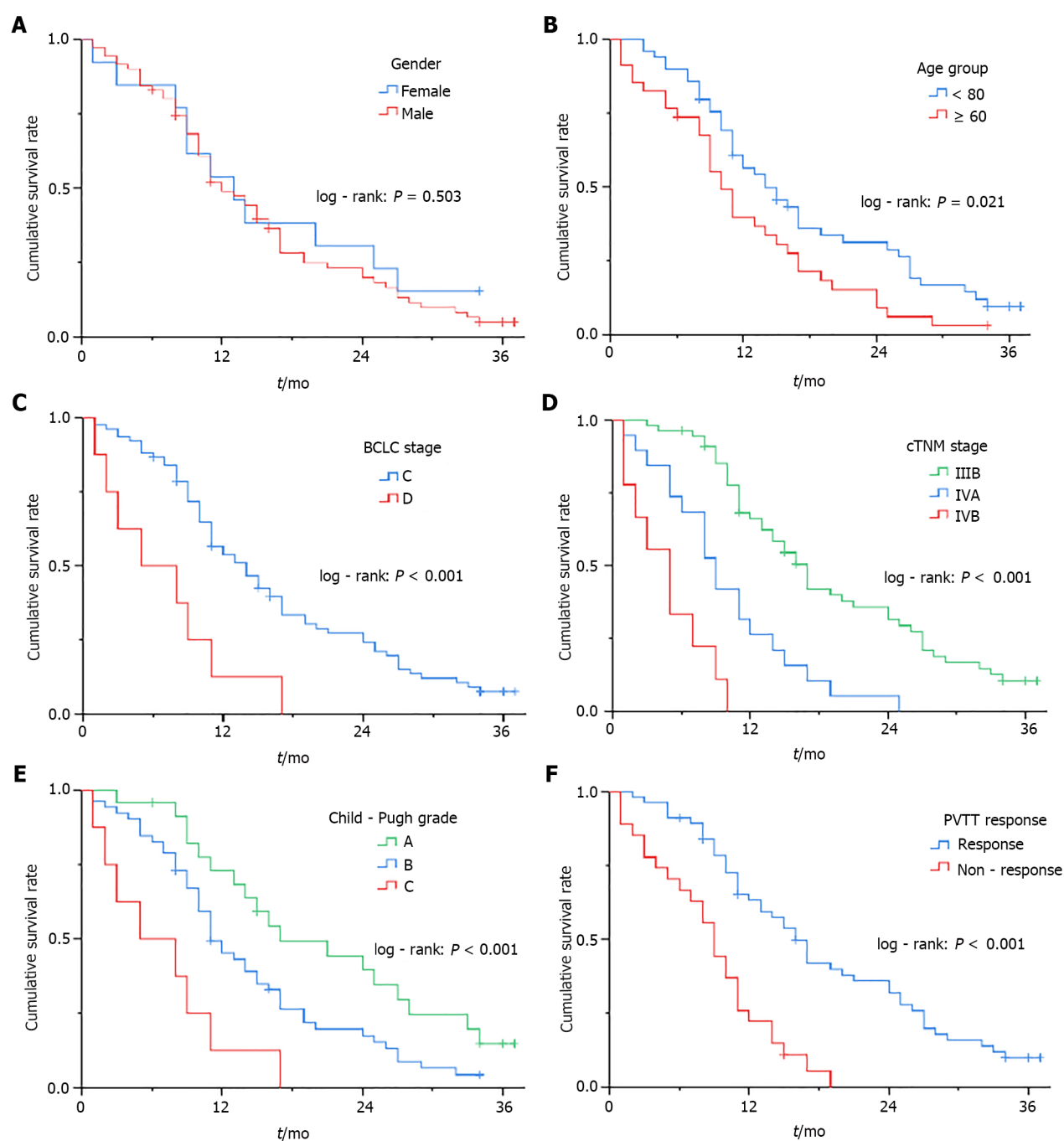
Among other factors that affected survival, cTNM staging showed a more detailed stratification capability than BCLC staging and showed an independent significant association with survival, with an increased risk of death for each increase in cTNM stage (HR = 2.745). Child-Pugh grade was an important factor affecting survival throughout, and the mortality risk in patients with grade C (HR = 7.308) and grade B (HR = 2.243) was much higher than those with grade A. Combining the Child-Pugh liver function grade and the cTNM tumor stage may be of great significance for the assessment of prognosis and survival.

Concerning other tumor-related factors, intrahepatic HCC morphology had no significant effect on survival, and the sum of longest viable tumor diameters approached significance, which might be related to active interventional treatment for intrahepatic primary lesions. Combined RFA was not significant, which might be related to RFA as an additional therapy after TACE for intrahepatic lesions. Combined targeted therapy was also not significant, and some high-quality studies[25,26] showed that targeted therapy did not achieve satisfactory outcomes in the treatment of HCC with PVTT.

BMI exerted a significant influence on survival (HR = 0.861). Patients with advanced HCC and decompensated cirrhosis often present malnutrition, so attention should be given to improving nutrition.

In addition, radioembolization was not used in combination therapy because it was not approved during the time of the study, but it could be considered for treatment in the future.





**Figure 4** Kaplan-Meier survival curve for different stratification factors. A: Gender group; B: Age group; C: Barcelona Clinic Liver Cancer stage; D: cTNM stage; E: Child-Pugh grade; F: Portal vein tumor thrombosis response). BCLC: Barcelona Clinic Liver Cancer; PVTT: Portal vein tumor thrombosis.

This single-arm retrospective cohort study has inherent limitations. Further relevant studies are warranted to follow and expand on the findings.

## CONCLUSION

In conclusion, the key points of this initial study may be summarized as follows: (1) TIPS combined with radioactive seed strand placement might be effective and safe in treating mPVTT with CPH, which could effectively alleviate symptoms of portal hypertension and prolong patient survival time; (2) In the management of PVTT or mPVTT patients, it is necessary to differentiate and effectively treat CPH; (3) Combining Child-Pugh liver function grade and cTNM tumor stage may be of guiding significance for the assessment of prognosis and survival.

## ARTICLE HIGHLIGHTS

### Research background

Main portal vein tumor thrombosis (mPVTT) is common in patients with hepatocellular carcinoma (HCC). Mostly based on cirrhosis, HCC is usually complicated with cirrhotic portal hypertension (CPH), which is often accompanied by high-mortality decompensated events such as esophagogastric variceal bleeding and refractory ascites/hydrothorax.

### Research motivation

HCC patients with PVTT have a poor prognosis with median survival of only 2.7-4.0 mo. Once mPVTT is combined with cirrhotic decompensated events, it would deteriorate the disease and accelerate the death of patients. However, there is a lack of a clinical treatment paradigm for mPVTT patients with CPH.

### Research objectives

This cohort study is to evaluate the efficacy and safety of transjugular intrahepatic portosystemic shunt (TIPS) combined with radioactive seed strand for the treatment of mPVTT complicated with CPH. It might contribute new perspectives into clinical treatment management.

### Research methods

The clinical data of 83 consecutive patients who underwent TIPS combined with <sup>125</sup>I seed strand placement for mPVTT and CPH from January 2015 to December 2018 were retrospectively reviewed, and the efficacy and safety were adequately evaluated by a 2-year follow-up.

### Research results

There was universal improvement in CPH and apparent relief of its decompensated complications after operation. The majority of patients had at least a decrease in the extent of PVTT and the objective response rate of PVTT was 67.5%. The cumulative rate of shunt stenosis and recurrence rate of CPH were low within the first year. The median survival time was 12.0 ± 1.3 mo (95% confidence interval: 9.5-14.5).

### Research conclusions

TIPS combined with radioactive seed strand might be effective and safe in the treatment of mPVTT with CPH, which could effectively alleviate symptoms of portal hypertension and prolong patient survival time.

### Research perspectives

In the management of HCC patients with PVTT or mPVTT, it is necessary to differentiate and effectively treat CPH. The treatment of mPVTT with CPH is still a clinical difficulty and requires multidisciplinary teamwork. Future studies may require randomized controlled trials to verify our results.

## FOOTNOTES

**Author contributions:** Liu FQ designed the research; Yue ZD, Zhao HW, Wang L, Fan ZH, Wu YF, Meng MM, Zhang K, Jiang L, Ding HG, Zhang YN and Yang YP performed the research; Yan XH analyzed the data and wrote the paper; Liu FQ reviewed and edited the manuscript; all authors read and approved the manuscript.

**Supported by** Beijing Municipal Science and Technology Commission project, The Capital of The Public Health Cultivation, No. Z17110000417031; The Capital Health Research and Development of Special, Beijing Municipal Health Commission, No. 2018-1-2081; and Scientific Research Common Program of Beijing Municipal Commission of Education, No. KM201810025028 (to Liu FQ).

**Institutional review board statement:** The study was reviewed and approved by the Ethics Committee and Institutional Review Board of Peking University Ninth School of Clinical Medicine.

**Informed consent statement:** All study participants or their legal guardians signed written informed consent forms.

**Conflict-of-interest statement:** All the authors report no relevant conflicts of interest for this article.

**Data sharing statement:** The datasets used and/or analyzed during the current study are available from the corresponding author on reasonable request.

**STROBE statement:** The authors have read the STROBE Statement-checklist of items, and the manuscript was

prepared and revised according to the STROBE Statement-checklist of items.

**Open-Access:** This article is an open-access article that was selected by an in-house editor and fully peer-reviewed by external reviewers. It is distributed in accordance with the Creative Commons Attribution NonCommercial (CC BY-NC 4.0) license, which permits others to distribute, remix, adapt, build upon this work non-commercially, and license their derivative works on different terms, provided the original work is properly cited and the use is non-commercial. See: <https://creativecommons.org/licenses/by-nc/4.0/>

**Country/Territory of origin:** China

**ORCID number:** Xuan-Hui Yan 0000-0003-1706-4847; Zhen-Dong Yue 0000-0001-5403-8336; Hong-Wei Zhao 0000-0001-6409-5537; Lei Wang 0000-0003-4080-1630; Zhen-Hua Fan 0000-0001-5417-1997; Yi-Fan Wu 0000-0003-2709-2729; Ming-Ming Meng 0000-0003-3560-1052; Ke Zhang 0000-0001-9803-138X; Li Jiang 0000-0001-6632-9229; Hui-Guo Ding 0000-0002-8716-4926; Yue-Ning Zhang 0000-0003-2205-3413; Yong-Ping Yang 0000-0002-8307-1095; Fu-Quan Liu 0000-0003-1972-7712.

**S-Editor:** Gao CC

**L-Editor:** A

**P-Editor:** Cai YX

## REFERENCES

- 1 **Zhang ZM**, Lai EC, Zhang C, Yu HW, Liu Z, Wan BJ, Liu LM, Tian ZH, Deng H, Sun QH, Chen XP. The strategies for treating primary hepatocellular carcinoma with portal vein tumor thrombus. *Int J Surg* 2015; **20**: 8-16 [PMID: 26026424 DOI: 10.1016/j.ijssu.2015.05.009]
- 2 **Chan SL**, Chong CC, Chan AW, Poon DM, Chok KS. Management of hepatocellular carcinoma with portal vein tumor thrombosis: Review and update at 2016. *World J Gastroenterol* 2016; **22**: 7289-7300 [PMID: 27621575 DOI: 10.3748/wjg.v22.i32.7289]
- 3 **Shi J**, Lai EC, Li N, Guo WX, Xue J, Lau WY, Wu MC, Cheng SQ. Surgical treatment of hepatocellular carcinoma with portal vein tumor thrombus. *Ann Surg Oncol* 2010; **17**: 2073-2080 [PMID: 20131013 DOI: 10.1245/s10434-010-0940-4]
- 4 **Wang K**, Guo WX, Chen MS, Mao YL, Sun BC, Shi J, Zhang YJ, Meng Y, Yang YF, Cong WM, Wu MC, Lau WY, Cheng SQ. Multimodality Treatment for Hepatocellular Carcinoma With Portal Vein Tumor Thrombus: A Large-Scale, Multicenter, Propensity Matching Score Analysis. *Medicine (Baltimore)* 2016; **95**: e3015 [PMID: 26986115 DOI: 10.1097/MD.0000000000003015]
- 5 **Kaneko S**, Tsuchiya K, Yasui Y, Inada K, Kirino S, Yamashita K, Osawa L, Hayakawa Y, Sekiguchi S, Higuchi M, Takaura K, Maeyashiki C, Tamaki N, Takeguchi T, Takeguchi Y, Nagano T, Nakanishi H, Itakura J, Takahashi Y, Himeno Y, Hoshi A, Kurosaki M, Izumi N. Strategy for advanced hepatocellular carcinoma based on liver function and portal vein tumor thrombosis. *Hepatol Res* 2020; **50**: 1375-1385 [PMID: 32924266 DOI: 10.1111/hepr.13567]
- 6 **de Franchis R**; Baveno VI Faculty. Expanding consensus in portal hypertension: Report of the Baveno VI Consensus Workshop: Stratifying risk and individualizing care for portal hypertension. *J Hepatol* 2015; **63**: 743-752 [PMID: 26047908 DOI: 10.1016/j.jhep.2015.05.022]
- 7 **Adebayo D**, Neong SF, Wong F. Refractory Ascites in Liver Cirrhosis. *Am J Gastroenterol* 2019; **114**: 40-47 [PMID: 29973706 DOI: 10.1038/s41395-018-0185-6]
- 8 **Liu PH**, Huo TI, Miksad RA. Hepatocellular Carcinoma with Portal Vein Tumor Involvement: Best Management Strategies. *Semin Liver Dis* 2018; **38**: 242-251 [PMID: 30041276 DOI: 10.1055/s-0038-1666805]
- 9 **Cerrito L**, Annicchiarico BE, Iezzi R, Gasbarrini A, Pompili M, Ponzianni FR. Treatment of hepatocellular carcinoma in patients with portal vein tumor thrombosis: Beyond the known frontiers. *World J Gastroenterol* 2019; **25**: 4360-4382 [PMID: 31496618 DOI: 10.3748/wjg.v25.i31.4360]
- 10 **Sankar K**, Moore CM. Transjugular Intrahepatic Portosystemic Shunts. *JAMA* 2017; **317**: 880 [PMID: 28245324 DOI: 10.1001/jama.2016.20899]
- 11 **Tripathi D**, Stanley AJ, Hayes PC, Travis S, Armstrong MJ, Tsochatzis EA, Rowe IA, Roslund N, Ireland H, Lomax M, Leithhead JA, Mehrzad H, Aspinall RJ, McDonagh J, Patch D. Transjugular intrahepatic portosystemic stent-shunt in the management of portal hypertension. *Gut* 2020; **69**: 1173-1192 [PMID: 32114503 DOI: 10.1136/gutjnl-2019-320221]
- 12 **Yuan D**, Gao Z, Zhao J, Zhang H, Wang J. <sup>125</sup>I seed implantation for hepatocellular carcinoma with portal vein tumor thrombus: A systematic review and meta-analysis. *Brachytherapy* 2019; **18**: 521-529 [PMID: 30954398 DOI: 10.1016/j.brachy.2019.01.014]
- 13 **Zhang L**, Hu B, Li W, Huang P, Zhang S, Zhong BY, Ni CF. <sup>125</sup>I Irradiation Stent for Hepatocellular Carcinoma with Main Portal Vein Tumor Thrombosis: A Systematic Review. *Cardiovasc Intervent Radiol* 2020; **43**: 196-203 [PMID: 31602496 DOI: 10.1007/s00270-019-02346-y]
- 14 **Li S**, Guo JH, Lu J, Wang C, Wu H, Wang H, Zha J, Fan R. <sup>125</sup>I irradiation stent for treatment of hepatocellular carcinoma with portal vein thrombosis: A meta-analysis. *Cancer Radiother* 2021; **25**: 340-349 [PMID: 33455874 DOI: 10.1016/j.canrad.2020.12.003]
- 15 **Lencioni R**, Llovet JM. Modified RECIST (mRECIST) assessment for hepatocellular carcinoma. *Semin Liver Dis* 2010; **30**: 52-60 [PMID: 20175033 DOI: 10.1055/s-0030-1247132]
- 16 **Moore KP**, Wong F, Gines P, Bernardi M, Ochs A, Salerno F, Angeli P, Porayko M, Moreau R, Garcia-Tsao G, Jimenez W, Planas R, Arroyo V. The management of ascites in cirrhosis: report on the consensus conference of the International

- Ascites Club. *Hepatology* 2003; **38**: 258-266 [PMID: [12830009](#) DOI: [10.1053/jhep.2003.50315](#)]
- 17 **European Association for the Study of the Liver.** EASL Clinical Practice Guidelines: Management of hepatocellular carcinoma. *J Hepatol* 2018; **69**: 182-236 [PMID: [29628281](#) DOI: [10.1016/j.jhep.2018.03.019](#)]
  - 18 **Chun YS,** Pawlik TM, Vauthey JN. 8th Edition of the AJCC Cancer Staging Manual: Pancreas and Hepatobiliary Cancers. *Ann Surg Oncol* 2018; **25**: 845-847 [PMID: [28752469](#) DOI: [10.1245/s10434-017-6025-x](#)]
  - 19 **Cheng S,** Chen M, Cai J, Sun J, Guo R, Bi X, Lau WY, Wu M. Chinese Expert Consensus on Multidisciplinary Diagnosis and Treatment of Hepatocellular Carcinoma with Portal Vein Tumor Thrombus (2018 Edition). *Liver Cancer* 2020; **9**: 28-40 [PMID: [32071907](#) DOI: [10.1159/000503685](#)]
  - 20 **Liu L,** Zhao Y, Qi X, Cai G, He C, Guo W, Yin Z, Chen H, Chen X, Fan D, Han G. Transjugular intrahepatic portosystemic shunt for symptomatic portal hypertension in hepatocellular carcinoma with portal vein tumor thrombosis. *Hepatol Res* 2014; **44**: 621-630 [PMID: [23679937](#) DOI: [10.1111/hepr.12162](#)]
  - 21 **Qiu B,** Li K, Dong X, Liu FQ. Transjugular Intrahepatic Portosystemic Shunt for Portal Hypertension in Hepatocellular Carcinoma with Portal Vein Tumor Thrombus. *Cardiovasc Intervent Radiol* 2017; **40**: 1372-1382 [PMID: [28488102](#) DOI: [10.1007/s00270-017-1655-8](#)]
  - 22 **Huo L,** Wei W, Yan Z, Lei Z, Xie Y, Gong R, Huang S, Jia N, Xia Y. Short-term and long-term outcomes of liver resection for HCC patients with portal vein tumor thrombus. *Cell Biosci* 2019; **9**: 23 [PMID: [30886700](#) DOI: [10.1186/s13578-019-0285-z](#)]
  - 23 **Luo JJ,** Zhang ZH, Liu QX, Zhang W, Wang JH, Yan ZP. Endovascular brachytherapy combined with stent placement and TACE for treatment of HCC with main portal vein tumor thrombus. *Hepatol Int* 2016; **10**: 185-195 [PMID: [26341514](#) DOI: [10.1007/s12072-015-9663-8](#)]
  - 24 **Yu TZ,** Zhang W, Liu QX, Li WH, Ma JQ, Zhang ZH, Yang MJ, Wang JH, Chen B, Zeng SC, Luo JJ, Liu LX, Yan ZP. Endovascular brachytherapy combined with portal vein stenting and transarterial chemoembolization improves overall survival of hepatocellular carcinoma patients with main portal vein tumor thrombus. *Oncotarget* 2017; **8**: 12108-12119 [PMID: [28076848](#) DOI: [10.18632/oncotarget.14520](#)]
  - 25 **Cheng AL,** Kang YK, Chen Z, Tsao CJ, Qin S, Kim JS, Luo R, Feng J, Ye S, Yang TS, Xu J, Sun Y, Liang H, Liu J, Wang J, Tak WY, Pan H, Burock K, Zou J, Voliotis D, Guan Z. Efficacy and safety of sorafenib in patients in the Asia-Pacific region with advanced hepatocellular carcinoma: a phase III randomised, double-blind, placebo-controlled trial. *Lancet Oncol* 2009; **10**: 25-34 [PMID: [19095497](#) DOI: [10.1016/S1470-2045\(08\)70285-7](#)]
  - 26 **Zhu K,** Chen J, Lai L, Meng X, Zhou B, Huang W, Cai M, Shan H. Hepatocellular carcinoma with portal vein tumor thrombus: treatment with transarterial chemoembolization combined with sorafenib--a retrospective controlled study. *Radiology* 2014; **272**: 284-293 [PMID: [24708192](#) DOI: [10.1148/radiol.14131946](#)]



Published by **Baishideng Publishing Group Inc**  
7041 Koll Center Parkway, Suite 160, Pleasanton, CA 94566, USA

**Telephone:** +1-925-3991568

**E-mail:** [bpgoffice@wjgnet.com](mailto:bpgoffice@wjgnet.com)

**Help Desk:** <https://www.f6publishing.com/helpdesk>

<https://www.wjgnet.com>

