

# World Journal of *Gastrointestinal Surgery*

*World J Gastrointest Surg* 2022 April 27; 14(4): 271-373



## Contents

Monthly Volume 14 Number 4 April 27, 2022

## DIAGNOSTIC AND THERAPEUTIC NORMS

- 271 Including video and novel parameter-height of penetration of external anal sphincter-in magnetic resonance imaging reporting of anal fistula  
*Garg P, Kaur B, Yagnik VD, Dawka S*

## MINIREVIEWS

- 276 Current status of surgical management of patients with gastroenteropancreatic neuroendocrine neoplasms  
*Stankiewicz R, Grąt M*
- 286 Gastrostomy tubes: Fundamentals, periprocedural considerations, and best practices  
*Rajan A, Wangrattanapranee P, Kessler J, Kidambi TD, Tabibian JH*

## ORIGINAL ARTICLE

## Retrospective Cohort Study

- 304 Laparoscopic-assisted *vs* open transhiatal gastrectomy for Siewert type II adenocarcinoma of the esophagogastric junction: A retrospective cohort study  
*Song QY, Li XG, Zhang LY, Wu D, Li S, Zhang BL, Xu ZY, Wu RLG, Guo X, Wang XX*

## Retrospective Study

- 315 How to examine anastomotic integrity intraoperatively in totally laparoscopic radical gastrectomy? Methylene blue testing prevents technical defect-related anastomotic leaks  
*Deng C, Liu Y, Zhang ZY, Qi HD, Guo Z, Zhao X, Li XJ*
- 329 Clinical outcomes of endoscopic resection of superficial nonampullary duodenal epithelial tumors: A 10-year retrospective, single-center study  
*Cho JH, Lim KY, Lee EJ, Lee SH*

## CASE REPORT

- 341 Subacute liver and respiratory failure after segmental hepatectomy for complicated hepatolithiasis with secondary biliary cirrhosis: A case report  
*Fan WJ, Zou XJ*
- 352 Surgical timing for primary encapsulating peritoneal sclerosis: A case report and review of literature  
*Deng P, Xiong LX, He P, Hu JH, Zou QX, Le SL, Wen SL*
- 362 Laparoscopic-assisted endoscopic full-thickness resection of a large gastric schwannoma: A case report  
*He CH, Lin SH, Chen Z, Li WM, Weng CY, Guo Y, Li GD*

**LETTER TO THE EDITOR**

- 370** Imaging of acute appendicitis: Advances

*Aydın S, Karavas E, Şenbil DC*

**ABOUT COVER**

Editorial Board Member of *World Journal of Gastrointestinal Surgery*, Tatsuya Kin, MD, PhD, Adjunct Professor, Senior Scientist, Surgeon, Department of Clinical Islet Laboratory, University of Alberta, Edmonton T6G2C8, Alberta, Canada. [tkin@ualberta.ca](mailto:tkin@ualberta.ca)

**AIMS AND SCOPE**

The primary aim of *World Journal of Gastrointestinal Surgery* (WJGS, *World J Gastrointest Surg*) is to provide scholars and readers from various fields of gastrointestinal surgery with a platform to publish high-quality basic and clinical research articles and communicate their research findings online.

WJGS mainly publishes articles reporting research results and findings obtained in the field of gastrointestinal surgery and covering a wide range of topics including biliary tract surgical procedures, biliopancreatic diversion, colectomy, esophagectomy, esophagostomy, pancreas transplantation, and pancreatectomy, etc.

**INDEXING/ABSTRACTING**

The WJGS is now abstracted and indexed in Science Citation Index Expanded (SCIE, also known as SciSearch®), Current Contents/Clinical Medicine, Journal Citation Reports/Science Edition, PubMed, and PubMed Central. The 2021 edition of Journal Citation Reports® cites the 2020 impact factor (IF) for WJGS as 2.582; IF without journal self cites: 2.564; 5-year IF: 3.378; Journal Citation Indicator: 0.53; Ranking: 97 among 212 journals in surgery; Quartile category: Q2; Ranking: 73 among 92 journals in gastroenterology and hepatology; and Quartile category: Q4.

**RESPONSIBLE EDITORS FOR THIS ISSUE**

Production Editor: Rui-Rui Wu, Production Department Director: Xiang Li, Editorial Office Director: Ya-Juan Ma.

**NAME OF JOURNAL**

*World Journal of Gastrointestinal Surgery*

**ISSN**

ISSN 1948-9366 (online)

**LAUNCH DATE**

November 30, 2009

**FREQUENCY**

Monthly

**EDITORS-IN-CHIEF**

Peter Schemmer

**EDITORIAL BOARD MEMBERS**

<https://www.wjgnet.com/1948-9366/editorialboard.htm>

**PUBLICATION DATE**

April 27, 2022

**COPYRIGHT**

© 2022 Baishideng Publishing Group Inc

**INSTRUCTIONS TO AUTHORS**

<https://www.wjgnet.com/bpg/gerinfo/204>

**GUIDELINES FOR ETHICS DOCUMENTS**

<https://www.wjgnet.com/bpg/gerinfo/287>

**GUIDELINES FOR NON-NATIVE SPEAKERS OF ENGLISH**

<https://www.wjgnet.com/bpg/gerinfo/240>

**PUBLICATION ETHICS**

<https://www.wjgnet.com/bpg/gerinfo/288>

**PUBLICATION MISCONDUCT**

<https://www.wjgnet.com/bpg/gerinfo/208>

**ARTICLE PROCESSING CHARGE**

<https://www.wjgnet.com/bpg/gerinfo/242>

**STEPS FOR SUBMITTING MANUSCRIPTS**

<https://www.wjgnet.com/bpg/gerinfo/239>

**ONLINE SUBMISSION**

<https://www.f6publishing.com>





## Imaging of acute appendicitis: Advances

Sonay Aydın, Erdal Karavas, Düzgün Can Şenbil

**Specialty type:** Radiology, nuclear medicine and medical imaging

**Provenance and peer review:** Invited article; Externally peer reviewed.

**Peer-review model:** Single blind

**Peer-review report's scientific quality classification**

Grade A (Excellent): 0  
Grade B (Very good): B  
Grade C (Good): C  
Grade D (Fair): 0  
Grade E (Poor): 0

**P-Reviewer:** Abd EL hafez A, Egypt; Wichmann D, Germany

**Received:** December 3, 2021

**Peer-review started:** December 3, 2021

**First decision:** January 30, 2022

**Revised:** February 2, 2022

**Accepted:** March 26, 2022

**Article in press:** March 26, 2022

**Published online:** April 27, 2022



**Sonay Aydın, Erdal Karavas, Düzgün Can Şenbil**, Department of Radiology, Erzincan Binali Yıldırım University Faculty of Medicine, Erzincan 24100, Turkey

**Corresponding author:** Düzgün Can Şenbil, MD, Academic Research, Doctor, Department of Radiology, Erzincan Binali Yıldırım University Faculty of Medicine, Başbağlar, Hacı Ali Akın Cd. No. 32 Erzincan 24100, Turkey. [senbilcan@gmail.com](mailto:senbilcan@gmail.com)

### Abstract

We read with interest the review by Teng *et al*, who summarized the current approach to the diagnosis and treatment of acute appendicitis (AA). Also, the article summarizes the clinical scoring systems very effectively. In one of the previous studies conducted by our research group, we showed that the use of the Alvarado score, ultrasound and C-reactive protein values in combination provides a safe confirmation or exclusion of the diagnosis of AA. Computed tomography is particularly sensitive in detecting periappendiceal abscess, peritonitis and gangrenous changes. Computed tomography is not a good diagnostic tool in pediatric patients because of the ionizing radiation it produces. Ultrasound is a valuable diagnostic tool to differentiate AA from lymphoid hyperplasia. Presence of fluid collection in the periappendiceal and lamina propria thickness less than 1 mm are the most effective parameters in differentiating appendicitis from lymphoid hyperplasia. Although AA is the most common cause of surgical acute abdomen, it remains an important diagnostic and clinical challenge. By combining clinical scoring systems, laboratory data and appropriate imaging methods, diagnostic accuracy and adherence to treatment can be increased. Lymphoid hyperplasia and perforated appendicitis present significant diagnostic challenges in children. Additional ultrasound findings are increasingly defined to differentiate AA from these conditions.

**Key Words:** Acute appendicitis; Inflammation; Acute abdomen; Perforation

©The Author(s) 2022. Published by Baishideng Publishing Group Inc. All rights reserved.

**Core Tip:** Despite the fact that acute appendicitis is the most common cause of acute abdomen, it remains a diagnostic and clinical challenge. When the ultrasound, Alvarado scoring and C-reactive protein are used in conjunction to diagnose acute appendicitis, the diagnosis can be safely confirmed or ruled out. Computed tomography scans are extremely sensitive in detecting complications from acute appendicitis. Computed tomography scans are especially effective at detecting periappendix abscesses, peritonitis and gangrenous changes. Because of the ionizing radiation it emits, computed tomography is not a good diagnostic tool in pediatric patients. In pediatric patients, ultrasound should be the preferred method.

**Citation:** Aydın S, Karavas E, Şenbil DC. Imaging of acute appendicitis: Advances. *World J Gastrointest Surg* 2022; 14(4): 370-373

**URL:** <https://www.wjgnet.com/1948-9366/full/v14/i4/370.htm>

**DOI:** <https://dx.doi.org/10.4240/wjgs.v14.i4.370>

## TO THE EDITOR

We read with interest the review by Teng *et al*[1], who summarized the current approach to the diagnosis and treatment of acute appendicitis (AA). Also, the article summarizes the clinical scoring systems very effectively.

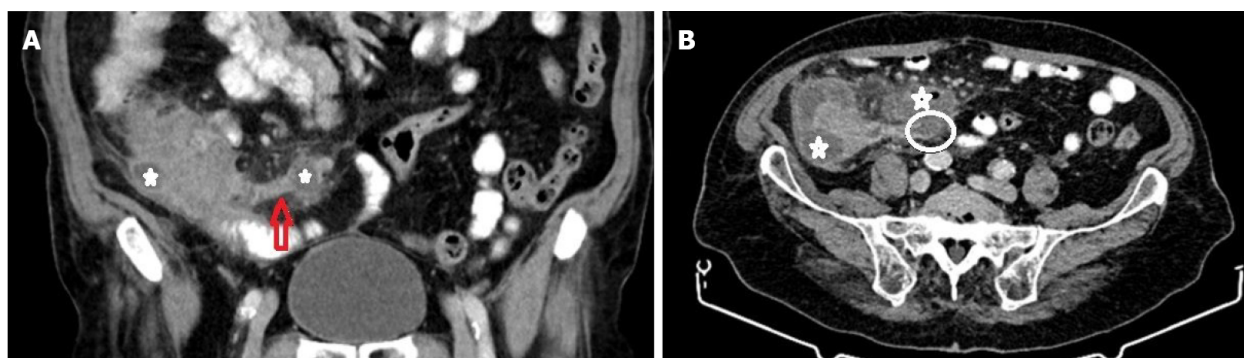
In one of the published studies of our research group, we have shown that using the Alvarado score, ultrasound (US) and C-reactive protein (CRP) levels in combination enables the confirmation or rejection of AA safely[2]. The Alvarado scoring system is one of the most commonly used methods[1]. Even though the scoring system contains series of laboratory parameters, it does not contain CRP levels. Rather than using the Alvarado system or US alone, combining these methods with CRP levels will increase diagnostic accuracy.

Teng *et al*[1] stated that computerized tomography scans have a well-established role in evaluating AA-related complications. Computed tomography is especially sensitive for detecting periappendiceal abscess, peritonitis and gangrenous changes[1] (Figure 1). Pediatric patients are more likely to develop perforated appendicitis. Imaging is critical in diagnosing perforated appendicitis; clinical differentiation can be challenging, especially in younger children. Computed tomography is not a good diagnostic tool in pediatric patients due to the ionizing radiation it produces. According to our results, US can also be used as an effective diagnostic tool for the detection of pediatric perforated appendicitis cases. The most valuable US parameters are the detection of loculated fluid in the periappendiceal area and fluid collection in all abdominal recesses. When these parameters are combined with CRP levels, diagnostic performance can be improved[3].

Teng *et al*[1] emphasized that AA occurs when the appendiceal orifice is obstructed (for example, by lymphoid hyperplasia or fecaliths), resulting in inflammation. We have demonstrated that, in addition to causing AA, lymphoid hyperplasia can serve as a significant mimicker of AA by forming an incompressible appendix larger than 6 mm in diameter, particularly in pediatric patients. US is a valuable diagnostic tool for differentiating AA from lymphoid hyperplasia. The presence of periappendiceal fluid collection and a lamina propria thickness of less than 1 mm are the most effective parameters for differentiating appendicitis from lymphoid hyperplasia[4] (Figure 2).

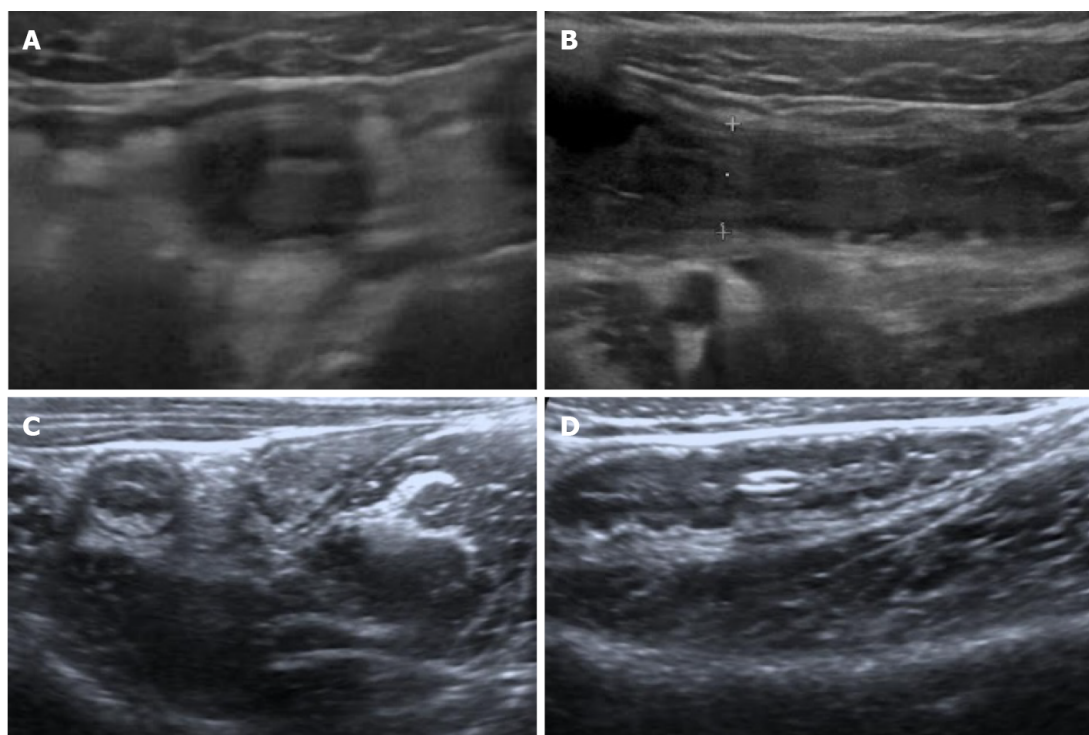
The portal vein can be affected from appendiceal inflammation, and thrombosis might occur[1]. In addition to complications, according to our data, portal vein hemodynamic changes can help to confirm AA diagnosis in children. In equivocal cases, detecting an increase in portal vein diameter and/or flow velocity may corroborate other clinical signs of AA[5].

To summarize, AA remains a significant diagnostic and clinical challenge despite being the most common cause of surgical acute abdomen. By combining clinical scoring systems, laboratory data and appropriate imaging methods, diagnostic accuracy and treatment adherence can be increased. Lymphoid hyperplasia and perforated appendicitis present significant diagnostic challenges in children. Additional US findings are increasingly being defined for the purpose of distinguishing AA from these entities.



DOI: 10.4240/wjgs.v14.i4.370 Copyright ©The Author(s) 2022.

**Figure 1** An 87-yr-old male. Coronal (A) and axial (B) sections are shown. The appendix diameter has increased, and it appears inflamed (red arrow). The distal part of the appendix is perforated (white circle). Abscesses are seen in the periappendiceal and pericecal areas (white star).



DOI: 10.4240/wjgs.v14.i4.370 Copyright ©The Author(s) 2022.

**Figure 2** Acute appendicitis in a 12-yr-old boy. A-B: Sonographic images taken axially (A) and longitudinally (B). The lamina propria is not discernible; C-D: For comparison, axial (C) and longitudinal (D) sonographic images of an 8-year-old girl with lymphoid hyperplasia. Note the prominent and thick lamina propria.

## FOOTNOTES

**Author contributions:** Aydın S put forward the concept; Şenbil DC was responsible for designing; Karavas E provided resources; Aydın S and Karavas E were responsible for supervision, did the literature search and reviewed the manuscript critically; Şenbil DC and Aydın S were responsible for materials and wrote the manuscript; All authors have read and approved the final manuscript.

**Conflict-of-interest statement:** The authors declare having no conflicts of interest.

**Open-Access:** This article is an open-access article that was selected by an in-house editor and fully peer-reviewed by external reviewers. It is distributed in accordance with the Creative Commons Attribution NonCommercial (CC BY-NC 4.0) license, which permits others to distribute, remix, adapt, build upon this work non-commercially, and license their derivative works on different terms, provided the original work is properly cited and the use is non-commercial. See: <https://creativecommons.org/licenses/by-nc/4.0/>

**Country/Territory of origin:** Turkey

**ORCID number:** Sonay Aydın 0000-0002-3812-6333; Erdal Karavas 0000-0001-6649-3256; Düzgün Can Şenbil 0000-0003-0233-7371.

**S-Editor:** Wu YXJ

**L-Editor:** Filipodia

**P-Editor:** Wu YXJ

## REFERENCES

- 1 **Teng TZJ**, Thong XR, Lau KY, Balasubramaniam S, Shelat VG. Acute appendicitis-advances and controversies. *World J Gastrointest Surg* 2021; **13**: 1293-1314 [PMID: 34950421 DOI: 10.4240/wjgs.v13.i11.1293]
- 2 **Aydın S**, Fatihoğlu E, Ramadan HS, Akhan B, Koseoglu EN. Alvarado score, ultrasound, and CRP: how to combine them for the most accurate acute appendicitis diagnosis. *Iranian J Radiol* 2017; **14** [DOI: 10.5812/iranjradiol.38160]
- 3 **Aydın S**, Fatihoğlu E. Perforated appendicitis: A sonographic diagnostic challenge. *Ankara Eğitim ve Araştırma Hastanesi Tıp Dergisi* 2018; **51**: 110-115
- 4 **Aydın S**, Tek C, Ergun E, Kazci O, Kosar PN. Acute Appendicitis or Lymphoid Hyperplasia: How to Distinguish More Safely? *Can Assoc Radiol J* 2019; **70**: 354-360 [PMID: 31500858 DOI: 10.1016/j.carj.2018.09.006]
- 5 **Aydın S**, Ucan B. Pediatric acute appendicitis: Searching the diagnosis in portal vein. *Ultrasound* 2020; **28**: 174-179 [PMID: 32831890 DOI: 10.1177/1742271X20918001]





Published by **Baishideng Publishing Group Inc**  
7041 Koll Center Parkway, Suite 160, Pleasanton, CA 94566, USA

**Telephone:** +1-925-3991568

**E-mail:** [bpgoffice@wjgnet.com](mailto:bpgoffice@wjgnet.com)

**Help Desk:** <https://www.f6publishing.com/helpdesk>

<https://www.wjgnet.com>

