

World Journal of *Gastroenterology*

World J Gastroenterol 2022 June 21; 28(23): 2527-2635



Contents

Weekly Volume 28 Number 23 June 21, 2022

REVIEW

- 2527 Autoimmune liver diseases in systemic rheumatic diseases

Wang CR, Tsai HW

- 2546 Fecal microbiota transplantation in the metabolic diseases: Current status and perspectives

Zheng L, Ji YY, Wen XL, Duan SL

MINIREVIEWS

- 2561 Up to seven criteria in selection of systemic therapy for hepatocellular carcinoma

Silk T, Silk M, Wu J

ORIGINAL ARTICLE

Basic Study

- 2569 Family with sequence similarity 134 member B-mediated reticulophagy ameliorates hepatocyte apoptosis induced by dithiothreitol

Guo YX, Han B, Yang T, Chen YS, Yang Y, Li JY, Yang Q, Xie RJ

Retrospective Study

- 2582 Infliximab trough level combined with inflammatory biomarkers predict long-term endoscopic outcomes in Crohn's disease under infliximab therapy

Cao WT, Huang R, Liu S, Fan YH, Xu MS, Xu Y, Ni H

- 2597 Higher infliximab and adalimumab trough levels are associated with fistula healing in patients with fistulising perianal Crohn's disease

Gu B, Venkatesh K, Williams AJ, Ng W, Corte C, Gholamrezaei A, Ghaly S, Xuan W, Paramsothy S, Connor S

- 2609 Whole lesion histogram analysis of apparent diffusion coefficient predicts therapy response in locally advanced rectal cancer

Jiménez de los Santos ME, Reyes-Pérez JA, Domínguez Osorio V, Villaseñor-Navarro Y, Moreno-Astudillo L, Vela-Sarmiento I, Sollozo-Dupont I

CASE REPORT

- 2625 Primary gastric dedifferentiated liposarcoma resected endoscopically: A case report

Cho JH, Byeon JH, Lee SH

LETTER TO THE EDITOR

- 2633 Reconstructing the puzzle of the role of therapeutic endoscopy in the management of post-bariatric surgery complications

Argyriou K, Parra-Blanco A

ABOUT COVER

Editorial Board Member of *World Journal of Gastroenterology*, Osamu Toyoshima, MD, Director, Department of Gastroenterology, Toyoshima Endoscopy Clinic, 6-17-5 Seijo, Setagaya-ku, Tokyo 157-0066, Japan. t@ichou.com

AIMS AND SCOPE

The primary aim of *World Journal of Gastroenterology* (WJG, *World J Gastroenterol*) is to provide scholars and readers from various fields of gastroenterology and hepatology with a platform to publish high-quality basic and clinical research articles and communicate their research findings online. WJG mainly publishes articles reporting research results and findings obtained in the field of gastroenterology and hepatology and covering a wide range of topics including gastroenterology, hepatology, gastrointestinal endoscopy, gastrointestinal surgery, gastrointestinal oncology, and pediatric gastroenterology.

INDEXING/ABSTRACTING

The WJG is now indexed in Current Contents®/Clinical Medicine, Science Citation Index Expanded (also known as SciSearch®), Journal Citation Reports®, Index Medicus, MEDLINE, PubMed, PubMed Central, and Scopus. The 2021 edition of Journal Citation Report® cites the 2020 impact factor (IF) for WJG as 5.742; Journal Citation Indicator: 0.79; IF without journal self cites: 5.590; 5-year IF: 5.044; Ranking: 28 among 92 journals in gastroenterology and hepatology; and Quartile category: Q2. The WJG's CiteScore for 2020 is 6.9 and Scopus CiteScore rank 2020: Gastroenterology is 19/136.

RESPONSIBLE EDITORS FOR THIS ISSUE

Production Editor: Wen-Wen Qi, Production Department Director: Xiang Li, Editorial Office Director: Ze-Mao Gong.

NAME OF JOURNAL

World Journal of Gastroenterology

ISSN

ISSN 1007-9327 (print) ISSN 2219-2840 (online)

LAUNCH DATE

October 1, 1995

FREQUENCY

Weekly

EDITORS-IN-CHIEF

Andrzej S Tarnawski

EDITORIAL BOARD MEMBERS

<http://www.wjgnet.com/1007-9327/editorialboard.htm>

PUBLICATION DATE

June 21, 2022

COPYRIGHT

© 2022 Baishideng Publishing Group Inc

INSTRUCTIONS TO AUTHORS

<https://www.wjgnet.com/bpg/gerinfo/204>

GUIDELINES FOR ETHICS DOCUMENTS

<https://www.wjgnet.com/bpg/GerInfo/287>

GUIDELINES FOR NON-NATIVE SPEAKERS OF ENGLISH

<https://www.wjgnet.com/bpg/gerinfo/240>

PUBLICATION ETHICS

<https://www.wjgnet.com/bpg/GerInfo/288>

PUBLICATION MISCONDUCT

<https://www.wjgnet.com/bpg/gerinfo/208>

ARTICLE PROCESSING CHARGE

<https://www.wjgnet.com/bpg/gerinfo/242>

STEPS FOR SUBMITTING MANUSCRIPTS

<https://www.wjgnet.com/bpg/GerInfo/239>

ONLINE SUBMISSION

<https://www.f6publishing.com>



Primary gastric dedifferentiated liposarcoma resected endoscopically: A case report

Joon Hyun Cho, Jun Hyeon Byeon, Si Hyung Lee

Specialty type: Gastroenterology and hepatology

Provenance and peer review: Unsolicited article; Externally peer reviewed.

Peer-review model: Single blind

Peer-review report's scientific quality classification

Grade A (Excellent): 0
Grade B (Very good): B, B
Grade C (Good): 0
Grade D (Fair): 0
Grade E (Poor): 0

P-Reviewer: Zhang X, United States; Zhao JW, China

Received: December 18, 2021

Peer-review started: December 18, 2021

First decision: January 23, 2022

Revised: January 29, 2022

Accepted: May 5, 2022

Article in press: May 5, 2022

Published online: June 21, 2022



Joon Hyun Cho, Jun Hyeon Byeon, Si Hyung Lee, Division of Gastroenterology and Hepatology, Department of Internal Medicine, Yeungnam University College of Medicine, Daegu 42415, South Korea

Corresponding author: Si Hyung Lee, MD, Professor, Division of Gastroenterology and Hepatology, Department of Internal Medicine, Yeungnam University College of Medicine, 170 Hyeonchung-ro, Nam-gu, Daegu 42415, South Korea. dr9696@gmail.com

Abstract

BACKGROUND

Liposarcoma is one of the most common adult mesenchymal tumors but is uncommon in the gastrointestinal tract and extremely rare in the stomach. Furthermore, the histological subtypes of liposarcoma usually reported in the stomach are well-differentiated or myxoid, and few reports have been issued on small-sized gastric liposarcomas resected endoscopically and followed up. Herein, we report a case of primary gastric dedifferentiated liposarcoma (DL) that was resected endoscopically.

CASE SUMMARY

A 67-year-old female Korean patient was referred to our institution for further evaluation of a gastric submucosal tumor (SMT) located in the lesser curvature of the gastric body by esophagogastroduodenoscopy. Endoscopic ultrasound revealed a well-circumscribed, slightly heterogeneous, isoechoic, 17 mm × 10 mm sized mass originating from the third sonographic layer. Computed tomography showed no evidence of significant lymph node enlargement or distant metastasis. Endoscopic resection was undertaken using the snare resection technique after mucosal precutting to provide a definitive histopathologic diagnosis, which proved to be consistent with DL, based on its morphology and the immunoections of MDM2 and CDK4. The patient was planned for surgery because the deep resection margin was positive for malignancy. After declining any invasive procedure or adjuvant treatment, the patient was placed under close follow-up, and at one year after endoscopic resection, remained disease free.

CONCLUSION

This is the first reported case of a small primary gastric DL resected endoscopically and followed up. This report demonstrates that when diagnosis of a SMT is uncertain, the use of invasive techniques, including endoscopic resection, should be considered.

Key Words: Gastric liposarcoma; Dedifferentiated liposarcoma; Submucosal tumor; Endoscopic resection; Case report

©The Author(s) 2022. Published by Baishideng Publishing Group Inc. All rights reserved.

Core Tip: Liposarcoma is uncommon in the gastrointestinal tract and rarely encountered in the stomach. Furthermore, the dedifferentiated histologic subtype has not been previously reported in the stomach in the English literature. We experienced a case of a small (1.7 cm) primary gastric dedifferentiated liposarcoma, which was resected endoscopically. This report cautions that if a diagnosis of submucosal tumor is uncertain, the use of aggressive techniques, including endoscopic resection, should be considered.

Citation: Cho JH, Byeon JH, Lee SH. Primary gastric dedifferentiated liposarcoma resected endoscopically: A case report. *World J Gastroenterol* 2022; 28(23): 2625-2632

URL: <https://www.wjgnet.com/1007-9327/full/v28/i23/2625.htm>

DOI: <https://dx.doi.org/10.3748/wjg.v28.i23.2625>

INTRODUCTION

Liposarcoma is one of the most common adult soft tissue sarcomas and has a peak incidence between the ages 50 and 65 and a prevalence of 15%-20% among all sarcoma patients[1]. There are four histological subtypes of liposarcomas[2]. Atypical lipomatous tumor/well-differentiated liposarcoma (WDL) is the most common subtype followed by dedifferentiated liposarcoma (DL), which frequently occurs in retroperitoneum[3,4]. The myxoid and pleomorphic types usually present in the extremities [5]. Thus, liposarcoma usually arises in deep soft tissues of the proximal extremities, retroperitoneum, or trunk[6], and is encountered in the gastrointestinal tract in only 2% of cases[7].

The majority of liposarcomas of the alimentary tract arise in the esophagus[8], and liposarcomas originating at more distal sites, such as stomach, small intestine, and large intestine, are rare[9]. Less than 40 cases of primary liposarcoma of the stomach have been described in the medical literature, and the most reported histological subtypes of gastric liposarcoma are WDL and myxoid liposarcoma[10]. In fact, no report on DL of the stomach has been published in the English literature, though one case report on DL of the gastroesophageal junction was issued in 2018[11]. Here, we describe the first case of a small primary gastric DL resected endoscopically and provide a review of the literature.

CASE PRESENTATION

Chief complaints

A 67-year-old female Korean patient was referred to our institution for further evaluation and treatment of a gastric submucosal tumor (SMT) incidentally discovered by esophagogastroduodenoscopy (EGD) during a routine medical check-up.

History of present illness

The patient had experienced no abdominal pain or discomfort.

History of past illness

She had a history of breast conserving surgery due to breast cancer 6 years previously.

Personal and family history

The patient had diabetes and was being treated with oral hypoglycemic agents. She was a non-smoker and non-alcohol drinker and had no significant family history.

Physical examination

Physical examination was unremarkable, and her abdomen was soft, nontender, and nondistended with no palpable mass.

Laboratory examinations

Laboratory tests, which included common serum tumor markers such as carcinoembryonic antigen (CEA) and carbohydrate antigen 19-9 (CA 19-9), were normal.

Imaging examinations

EGD revealed a SMT-like protruding lesion of approximately 15 mm diameter located in the posterior wall of the lesser curvature of the distal part of the gastric body (Figure 1A). The lesion was covered with normally appearing mucosa except for focal mucosal erythema and depression over the lesion. Gastric endoscopic ultrasonography (EUS) examination demonstrated a well-demarcated mass, which measured 17 mm × 10 mm, located in the third layer of the gastric wall. The echo pattern of the mass was slightly heterogeneous and isoechoic (Figure 1B), but its EUS appearance was insufficient for diagnosis. The differential diagnosis included lipoma, neuroendocrine tumor, and ectopic pancreas. Initial biopsy specimens obtained at the site of the focal mucosal erythema and depression were negative for a neoplasm. Computed tomography (CT) of the abdomen showed a well-enhanced, intraluminal protruding polypoid lesion arising from the gastric body but no evidence of lymph node enlargement or distant metastasis (Figure 2).

FINAL DIAGNOSIS

After initial work-up, endoscopic resection was conducted using the snare resection technique after mucosal precutting for a definitive histopathologic result (Figure 3). At gross examination, the tumor was whitish yellow, well-shaped, and solid. Histopathologic examination showed the tumor was located submucosally and primarily composed of spindle-shaped atypical cells with pleomorphic and hyperchromatic nuclei and indistinct pale cytoplasm (Figure 4A-D). Deep resection margins were positive for tumor. Immunohistochemical staining performed for the differential diagnosis of gastrointestinal stromal tumor, schwannoma, leiomyosarcoma, malignant melanoma, and any poorly or undifferentiated sarcoma, revealed tumor cells were negative for CD117, DOG1, CD34, SMA, S-100, Desmin, HMB45, and SOX10, but positive for MDM2 and CDK4 nuclear staining (Figure 4E and F). Based on these findings, the histopathological diagnosis was consistent with DL.

TREATMENT

The patient was planned for surgery because the deep resection margin was positive for DL, but declined any invasive procedure or adjuvant treatment.

OUTCOME AND FOLLOW-UP

She remains under close follow-up, which includes biannual CT scanning and EGD, and at one year after endoscopic resection remained disease free.

DISCUSSION

Although they are the most common mesenchymal neoplasms, liposarcomas are rarely found in the gastrointestinal tract. Since the disease was first described by Abrams *et al* [12] in 1941, fewer than 40 cases of gastric liposarcoma have been reported in the literature worldwide [10]. The etiology of gastric liposarcoma remains uncertain, though some patients have a family history of soft tissue neoplasms, which suggests the involvement of genetic factors [13]. Gastric liposarcomas originate due to the proliferation of undifferentiated mesenchymal cells within submucosa and the tunica muscularis layer of stomach, and an exophytic growth is typical [10,14]. Most gastric liposarcomas are located in the antrum or lesser curvature.

As is the case for other soft tissue sarcomas, there are no characteristic clinical findings [15], and patients may remain asymptomatic for years. Symptoms depend primarily on tumor location and size and the presence or absence of ulceration. The most common symptoms are a palpable mass, mechanical obstruction, and gastrointestinal bleeding. In general, nonspecific symptoms are the main cause of delayed diagnoses, and thus, most liposarcomas are large at diagnosis. However, our patient underwent regular biennial EGD under a national cancer screening program, and the small SMT was detected early. Furthermore, endoscopic resection performed for a definite diagnosis resulted in the diagnosis of a small, asymptomatic gastric liposarcoma.

The characteristic histological features of liposarcoma are the presence of immature fat cells and lipoblasts [14]. Liposarcomas are classified histologically as WDL, DL, myxoid/round cell liposarcoma, or pleomorphic liposarcoma [2], and considerations of histological subtype are important during the disease course. While DL, round-cell, and pleomorphic liposarcomas are high-grade aggressive tumors with the ability to metastasize, WDL and myxoid liposarcomas are low-grade tumors that progress

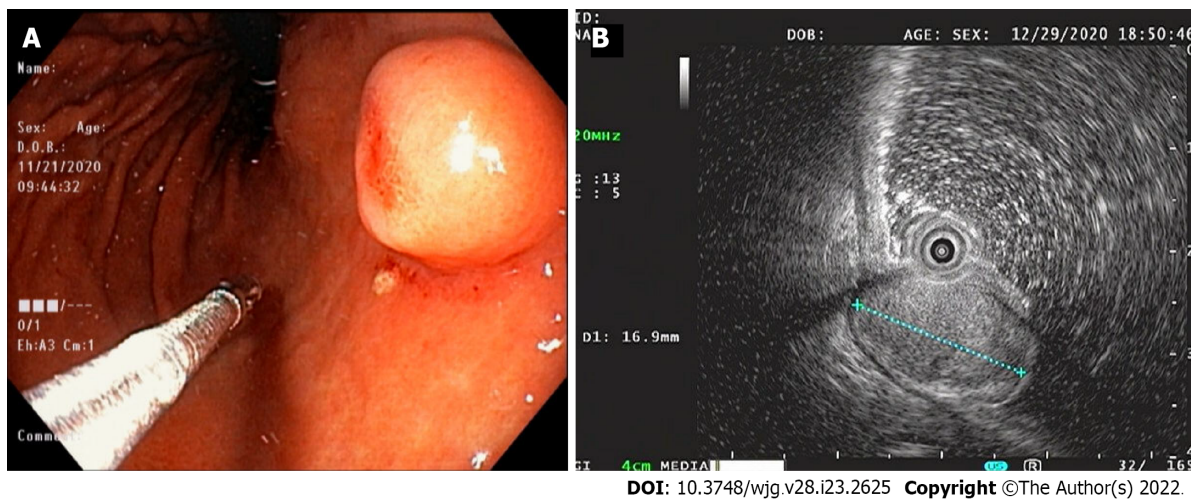


Figure 1 Endoscopy and endoscopic ultrasound images. A: Endoscopic image showing a 15-mm-sized, submucosal tumor-like, protruding lesion with focal mucosal erythema and depression of overlying mucosa; B: Endoscopic ultrasound image showing a well-circumscribed, slightly heterogeneous, 17 mm × 10 mm sized, isoechoic mass originating from the third sonographic layer.

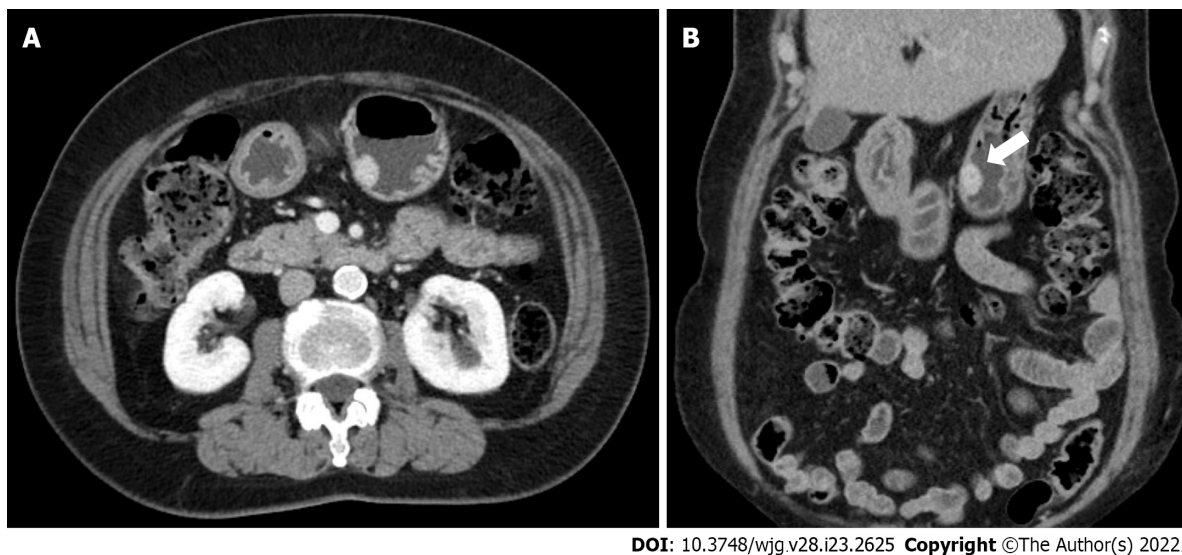
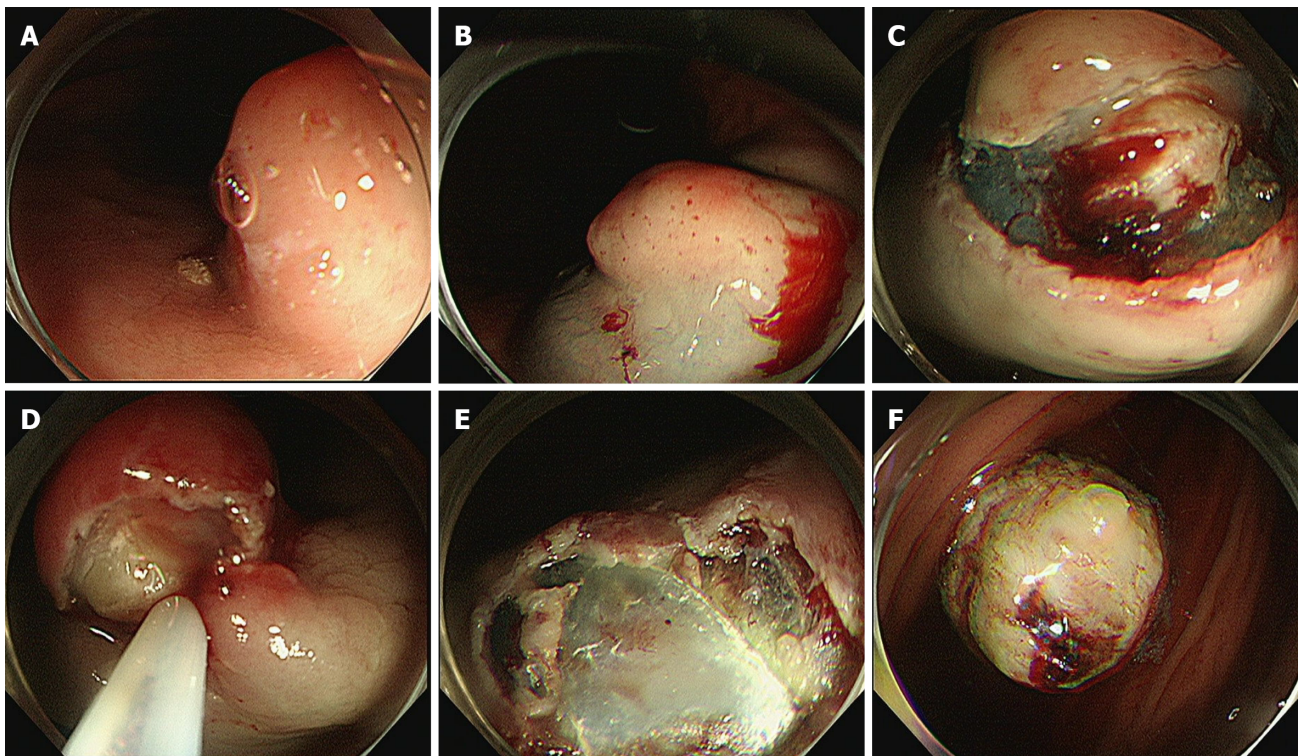


Figure 2 Abdominal computed tomography images. A and B: Axial and coronal computed tomography images showing a well-enhanced and protruding intraluminal mass in the gastric body.

more slowly[3,5]. Most of the gastric liposarcomas reported have been of the well-differentiated or myxoid histologic subtypes[10], and DL arising in the stomach has not been previously reported in the English literature; although a case of DL of heart and stomach was reported in 2017[16]. Notably, in this report, histopathological examination failed to determine that the primary lesion was located in the stomach. In addition, one case of primary DL of the gastroesophageal junction has been reported[11]. Thus, to the best of our knowledge, this is the first reported case of primary gastric DL.

DL is defined as a combination of WDL and high-grade sarcoma that displays evidence of non-lipogenic differentiation like undifferentiated high-grade pleomorphic sarcoma, fibrosarcoma, or myxofibrosarcoma[17,18]. DL can occur *de novo* (90% of cases) or as recurrence from a preexisting WDL (10% of cases)[19]. If DL develops from the transformation of a preexisting WDL into non-lipogenic sarcoma, dedifferentiation develops in 20% of the first and 44% of the second local recurrences and has been shown to be associated with poor progression and metastasis[5]. The histologic diagnosis of DL is generally based on the identification of WDL areas, which were scarce in our patient. In these cases, the differential diagnosis of any poorly-differentiated or undifferentiated sarcoma is important, and MDM2 and CDK4 immunohistochemical staining or FISH testing for amplification of the MDM2 and CDK4 genes is diagnostically helpful[20]. In our patient, DL was confirmed by CDK4 and MDM2 immunostaining.



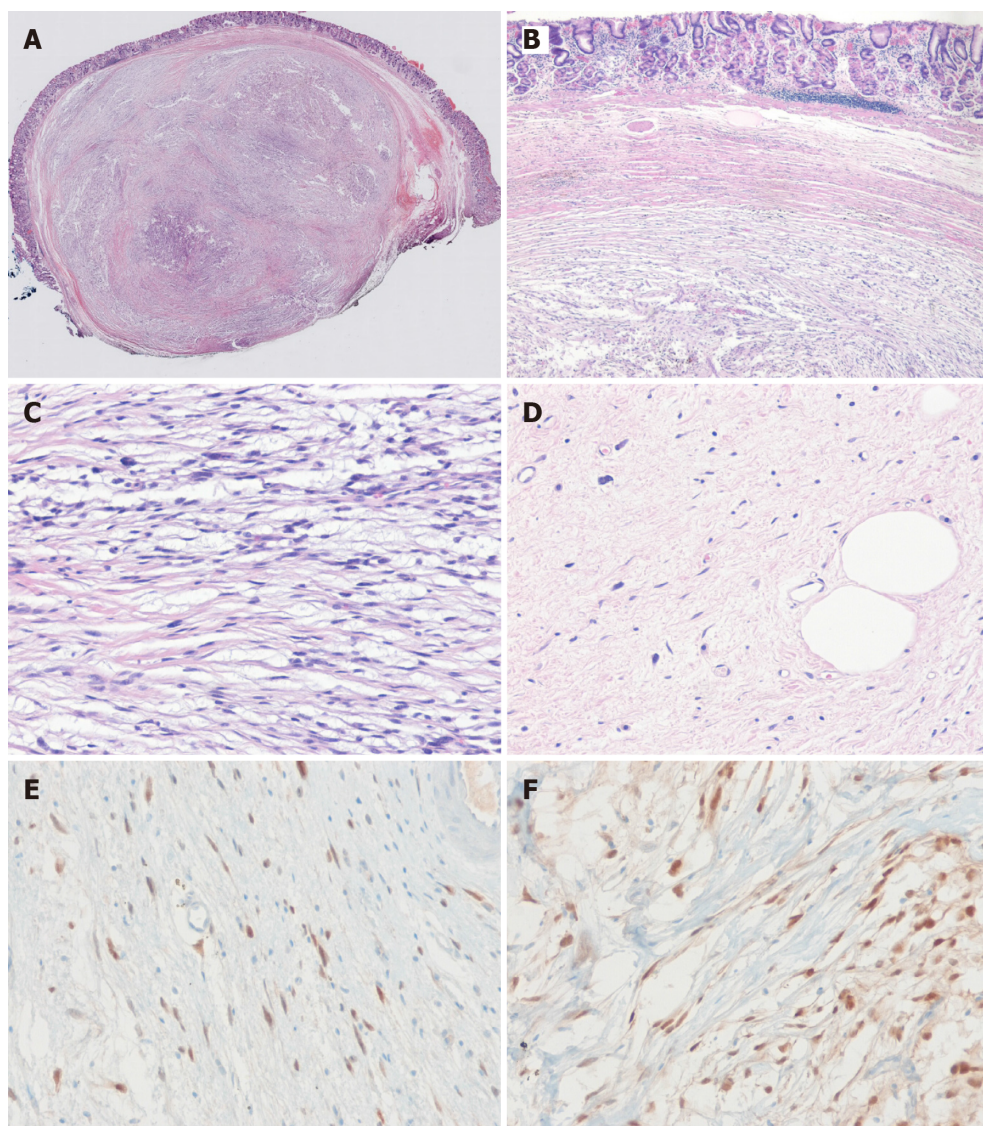
DOI: 10.3748/wjg.v28.i23.2625 Copyright ©The Author(s) 2022.

Figure 3 Process of the endoscopic resection. A: Marking outside the lesion; B: Injection of saline-epinephrine for submucosal lifting; C: Circumferential mucosal incision and partial submucosal dissection; D and E: Resection using a snare; F: Resected tumor.

DL often exhibits abdominal cavity involvement usually of retroperitoneum, and an intraperitoneal origin is extremely rare[3,21,22]. When DL occurs inside the abdominal cavity it presents as a space-occupying mass lesion. The pathognomonic findings of DL in CT and magnetic resonance images are a heterogeneous, non-lipogenic, encapsulated mass[23], which are sufficient for diagnosis and obviate the need for needle biopsy. In our patient, because DL arising from the gastric wall presented as a small gastric SMT, CT was not diagnostically useful. Although EUS is considered the most useful modality in terms of defining the presumptive nature of SMT, our case demonstrates the difficulty of differentiating benign and malignant SMT by EUS alone, particularly when a lesion is small. Lesion echogenicity is also worth mentioning. Unlike the hyperechoic EUS feature of other pathologic types[10,24,25], our case showed isoechoic EUS features, which appeared to be related to a sparsity of immature lipocytes or lipoblasts as the WDL area was extremely limited in our patient. DL seems to have a better prognosis than other high-grade sarcomas, especially in terms of its metastatic potential. Yet, careful long-term follow-up is essential because approximately 40% of DLs recur locally, 17% metastasize, and 28% of patients eventually die of the disease[1]. Surgery remains the treatment of choice for DL, and it is crucial that the tumor be completely removed[4], though the efficacies of targeted chemotherapy and radiotherapy are being investigated[26].

CONCLUSION

Liposarcoma is uncommon in the gastrointestinal tract and rare in the stomach, and primary DL in the stomach is extremely rare but should be considered in the differential diagnosis of any poorly-differentiated or undifferentiated sarcoma. The reasons why this case report is valuable are: (1) It presents the first reported case of a small primary gastric DL, resected endoscopically, and followed up; and (2) it cautions that if a diagnosis of SMT is uncertain after initial examination by EGD, EUS, and/or CT, the use of aggressive techniques, including endoscopic resection, should be considered.



DOI: 10.3748/wjg.v28.i23.2625 Copyright ©The Author(s) 2022.

Figure 4 The histopathological diagnosis of the endoscopically resected lesion. A and B: The tumor had a smooth margin, an internal heterogeneous morphology, and was located in submucosa (H & E, original magnification $\times 10$, $\times 40$); the deep resection margin was positive for tumor; C: The neoplasm consists of infiltrated, atypical spindle-shaped tumor cells with nuclear hyperchromasia (H & E, original magnification $\times 100$); D: Photomicrograph showing highly pleomorphic spindle cells with some rare lipoblasts (H&E, original magnification $\times 100$); E and F: Immunohistochemical staining for tumor cells show diffuse positivity for MDM2 (E) and CDK4 (F).

FOOTNOTES

Author contributions: Cho JH, Byeon JH, and Lee SH were responsible for acquiring clinical data and for manuscript writing and revision.

Informed consent statement: Informed written consent was obtained from the patients for the publication of this report and any accompanying images.

Conflict-of-interest statement: The authors declare that they have no conflict of interest.

CARE Checklist (2016) statement: The authors have read the CARE Checklist (2016), and the manuscript was prepared and revised according to the CARE Checklist (2016).

Open-Access: This article is an open-access article that was selected by an in-house editor and fully peer-reviewed by external reviewers. It is distributed in accordance with the Creative Commons Attribution NonCommercial (CC BY-NC 4.0) license, which permits others to distribute, remix, adapt, build upon this work non-commercially, and license their derivative works on different terms, provided the original work is properly cited and the use is non-commercial. See: <https://creativecommons.org/Licenses/by-nc/4.0/>

Country/Territory of origin: South Korea

ORCID number: Joon Hyun Cho 0000-0002-3584-6300; Jun Hyeon Byeon 0000-0001-9857-1810; Si Hyung Lee 0000-0001-7221-7506.

S-Editor: Chen YL

L-Editor: A

P-Editor: Chen YL

REFERENCES

- 1 Goldblum JR, Folpe AL, Weiss SW. Enzinger and Weiss's Soft Tissue Tumors. 6th ed. Philadelphia: Elsevier, 2014 [DOI: [10.1097/pap.0000000000000020](https://doi.org/10.1097/pap.0000000000000020)]
- 2 Fletcher CDM, Bridge JA, Hogendoom PCW. World Health Organization classification of tumours. In: Pathology and genetics of tumours of soft tissue and bone. Lyon: IARC Press, 2013: 10-238 [DOI: [10.1302/0301-620x.86b3.0860466b](https://doi.org/10.1302/0301-620x.86b3.0860466b)]
- 3 Singer S, Antonescu CR, Riedel E, Brennan MF. Histologic subtype and margin of resection predict pattern of recurrence and survival for retroperitoneal liposarcoma. *Ann Surg* 2003; **238**: 358-70; discussion 370 [PMID: [14501502](https://pubmed.ncbi.nlm.nih.gov/14501502/) DOI: [10.1097/01.sla.0000086542.11899.38](https://doi.org/10.1097/01.sla.0000086542.11899.38)]
- 4 Choi YY, Kim YJ, Jin SY. Primary liposarcoma of the ascending colon: a rare case of mixed type presenting as hemoperitoneum combined with other type of retroperitoneal liposarcoma. *BMC Cancer* 2010; **10**: 239 [PMID: [20507577](https://pubmed.ncbi.nlm.nih.gov/20507577/) DOI: [10.1186/1471-2407-10-239](https://doi.org/10.1186/1471-2407-10-239)]
- 5 Dalal KM, Kattan MW, Antonescu CR, Brennan MF, Singer S. Subtype specific prognostic nomogram for patients with primary liposarcoma of the retroperitoneum, extremity, or trunk. *Ann Surg* 2006; **244**: 381-391 [PMID: [16926564](https://pubmed.ncbi.nlm.nih.gov/16926564/) DOI: [10.1097/01.sla.0000234795.98607.00](https://doi.org/10.1097/01.sla.0000234795.98607.00)]
- 6 Lahat G, Lazar A, Lev D. Sarcoma epidemiology and etiology: potential environmental and genetic factors. *Surg Clin North Am* 2008; **88**: 451-481, v [PMID: [18514694](https://pubmed.ncbi.nlm.nih.gov/18514694/) DOI: [10.1016/j.suc.2008.03.006](https://doi.org/10.1016/j.suc.2008.03.006)]
- 7 Enzinger FM, Weiss SW. Liposarcoma. In: Soft Tissue Tumors. St Louis: Mosby Year Book, 1995: 431-466 [DOI: [10.1002/bjs.1800821050](https://doi.org/10.1002/bjs.1800821050)]
- 8 Graham RP, Yasir S, Fritchie KJ, Reid MD, Greipp PT, Folpe AL. Polypoid fibroadipose tumors of the esophagus: 'giant fibrovascular polyp' or liposarcoma? *Mod Pathol* 2018; **31**: 337-342 [PMID: [28984298](https://pubmed.ncbi.nlm.nih.gov/28984298/) DOI: [10.1038/modpathol.2017.140](https://doi.org/10.1038/modpathol.2017.140)]
- 9 Gajzer DC, Fletcher CD, Agaimy A, Brcic I, Khanlari M, Rosenberg AE. Primary gastrointestinal liposarcoma—a clinico-pathological study of 8 cases of a rare entity. *Human Pathol* 2020; **97**: 80-93 [DOI: [10.1016/j.humpath.2019.12.004](https://doi.org/10.1016/j.humpath.2019.12.004)]
- 10 Kang WZ, Xue LY, Wang GQ, Ma FH, Feng XL, Guo L, Li Y, Li WK, Tian YT. Liposarcoma of the stomach: Report of two cases and review of the literature. *World J Gastroenterol* 2018; **24**: 2776-2784 [PMID: [29991881](https://pubmed.ncbi.nlm.nih.gov/29991881/) DOI: [10.3748/wjg.v24.i25.2776](https://doi.org/10.3748/wjg.v24.i25.2776)]
- 11 Aşkan G, Bağcı P, Hameed M, Baştürk O. Dedifferentiated Liposarcoma of the Gastroesophageal Junction. *Türk Patoloji Derg* 2018; **34**: 104-107 [PMID: [25690861](https://pubmed.ncbi.nlm.nih.gov/25690861/) DOI: [10.5146/tjpath.2014.01297](https://doi.org/10.5146/tjpath.2014.01297)]
- 12 Abrams MJ, Truberville JS. Liposarcoma of the stomach. *South Surg* 1941; **10**: 891-896
- 13 Matone J, Okazaki S, Maccapani GN, Amancio TT, Filippi RZ, Macedo AL. Giant gastric liposarcoma: case report and review of the literature. *Einstein (Sao Paulo)* 2016; **14**: 557-560 [PMID: [28076606](https://pubmed.ncbi.nlm.nih.gov/28076606/) DOI: [10.1590/S1679-45082016RC3770](https://doi.org/10.1590/S1679-45082016RC3770)]
- 14 Tepetes K, Christodoulidis G, Spyridakis ME, Nakou M, Koukoulis G, Hatzitheofilou K. Liposarcoma of the stomach: a rare case report. *World J Gastroenterol* 2007; **13**: 4154-4155 [PMID: [17696242](https://pubmed.ncbi.nlm.nih.gov/17696242/) DOI: [10.3748/wjg.v13.i30.4154](https://doi.org/10.3748/wjg.v13.i30.4154)]
- 15 López-Negrete L, Luyando L, Sala J, López C, Menéndez de Llano R, Gomez JL. Liposarcoma of the stomach. *Abdom Imaging* 1997; **22**: 373-375 [PMID: [9157853](https://pubmed.ncbi.nlm.nih.gov/9157853/) DOI: [10.1007/s002619900213](https://doi.org/10.1007/s002619900213)]
- 16 Hisata Y, Tasaki Y, Kozaki S, Yamada T. A case of dedifferentiated liposarcoma of the heart and stomach. *Int J Surg Case Rep* 2017; **41**: 36-38 [PMID: [29031176](https://pubmed.ncbi.nlm.nih.gov/29031176/) DOI: [10.1016/j.ijscr.2017.10.001](https://doi.org/10.1016/j.ijscr.2017.10.001)]
- 17 Evans HL. Liposarcoma: a study of 55 cases with a reassessment of its classification. *Am J Surg Pathol* 1979; **3**: 507-523 [PMID: [534388](https://pubmed.ncbi.nlm.nih.gov/534388/) DOI: [10.1097/00000478-197912000-00004](https://doi.org/10.1097/00000478-197912000-00004)]
- 18 Dei Tos AP. Liposarcoma: new entities and evolving concepts. *Ann Diagn Pathol* 2000; **4**: 252-266 [PMID: [10982304](https://pubmed.ncbi.nlm.nih.gov/10982304/) DOI: [10.1053/adpa.2000.8133](https://doi.org/10.1053/adpa.2000.8133)]
- 19 Henricks WH, Chu YC, Goldblum JR, Weiss SW. Dedifferentiated liposarcoma: a clinicopathological analysis of 155 cases with a proposal for an expanded definition of dedifferentiation. *Am J Surg Pathol* 1997; **21**: 271-281 [PMID: [9060596](https://pubmed.ncbi.nlm.nih.gov/9060596/) DOI: [10.1097/00000478-199703000-00002](https://doi.org/10.1097/00000478-199703000-00002)]
- 20 Binh MB, Sastre-Garau X, Guillou L, de Pinieux G, Terrier P, Lagacé R, Aurias A, Hostein I, Coindre JM. MDM2 and CDK4 immunostainings are useful adjuncts in diagnosing well-differentiated and dedifferentiated liposarcoma subtypes: a comparative analysis of 559 soft tissue neoplasms with genetic data. *Am J Surg Pathol* 2005; **29**: 1340-1347 [PMID: [16160477](https://pubmed.ncbi.nlm.nih.gov/16160477/) DOI: [10.1097/01.pas.0000170343.09562.39](https://doi.org/10.1097/01.pas.0000170343.09562.39)]
- 21 D'Annibile M, Cosimelli M, Covello R, Stasi E. Liposarcoma of the colon presenting as an endoluminal mass. *World J Surg Oncol* 2009; **7**: 78 [PMID: [19852822](https://pubmed.ncbi.nlm.nih.gov/19852822/) DOI: [10.1186/1477-7819-7-78](https://doi.org/10.1186/1477-7819-7-78)]
- 22 Goel AK, Sinha S, Kumar A, Karak AK, Chattopadhyay TK. Liposarcoma of the mesocolon--case report of a rare lesion. *Surg Today* 1994; **24**: 1003-1006 [PMID: [7772897](https://pubmed.ncbi.nlm.nih.gov/7772897/) DOI: [10.1007/BF02215814](https://doi.org/10.1007/BF02215814)]
- 23 Murphey MD, Arcara LK, Fanburg-Smith J. From the archives of the AFIP: imaging of musculoskeletal liposarcoma with radiologic-pathologic correlation. *Radiographics* 2005; **25**: 1371-1395 [PMID: [16160117](https://pubmed.ncbi.nlm.nih.gov/16160117/) DOI: [10.1148/rg.255055106](https://doi.org/10.1148/rg.255055106)]
- 24 Yamamoto K, Teramae N, Uehira H, Wakabayashi N, Fukuda S, Kodama T, Kashina K, Tsuchihashi Y. Primary liposarcoma of the stomach resected endoscopically. *Endoscopy* 1995; **27**: 711 [PMID: [8903993](https://pubmed.ncbi.nlm.nih.gov/8903993/) DOI: [10.1053/end.1995.270711](https://doi.org/10.1053/end.1995.270711)]

[10.1055/s-2007-1005798](https://doi.org/10.1055/s-2007-1005798)

- 25 **Cure HW**, Gómez D, Pedraza M, Bulicic HC, Cabrera LF, Gil LPG, Acevedo D, Cabrera L, Moreno V, Mendoza A. Laparoscopic management of gastric liposarcoma: A case report and review of the literature. *Int J Surg Case Rep* 2020; **73**: 268-270 [PMID: [32721886](https://pubmed.ncbi.nlm.nih.gov/32721886/) DOI: [10.1016/j.ijscr.2020.07.044](https://doi.org/10.1016/j.ijscr.2020.07.044)]
- 26 **Radaelli S**, Stacchiotti S, Casali PG, Gronchi A. Emerging therapies for adult soft tissue sarcoma. *Expert Rev Anticancer Ther* 2014; **14**: 689-704 [PMID: [24555529](https://pubmed.ncbi.nlm.nih.gov/24555529/) DOI: [10.1586/14737140.2014.885840](https://doi.org/10.1586/14737140.2014.885840)]



Published by **Baishideng Publishing Group Inc**
7041 Koll Center Parkway, Suite 160, Pleasanton, CA 94566, USA

Telephone: +1-925-3991568

E-mail: bpgoffice@wjgnet.com

Help Desk: <https://www.f6publishing.com/helpdesk>

<https://www.wjgnet.com>

