


# World Journal of *Gastroenterology*

*World J Gastroenterol* 2022 July 14; 28(26): 3008-3281



### REVIEW

- 3008** Advances in the imaging of gastroenteropancreatic neuroendocrine neoplasms  
*Ramachandran A, Madhusudhan KS*
- 3027** Tumor microenvironment involvement in colorectal cancer progression *via* Wnt/ $\beta$ -catenin pathway: Providing understanding of the complex mechanisms of chemoresistance  
*Novoa Díaz MB, Martín MJ, Gentili C*
- 3047** Role of baicalin as a potential therapeutic agent in hepatobiliary and gastrointestinal disorders: A review  
*Ganguly R, Gupta A, Pandey AK*

### MINIREVIEWS

- 3063** Alterations of autophagic and innate immune responses by the Crohn's disease-associated ATG16L1 mutation  
*Okai N, Watanabe T, Minaga K, Kamata K, Honjo H, Kudo M*
- 3071** Anabolic androgenic steroid-induced liver injury: An update  
*Petrovic A, Vukadin S, Sikora R, Bojanic K, Smolic R, Plavec D, Wu GY, Smolic M*
- 3081** Epidemiological and clinical aspects of hepatitis B virus infection in Italy over the last 50 years  
*Sagnelli C, Sica A, Creta M, Calogero A, Ciccozzi M, Sagnelli E*
- 3092** Shared decision-making in the management of patients with inflammatory bowel disease  
*Song K, Wu D*
- 3101** Clinical implications and mechanism of histopathological growth pattern in colorectal cancer liver metastases  
*Kong BT, Fan QS, Wang XM, Zhang Q, Zhang GL*
- 3116** Role of gadoteric acid-enhanced liver magnetic resonance imaging in the evaluation of hepatocellular carcinoma after locoregional treatment  
*Gatti M, Maino C, Darvizeh F, Serafini A, Tricarico E, Guarneri A, Inchingolo R, Ippolito D, Ricardi U, Fonio P, Faletti R*

### ORIGINAL ARTICLE

#### Basic Study

- 3132** Neutrophil extracellular traps participate in the development of cancer-associated thrombosis in patients with gastric cancer  
*Li JC, Zou XM, Yang SF, Jin JQ, Zhu L, Li CJ, Yang H, Zhang AG, Zhao TQ, Chen CY*
- 3150** Activation of natural killer T cells contributes to Th1 bias in the murine liver after 14 d of ethinylestradiol exposure  
*Zou MZ, Kong WC, Cai H, Xing MT, Yu ZX, Chen X, Zhang LY, Wang XZ*

- 3164** *Bifidobacterium infantis* regulates the programmed cell death 1 pathway and immune response in mice with inflammatory bowel disease

Zhou LY, Xie Y, Li Y

- 3177** Involvement of Met receptor pathway in aggressive behavior of colorectal cancer cells induced by parathyroid hormone-related peptide

Novoa Díaz MB, Carriere P, Gigola G, Zwenger AO, Calvo N, Gentili C

- 3201** Intracellular alpha-fetoprotein mitigates hepatocyte apoptosis and necroptosis by inhibiting endoplasmic reticulum stress

Chen YF, Liu SY, Cheng QJ, Wang YJ, Chen S, Zhou YY, Liu X, Jiang ZG, Zhong WW, He YH

### Retrospective Cohort Study

- 3218** Divergent trajectories of lean *vs* obese non-alcoholic steatohepatitis patients from listing to post-transplant: A retrospective cohort study

Qazi-Arisar FA, Uchila R, Chen C, Yang C, Chen SY, Karnam RS, Azhie A, Xu W, Galvin Z, Selzner N, Lilly L, Bhat M

### Retrospective Study

- 3232** Tumor-feeding artery diameter reduction is associated with improved short-term effect of hepatic arterial infusion chemotherapy plus lenvatinib treatment

Wu DD, He XF, Tian C, Peng P, Chen CL, Liu XH, Pang HJ

### Observational Study

- 3243** Impact of sodium glucose cotransporter-2 inhibitors on liver steatosis/fibrosis/inflammation and redox balance in non-alcoholic fatty liver disease

Bellanti F, Lo Buglio A, Dobrakowski M, Kasperczyk A, Kasperczyk S, Aich P, Singh SP, Serviddio G, Vendemiale G

## SYSTEMATIC REVIEWS

- 3258** Endoscopic techniques for diagnosis and treatment of gastro-entero-pancreatic neuroendocrine neoplasms: Where we are

Rossi RE, Elvevi A, Gallo C, Palermo A, Invernizzi P, Massironi S

## LETTER TO THE EDITOR

- 3274** Intestinal inflammation and the microbiota: Beyond diversity

Alberca GGF, Cardoso NSS, Solis-Castro RL, Nakano V, Alberca RW

- 3279** Intestinal virome: An important research direction for alcoholic and nonalcoholic liver diseases

Li Y, Liu WC, Chang B

**ABOUT COVER**

Editorial Board Member of *World Journal of Gastroenterology*, Koichi Suda, MD, PhD, FACS, Professor and Head, Divisions of GI and HPB Surgery, Department of Surgery, Fujita Health University, Rm C908, 1-98 Dengakugakubo, Kutsukake, Toyoake, Aichi 470-1192, Japan. ko-suda@fujita-hu.ac.jp

**AIMS AND SCOPE**

The primary aim of *World Journal of Gastroenterology* (WJG, *World J Gastroenterol*) is to provide scholars and readers from various fields of gastroenterology and hepatology with a platform to publish high-quality basic and clinical research articles and communicate their research findings online. WJG mainly publishes articles reporting research results and findings obtained in the field of gastroenterology and hepatology and covering a wide range of topics including gastroenterology, hepatology, gastrointestinal endoscopy, gastrointestinal surgery, gastrointestinal oncology, and pediatric gastroenterology.

**INDEXING/ABSTRACTING**

The WJG is now abstracted and indexed in Science Citation Index Expanded (SCIE, also known as SciSearch®), Current Contents/Clinical Medicine, Journal Citation Reports, Index Medicus, MEDLINE, PubMed, PubMed Central, Scopus, Reference Citation Analysis, China National Knowledge Infrastructure, China Science and Technology Journal Database, and Superstar Journals Database. The 2022 edition of Journal Citation Reports® cites the 2021 impact factor (IF) for WJG as 5.374; IF without journal self cites: 5.187; 5-year IF: 5.715; Journal Citation Indicator: 0.84; Ranking: 31 among 93 journals in gastroenterology and hepatology; and Quartile category: Q2. The WJG's CiteScore for 2021 is 8.1 and Scopus CiteScore rank 2021: Gastroenterology is 18/149.

**RESPONSIBLE EDITORS FOR THIS ISSUE**

Production Editor: Hua-Ge Yu; Production Department Director: Xu Guo; Editorial Office Director: Jia-Ru Fan.

**NAME OF JOURNAL**

*World Journal of Gastroenterology*

**ISSN**

ISSN 1007-9327 (print) ISSN 2219-2840 (online)

**LAUNCH DATE**

October 1, 1995

**FREQUENCY**

Weekly

**EDITORS-IN-CHIEF**

Andrzej S Tarnawski

**EDITORIAL BOARD MEMBERS**

<http://www.wjgnet.com/1007-9327/editorialboard.htm>

**PUBLICATION DATE**

July 14, 2022

**COPYRIGHT**

© 2022 Baishideng Publishing Group Inc

**INSTRUCTIONS TO AUTHORS**

<https://www.wjgnet.com/bpg/gerinfo/204>

**GUIDELINES FOR ETHICS DOCUMENTS**

<https://www.wjgnet.com/bpg/GerInfo/287>

**GUIDELINES FOR NON-NATIVE SPEAKERS OF ENGLISH**

<https://www.wjgnet.com/bpg/gerinfo/240>

**PUBLICATION ETHICS**

<https://www.wjgnet.com/bpg/GerInfo/288>

**PUBLICATION MISCONDUCT**

<https://www.wjgnet.com/bpg/gerinfo/208>

**ARTICLE PROCESSING CHARGE**

<https://www.wjgnet.com/bpg/gerinfo/242>

**STEPS FOR SUBMITTING MANUSCRIPTS**

<https://www.wjgnet.com/bpg/GerInfo/239>

**ONLINE SUBMISSION**

<https://www.f6publishing.com>



## Anabolic androgenic steroid-induced liver injury: An update

Ana Petrovic, Sonja Vukadin, Renata Sikora, Kristina Bojanic, Robert Smolic, Davor Plavec, George Y Wu, Martina Smolic

**Specialty type:** Gastroenterology and hepatology

**Provenance and peer review:**

Invited article; Externally peer reviewed.

**Peer-review model:** Single blind

**Peer-review report's scientific quality classification**

Grade A (Excellent): 0

Grade B (Very good): B, B

Grade C (Good): C

Grade D (Fair): D

Grade E (Poor): 0

**P-Reviewer:** He F, China; Kreisel W, Germany; Liu P, China

**Received:** January 11, 2022

**Peer-review started:** January 11, 2022

**First decision:** March 8, 2022

**Revised:** March 22, 2022

**Accepted:** June 18, 2022

**Article in press:** June 18, 2022

**Published online:** July 14, 2022



**Ana Petrovic, Sonja Vukadin, Robert Smolic, Martina Smolic,** Department of Pharmacology and Biochemistry, Faculty of Dental Medicine and Health Osijek, J. J. Strossmayer University of Osijek, Osijek 31000, Croatia

**Ana Petrovic, Sonja Vukadin, Martina Smolic,** Department of Pharmacology, Faculty of Medicine Osijek, J. J. Strossmayer University of Osijek, Osijek 31000, Croatia

**Renata Sikora,** Department of Dental Medicine, Faculty of Dental Medicine and Health Osijek, J. J. Strossmayer University of Osijek, Osijek 31000, Croatia

**Renata Sikora,** Department of Dental Medicine, Health Center Osijek-Baranja County, Osijek 31000, Croatia

**Kristina Bojanic,** Department of Otorhinolaryngology, Neurosurgery and Radiology, Faculty of Dental Medicine and Health Osijek, J. J. Strossmayer University of Osijek, Osijek 31000, Croatia

**Kristina Bojanic,** Department of Biophysics and Radiology, Faculty of Medicine Osijek, J. J. Strossmayer University of Osijek, Osijek 31000, Croatia

**Kristina Bojanic,** Department of Radiology, Health Center Osijek-Baranja County, Osijek 31000, Croatia

**Davor Plavec,** Research Department, Srebrnjak Children's Hospital, Zagreb 10000, Croatia

**George Y Wu,** Department of Medicine, Division of Gastroenterology/Hepatology, University of Connecticut Health Center, Farmington, CT 06030, United States

**Corresponding author:** Martina Smolic, MD, PhD, Professor, Department of Pharmacology and Biochemistry, Faculty of Dental Medicine and Health Osijek, J. J. Strossmayer University of Osijek, 10E Cara Hadrijana, Osijek 31000, Croatia. [martina.smolic@mefos.hr](mailto:martina.smolic@mefos.hr)

### Abstract

Anabolic androgenic steroids (AASs) are a group of molecules including endogenous testosterone and synthetic derivatives that have both androgenic and anabolic effects. These properties make them therapeutically beneficial in medical conditions such as hypogonadism. However, they are commonly bought illegally and misused for their anabolic, skeletal muscle building, and performance-enhancing effects. Supraphysiologic and long-term use of AASs affects all organs, leading to cardiovascular, neurological, endocrine, gastrointestinal, renal, and hematologic disorders. Hepatotoxicity is one of the major concerns regarding



AASs treatment and abuse. Testosterone and its derivatives have been most often shown to induce a specific form of cholestasis, peliosis hepatis, and hepatic benign and malignant tumors. It is currently believed that mechanisms of pathogenesis of these disorders include disturbance of antioxidative factors, upregulation of bile acid synthesis, and induction of hepatocyte hyperplasia. Most toxicity cases are treated with supportive measures and liver function normalizes with discontinuation of AAS. However, some long-term consequences are irreversible. AAS-induced liver injury should be taken in consideration in patients with liver disorders, especially with the increasing unintentional ingestion of supplements containing AAS. In this paper, we review the most current knowledge about AAS-associated adverse effects on the liver, and their clinical presentations, prevalence, and pathophysiological mechanisms.

**Key Words:** Androgens; Steroids; Cholestasis; Fibrosis; Liver; Chemical and drug induced liver injury

©The Author(s) 2022. Published by Baishideng Publishing Group Inc. All rights reserved.

**Core Tip:** There is a great deal of literature on the prevalence, pathophysiology, and therapeutic options for anabolic androgenic steroid (AAS)-associated adverse effects. However, AAS-induced liver injury is perhaps still underreported and poorly understood. In this paper, we review the latest knowledge obtained about molecular mechanisms of AAS-associated liver injury from most recent *in vitro* and animal studies, as well as the latest case reports regarding adverse effects of AASs in dietary supplements.

**Citation:** Petrovic A, Vukadin S, Sikora R, Bojanic K, Smolic R, Plavec D, Wu GY, Smolic M. Anabolic androgenic steroid-induced liver injury: An update. *World J Gastroenterol* 2022; 28(26): 3071-3080

**URL:** <https://www.wjgnet.com/1007-9327/full/v28/i26/3071.htm>

**DOI:** <https://dx.doi.org/10.3748/wjg.v28.i26.3071>

## INTRODUCTION

Anabolic androgenic steroids (AASs) are group of compounds that include endogenous androgens, most importantly testosterone, and their synthetic derivatives[1]. Testosterone and synthetic AASs have been commonly used for their androgenic masculinizing effects resulting in male secondary characteristics, as well as anabolic skeletal muscle building effects due to enhanced protein utilization and synthesis mechanisms[2,3]. AASs are medically indicated in conditions such as male primary and secondary hypogonadism, aplastic anemia, muscle wasting in human immunodeficiency virus-infected patients, osteoporosis, libido dysfunction, chronic kidney disease, and breast cancer[4]. However, they are often misused because of their performance-enhancing and anabolic effects resulting in increased fat-free mass and improved muscle fiber size and strength. Abuse of AASs for aesthetic purposes and athletic performance improvement has surged as a public health problem in the past few decades among both professional and recreational athletes and bodybuilders[5,6]. Unmodified testosterone is rapidly metabolized when administered orally or parenterally and exerts a similar proportion of anabolic and androgenic effects. Chemical modifications of testosterone allow prolonged effective blood concentrations and changes to its pharmacodynamic properties, therefore enhancing desired anabolic or androgenic effects. In its synthetic derivatives used for aesthetic and performance-enhancing purposes, testosterone is altered mainly through alkylation and esterification to enhance bioavailability by reducing hepatic metabolism, prolong duration of action, and maximize anabolic properties, though all of the synthetic compounds still exert significant androgenic effects. Supraphysiologic doses and prolonged unsupervised use of AASs have major impacts on users, affecting all organs and causing cardiovascular, neuroendocrine, neuropsychiatric, renal, gastrointestinal, musculoskeletal, dermatologic, immune, and hematologic disorders. Testosterone has a major impact on homeostasis of electrolytes, macromolecules, and micromolecules, including alterations in systemic iron balance and erythropoiesis. It has been established that AAS-induced erythropoiesis is mediated by erythropoietin [7]. Most recent studies also imply suppression of hepcidin (a negative regulator of the iron transporter ferroportin) as a mechanism of androgen-induced enhanced iron absorption and incorporation into red blood cells[8]. Some of the most common adverse effects related to AASs are dyslipidemia, hypertension, hypogonadism and infertility, aggression and mood disorders, addiction, and liver and kidney injury[9-11]. This has led to stricter laws regarding availability of AASs, mainly in professional sports organizations which ban anabolic steroid use, and test competitors for the presence of illegal steroids not only because of the unfair advantage in performance, but also because of their potentially dangerous side effects. In legal terms, AASs are classified in the United States as schedule 3 drugs by the

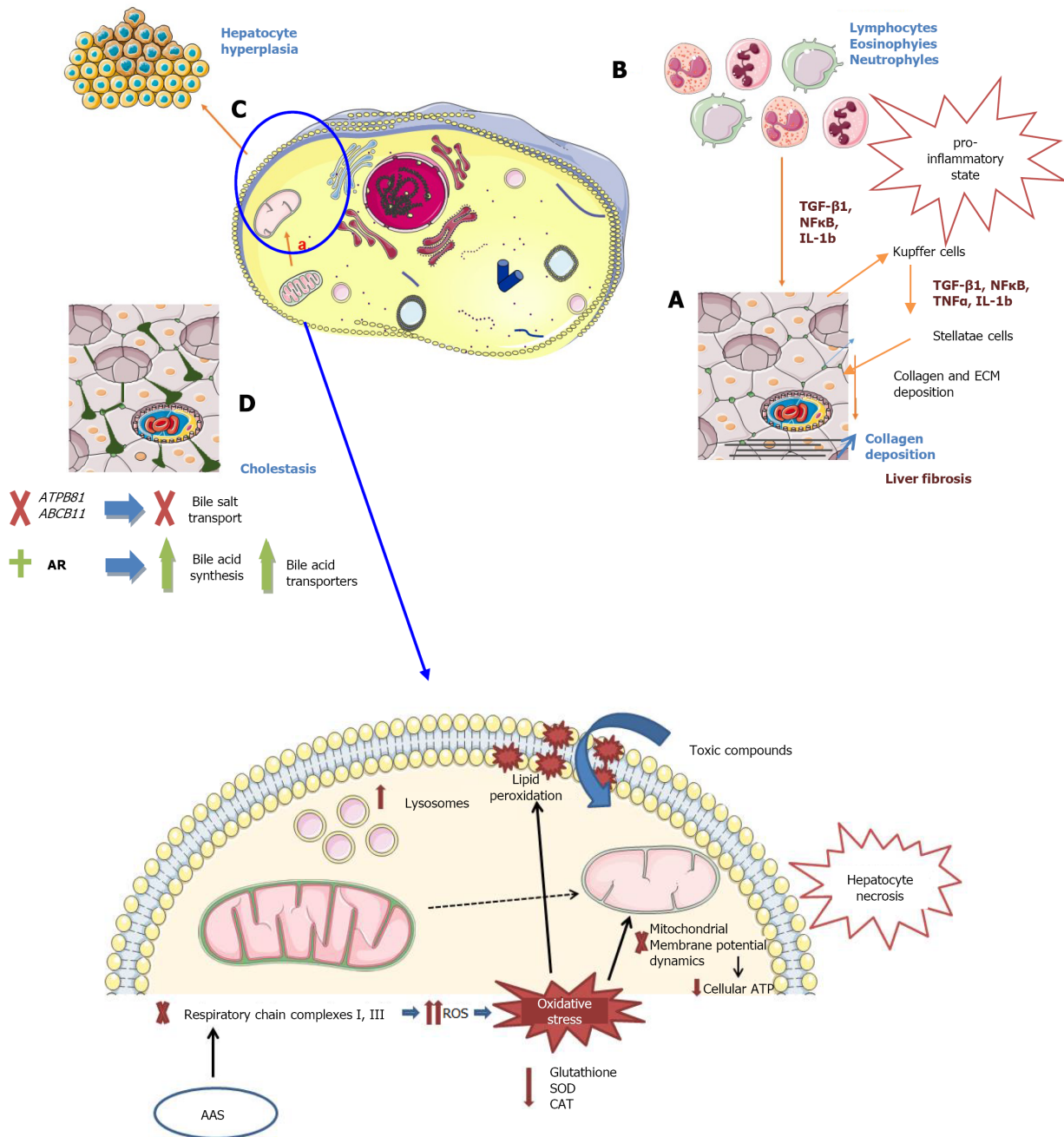
Drug Enforcement Agency, meaning that they can be legally obtained as prescription-only drugs. However, they are illegally sold among teammates, trainers, and fitness centers, through black market or counterfeit prescriptions. Furthermore, many AASs are legally bought and consumed unknowingly in over-the-counter dietary supplements advertised as energy, virility, and muscle strength enhancers [12-14]. Although the precise number of AAS users is difficult to determine, it is estimated that the prevalence across the world is 1%-5% [15]. A study in 2013 found that the prevalence of AAS use among male elite college students in the United States during their lifetime is about 20% [16]. In Norway high school population, a prevalence of 4% was found [17]. While it is difficult to establish a true prevalence of AAS use due to underreporting of this socially undesirable behavior, all the surveys nevertheless found significantly higher AAS use in male compared to female persons and the majority of AAS users are or were professional or near professional athletes [15]. With the liver being the main site of steroid clearance, hepatotoxicity is one of the major adverse effects of chronic AAS use. The aim of this paper is to focus on the most recent studies and knowledge obtained regarding AAS-induced liver injury.

## HEPATOTOXICITY

Since the 1950s, a significant number of studies and case reports have raised concerns regarding hepatotoxic effects including cholestasis, hepatic neoplasms, hepatocyte toxicity, and peliosis hepatis related to use of AASs [11,18]. Correlation between steroids and these effects has been attributed to the role of the liver as the primary clearance site for AASs. As mentioned before, synthetic steroids are usually modified to prevent first-pass hepatic metabolism, preventing their clearance by the liver and, therefore, elevating their risk of hepatotoxicity [19]. Most studies of long-term use have not identified exact dosages and concentrations, administration paths, and types of steroid compounds often used simultaneously. Prospective studies with supraphysiologic doses are difficult to gain institutional review board (IRB) approval due to ethical and legal considerations [20], therefore randomized controlled trials are lacking and in this minireview we discuss data from case reports, *in vitro* studies, and studies on animal models.

Proposed mechanisms of liver injury include anabolic steroid-induced infiltration of inflammatory cells in the hepatic tissue, and Kupffer cell activation resulting in production of inflammatory cytokines and collagen deposition, increased oxidative stress and reactive oxygen species with subsequent mitochondrial degeneration in liver cells, and stimulation of intracellular androgenic steroid receptors inducing unregulated growth of hepatocytes. An *in vitro* study in 2021 reported that disruption of mitochondrial respiratory chain reactions occurs early in the pathogenesis of liver injury caused by supraphysiologic doses of nandrolone, a synthetic AAS commonly used for performance enhancement. It specifically inhibits respiratory chain complexes I and III, which causes accumulation of reactive oxygen species and oxidative stress [21]. Indeed, earlier animal studies detected a reduced amount of glutathione and enzymes that serve as free radical scavengers (superoxide dismutase and catalase) as well as increasing thiobarbituric acid-reactive substances indicating impaired redox homeostasis [22,23]. Furthermore, oxidative stress interfered with mitochondrial membrane potential dynamics [24] and altogether resulted in reduced cell energy supply leading to malfunction and necrosis of hepatocytes. Apart from disturbance in cellular function, distortion in mitochondrial morphology and increased number of lysosomes in hepatocytes were observed by electron microscopy [25]. Another process observed after prolonged administration of nandrolone in animal studies was excess collagen deposition in liver parenchyma. It is known that AASs induce infiltration of the liver with inflammatory cells, which together with activated Kupffer cells, favor a pro-inflammatory state by releasing nuclear factor- $\kappa$ B (NF- $\kappa$ B) and inflammatory cytokines transforming growth factor beta1 (TGF- $\beta$ 1), tumor necrosis factor alpha (TNF $\alpha$ ), and interleukin-1B (IL-1B). Such conditions also lead to activation of liver stellate cells, resulting in excessive collagen synthesis and deposition [26]. Interestingly, AASs can also promote collagen synthesis by activating their intracellular receptor and activation of transcription factors involved in collagen synthesis [27]. A recent study also gave convincing evidence for a role of testosterone in the pathophysiology of liver diseases with higher occurrences in males than in females. It demonstrated that the susceptibility of the mouse liver to injury was correlated with excessive inflammatory response mediated by androgen receptors (ARs) and testosterone-induced NOD-like receptor family pyrin domain containing 3 (NLRP3) inflammasome activation associated with a variety of chronic diseases [28]. Hepatotoxicity of AASs may also vary due to individual susceptibility, pre-existing liver conditions, and genetic factors. Most frequently reported liver disorders related to AASs are cholestasis, peliosis hepatis, and development of liver tumors [11,29-32]. Figure 1 shows an overview of proposed mechanisms of hepatotoxicity caused by AAS.

AAS drug-induced liver injury (AAS DILI) has also been frequently reported to cause serum liver enzyme elevations in AAS users. Elevated aspartate aminotransferase (AST), alanine aminotransferase (ALT), and lactate dehydrogenase (LDH) activities are, in general, regarded as indicators of hepatocellular damage. Transient elevation of AST and ALT in plasma has been largely reported in AAS users [33], but liver damage may not be the cause of the elevations because of the possible contribution of heavy and intense workouts with consequent muscle damage and rhabdomyolysis. Thus, liver enzymes



DOI: 10.3748/wjg.v28.i26.3071 Copyright ©The Author(s) 2022.

**Figure 1 Proposed mechanisms of anabolic androgen steroid-induced liver injury.** A: Oxidative stress in the mitochondria. Anabolic androgenic steroids (AASs) impair mitochondrial respiratory function, which leads to reactive oxygen species (ROS) accumulation. Cell membrane is damaged due to lipid peroxidation and intracellular ATP depletion occurs due to mitochondrial impairment. This results in cellular dysfunction at many levels (e.g., toxic compounds can enter the cell). Mitochondrial morphology is also changed, with reduced cristae and swelling. In addition, there is an increase in lysosome number. Lack of energy supply eventually leads to hepatocyte necrosis; B: Immune cell infiltration of liver parenchyma. Long-term treatment with AASs like nandrolone is associated with immune cell infiltration which maintains proinflammatory state in liver tissue. Under such conditions, Kupffer cells release transforming growth factor beta1 (TGF- $\beta$ 1), tumor necrosis factor alpha (TNF $\alpha$ ), and interleukin-1B (IL-1B) which mediate hepatic stellate cell activation: Extracellular matrix and collagen deposition leading to liver fibrosis; C: Hepatocyte hyperplasia causes formation of hepatic tumors. In rats treated with high-dose nandrolone, it was observed that it supported the viability of hepatic stem cells, which are potential reservoir of cancer stem cells. Nodular hepatocyte hyperplasia causes parenchyma distortion and mechanical blockage of vasculature which forms cystic lesions filled with blood, known as peliosis hepatic; D: "Bland cholestasis". Activation of androgen receptors (ARs) by AASs interferes with bile transporters, mediates intrahepatic microfilament damage, and increases expression of genes for acid bile and bile transporter synthesis, and these changes result in bile acid accumulation, cholestasis, and cholestatic jaundice. SOD: Superoxide dismutase; CAT: Catalase; AR: Androgene receptor; AAS: Anabolic androgenic steroid; AR: Androgen receptor. Figure created with Servier Medical Art, <https://smart.servier.com/>.



can be elevated independent of androgenic steroid use. Studies showing elevations of creatine kinase (CK) and AST, with no ALT and gamma glutamyl transferase (GGT) elevations, support this concept and suggest that hepatotoxicity related to AASs may be over-estimated if serum ALT, AST, and GGT concentrations are the sole criteria used[34]. Furthermore, a recent multi-center prospective study regarding the incidence of liver injury in transgender patients treated with hormone therapy including AASs showed no significant ALT, AST, alkaline phosphatase (ALP), or GGT elevations[35]. Most of the hepatotoxic effects, cholestasis, peliosis, and liver tumors are associated with orally administered AASs such as testosterone cypionate, enanthate, propionate, methyltestosterone, oxymetholone, danazol, stanozolol, formebolone, and methandienone[36,37], but intramuscular preparations were also linked to hepatotoxic effects[38]. Patil *et al*[38] reported three cases of AAS-induced hepatotoxicity which all manifested differently. The first case was a 31-year-old man who developed cholestatic liver injury after 2 mo of oxymetholone use, the second case was a 24-year-old man who developed well-differentiated hepatocellular carcinomas (HCC) and multiple hepatic adenomas after 3 years of intramuscular testosterone decanoate and daily oral stanozolol use, and the third case was a 36-year-old man with steatohepatitis after 2 mo of intramuscular nandrolone decanoate use[38]. The exact incidence of AAS DILI is difficult to establish due to both underreporting and lack of awareness. On the other hand, even when a history of AAS use is known, it may be difficult to establish the causality, particularly when multiple agents are used concomitantly or if there is an underlying liver condition. However, there has been a trend of increased AAS DILI reporting in recent years which may lead to new insights into pathophysiology and disease course. According to currently available data, AAS DILI has a good prognosis as the majority of cases recover completely and only a very small number of cases develop hepatic failure or die[39].

## CHOLESTASIS

Although cholestasis is unlikely in patients treated with parenterally administered unmodified testosterone, 17 $\alpha$ -alkyl-substituted steroids, which are designed to decrease hepatic metabolism, directly contribute to a highly characteristic form of acute cholestasis, ranging from very mild to severe. Some characteristic clinical manifestations are nausea, pruritus, fatigue, jaundice, and dark urine with elevated bilirubin and ALP, but without significant elevations of AST, ALT, and GGT. Such characteristics are indicative of cholestasis with minimal inflammation of the liver or bile duct. Resolution usually occurs upon discontinuation of anabolic steroids, although some case reports indicate benefits of hydrocortisone and ursodeoxycholic acid treatment[13,39-42].

Some animal model studies have suggested AAS-induced disruption of intrahepatic microfilaments and interference with bile transporter proteins as a pathophysiological mechanism of this syndrome rather than inflammation and injury to the liver and bile duct[29,43]. El-Sherrif *et al*[13] reported two cases of cholestatic DILI caused by the short-term use of AAS-containing dietary supplement Mass-Drol. The authors found that inhibition of expression of genes *ATPB81* and *ABCB11* by AAS may play a crucial role as the underlying mechanism of cholestatic injury. This leads to impaired bile salt transport and also reduced excretion of different hepatic ectoenzymes. Indeed, both patients presented with cholestasis with marked hyperbilirubinemia, but lack of GGT rise. The authors postulated that individuals who are carriers of c.2093G >A mutation in *ABCB11* may be specifically susceptible to cholestatic hepatic injury caused by AASs due to this mechanism[13]. Additionally, the role of multidrug-related proteins (MRP2, MRP3, and MRP4) is important in bile acid transfer as a complementary mechanism. It was shown that testosterone metabolites are substrates of MRP2 protein, which has reduced activity in Dubin-Johnson syndrome (DJS). The effect of AAS in DJS has not been investigated to our knowledge, whereas it was found that pregnancy and oral contraceptives increase bilirubin levels in women with DJS[44]. Different underlying mechanism was proposed by Petrov *et al* [45], who used an *in vitro* model to demonstrate that AR activation may upregulate the expression of bile acid synthesis genes as well as bile acid transporters. Most recent studies have reported that the patterns of "bland" cholestasis in AAS users are so specific that this picture can be virtually sufficient to make a diagnosis of AAS-induced cholestasis[46]. Many reports refer to these phenomena as AAS DILI [39,47].

## PELIOSIS HEPATIS

Peliosis hepatis is a rare condition characterized by hypervascular liver parenchyma and blood-filled cysts that is known to be associated with use of AASs and several other drugs like estrogens, corticosteroids, and azathioprine. So far, disruption of hepatic extracellular matrix and direct endothelial cell injury have been suggested as generating mechanisms for liver peliosis. It has also been proposed that steroid-induced hepatocyte hyperplasia results in mechanical obstruction of hepatic vascular system, causing dilatation and loss of endothelial barrier function[11,30,48]. Molecular mechanisms in pathophysiology of peliosis remain poorly understood; however, an important role of vascular

endothelial growth factor (VEGF) has been suggested in recent studies. VEGF induces angiogenesis, capillary permeability, and proliferation of endothelial cells in liver and other tissues. Tzirogiannis *et al* [49] found a major protective effect of VEGF which almost totally reversed the extent of peliosis in a model of cadmium-induced toxic liver injury and peliosis, implying that it preserves endothelial cell function. However, a study of peliosis hepatitis in a patient with follicular lymphoma found elevated VEGF and suggested that lesions could be caused by elevation of VEGF and its angiogenic effects[50]. An animal model study of peliosis hepatitis associated with melanoma supports a concept that a tumor-derived factor such as VEGF could induce development of peliosis due to its endothelial cell proliferation effect[51]. These conclusions indicate a need for further research of pathophysiology in peliosis hepatitis as well as AASs and their impact on growth factors. Peliosis hepatitis is commonly asymptomatic, but case reports described presentation characterized by sharp abdominal pain and hemoperitoneum in cases of cyst rupture[52]. Peliosis is usually treated with supportive care and the condition has shown to regress with discontinuation of AASs[53,54]. The condition has been reported not only in use of 17-alpha-alkylated steroids, but also in patients treated with unmodified testosterone[19]. Given its benign nature, most cases of peliosis hepatitis are incidentally found and the most appropriate diagnostic modalities are magnetic resonance imaging[55] and histological examination. Once diagnosed, the offending drug should be discontinued and the condition closely monitored to reduce the risk of rupture, especially with larger lesions.

## NEOPLASMS

Hepatic tumors, ranging from benign adenomas to malignant hepatocellular carcinoma, have been reported in patients with long-term anabolic steroid therapy[56-58]. Studies have suggested a higher hepatic cancer prevalence in males than in females. Higher endogenous concentrations of androgens may be a major factor in the development of liver carcinomas. Having both the estrogen and ARs, the liver is a hormone sensitive organ. The use of AASs is highly associated with hepatocyte proliferation and liver tumors[59]. An *in vitro* study on HepG2 cells showed that a supraphysiologic dose of nandrolone changed their phenotype to be stem-like, but the mechanism of this transformation remains to be elucidated. In the same study, nandrolone administered *in vivo* in a mouse model promoted "stemness" in healthy organs, primarily ones naturally rich in stem cells such as the liver. Cell "stemness" phenotype is a metabolically latent state in which there is a lower oxygen consumption in the mitochondria. Expression of *Nanog*, *Lin28*, *Myc*, and *Klf4* genes and CD133 membrane protein is also considered to be markers of cell stemness. This led to a hypothesis that long-term supraphysiologic doses of nandrolone in young healthy individuals possibly increase the risk of malignancy in stem-cell rich organs by increasing the reservoir of stem cells which over a period of time under additional toxic stimuli may turn into cancer stem cells[21]. Studies to date indicate that most of AAS-induced tumors occur with use of agents containing a 17-alpha-alkyl group, but it has also been reported in patients treated with unmodified testosterone[56,60,61]. Histologically, these tumors are most commonly hepatic adenomas or HCC, but cholangiocarcinomas and angiosarcomas have also been reported with long-term AAS use[20]. Given the possibility of malignant transformation of hepatic adenoma, which occurs 10 times more commonly in men than in women, it is recommended that surgical resection be the most appropriate approach in men. In women, estrogen-containing oral contraceptives are a common cause, so their cessation, together with periodic surveillance, is an acceptable approach[62,63]. Solimini *et al*[11] reviewed case reports regarding liver tumors as well as cholestatic hepatitis associated with AASs and reported that several different AAS agents were associated with such liver pathology. Notably, chronic AAS use of several years is linked to development of HCC, while benign neoplasms were mostly linked to short-term use of AAS[11].

## ADDITIONAL CONCERNS REGARDING AASS AND THE LIVER

Other hepatic disorders associated with AASs include toxicant-associated fatty liver disease (TAFLD), and possible increased risk of hepatitis B and C infections due to unsafe administration of AASs[64]. In addition, a negative effect on lipoproteins with reduced HDL-cholesterol and increased LDL-cholesterol concentrations has been reported mostly in long-term steroid users[65,66], which contribute to increased risk of coronary disease with AAS use.

Another concerning issue is the increasing number of mislabeled over-the-counter dietary supplements sold legally and containing significant amount of AASs. This has also been associated with adverse effects, but remains underreported and poorly understood. However, new case reports have been published on DILI with jaundice, cholestasis, dyslipidemia, and elevated serum liver enzyme panels in patients directly associated with dietary supplement use. After discontinuation of supplements, liver function commonly returned to normal[67,68]. Consumers may unknowingly use AASs which can result in acute, but also chronic, health problems that are difficult to link to these products and lead to re-exposure[69-71].

## CONCLUSION

AAS use is closely linked to hepatotoxicity and serious hepatic conditions such as cholestasis, peliosis hepatis, and benign and malignant hepatic tumors, as well as steatohepatitis and dyslipidemia with multiple studies supporting a causal association. Several pathophysiological mechanisms have been proposed including AR receptor-mediated inflammatory response, disturbance of hepatic antioxidant factors, promotion of hepatocyte hyperplasia, and upregulation of bile acid synthesis. Most of these conditions have been reported with 17- $\alpha$ -alkylated steroids. Liver function usually returns to normal with discontinuation of use, but a higher HCC prevalence with AASs is concerning. Another important fact is the increasing number of case reports presenting patients with dietary supplements-associated liver conditions that are still underreported. Given all of the above, screening for liver pathology in known AAS users should be considered in order to possibly reverse the condition. Also, if certain liver pathology is diagnosed incidentally, a history of AAS as potential causal agent should be actively sought, and if found, addressed promptly.

## FOOTNOTES

**Author contributions:** Petrovic A, Smolic R, Smolic M, and Wu GY designed the research study; Petrovic A, Vukadin S, Sikora R, Bojanic K, Plavec D, and Smolic M performed the research; Petrovic A and Vukadin S analyzed the data and wrote the manuscript; all authors have read and approved the final manuscript.

**Conflict-of-interest statement:** There are no conflicts of interest to report.

**Open-Access:** This article is an open-access article that was selected by an in-house editor and fully peer-reviewed by external reviewers. It is distributed in accordance with the Creative Commons Attribution NonCommercial (CC BY-NC 4.0) license, which permits others to distribute, remix, adapt, build upon this work non-commercially, and license their derivative works on different terms, provided the original work is properly cited and the use is non-commercial. See: <https://creativecommons.org/licenses/by-nc/4.0/>

**Country/Territory of origin:** Croatia

**ORCID number:** Ana Petrovic 0000-0001-5585-3121; Sonja Vukadin 0000-0002-1636-2538; Renata Sikora 0000-0001-8594-549X; Kristina Bojanic 0000-0003-4473-5706; Robert Smolic 0000-0003-4614-4344; Davor Plavec 0000-0003-2020-8119; George Y. Wu 0000-0003-0068-1072; Martina Smolic 0000-0002-6867-826X.

**S-Editor:** Chen YL

**L-Editor:** Wang TQ

**P-Editor:** Chen YL

## REFERENCES

- 1 Roman M, Roman DL, Ostafe V, Ciorsac A, Isvoran A. Computational Assessment of Pharmacokinetics and Biological Effects of Some Anabolic and Androgen Steroids. *Pharm Res* 2018; **35**: 41 [PMID: 29404794 DOI: 10.1007/s11095-018-2353-1]
- 2 Mullen C, Whalley BJ, Schifano F, Baker JS. Anabolic androgenic steroid abuse in the United Kingdom: An update. *Br J Pharmacol* 2020; **177**: 2180-2198 [PMID: 31989581 DOI: 10.1111/bph.14995]
- 3 Barceloux DG, Palmer RB. Anabolic-androgenic steroids. *Dis Mon* 2013; **59**: 226-248 [PMID: 23719201 DOI: 10.1016/j.disamonth.2013.03.010]
- 4 Margo K, Winn R. Testosterone treatments: why, when, and how? *Am Fam Physician* 2006; **73**: 1591-1598 [PMID: 16719252]
- 5 Basaria S. Androgen abuse in athletes: detection and consequences. *J Clin Endocrinol Metab* 2010; **95**: 1533-1543 [PMID: 20139230 DOI: 10.1210/jc.2009-1579]
- 6 Bhasin S, Storer TW, Berman N, Callegari C, Clevenger B, Phillips J, Bunnell TJ, Tricker R, Shirazi A, Casaburi R. The effects of supraphysiologic doses of testosterone on muscle size and strength in normal men. *N Engl J Med* 1996; **335**: 1-7 [PMID: 8637535 DOI: 10.1056/NEJM199607043350101]
- 7 Shahidi NT. Androgens and erythropoiesis. *N Engl J Med* 1973; **289**: 72-80 [PMID: 4575719 DOI: 10.1056/NEJM197307122890205]
- 8 Beggs LA, Yarrow JF, Conover CF, Meuleman JR, Beck DT, Morrow M, Zou B, Shuster JJ, Borst SE. Testosterone alters iron metabolism and stimulates red blood cell production independently of dihydrotestosterone. *Am J Physiol Endocrinol Metab* 2014; **307**: E456-E461 [PMID: 25074984 DOI: 10.1152/ajpendo.00184.2014]
- 9 Hoffman JR, Ratamess NA. Medical issues associated with anabolic steroid use: are they exaggerated? *J Sports Sci Med* 2006; **5**: 182-193 [PMID: 24259990]
- 10 Pope HG Jr, Wood RI, Rogol A, Nyberg F, Bowers L, Bhasin S. Adverse health consequences of performance-enhancing drugs: an Endocrine Society scientific statement. *Endocr Rev* 2014; **35**: 341-375 [PMID: 24423981 DOI: 10.1210/er.2013-1058]

- 11 **Solimini R**, Rotolo MC, Mastrobattista L, Mortali C, Minutillo A, Pichini S, Pacifici R, Palmi I. Hepatotoxicity associated with illicit use of anabolic androgenic steroids in doping. *Eur Rev Med Pharmacol Sci* 2017; **21**: 7-16 [PMID: [28379599](#)]
- 12 **Rahnema CD**, Crosnoe LE, Kim ED. Designer steroids - over-the-counter supplements and their androgenic component: review of an increasing problem. *Andrology* 2015; **3**: 150-155 [PMID: [25684733](#) DOI: [10.1111/andr.307](#)]
- 13 **El Sherrif Y**, Potts JR, Howard MR, Barnardo A, Cairns S, Knisely AS, Verma S. Hepatotoxicity from anabolic androgenic steroids marketed as dietary supplements: contribution from ATP8B1/ABCB11 mutations? *Liver Int* 2013; **33**: 1266-1270 [PMID: [23750872](#) DOI: [10.1111/liv.12216](#)]
- 14 **DEA**. Drugs of abuse. In: Administration. United States department of justice, 2020
- 15 **Anawalt BD**. Diagnosis and Management of Anabolic Androgenic Steroid Use. *J Clin Endocrinol Metab* 2019; **104**: 2490-2500 [PMID: [30753550](#) DOI: [10.1210/je.2018-01882](#)]
- 16 **Buckman JF**, Farris SG, Yusko DA. A national study of substance use behaviors among NCAA male athletes who use banned performance enhancing substances. *Drug Alcohol Depend* 2013; **131**: 50-55 [PMID: [23688842](#) DOI: [10.1016/j.drugalcdep.2013.04.023](#)]
- 17 **Jenssen IH**, Johannessen KB. Aggression and body image concerns among anabolic androgenic steroid users, contemplators, and controls in Norway. *Body Image* 2015; **12**: 6-13 [PMID: [25261635](#) DOI: [10.1016/j.bodyim.2014.08.009](#)]
- 18 **Quaglio G**, Fornasiero A, Mezzelani P, Moreschini S, Lugoboni F, Lechi A. Anabolic steroids: dependence and complications of chronic use. *Intern Emerg Med* 2009; **4**: 289-296 [PMID: [19468827](#) DOI: [10.1007/s11739-009-0260-5](#)]
- 19 **Shahidi NT**. A review of the chemistry, biological action, and clinical applications of anabolic-androgenic steroids. *Clin Ther* 2001; **23**: 1355-1390 [PMID: [11589254](#) DOI: [10.1016/s0149-2918\(01\)80114-4](#)]
- 20 **Niedfeldt MW**. Anabolic Steroid Effect on the Liver. *Curr Sports Med Rep* 2018; **17**: 97-102 [PMID: [29521706](#) DOI: [10.1249/JSR.0000000000000467](#)]
- 21 **Agriesti F**, Tataranni T, Pacelli C, Scrima R, Laurenzana I, Ruggieri V, Cela O, Mazzocchi C, Salerno M, Sessa F, Sani G, Pomara C, Capitanio N, Piccoli C. Nandrolone induces a stem cell-like phenotype in human hepatocarcinoma-derived cell line inhibiting mitochondrial respiratory activity. *Sci Rep* 2020; **10**: 2287 [PMID: [32041983](#) DOI: [10.1038/s41598-020-58871-1](#)]
- 22 **Sadowska-Krępa E**, Kłapińska B, Nowara A, Jagusz S, Szoltysek-Boldys I, Chalimoniuk M, Langfort J, Chrapusta SJ. High-dose testosterone supplementation disturbs liver pro-oxidant/antioxidant balance and function in adolescent male Wistar rats undergoing moderate-intensity endurance training. *PeerJ* 2020; **8**: e10228 [PMID: [33240609](#) DOI: [10.7717/peerj.10228](#)]
- 23 **Lima EM**, Cassaro KODS, Silva CLD, Silva MA, Poltronieri MP, Nascimento AMD, Andrade TU, Bissoli NS, Brasil GA. Eight weeks of treatment with nandrolone decanoate in female rats promotes disruption in the redox homeostasis and impaired renal function. *Life Sci* 2020; **242**: 117227 [PMID: [31881226](#) DOI: [10.1016/j.lfs.2019.117227](#)]
- 24 **Carteri RB**, Kopczynski A, Rodolphi MS, Strogulski NR, Wannmacher CMD, Franceschi ID, Hammerschmitt ME, Driemeier D, Portela LV. Anabolic-androgenic steroids impair mitochondrial function and redox status in the heart and liver of mice. *Steroids* 2021; **172**: 108861 [PMID: [33984388](#) DOI: [10.1016/j.steroids.2021.108861](#)]
- 25 **Gragera R**, Saborido A, Molano F, Jiménez L, Muñiz E, Megias A. Ultrastructural changes induced by anabolic steroids in liver of trained rats. *Histol Histopathol* 1993; **8**: 449-455 [PMID: [8358156](#)]
- 26 **Shalaby AM**, Bahey NG. Reversal of the hepatic damage induced by the supraphysiological dose of nandrolone decanoate after its withdrawal in the adult male rat. *Tissue Cell* 2018; **53**: 44-52 [PMID: [30060826](#) DOI: [10.1016/j.tice.2018.05.013](#)]
- 27 **Markova MS**, Zeskand J, McEntee B, Rothstein J, Jimenez SA, Siracusa LD. A role for the androgen receptor in collagen content of the skin. *J Invest Dermatol* 2004; **123**: 1052-1056 [PMID: [15610513](#) DOI: [10.1111/j.0022-202X.2004.23494.x](#)]
- 28 **Ma X**, Zhou Y, Qiao B, Jiang S, Shen Q, Han Y, Liu A, Chen X, Wei L, Zhou L, Zhao J. Androgen aggravates liver fibrosis by activation of NLRP3 inflammasome in CCl<sub>4</sub>-induced liver injury mouse model. *Am J Physiol Endocrinol Metab* 2020; **318**: E817-E829 [PMID: [32182125](#) DOI: [10.1152/ajpendo.00427.2019](#)]
- 29 **Neri M**, Bello S, Bonsignore A, Cantatore S, Riezzo I, Turillazzi E, Fineschi V. Anabolic androgenic steroids abuse and liver toxicity. *Mini Rev Med Chem* 2011; **11**: 430-437 [PMID: [21443508](#) DOI: [10.2174/138955711795445916](#)]
- 30 **Vieira RP**, França RF, Damaceno-Rodrigues NR, Dolhnikoff M, Caldini EG, Carvalho CR, Ribeiro W. Dose-dependent hepatic response to subchronic administration of nandrolone decanoate. *Med Sci Sports Exerc* 2008; **40**: 842-847 [PMID: [18408615](#) DOI: [10.1249/MSS.0b013e3181666f1c](#)]
- 31 **Schwingel PA**, Cotrim HP, Salles BR, Almeida CE, dos Santos CR Jr, Nachev B, Andrade AR, Zoppi CC. Anabolic-androgenic steroids: a possible new risk factor of toxicant-associated fatty liver disease. *Liver Int* 2011; **31**: 348-353 [PMID: [21040407](#) DOI: [10.1111/j.1478-3231.2010.02346.x](#)]
- 32 **Riezzo I**, Turillazzi E, Bello S, Cantatore S, Cerretani D, Di Paolo M, Fiaschi AI, Frati P, Neri M, Pedretti M, Fineschi V. Chronic nandrolone administration promotes oxidative stress, induction of pro-inflammatory cytokine and TNF- $\alpha$  mediated apoptosis in the kidneys of CD1 treated mice. *Toxicol Appl Pharmacol* 2014; **280**: 97-106 [PMID: [25065671](#) DOI: [10.1016/j.taap.2014.06.031](#)]
- 33 **Hartgens F**, Kuipers H. Effects of androgenic-anabolic steroids in athletes. *Sports Med* 2004; **34**: 513-554 [PMID: [15248788](#) DOI: [10.2165/00007256-200434080-00003](#)]
- 34 **Dickerman RD**, Pertusi RM, Zachariah NY, Dufour DR, McConathy WJ. Anabolic steroid-induced hepatotoxicity: is it overstated? *Clin J Sport Med* 1999; **9**: 34-39 [PMID: [10336050](#) DOI: [10.1097/00042752-199901000-00007](#)]
- 35 **A Stangl T**, M Wiepjes C, Defreyne J, Conemans E, D Fisher A, Schreiner T, T'Sjoen G, den Heijer M. Is there a need for liver enzyme monitoring in people using gender-affirming hormone therapy? *Eur J Endocrinol* 2021; **184**: 513-520 [PMID: [33524005](#) DOI: [10.1530/EJE-20-1064](#)]
- 36 **Büttner A**, Thieme D. Side effects of anabolic androgenic steroids: pathological findings and structure-activity relationships. *Handb Exp Pharmacol* 2010; 459-484 [PMID: [20020376](#) DOI: [10.1007/978-3-540-79088-4\\_19](#)]
- 37 **Maravelias C**, Dona A, Stefanidou M, Spiliopoulou C. Adverse effects of anabolic steroids in athletes. A constant threat. *Toxicol Lett* 2005; **158**: 167-175 [PMID: [16005168](#) DOI: [10.1016/j.toxlet.2005.06.005](#)]
- 38 **Patil V**, Jothamani D, Harika K, Hakeem AR, Sachan D, Vij M, Rela M. Versatility of Anabolic Androgenic Steroid-



- Induced Hepatotoxicity. *J Clin Exp Hepatol* 2022; **12**: 216-221 [PMID: 35068803 DOI: 10.1016/j.jceh.2021.03.003]
- 39 **Abeles RD**, Foxton M, Khan S, Goldin R, Smith B, Thursz MR, Verma S. Androgenic anabolic steroid-induced liver injury: two case reports assessed for causality by the updated Roussel Uclaf Causality Assessment Method (RUCAM) score and a comprehensive review of the literature. *BMJ Open Gastroenterol* 2020; **7** [PMID: 33214235 DOI: 10.1136/bmjgast-2020-000549]
  - 40 **Robles-Díaz M**, Gonzalez-Jimenez A, Medina-Caliz I, Stephens C, García-Cortes M, García-Muñoz B, Ortega-Alonso A, Blanco-Reina E, Gonzalez-Grande R, Jimenez-Perez M, Rendón P, Navarro JM, Gines P, Prieto M, Garcia-Eliz M, Bessone F, Brahm JR, Paraná R, Lucena MI, Andrade RJ; Spanish DILI Registry; SLatinDILI Network. Distinct phenotype of hepatotoxicity associated with illicit use of anabolic androgenic steroids. *Aliment Pharmacol Ther* 2015; **41**: 116-125 [PMID: 25394890 DOI: 10.1111/apt.13023]
  - 41 **Kafrouni MI**, Anders RA, Verma S. Hepatotoxicity associated with dietary supplements containing anabolic steroids. *Clin Gastroenterol* 2007; **5**: 809-812 [PMID: 17509944 DOI: 10.1016/j.cgh.2007.02.036]
  - 42 **Stępień PM**, Reczko K, Wiecek A, Zarębska-Michaluk D, Pabjan P, Król T, Kryczka W. Severe intrahepatic cholestasis and liver failure after stanozolol usage - case report and review of the literature. *Clin Exp Hepatol* 2015; **1**: 30-33 [PMID: 28856252 DOI: 10.5114/ceh.2015.51376]
  - 43 **Modlinski R**, Fields KB. The effect of anabolic steroids on the gastrointestinal system, kidneys, and adrenal glands. *Curr Sports Med Rep* 2006; **5**: 104-109 [PMID: 16529682 DOI: 10.1097/01.csmr.0000306529.74500.f6]
  - 44 **Erlinger S**, Arias IM, Dhumeaux D. Inherited disorders of bilirubin transport and conjugation: new insights into molecular mechanisms and consequences. *Gastroenterology* 2014; **146**: 1625-1638 [PMID: 24704527 DOI: 10.1053/j.gastro.2014.03.047]
  - 45 **Petrov PD**, Fernández-Murga L, Conde I, Martínez-Sena T, Guzmán C, Castell JV, Jover R. Epistane, an anabolic steroid used for recreational purposes, causes cholestasis with elevated levels of cholic acid conjugates, by upregulating bile acid synthesis (CYP8B1) and cross-talking with nuclear receptors in human hepatocytes. *Arch Toxicol* 2020; **94**: 589-607 [PMID: 31894354 DOI: 10.1007/s00204-019-02643-y]
  - 46 **Chopra S**, Gawrieh S, Vuppalandhi R, Saxena R. Role of the Surgical Pathologist in Diagnosis of Drug-induced Liver Injury: Recognizing Specific Patterns of Drug Injury. *Adv Anat Pathol* 2021; **28**: 383-395 [PMID: 34050060 DOI: 10.1097/PAP.0000000000000307]
  - 47 **Goh HG**, Lee YJ, Kim TH. Severe Persistent Jaundice after the Abuse of an Anabolic Androgenic Steroid Analogue. *Korean J Gastroenterol* 2020; **76**: 167-170 [PMID: 32969366 DOI: 10.4166/kjg.2020.76.3.167]
  - 48 **Tsirigotis P**, Sella T, Shapira MY, Bitan M, Bloom A, Kiselgoff D, Levin M, Libster D, Abdul Hai A, Gesundheit B, Or R, Slavin S, Resnick I. Peliosis hepatis following treatment with androgen-steroids in patients with bone marrow failure syndromes. *Haematologica* 2007; **92**: e106-e110 [PMID: 18024386 DOI: 10.3324/haematol.11343]
  - 49 **Tzirogiannis KN**, Papadimas GK, Kondyli VG, Kourentzi KT, Demonakou MD, Kyriakou LG, Mykoniatis MG, Hereti RI, Panoutsopoulos GI. Peliosis hepatis: microscopic and macroscopic type, time pattern, and correlation with liver cell apoptosis in a model of toxic liver injury. *Dig Dis Sci* 2006; **51**: 1998-2006 [PMID: 17053957 DOI: 10.1007/s10620-006-9242-x]
  - 50 **de la Mano EP**, Martín-Sánchez G, López RL, Galán MAF, Ríos ST, Jiménez MJM, de Morales JMGR, Santos MAC, Núñez GM. Peliosis hepatis associated with follicular lymphoma with a rise in vascular endothelial growth factor and anaemia of inflammation. *Ecancermedicallscience* 2018; **12**: 882 [PMID: 30679949 DOI: 10.3332/ecancer.2018.882]
  - 51 **Edwards R**, Colombo T, Greaves P. "Have you seen this? *Toxicol Pathol* 2002; **30**: 521-523 [PMID: 12187943 DOI: 10.1080/01926230290105686]
  - 52 **Choi SK**, Jin JS, Cho SG, Choi SJ, Kim CS, Choe YM, Lee KY. Spontaneous liver rupture in a patient with peliosis hepatis: a case report. *World J Gastroenterol* 2009; **15**: 5493-5497 [PMID: 19916182 DOI: 10.3748/wjg.15.5493]
  - 53 **Nadell J**, Kosek J. Peliosis hepatis. Twelve cases associated with oral androgen therapy. *Arch Pathol Lab Med* 1977; **101**: 405-410 [PMID: 577673]
  - 54 **Fidelman N**, LaBerge JM, Kerlan RK Jr. SCVIR 2002 Film Panel case 4: massive intraperitoneal hemorrhage caused by peliosis hepatis. *J Vasc Interv Radiol* 2002; **13**: 542-545 [PMID: 11997366 DOI: 10.1016/s1051-0443(07)61539-5]
  - 55 **Hui CL**, Lee ZJ. Hepatic disorders associated with exogenous sex steroids: MR imaging findings. *Abdom Radiol (NY)* 2019; **44**: 2436-2447 [PMID: 30955069 DOI: 10.1007/s00261-019-01941-4]
  - 56 **Nakao A**, Sakagami K, Nakata Y, Komazawa K, Amimoto T, Nakashima K, Isozaki H, Takakura N, Tanaka N. Multiple hepatic adenomas caused by long-term administration of androgenic steroids for aplastic anemia in association with familial adenomatous polyposis. *J Gastroenterol* 2000; **35**: 557-562 [PMID: 10905366 DOI: 10.1007/s005350070081]
  - 57 **Evert M**, Dombrowski F. [Hepatocellular carcinoma in the non-cirrhotic liver]. *Pathologe* 2008; **29**: 47-52 [PMID: 18057936 DOI: 10.1007/s00292-007-0953-3]
  - 58 **Socas L**, Zumbado M, Pérez-Luzardo O, Ramos A, Pérez C, Hernández JR, Boada LD. Hepatocellular adenomas associated with anabolic androgenic steroid abuse in bodybuilders: a report of two cases and a review of the literature. *Br J Sports Med* 2005; **39**: e27 [PMID: 15849280 DOI: 10.1136/bjsm.2004.013599]
  - 59 **Velazquez I**, Alter BP. Androgens and liver tumors: Fanconi's anemia and non-Fanconi's conditions. *Am J Hematol* 2004; **77**: 257-267 [PMID: 15495253 DOI: 10.1002/ajh.20183]
  - 60 **El-Serag HB**. Hepatocellular carcinoma: recent trends in the United States. *Gastroenterology* 2004; **127**: S27-S34 [PMID: 15508094 DOI: 10.1053/j.gastro.2004.09.013]
  - 61 **Tanaka K**, Sakai H, Hashizume M, Hirohata T. Serum testosterone:estradiol ratio and the development of hepatocellular carcinoma among male cirrhotic patients. *Cancer Res* 2000; **60**: 5106-5110 [PMID: 11016636]
  - 62 **Farges O**, Ferreira N, Dokmak S, Belghiti J, Bedossa P, Paradis V. Changing trends in malignant transformation of hepatocellular adenoma. *Gut* 2011; **60**: 85-89 [PMID: 21148580 DOI: 10.1136/gut.2010.222109]
  - 63 **European Association for the Study of the Liver (EASL)**. EASL Clinical Practice Guidelines on the management of benign liver tumours. *J Hepatol* 2016; **65**: 386-398 [PMID: 27085809 DOI: 10.1016/j.jhep.2016.04.001]
  - 64 **Aitken C**, Delalande C, Stanton K. Pumping iron, risking infection? *Drug Alcohol Depend* 2002; **65**: 303-308 [PMID: 11841901 DOI: 10.1016/s0376-8716(01)00174-0]

- 65 **Hartgens F**, Rietjens G, Keizer HA, Kuipers H, Wolffenbuttel BH. Effects of androgenic-anabolic steroids on apolipoproteins and lipoprotein (a). *Br J Sports Med* 2004; **38**: 253-259 [PMID: [15155420](#) DOI: [10.1136/bjsm.2003.000199](#)]
- 66 **Kouri EM**, Pope HG Jr, Oliva PS. Changes in lipoprotein-lipid levels in normal men following administration of increasing doses of testosterone cypionate. *Clin J Sport Med* 1996; **6**: 152-157 [PMID: [8792045](#) DOI: [10.1097/00042752-199607000-00003](#)]
- 67 **Magge CD**, Witte S, Kwok RM, Deuster PA. Mission Compromised? *Mil Med* 2016; **181**: e1169-e1171 [PMID: [27612377](#) DOI: [10.7205/MILMED-D-15-00502](#)]
- 68 **Cabb E**, Baltar S, Powers DW, Mohan K, Martinez A, Pitts E. The Diagnosis and Manifestations of Liver Injury Secondary to Off-Label Androgenic Anabolic Steroid Use. *Case Rep Gastroenterol* 2016; **10**: 499-505 [PMID: [27721739](#) DOI: [10.1159/000448883](#)]
- 69 **García-Cortés M**, Robles-Díaz M, Ortega-Alonso A, Medina-Caliz I, Andrade RJ. Hepatotoxicity by Dietary Supplements: A Tabular Listing and Clinical Characteristics. *Int J Mol Sci* 2016; **17**: 537 [PMID: [27070596](#) DOI: [10.3390/ijms17040537](#)]
- 70 **Pascale B**, Steele C, Attipoe S, O'Connor FG, Deuster PA. Dietary Supplements: Knowledge and Adverse Event Reporting Among American Medical Society for Sports Medicine Physicians. *Clin J Sport Med* 2016; **26**: 139-144 [PMID: [26035683](#) DOI: [10.1097/JSM.0000000000000213](#)]
- 71 **Medina-Caliz I**, García-Cortés M, González-Jiménez A, Cabello MR, Robles-Díaz M, Sanabria-Cabrera J, Sanjuan-Jiménez R, Ortega-Alonso A, García-Muñoz B, Moreno I, Jiménez-Pérez M, Fernández MC, Ginés P, Prieto M, Conde I, Hallal H, Soriano G, Roman E, Castiella A, Blanco-Reina E, Montes MR, Quiros-Cano M, Martín-Reyes F, Lucena MI, Andrade RJ; Spanish DILI Registry. Herbal and Dietary Supplement-Induced Liver Injuries in the Spanish DILI Registry. *Clin Gastroenterol Hepatol* 2018; **16**: 1495-1502 [PMID: [29307848](#) DOI: [10.1016/j.cgh.2017.12.051](#)]



Published by **Baishideng Publishing Group Inc**  
7041 Koll Center Parkway, Suite 160, Pleasanton, CA 94566, USA

**Telephone:** +1-925-3991568

**E-mail:** [bpgoffice@wjgnet.com](mailto:bpgoffice@wjgnet.com)

**Help Desk:** <https://www.f6publishing.com/helpdesk>

<https://www.wjgnet.com>

