

World Journal of *Clinical Cases*

World J Clin Cases 2022 June 16; 10(17): 5518-5933



MINIREVIEWS

- 5518** Occult hepatitis B — the result of the host immune response interaction with different genomic expressions of the virus
Gherlan GS
- 5531** Pulmonary complications of portal hypertension: The overlooked decompensation
Craciun R, Mocan T, Procopet B, Nemes A, Tefas C, Sparchez M, Mocan LP, Sparchez Z
- 5541** Ethical review of off-label drugs during the COVID-19 pandemic
Li QY, Lv Y, An ZY, Dai NN, Hong X, Zhang Y, Liang LJ

ORIGINAL ARTICLE

Case Control Study

- 5551** Gut peptide changes in patients with obstructive jaundice undergoing biliary drainage: A prospective case control study
Pavić T, Pelajić S, Blažević N, Kralj D, Milošević M, Mikolasevic I, Lerotic I, Hrabar D

Retrospective Cohort Study

- 5566** Longitudinal assessment of liver stiffness by transient elastography for chronic hepatitis C patients
Mezina A, Krishnan A, Woreta TA, Rubenstein KB, Watson E, Chen PH, Rodriguez-Watson C

Retrospective Study

- 5577** Clinical evaluation of prone position ventilation in the treatment of acute respiratory distress syndrome induced by sepsis
Xia WH, Yang CL, Chen Z, Ouyang CH, Ouyang GQ, Li QG
- 5586** Three-dimensional arterial spin labeling and diffusion kurtosis imaging in evaluating perfusion and infarct area size in acute cerebral ischemia
Jiang YY, Zhong ZL, Zuo M
- 5595** Intrathecal methotrexate in combination with systemic chemotherapy in glioblastoma patients with leptomeningeal dissemination: A retrospective analysis
Kang X, Chen F, Yang SB, Wang YL, Qian ZH, Li Y, Lin H, Li P, Peng YC, Wang XM, Li WB
- 5606** Hepatic epithelioid hemangioendothelioma: Clinical characteristics, diagnosis, treatment, and prognosis
Zhao M, Yin F
- 5620** Difference between type 2 gastroesophageal varices and isolated fundic varices in clinical profiles and portosystemic collaterals
Song YH, Xiang HY, Si KK, Wang ZH, Zhang Y, Liu C, Xu KS, Li X

- 5634** Assessment of incidental focal colorectal uptake by analysis of fluorine-18 fluorodeoxyglucose positron emission tomography parameters

Lee H, Hwang KH, Kwon KA

Observational Study

- 5646** "Zero ischemia" laparoscopic partial nephrectomy by high-power GreenLight laser enucleation for renal carcinoma: A single-center experience

Zhang XM, Xu JD, Lv JM, Pan XW, Cao JW, Chu J, Cui XG

- 5655** High Eckardt score and previous treatment were associated with poor postperoral endoscopic myotomy pain control: A retrospective study

Chen WN, Xu YL, Zhang XG

- 5667** Higher volume growth rate is associated with development of worrisome features in patients with branch duct-intraductal papillary mucinous neoplasms

Innocenti T, Danti G, Lynch EN, Dragoni G, Gottin M, Fedeli F, Palatresi D, Biagini MR, Milani S, Miele V, Galli A

Prospective Study

- 5680** Application of a new anatomic hook-rod-pedicle screw system in young patients with lumbar spondylolysis: A pilot study

Li DM, Li YC, Jiang W, Peng BG

META-ANALYSIS

- 5690** Systematic review of Yougui pills combined with levothyroxine sodium in the treatment of hypothyroidism

Liu XP, Zhou YN, Tan CE

CASE REPORT

- 5702** Allogeneic stem cell transplantation-A curative treatment for paroxysmal nocturnal hemoglobinuria with PIGT mutation: A case report

Schenone L, Notarantonio AB, Latger-Cannard V, Fremeaux-Bacchi V, De Carvalho-Bittencourt M, Rubio MT, Muller M, D'Aveni M

- 5708** Gray zone lymphoma effectively treated with cyclophosphamide, doxorubicin, vincristine, prednisolone, and rituximab chemotherapy: A case report

Hojo N, Nagasaki M, Mihara Y

- 5717** Diagnosis of spontaneous isolated superior mesenteric artery dissection with ultrasound: A case report

Zhang Y, Zhou JY, Liu J, Bai C

- 5723** Adrenocorticotrophic hormone-secreting pancreatic neuroendocrine carcinoma with multiple organ infections and widespread thrombosis: A case report

Yoshihara A, Nishihama K, Inoue C, Okano Y, Eguchi K, Tanaka S, Maki K, Fridman D'Alessandro V, Takeshita A, Yasuma T, Uemura M, Suzuki T, Gabazza EC, Yano Y

- 5732** Management of the palato-radicular groove with a periodontal regenerative procedure and prosthodontic treatment: A case report

Ling DH, Shi WP, Wang YH, Lai DP, Zhang YZ

- 5741** Combined thoracic paravertebral block and interscalene brachial plexus block for modified radical mastectomy: A case report
Hu ZT, Sun G, Wang ST, Li K
- 5748** Chondromyxoid fibroma of the cervical spine: A case report
Li C, Li S, Hu W
- 5756** Preterm neonate with a large congenital hemangioma on maxillofacial site causing thrombocytopenia and heart failure: A case report
Ren N, Jin CS, Zhao XQ, Gao WH, Gao YX, Wang Y, Zhang YF
- 5764** Simultaneous multiple primary malignancies diagnosed by endoscopic ultrasound-guided fine-needle aspiration: A case report
Yang J, Zeng Y, Zhang JW
- 5770** Neuroendocrine tumour of the descending part of the duodenum complicated with schwannoma: A case report
Zhang L, Zhang C, Feng SY, Ma PP, Zhang S, Wang QQ
- 5776** Massive hemothorax following internal jugular vein catheterization under ultrasound guidance: A case report
Kang H, Cho SY, Suk EH, Ju W, Choi JY
- 5783** Unilateral adrenal tuberculosis whose computed tomography imaging characteristics mimic a malignant tumor: A case report
Liu H, Tang TJ, An ZM, Yu YR
- 5789** Modified membrane fixation technique in a severe continuous horizontal bone defect: A case report
Wang LH, Ruan Y, Zhao WY, Chen JP, Yang F
- 5798** Surgical repair of an emergent giant hepatic aneurysm with an abdominal aortic dissection: A case report
Wen X, Yao ZY, Zhang Q, Wei W, Chen XY, Huang B
- 5805** Heterotopic ossification beneath the upper abdominal incision after radical gastrectomy: Two case reports
Zhang X, Xia PT, Ma YC, Dai Y, Wang YL
- 5810** Non-alcoholic Wernicke encephalopathy in an esophageal cancer patient receiving radiotherapy: A case report
Zhang Y, Wang L, Jiang J, Chen WY
- 5816** New approach for the treatment of vertical root fracture of teeth: A case report and review of literature
Zhong X, Yan P, Fan W
- 5825** Ultrasound-guided microwave ablation as a palliative treatment for mycosis fungoides eyelid involvement: A case report
Chen YW, Yang HZ, Zhao SS, Zhang Z, Chen ZM, Feng HH, An MH, Wang KK, Duan R, Chen BD
- 5833** Pulp revascularization on an adult mandibular right second premolar: A case report
Yang YQ, Wu BL, Zeng JK, Jiang C, Chen M

- 5841** Barrett's esophagus in a patient with bulimia nervosa: A case report
Gouda A, El-Kassas M
- 5846** Spontaneous gallbladder perforation and colon fistula in hypertriglyceridemia-related severe acute pancreatitis: A case report
Wang QP, Chen YJ, Sun MX, Dai JY, Cao J, Xu Q, Zhang GN, Zhang SY
- 5854** Beware of gastric tube in esophagectomy after gastric radiotherapy: A case report
Yurttas C, Wichmann D, Gani C, Bongers MN, Singer S, Thiel C, Koenigsrainer A, Thiel K
- 5861** Transition from minimal change disease to focal segmental glomerulosclerosis related to occupational exposure: A case report
Tang L, Cai Z, Wang SX, Zhao WJ
- 5869** Lung adenocarcinoma metastasis to paranasal sinus: A case report
Li WJ, Xue HX, You JQ, Chao CJ
- 5877** Follicular lymphoma presenting like marginal zone lymphoma: A case report
Peng HY, Xiu YJ, Chen WH, Gu QL, Du X
- 5884** Primary renal small cell carcinoma: A case report
Xie K, Li XY, Liao BJ, Wu SC, Chen WM
- 5893** Gitelman syndrome: A case report
Chen SY, Jie N
- 5899** High-frame-rate contrast-enhanced ultrasound findings of liver metastasis of duodenal gastrointestinal stromal tumor: A case report and literature review
Chen JH, Huang Y
- 5910** Tumor-like disorder of the brachial plexus region in a patient with hemophilia: A case report
Guo EQ, Yang XD, Lu HR
- 5916** Response to dacomitinib in advanced non-small-cell lung cancer harboring the rare delE709_T710insD mutation: A case report
Xu F, Xia ML, Pan HY, Pan JW, Shen YH
- 5923** Loss of human epidermal receptor-2 in human epidermal receptor-2+ breast cancer after neoadjuvant treatment: A case report
Yu J, Li NL

LETTER TO THE EDITOR

- 5929** Repetitive transcranial magnetic stimulation for post-traumatic stress disorder: Lights and shadows
Concerto C, Lanza G, Fisticaro F, Pennisi M, Rodolico A, Torrisi G, Bella R, Aguglia E

ABOUT COVER

Editorial Board Member of *World Journal of Clinical Cases*, Raden Andri Primadhi, MD, PhD, Assistant Professor, Surgeon, Department of Orthopaedics and Traumatology, Universitas Padjadjaran Medical School, Hasan Sadikin Hospital, Bandung 40161, Indonesia. randri@unpad.ac.id

AIMS AND SCOPE

The primary aim of *World Journal of Clinical Cases* (WJCC, *World J Clin Cases*) is to provide scholars and readers from various fields of clinical medicine with a platform to publish high-quality clinical research articles and communicate their research findings online.

WJCC mainly publishes articles reporting research results and findings obtained in the field of clinical medicine and covering a wide range of topics, including case control studies, retrospective cohort studies, retrospective studies, clinical trials studies, observational studies, prospective studies, randomized controlled trials, randomized clinical trials, systematic reviews, meta-analysis, and case reports.

INDEXING/ABSTRACTING

The WJCC is now indexed in Science Citation Index Expanded (also known as SciSearch®), Journal Citation Reports/Science Edition, Scopus, PubMed, and PubMed Central. The 2021 Edition of Journal Citation Reports® cites the 2020 impact factor (IF) for WJCC as 1.337; IF without journal self cites: 1.301; 5-year IF: 1.742; Journal Citation Indicator: 0.33; Ranking: 119 among 169 journals in medicine, general and internal; and Quartile category: Q3. The WJCC's CiteScore for 2020 is 0.8 and Scopus CiteScore rank 2020: General Medicine is 493/793.

RESPONSIBLE EDITORS FOR THIS ISSUE

Production Editor: Hua-Ge Yin, Production Department Director: Xiang Li, Editorial Office Director: Jin-Lai Wang.

NAME OF JOURNAL

World Journal of Clinical Cases

ISSN

ISSN 2307-8960 (online)

LAUNCH DATE

April 16, 2013

FREQUENCY

Thrice Monthly

EDITORS-IN-CHIEF

Bao-Gan Peng, Jerzy Tadeusz Chudek, George Kontogeorgos, Maurizio Serati, Ja Hyeon Ku

EDITORIAL BOARD MEMBERS

<https://www.wjgnet.com/2307-8960/editorialboard.htm>

PUBLICATION DATE

June 16, 2022

COPYRIGHT

© 2022 Baishideng Publishing Group Inc

INSTRUCTIONS TO AUTHORS

<https://www.wjgnet.com/bpg/gerinfo/204>

GUIDELINES FOR ETHICS DOCUMENTS

<https://www.wjgnet.com/bpg/GerInfo/287>

GUIDELINES FOR NON-NATIVE SPEAKERS OF ENGLISH

<https://www.wjgnet.com/bpg/gerinfo/240>

PUBLICATION ETHICS

<https://www.wjgnet.com/bpg/GerInfo/288>

PUBLICATION MISCONDUCT

<https://www.wjgnet.com/bpg/gerinfo/208>

ARTICLE PROCESSING CHARGE

<https://www.wjgnet.com/bpg/gerinfo/242>

STEPS FOR SUBMITTING MANUSCRIPTS

<https://www.wjgnet.com/bpg/GerInfo/239>

ONLINE SUBMISSION

<https://www.f6publishing.com>



Loss of human epidermal receptor-2 in human epidermal receptor-2+ breast cancer after neoadjuvant treatment: A case report

Jing Yu, Nan-Lin Li

Specialty type: Medicine, research and experimental

Provenance and peer review: Unsolicited article; Externally peer reviewed.

Peer-review model: Single blind

Peer-review report's scientific quality classification

Grade A (Excellent): 0
Grade B (Very good): B, B
Grade C (Good): 0
Grade D (Fair): 0
Grade E (Poor): 0

P-Reviewer: Chia CL, Singapore; Sheikh Hassan M, Somalia

Received: January 25, 2022

Peer-review started: January 25, 2022

First decision: March 16, 2022

Revised: March 18, 2022

Accepted: April 4, 2022

Article in press: April 4, 2022

Published online: June 16, 2022



Jing Yu, Nan-Lin Li, Department of Thyroid, Breast and Vascular Surgery, Xijing Hospital, Air Force Medical University, Xi'an 710032, Shaanxi Province, China

Corresponding author: Nan-Lin Li, MD, Associate Chief Physician, Department of Thyroid, Breast and Vascular Surgery, Xijing Hospital, Air Force Medical University, No. 127 West Changle Road, Xi'an 710032, Shaanxi Province, China. yuyujing0729@163.com

Abstract

BACKGROUND

Human epidermal receptor-2 (HER-2) expression has been reported to be discordant between primary tumor and metastatic tissue.

CASE SUMMARY

We presented a case diagnosed with the HER-2+ breast cancer patient who exhibited changes in the expression of HER-2 receptors on tumour samples from surgical specimens obtained after neoadjuvant treatment (NAT) compared with initial biopsy. The patient underwent a HER-2-targeted therapy consequently, in spite of HER+ gene loss. After the surgery, the patient subsequently underwent endocrine therapy and radiotherapy.

CONCLUSION

Changes in HER-2 expression after NAT should be retested by physicians and pathologists before systemic treatment instead of avoiding further HER-2-targeted therapy, and we will perform immunohistochemical multiple-spot biopsy analyses of other important clinical issues to better define prognosis and tailor subsequent adjuvant therapy.

Key Words: Human epidermal receptor-2+ breast cancer; Human epidermal receptor-2 loss; Neoadjuvant treatment; Case report

©The Author(s) 2022. Published by Baishideng Publishing Group Inc. All rights reserved.

Core Tip: We presented a case diagnosed with the human epidermal receptor(HER)-2+ breast cancer patient who exhibited changes in the expression of HER-2 receptors on tumour samples from surgical specimens obtained after neoadjuvant treatment (NAT) compared with initial biopsy. Changes in HER-2 expression after NAT should be retested by physicians and pathologists before systemic treatment instead of avoiding further HER-2-targeted therapy. In general, the exact mechanisms of HER-2 discordance remain unknown and further investigations are needed.

Citation: Yu J, Li NL. Loss of human epidermal receptor-2 in human epidermal receptor-2+ breast cancer after neoadjuvant treatment: A case report. *World J Clin Cases* 2022; 10(17): 5923-5928

URL: <https://www.wjgnet.com/2307-8960/full/v10/i17/5923.htm>

DOI: <https://dx.doi.org/10.12998/wjcc.v10.i17.5923>

INTRODUCTION

The Human epidermal receptor-2 (HER-2) gene is over-expressed in approximately 15%-20% of primary breast cancers, and HER-2-targeted therapies are associated with significantly improved survival. Neoadjuvant treatment (NAT) is the standard of care for HER-2-positive early breast cancer, especially for positive pathologic axillary lymph nodes. However, HER-2 expression has been reported to be discordant between the primary tumour and the remaining tumour after NAT and is associated with poor prognosis and treatment. Data regarding HER-2 Loss suggest that 2.3%-43% of post-treatment tumours lose HER-2 positivity, which is associated with worse survival[1-3]. Herein, by reviewing the relevant literature, we present a case of HER-2 Loss with HER-2+ breast cancer undergoing NAT, to determine the prognostic impact of HER-2 Loss and improve disease management.

CASE PRESENTATION

Chief complaints

She complained of a mass in her left breast for several months.

History of present illness

A 55-year-old postmenopausal female patient presented to the Xi Jing Hospital of Air Force Medical University in September 2019. She complained of a mass in her left breast for several months.

History of past illness

The patient was healthy with no previous comorbidity.

Personal and family history

Her family history of cancer was negative.

Physical examination

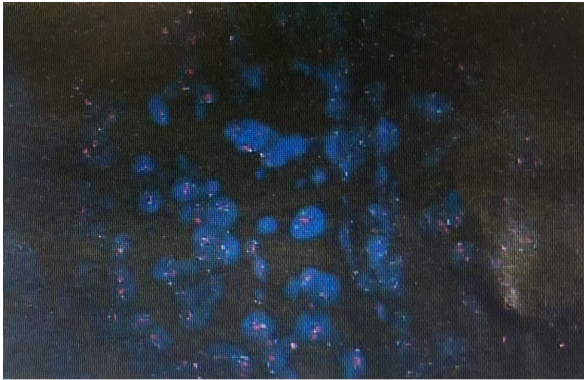
She found two irregular nodules in the upper external quadrant of the left breast.

Laboratory examinations

All tumour markers, including serum carcinoembryonic antigen, neuron-specific enolase, and alpha fetoprotein, were within normal ranges. Histopathology revealed invasive breast carcinoma and infiltrating ductal carcinoma in the axillary lymph nodes. Immunohistochemical (IHC) staining was positive for ER, progesterone receptor, Ki-67 30% and suspicious positive for HER-2. Because of the suspicious positivity for HER-2, the fluorescence in situ hybridization (FISH) method was strongly recommended. FISH testing was positive, as shown in [Figure 1](#). Breast cancer and metastatic lymph nodes were identical in FISH expression. The physical and imaging examinations showed no primary lesions in either breast or in other organs.

Imaging examinations

Ultrasonographic examination showed two irregular nodules in the upper external quadrant of the left breast. The largest mass was 2.6 cm × 0.9 cm × 1.1 cm in diameter, with invasion of deeper structures. Doppler ultrasound showed a fixed, 2 cm lymph nodule.



DOI: 10.12998/wjcc.v10.i17.5923 Copyright ©The Author(s) 2022.

Figure 1 The fluorescence in situ hybridization results before neoadjuvant treatment.

FINAL DIAGNOSIS

The patient was diagnosed with the HER-2+ early breast cancer.

TREATMENT

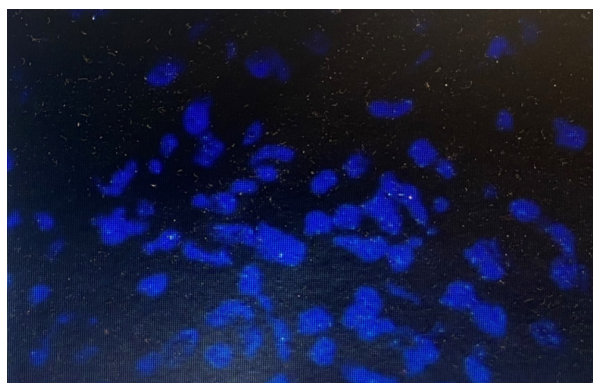
The multidisciplinary board of the Breast Centre recommended “neoadjuvant” chemotherapy: T(HP)-EC scheme: 4 cycles of docetaxel 90 mg/m², trastuzumab, and pertuzumab, followed by 4 cycles of epirubicin 90 mg/m² and cyclophosphamide 600 mg/m², every 3 wk for 8 cycles) before total mastectomy and axillary lymph node dissection. Histopathologic analysis of these specimens showed residual ductal carcinoma disease. Histopathology revealed grade 3 invasive breast carcinoma, (RCB-II, 6 scores). Microscopically, the residual invasive breast cancer was approximately 7 mm, and 5 out of 20 dissected axillary lymph nodes showed metastasis. With all of this, the tumour was classified as ypT1bN2aM0. Immunohistochemistry was performed, and the results were as follows: 90% positivity for estrogen receptors with high intensity, 90% positivity for progesterone receptors with high intensity, and suspicious positivity for HER-2 (++). FISH testing was negative, as shown in [Figure 2](#). We retrospectively reevaluated these results from the central laboratory FISH screening. On May 8, 2020, the patient received T-DM1 at a dose of 3.6 mg per kilogram of body weight intravenously every 3 wk for 14 cycles. Simultaneously, adjuvant radiotherapy was also recommended because of her axillary lymph node features on excisional biopsy. At the follow-up, 1 year after diagnosis and treatment initiation, the patient had no sign of local or distant recurrence. Considering the hormone sensitivity of the tumour, the guidelines decided for endocrine adjuvant therapy were as follows: (abemaciclib 150 mg twice daily + anastrozole 1mg once daily).

OUTCOME AND FOLLOW-UP

At the time of drafting the present report (January 2022), routine follow-up of the patient continued, showing no complications.

DISCUSSION

The current standard presurgical systemic treatment in HER-2-positive breast cancer patients is NAT, especially for positive pathologic axillary lymph nodes. The addition of anti-HER-2 treatment to neoadjuvant chemotherapy significantly improves the pathological complete response (pCR) rate, which is a surrogate for disease-free survival (DFS), overall survival and distant recurrence-free survival (DRFS)[4]. Mittendorf *et al*[5] found that according to FISH analysis, approximately one-third of their patients with sufficient residual disease to warrant repeat HER-2 testing had lost HER-2 gene amplification. Furthermore, patients who lose HER-2 gene amplification have significantly lower relapse-free survival than those whose tumours retain HER-2 gene amplification[6]. Notably, we found that this case exhibited changes in the expression of HER-2 receptors on tumour samples from surgical specimens obtained after NAT compared with initial biopsy. This is in agreement with early studies in which the rate of HER-2 gain and loss was observed to be 6.5% and 14.2%, respectively, and loss of HER-2 expression was more commonly observed than gain of HER-2 expression[3,7].



DOI: 10.12998/wjcc.v10.i17.5923 Copyright ©The Author(s) 2022.

Figure 2 The fluorescence in situ hybridization results after neoadjuvant treatment.

In the neoadjuvant setting, the addition of trastuzumab and, more recently, pertuzumab to chemotherapy significantly improves the pCR rate compared to chemotherapy alone[8]. The KATHERINE study showed that among patients with HER-2-positive early breast cancer who had residual invasive disease after completion of neoadjuvant therapy, the risk of recurrence of invasive breast cancer or death was 50% lower with adjuvant trastuzumab emtansine (T-DM1) than with trastuzumab alone. Further subgroup analyses showed that 8.3% of posttreatment tumours lost HER-2 positivity after NAT ($n = 70$); invasive-disease events occurred in 11 patients in the adjuvant trastuzumab group; and no events occurred in the T-DM1 group, reminding us that adjuvant T-DM1 remains beneficial in tumour loss in the HER-2 population[9]. This case was HR+, HER-2+ breast cancer. The ExteNET trial demonstrated that neratinib given for 1 year following trastuzumab-based therapy significantly improved invasive DFS (iDFS) in patients with HER-2+ breast cancer, with the greatest efficacy seen in patients who initiated treatment within 1 year of prior trastuzumab therapy and in those with HR+ disease[10]. Meanwhile, the most recently results showed that neratinib achieved an 11.9% iDFS benefit for the HR+ subgroup within 1 year of prior trastuzumab therapy in the 5-year analysis. In comparison with the previously reported KATHERINE trial, the iDFS benefit was 11.3% at the 3-year analysis in patients with T-DM1. However, patients in the KATHERINE trial had a substantially worse baseline prognosis than those enrolled in the ExteNET trial. The KATHERINE trial focused on higher-risk patients with residual invasive breast cancer after completion of neoadjuvant chemotherapy administered with trastuzumab-containing therapy. We considered that the patient could benefit from T-DM1 rather than neratinib, owing to adverse events, group characteristics and accessibility. Subsequently, the MonarchE study showed that there was a 25% reduction in the risk of developing an iDFS event in the abemaciclib plus endocrine therapy (ET) group relative to ET alone, as well as a 3.5% absolute improvement in 2-year IDFS rates (92.2% *vs* 88.7%). The addition of abemaciclib to ET also resulted in an improvement in DRFS (distant relapse-free survival) compared with ET alone, with 2-year DRFS rates of 93.6% in the abemaciclib arm and 90.3% in the control arm[11,12].

In general, the exact mechanisms of HER-2 discordance remain unknown and further investigations are needed. The interval between the last HER-2-targeted treatment, the time of surgical excision of the tumour after NAT, and biopsy of the metachronous metastasis or intratumoural heterogeneity of the HER-2 gene were associated with a significant change in HER-2 expression. Nevertheless, FISH testing is associated with less discordance than the IHC method[1,13]. Despite observations revealing HER-2 Loss between initial biopsy and surgical specimens, management of patients with HER-2+ breast cancer is frequently based on primary tumor characteristics. Furthermore, Several studies suggested that all subgroups of women seem to benefit from trastuzumab in exploratory subgroup analysis, regardless of changes in HER status[13-16]. In our opinion, changes in HER-2 expression after NAT should be retested by physicians and pathologists before systemic treatment instead of avoiding further HER-2-targeted therapy. Furthermore, if the HER-2 status changes between the primary tumour and the remaining tumour undergoing NAT, the actual guidelines recommend the use of HER-2 status in metastatic tissue, and the FISH method is strongly recommended. In this way, changes in HER-2 expression influenced by HER-2 internalization and degradation may be avoided. Finally, we will perform IHC multiple-spot biopsy analyses of other important clinical issues to better define prognosis and tailor subsequent adjuvant therapy.

CONCLUSION

In conclusion, our study presented a case of HER+ gene loss in a patient with the HER-2+ breast cancer after NAT and we went on to do a literature review of this phenomenon which has been shown in about

10% of patient in case series. Although HER-2 Loss after NAT is considered extremely rare, repeating HER-2 test or IHC multiple-spot biopsy analyses is required for accurate prognosis and therapy.

FOOTNOTES

Author contributions: Yu J analyzed the data and wrote the manuscript; Li NL and Yu J performed the research; all authors have read and approve the final manuscript.

Informed consent statement: Informed written consent was obtained from the patient for publication of this report and any accompanying images.

Conflict-of-interest statement: The authors declare that they have no conflict of interest.

CARE Checklist (2016) statement: The authors have read the CARE Checklist (2016), and the manuscript was prepared and revised according to the CARE Checklist (2016).

Open-Access: This article is an open-access article that was selected by an in-house editor and fully peer-reviewed by external reviewers. It is distributed in accordance with the Creative Commons Attribution NonCommercial (CC BY-NC 4.0) license, which permits others to distribute, remix, adapt, build upon this work non-commercially, and license their derivative works on different terms, provided the original work is properly cited and the use is non-commercial. See: <https://creativecommons.org/licenses/by-nc/4.0/>

Country/Territory of origin: China

ORCID number: Jing Yu 0000-0001-9733-9286; Nanlin Li 0000-0002-7212-1026.

S-Editor: Wang LL

L-Editor: A

P-Editor: Wang LL

REFERENCES

- 1 Ignatov T, Gorbunov F, Eggemann H, Ortmann O, Ignatov A. Loss of HER2 after HER2-targeted treatment. *Breast Cancer Res Treat* 2019; **175**: 401-408 [PMID: 30806922 DOI: 10.1007/s10549-019-05173-4]
- 2 Branco FP, Machado D, Silva FF, André S, Catarino A, Madureira R, Pinto JM, Godinho JP, Simões PD, Brito M, Casa-Nova M, Moreira AR, Passos-Coelho JL. Loss of HER2 and disease prognosis after neoadjuvant treatment of HER2+ breast cancer. *Am J Transl Res* 2019; **11**: 6110-6116 [PMID: 31632579 DOI: 10.1016/s0959-8049(18)30510-0]
- 3 Niikura N, Tomotaki A, Miyata H, Iwamoto T, Kawai M, Anan K, Hayashi N, Aogi K, Ishida T, Masuoka H, Iijima K, Masuda S, Tsugawa K, Kinoshita T, Nakamura S, Tokuda Y. Changes in tumor expression of HER2 and hormone receptors status after neoadjuvant chemotherapy in 21,755 patients from the Japanese breast cancer registry. *Ann Oncol* 2016; **27**: 480-487 [PMID: 26704052 DOI: 10.1093/annonc/mdv611]
- 4 Press MF, Sauter G, Buyse M, Fourmanoir H, Quinaux E, Tsao-Wei DD, Eiermann W, Robert N, Pienkowski T, Crown J, Martin M, Valero V, Mackey JR, Bee V, Ma Y, Villalobos I, Campeau A, Mirlacher M, Lindsay MA, Slamon DJ. HER2 Gene Amplification Testing by Fluorescent In Situ Hybridization (FISH): Comparison of the ASCO-College of American Pathologists Guidelines With FISH Scores Used for Enrollment in Breast Cancer International Research Group Clinical Trials. *J Clin Oncol* 2016; **34**: 3518-3528 [PMID: 27573653 DOI: 10.1200/jco.2016.66.6693]
- 5 Mittendorf EA, Wu Y, Scaltriti M, Meric-Bernstam F, Hunt KK, Dawood S, Esteva FJ, Buzdar AU, Chen H, Eksambi S, Hortobagyi GN, Baselga J, Gonzalez-Angulo AM. Loss of HER2 amplification following trastuzumab-based neoadjuvant systemic therapy and survival outcomes. *Clin Cancer Res* 2009; **15**: 7381-7388 [PMID: 19920100 DOI: 10.1158/1078-0432.ccr-09-1735]
- 6 Niikura N, Liu J, Hayashi N, Mittendorf EA, Gong Y, Palla SL, Tokuda Y, Gonzalez-Angulo AM, Hortobagyi GN, Ueno NT. Loss of human epidermal growth factor receptor 2 (HER2) expression in metastatic sites of HER2-overexpressing primary breast tumors. *J Clin Oncol* 2012; **30**: 593-599 [PMID: 22124109 DOI: 10.1200/jco.2010.33.8889]
- 7 Yeung C, Hilton J, Clemons M, Mazzarello S, Hutton B, Haggart F, Addison CL, Kuchuk I, Zhu X, Gelmon K, Arnaout A. Estrogen, progesterone, and HER2/neu receptor discordance between primary and metastatic breast tumours-a review. *Cancer Metastasis Rev* 2016; **35**: 427-437 [PMID: 27405651 DOI: 10.1007/s10555-016-9631-3]
- 8 Gianni L, Pienkowski T, Im YH, Tseng LM, Liu MC, Lluch A, Starosławska E, de la Haba-Rodriguez J, Im SA, Pedrini JL, Poirier B, Morandi P, Semiglazov V, Srimuninnimit V, Bianchi GV, Magazzù D, McNally V, Douthwaite H, Ross G, Valagussa P. 5-year analysis of neoadjuvant pertuzumab and trastuzumab in patients with locally advanced, inflammatory, or early-stage HER2-positive breast cancer (NeoSphere): a multicentre, open-label, phase 2 randomised trial. *Lancet Oncol* 2016; **17**: 791-800 [PMID: 27179402 DOI: 10.1016/s1470-2045(16)00163-7]
- 9 Haran JP, Wilsterman E, Zeoli T, Goulding M, McLendon E, Clark MA. Deviating from IDSA treatment guidelines for non-purulent skin infections increases the risk of treatment failure in emergency department patients. *Epidemiol Infect* 2018; **147**: e68 [PMID: 30516120 DOI: 10.1056/nejmoa1814017]
- 10 Chan A, Moy B, Mansi J, Ejlersen B, Holmes FA, Chia S, Iwata H, Gnani M, Loibl S, Barrios CH, Somali I, Smichkoska

- S, Martinez N, Alonso MG, Link JS, Mayer IA, Cold S, Murillo SM, Senecal F, Inoue K, Ruiz-Borrego M, Hui R, Denduluri N, Patt D, Rugo HS, Johnston SRD, Bryce R, Zhang B, Xu F, Wong A, Martin M; ExteNET Study Group. Final Efficacy Results of Neratinib in HER2-positive Hormone Receptor-positive Early-stage Breast Cancer From the Phase III ExteNET Trial. *Clin Breast Cancer* 2021; **21**: 80-91.e7 [PMID: [33183970](#) DOI: [10.1016/s0960-9776\(21\)00093-x](#)]
- 11 **Harbeck N**, Rastogi P, Martin M, Tolane SM, Shao ZM, Fasching PA, Huang CS, Jaliffe GG, Tryakin A, Goetz MP, Rugo HS, Senkus E, Testa L, Andersson M, Tamura K, Del Mastro L, Steger GG, Kreipe H, Hegg R, Sohn J, Guarneri V, Cortés J, Hamilton E, André V, Wei R, Barriga S, Sherwood S, Forrester T, Munoz M, Shahir A, San Antonio B, Nabinger SC, Toi M, Johnston SRD, O'Shaughnessy J; monarchE Committee Members. Adjuvant abemaciclib combined with endocrine therapy for high-risk early breast cancer: updated efficacy and Ki-67 analysis from the monarchE study. *Ann Oncol* 2021; **32**: 1571-1581 [PMID: [34656740](#) DOI: [10.1200/jco.20.02514](#)]
- 12 **Burstein HJ**, Somerfield MR, Barton DL, Dorris A, Fallowfield LJ, Jain D, Johnston SRD, Korde LA, Litton JK, Macrae ER, Peterson LL, Vikas P, Yung RL, Rugo HS. Endocrine Treatment and Targeted Therapy for Hormone Receptor-Positive, Human Epidermal Growth Factor Receptor 2-Negative Metastatic Breast Cancer: ASCO Guideline Update. *J Clin Oncol* 2021; **39**: 3959-3977 [PMID: [34324367](#) DOI: [10.1200/JCO.21.01392](#)]
- 13 **Yoshida A**, Hayashi N, Suzuki K, Takimoto M, Nakamura S, Yamauchi H. Change in HER2 status after neoadjuvant chemotherapy and the prognostic impact in patients with primary breast cancer. *J Surg Oncol* 2017; **116**: 1021-1028 [PMID: [28767137](#) DOI: [10.1002/jso.24762](#)]
- 14 **Lindström LS**, Karlsson E, Wilking UM, Johansson U, Hartman J, Lidbrink EK, Hatschek T, Skoog L, Bergh J. Clinically used breast cancer markers such as estrogen receptor, progesterone receptor, and human epidermal growth factor receptor 2 are unstable throughout tumor progression. *J Clin Oncol* 2012; **30**: 2601-2608 [PMID: [22711854](#) DOI: [10.1200/jco.2011.37.2482](#)]
- 15 **Smith I**, Procter M, Gelber RD, Guillaume S, Feyereislova A, Dowsett M, Goldhirsch A, Untch M, Mariani G, Baselga J, Kaufmann M, Cameron D, Bell R, Bergh J, Coleman R, Wardley A, Harbeck N, Lopez RI, Mallmann P, Gelmon K, Wilcken N, Wist E, Sánchez Rovira P, Piccart-Gebhart MJ; HERA study team. 2-year follow-up of trastuzumab after adjuvant chemotherapy in HER2-positive breast cancer: a randomised controlled trial. *Lancet* 2007; **369**: 29-36 [PMID: [17208639](#) DOI: [10.1016/s0140-6736\(07\)60028-2](#)]
- 16 **Gianni L**, Eiermann W, Semiglazov V, Manikhas A, Lluch A, Tjulandin S, Zambetti M, Vazquez F, Byakhov M, Lichinitser M, Climent MA, Ciruelos E, Ojeda B, Mansutti M, Bozhok A, Baronio R, Feyereislova A, Barton C, Valagussa P, Baselga J. Neoadjuvant chemotherapy with trastuzumab followed by adjuvant trastuzumab versus neoadjuvant chemotherapy alone, in patients with HER2-positive locally advanced breast cancer (the NOAH trial): a randomised controlled superiority trial with a parallel HER2-negative cohort. *Lancet* 2010; **375**: 377-384 [PMID: [20113825](#) DOI: [10.1016/s0140-6736\(09\)61964-4](#)]



Published by **Baishideng Publishing Group Inc**
7041 Koll Center Parkway, Suite 160, Pleasanton, CA 94566, USA

Telephone: +1-925-3991568

E-mail: bpgoffice@wjgnet.com

Help Desk: <https://www.f6publishing.com/helpdesk>

<https://www.wjgnet.com>

