

World Journal of *Clinical Cases*

World J Clin Cases 2022 July 26; 10(21): 7187-7619



Contents

Thrice Monthly Volume 10 Number 21 July 26, 2022

OPINION REVIEW

- 7187 Effects of glucocorticoids on leukocytes: Genomic and non-genomic mechanisms
Jia WY, Zhang JJ

MINIREVIEWS

- 7195 Apheresis: A cell-based therapeutic tool for the inflammatory bowel disease
Yasmin F, Najeeb H, Naeem U, Moeed A, Koritala T, Surani S
- 7209 *Helicobacter pylori* infection and small intestinal bacterial overgrowth—more than what meets the eye
Dharan M, Wozny D
- 7215 Anatomy of the anterolateral ligament of the knee joint
Park JG, Han SB, Rhim HC, Jeon OH, Jang KM

ORIGINAL ARTICLE

Clinical and Translational Research

- 7224 Molecular mechanisms of Biyu decoction as treatment for psoriasis: A network pharmacology and molecular docking study
Wang Z, Zhang HM, Guo YR, Li LL
- 7242 Expression of hepatocyte nuclear factor 4 alpha, wingless-related integration site, and β -catenin in clinical gastric cancer
Hu Q, Li LL, Peng Z, Yi P

Case Control Study

- 7256 Improved Pittsburgh Sleep Quality Index scores on first postoperative night achieved by propofol anesthesia in patients undergoing ambulatory gynecologic surgery
Hu CH, Chou WY
- 7265 Efficacy of Guhong injection *versus* Butylphthalide injection for mild ischemic stroke: A multicenter controlled study
Zhang WW, Xin J, Zhang GY, Zhai QJ, Zhang HM, Wu CS

Retrospective Study

- 7275 Clinical values of Barcelona Clinic Liver Cancer subgroup and up-to-7 criteria in intermediate stage hepatocellular carcinoma with transcatheter arterial chemoembolization
Lee SW, Peng YC, Lien HC, Ko CW, Tung CF, Chang CS
- 7285 Intervention effect of encouraging mental and programmed nursing of patients in interventional operating room on their compliance and bad moods
Chi RB, Cai YY, Mao HP

- 7293** Preoperative neoadjuvant chemotherapy in patients with breast cancer evaluated using strain ultrasonic elastography
Pan HY, Zhang Q, Wu WJ, Li X
- 7302** Risk factors for delayed intracranial hemorrhage secondary to ventriculoperitoneal shunt: A retrospective study
Chen JC, Duan SX, Xue ZB, Yang SY, Li Y, Lai RL, Tan DH
- 7314** Sequential treatment of severe pneumonia with respiratory failure and its influence on respiratory mechanical parameters and hemodynamics
Niu BY, Wang G, Li B, Zhen GS, Weng YB
- 7324** Effects of alendronate sodium combined with InterTan on osteoporotic femoral intertrochanteric fractures and fracture recurrence
Wang KM, Wei SP, Yin XY, Meng QJ, Kong YM
- 7333** Correlation of magnetic resonance imaging quantitative parameters and apparent diffusion coefficient value with pathological breast cancer
Wang Z, Ren GY, Yin Q, Wang Q
- 7341** Risk factors for delirium after surgery for craniocerebral injury in the neurosurgical intensive care unit
Chen RY, Zhong CH, Chen W, Lin M, Feng CF, Chen CN

Observational Study

- 7348** Effect of osteoarthritic knee flexion deformity correction by total knee arthroplasty on sagittal spinopelvic alignment in Indian population
Puthiyapura LK, Jain M, Tripathy SK, Puliappadamb HM
- 7356** Imaging characteristics of orbital peripheral nerve sheath tumors: Analysis of 34 cases
Dai M, Wang T, Wang JM, Fang LP, Zhao Y, Thakur A, Wang D

Randomized Controlled Trial

- 7365** Comparison of involved-field intensity-modulated radiotherapy combined with S-1 *vs* radiotherapy alone for elderly patients with esophageal cancer
Liu LH, Yan MH, Di YP, Fu ZG, Zhang XD, Li HQ

Randomized Clinical Trial

- 7376** Dexmedetomidine in pediatric unilateral internal inguinal ring ligation
Liu G, Zhang L, Wang HS, Lin Y, Jin HQ, Wang XD, Qiao WN, Zhang YT, Sun JQ, Liu ZN

META-ANALYSIS

- 7386** Impact of cancer on mortality rates in patients with sepsis: A meta-analysis and meta-regression of current studies
Xiang MJ, Chen GL

CASE REPORT

- 7397** Updated clinical and glycomic features of mannosyl-oligosaccharide glucosidase deficiency: Two case reports
Abuduxikuer K, Wang L, Zou L, Cao CY, Yu L, Guo HM, Liang XM, Wang JS, Chen L
- 7409** Solitary necrotic nodules of the liver with "ring"-like calcification: A case report
Bao JP, Tian H, Wang HC, Wang CC, Li B
- 7415** Corticosteroid-induced bradycardia in multiple sclerosis and maturity-onset diabetes of the young due to hepatocyte nuclear factor 4-alpha mutation: A case report
Sohn SY, Kim SY, Joo IS
- 7422** Essential thrombocythemia with non-ST-segment elevation myocardial infarction as the first manifestation: A case report
Wang ZM, Chen WH, Wu YM, Wang LQ, Ye FL, Yin RL
- 7429** Extranasopharyngeal angiofibroma in children: A case report
Yan YY, Lai C, Wu L, Fu Y
- 7438** Deep Sylvian fissure meningiomas: A case report
Wang A, Zhang X, Sun KK, Li C, Song ZM, Sun T, Wang F
- 7445** Acute pulmonary embolism originating from upper limb venous thrombosis following breast cancer surgery: Two case reports
Duan Y, Wang GL, Guo X, Yang LL, Tian FG
- 7451** Managing spondylitis tuberculosis in a patient with underlying diabetes and hypothyroidism: A case report
Novita BD, Muliono AC, Wijaya S, Theodora I, Tjahjono Y, Supit VD, Willianto VM
- 7459** Ovarian mucinous tumor with mural nodules of anaplastic carcinoma: Three case reports
Wang XJ, Wang CY, Xi YF, Bu P, Wang P
- 7467** Transcatheter arterial infusion chemotherapy and embolization for primary lacrimal sac squamous cell carcinoma: A case report
Sun MH, Yi WD, Shen L, Zhou L, Lu JX
- 7474** Programmed cell death-1 inhibitor combination treatment for recurrent proficient mismatch repair/microsatellite-stable type endometrial cancer: A case report
Zhai CY, Yin LX, Han WD
- 7483** Novel compound heterozygous mutation of *SLC12A3* in Gitelman syndrome co-existent with hyperthyroidism: A case report and literature review
Qin YZ, Liu YM, Wang Y, You C, Li LN, Zhou XY, Lv WM, Hong SH, Xiao LX
- 7495** Successful treatment of hyperglycemia with liraglutide in a hospitalized 27-year-old patient with schizophrenia: A case report
Zhang L, Yu WJ, Zhu H, Li HF, Qiao J

- 7502** Refractory lymphoma treated with chimeric antigen receptor T cells combined with programmed cell death-1 inhibitor: A case report
Zhang CJ, Zhang JY, Li LJ, Xu NW
- 7509** Median arcuate ligament syndrome with retroperitoneal haemorrhage: A case report
Lu XC, Pei JG, Xie GH, Li YY, Han HM
- 7517** Novel frameshift mutation in the *AHDC1* gene in a Chinese global developmental delay patient: A case report
Lin SZ, Xie HY, Qu YL, Gao W, Wang WQ, Li JY, Feng XC, Jin CQ
- 7523** Selective nerve block for the treatment of neuralgia in Kummell's disease: A case report
Zhang X, Li ZX, Yin LJ, Chen H
- 7531** Traditional Chinese medicine manipulative reduction combined with percutaneous vertebroplasty for treating type III Kummell's disease: A case report
Hao SS, Zhang RJ, Dong SL, Li HK, Liu S, Li RF, Ren HH, Zhang LY
- 7539** Differential diagnosis and treatment of foot drop caused by an extraneural ganglion cyst above the knee: A case report
Won KH, Kang EY
- 7545** Effect of hydrogen intervention on refractory wounds after radiotherapy: A case report
Zhao PX, Luo RL, Dang Z, Wang YB, Zhang XJ, Liu ZY, Wen XH, Liu MY, Zhang MZ, Adzavon YM, Ma XM
- 7553** Chronic urticaria associated with lung adenocarcinoma — a paraneoplastic manifestation: A case report and literature review
Jiménez LF, Castellón EA, Marengo JD, Mejía JM, Rojas CA, Jiménez FT, Coronell L, Osorio-Llanes E, Mendoza-Torres E
- 7565** Spinal giant cell-rich osteosarcoma-diagnostic dilemma and treatment strategy: A case report
Tseng CS, Wong CE, Huang CC, Hsu HH, Lee JS, Lee PH
- 7571** Primary clear cell sarcoma of soft tissue in the posterior cervical spine invading the medulla oblongata: A case report
Liu CC, Huang WP, Gao JB
- 7577** *Pseudomonas aeruginosa*-related effusive-constrictive pericarditis diagnosed with echocardiography: A case report
Chen JL, Mei DE, Yu CG, Zhao ZY
- 7585** Maternal peripartum bacteremia caused by intrauterine infection with *Comamonas kerstersii*: A case report
Qu H, Zhao YH, Zhu WM, Liu L, Zhu M
- 7592** Considerations of single-lung ventilation in neonatal thoracoscopic surgery with cardiac arrest caused by bilateral pneumothorax: A case report
Zhang X, Song HC, Wang KL, Ren YY

- 7599** Rare primary rectal mucosa-associated lymphoid tissue lymphoma with curative resection by endoscopic submucosal dissection: A case report and review of literature

Tao Y, Nan Q, Lei Z, Miao YL, Niu JK

- 7609** Differences in examination results of small anastomotic fistula after radical gastrectomy with afterward treatments: A case report

Lu CY, Liu YL, Liu KJ, Xu S, Yao HL, Li L, Guo ZS

LETTER TO THE EDITOR

- 7617** Baseline differences may impact on relationship between dietary tryptophan and risk of obesity and type 2 diabetes

Ren XH, Ye YW, He LP

ABOUT COVER

Editorial Board Member of *World Journal of Clinical Cases*, Rajesh Kumar Rajnish, MBBS, MS, Assistant Professor, Department of Orthopaedics, All India Institute of Medical Sciences, Bilaspur, Bilaspur 174001, Himachal Pradesh, India. duktiraj@gmail.com

AIMS AND SCOPE

The primary aim of *World Journal of Clinical Cases* (WJCC, *World J Clin Cases*) is to provide scholars and readers from various fields of clinical medicine with a platform to publish high-quality clinical research articles and communicate their research findings online.

WJCC mainly publishes articles reporting research results and findings obtained in the field of clinical medicine and covering a wide range of topics, including case control studies, retrospective cohort studies, retrospective studies, clinical trials studies, observational studies, prospective studies, randomized controlled trials, randomized clinical trials, systematic reviews, meta-analysis, and case reports.

INDEXING/ABSTRACTING

The WJCC is now abstracted and indexed in Science Citation Index Expanded (SCIE, also known as SciSearch®), Journal Citation Reports/Science Edition, Current Contents®/Clinical Medicine, PubMed, PubMed Central, Scopus, Reference Citation Analysis, China National Knowledge Infrastructure, China Science and Technology Journal Database, and Superstar Journals Database. The 2022 Edition of Journal Citation Reports® cites the 2021 impact factor (IF) for WJCC as 1.534; IF without journal self cites: 1.491; 5-year IF: 1.599; Journal Citation Indicator: 0.28; Ranking: 135 among 172 journals in medicine, general and internal; and Quartile category: Q4. The WJCC's CiteScore for 2021 is 1.2 and Scopus CiteScore rank 2021: General Medicine is 443/826.

RESPONSIBLE EDITORS FOR THIS ISSUE

Production Editor: *Ying-Yi Yuan*; Production Department Director: *Xiang Li*; Editorial Office Director: *Jin-Lei Wang*.

NAME OF JOURNAL

World Journal of Clinical Cases

ISSN

ISSN 2307-8960 (online)

LAUNCH DATE

April 16, 2013

FREQUENCY

Thrice Monthly

EDITORS-IN-CHIEF

Bao-Gan Peng, Jerzy Tadeusz Chudek, George Kontogeorgos, Maurizio Serati, Ja Hyeon Ku

EDITORIAL BOARD MEMBERS

<https://www.wjgnet.com/2307-8960/editorialboard.htm>

PUBLICATION DATE

July 26, 2022

COPYRIGHT

© 2022 Baishideng Publishing Group Inc

INSTRUCTIONS TO AUTHORS

<https://www.wjgnet.com/bpg/gerinfo/204>

GUIDELINES FOR ETHICS DOCUMENTS

<https://www.wjgnet.com/bpg/GerInfo/287>

GUIDELINES FOR NON-NATIVE SPEAKERS OF ENGLISH

<https://www.wjgnet.com/bpg/gerinfo/240>

PUBLICATION ETHICS

<https://www.wjgnet.com/bpg/GerInfo/288>

PUBLICATION MISCONDUCT

<https://www.wjgnet.com/bpg/gerinfo/208>

ARTICLE PROCESSING CHARGE

<https://www.wjgnet.com/bpg/gerinfo/242>

STEPS FOR SUBMITTING MANUSCRIPTS

<https://www.wjgnet.com/bpg/GerInfo/239>

ONLINE SUBMISSION

<https://www.f6publishing.com>

Pseudomonas aeruginosa-related effusive-constrictive pericarditis diagnosed with echocardiography: A case report

Jin-Ling Chen, Dan-E Mei, Cai-Gui Yu, Zhi-Yu Zhao

Specialty type: Cardiac and cardiovascular systems

Provenance and peer review: Unsolicited article; Externally peer reviewed.

Peer-review model: Single blind

Peer-review report's scientific quality classification

Grade A (Excellent): 0
Grade B (Very good): B
Grade C (Good): C, C
Grade D (Fair): 0
Grade E (Poor): 0

P-Reviewer: Ghimire R, Nepal; Russo D, Italy

A-Editor: Liu X, China

Received: February 18, 2022

Peer-review started: February 18, 2022

First decision: March 24, 2022

Revised: April 5, 2022

Accepted: May 28, 2022

Article in press: May 28, 2022

Published online: July 26, 2022



Jin-Ling Chen, Dan-E Mei, Cai-Gui Yu, Zhi-Yu Zhao, Department of Echocardiography, Renmin Hospital of Wuhan University, Wuhan 430060, Hubei Province, China

Corresponding author: Dan-E Mei, MD, Doctor, Department of Echocardiography, Renmin Hospital of Wuhan University, No. 238 Jiefang Road, Wuchang District, Wuhan 430060, Hubei Province, China. 1124635677@qq.com

Abstract

BACKGROUND

Effusive-constrictive pericarditis (ECP) is an uncommon pericardial syndrome. Careful echocardiographic examination may provide helpful information not only for diagnosing but also for managing ECP. ECP has various etiologies; however, *Pseudomonas aeruginosa* (*P. aeruginosa*) infection has not been reported as a cause to date. Herein, we present a rare case of ECP caused by *P. aeruginosa* infection, which was followed up using echocardiography.

CASE SUMMARY

A 30-year-old man was admitted to our hospital with a 2-mo history of cough, dyspnea, bloating, palpitations, and lower-extremity edema. The patient was initially diagnosed with pericardial effusion by transthoracic echocardiography. Drainage of pericardial effusion was performed to relieve the clinical symptoms. A follow-up echocardiogram showed that the pericardial effusion had decreased; however, the right atrial pressure continued to increase, and signs of constrictive pericarditis were observed upon a more comprehensive inspection. Therefore, the diagnosis of ECP was established based on the comprehensive pre- and post-pericardiocentesis echocardiographic findings. An urgent pericardiectomy was subsequently performed, which significantly relieved the patient's clinical symptoms, and the signs of pericardial constriction on echocardiography improved. Pericardial effusion and pericardial culture showed growth of *P. aeruginosa*.

CONCLUSION

ECP induced by *P. aeruginosa* infection remains a rare disease. The presence of echocardiographic features of constrictive pericarditis after pericardiocentesis therapy is highly indicative of ECP.

Key Words: Effusive-constrictive pericarditis; *Pseudomonas aeruginosa* infection; Echocardiography; Case report

Core Tip: Effusive-constrictive pericarditis (ECP) is an uncommon clinical syndrome with varied causes, and *Pseudomonas aeruginosa* (*P. aeruginosa*) infection is an extremely rare etiology of ECP. This report presents a rare case of *P. aeruginosa*-induced ECP that was diagnosed based on comprehensive post-pericardiocentesis follow-up echocardiography. The patient was initially misdiagnosed with pure pericardial effusion. This emphasizes the importance of sensitive identification of ECP echocardiographic features and the advantage of follow-up echocardiography after pericardiocentesis for the diagnosis and treatment of ECP.

Citation: Chen JL, Mei DE, Yu CG, Zhao ZY. *Pseudomonas aeruginosa*-related effusive-constrictive pericarditis diagnosed with echocardiography: A case report. *World J Clin Cases* 2022; 10(21): 7577-7584

URL: <https://www.wjgnet.com/2307-8960/full/v10/i21/7577.htm>

DOI: <https://dx.doi.org/10.12998/wjcc.v10.i21.7577>

INTRODUCTION

Pericardial effusion is a common clinical condition that can be accurately diagnosed using echocardiography. However, when acute pericardial effusion gradually transforms into chronic constrictive pericarditis, which is defined as effusive-constrictive pericarditis (ECP), the diagnosis becomes confusing and may lead to misdiagnosis and inappropriate treatment. As an uncommon clinical syndrome, ECP is characterized by the coexistence of pericardial effusion and constriction of the heart by the visceral pericardium[1]. The persistence of elevated central venous pressure after pericardiocentesis is the hemodynamic characteristic of ECP. The etiologies of ECP include purulent pericarditis, tuberculosis, trauma, and neoplastic involvement[2], of which *Pseudomonas aeruginosa* (*P. aeruginosa*) infection represents an extremely small percentage. Follow-up echocardiography is a useful tool for diagnosing and treating ECP. Herein, we report a rare case of ECP caused by *P. aeruginosa* infection, diagnosed using echocardiography before and after pericardiocentesis.

CASE PRESENTATION

Chief complaints

A 30-year-old man was admitted to our hospital with a 2-mo history of cough, dyspnea, bloating, palpitations, and lower extremity edema (Table 1).

History of present illness

He was diagnosed with atrial fibrillation, heart failure, and multiple serous effusions (pleural, pericardial, and abdominal effusions) at a local hospital.

History of past illness

The patient had no history of any previous disease.

Personal and family history

The patient had no previous or family history of similar illnesses.

Physical examination

The patient's vital signs on admission were stable. Cardiac auscultation revealed muffled heart sounds. Palpation revealed mild edema in both the lower extremities. Electrocardiography revealed atrial fibrillation and a decreased voltage.

Laboratory examinations

Blood tests revealed slightly elevated thyroid-stimulating hormone levels, moderately elevated inflammatory markers, and significantly increased N-terminal-pro hormone brain natriuretic peptide levels. The liver and kidney functions were within the normal range. The T-SPOT test yielded a negative result.

Imaging examinations

Two-dimensional transthoracic echocardiography (2D-TTE), on admission, revealed a significantly

Table 1 Timeline

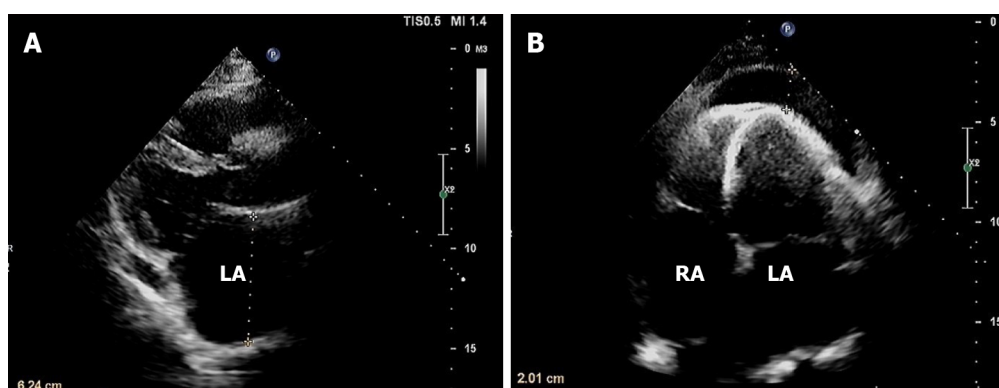
Day 1	A 30-yr-old man was admitted to our hospital with a 2-mo history of cough, dyspnea, bloating, palpitation, and lower extremity oedema
Day 2	The patient was taken to the ultrasound department for an echocardiogram showing a moderate-sized localized pericardial effusion, with an increase in the RAD and LAD (Figure 1)
Day 5	The patient underwent pericardiocentesis to relieve the clinical conditions
Day 6	The patient's clinical symptoms were slightly relieved
Day 8	A repeat echocardiogram showed decreased pericardial effusion compared with the first examination and characteristic manifestations of pericardial constriction. A diagnosis of ECP was established (Figure 2)
Day 10	A CT scan demonstrated a small amount of pericardial effusion with thickened pericardium
Day 15	PET-CT examination ruled out neoplastic and connective tissue diseases
Day 17	The patient underwent pericardectomy, which led to a rapid improvement in the clinical symptoms
Day 19	Histologic examination performed on the pericardial tissue obtained during pericardectomy showed increased thickening with the proliferation of collagen fibers, hyaline degeneration, and calcification (Figure 4)
Day 20	Cytologic examination of the pericardial fluid obtained during pericardectomy showed many inflammatory cells and few mesothelial cells. Cultures of the pericardial fluid and pericardium grew <i>Pseudomonas aeruginosa</i>
Day 24	A repeat 2D-TTE 1 wk after pericardectomy revealed improvement in the biatrial diameter, Doppler features of pericardial constriction, and the right atrial pressure (Figure 3)
Day 26	The patient was discharged home in stable condition
1 mo post-discharge	A follow-up echocardiogram revealed that the right atrial pressure assessed using echocardiography had significantly decreased in the absence of pericardial constriction echocardiographic features (Figure 5)

RAD: Right atrium dimension; LAD: Left atrium dimension; ECP: Effusive-constrictive pericarditis; 2D-TTE: two-dimensional transthoracic echocardiography; PET: Positron emission tomography; CT: Computed tomography.

enlarged diameter of the left atrium (LAD) and right atrium (RAD) and a moderate pericardial effusion that was predominantly along the apical wall, measuring up to 2 cm (Figure 1). The diagnosis of biatrial enlargement due to atrial fibrillation and localized pericardial effusion was established according to echocardiographic manifestations and history. Emergency surgical pericardial drainage was performed by removing 500 mL purulent fluid to relieve the clinical presentation. Despite the removal of most of the pericardial fluid, which indicates a significant decrease in intrapericardial pressure, the patient's clinical symptoms showed no significant improvement. Subsequent 2D-TTE (Figure 2) failed to show normalization of LAD and RAD. In addition, echocardiography revealed other information with significant diagnostic value, such as abnormal movement of the interventricular septum ("interventricular septum bounce") and increased pericardial thickness. Notably, pulsed-wave Doppler revealed significant respiratory variation (greater than 25%) in the peak mitral inflow velocity (E) and an increase in the peak velocity blood flow from left ventricular relaxation in early diastole to peak velocity flow in late diastole caused by atrial contraction (E/A) ratio (> 2). Tissue Doppler imaging of the mitral annulus revealed "annulus reversus," as the lateral mitral e' velocity was lower than the medial mitral e' velocity. M-mode echocardiography revealed a dilated inferior vena cava (IVC) with almost no aspiratory variation, according to which the estimated right atrial pressure was elevated (20 mmHg). Thus, a diagnosis of ECP as the underlying cause of the clinical presentation was established according to the pre- and post-pericardiocentesis echocardiographic performance. Computed tomography (CT) scan also revealed a small amount of pericardial effusion with a thickened pericardium. Positron emission tomography-CT (PET-CT) ruled out connective tissue and neoplastic diseases. Clinical and imaging tests revealed the need for urgent surgical removal of the residual pericardial effusion and visceral pericardium. A repeat 2D-TTE 1-wk after pericardectomy revealed that the biatrial diameter and echocardiographic features of pericardial constriction improved, and the right atrial pressure assessed using echocardiography also decreased (Figure 3 and Table 1).

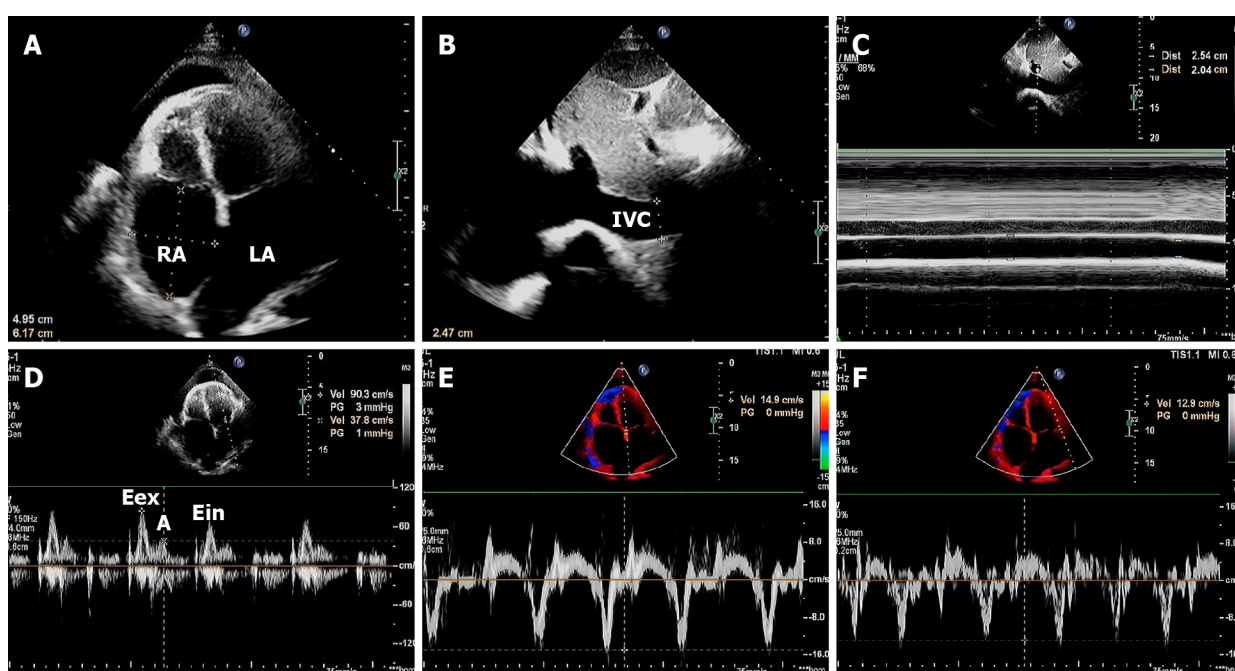
Postoperative biochemical examination and pathological examination

Cytological examination of the pericardial fluid revealed many inflammatory cells and few mesothelial cells. Cultures of the pericardial fluid and the pericardium grew *P. aeruginosa*. Histological examination of the pericardial tissue obtained during pericardectomy revealed increased thickening with the proliferation of collagen fibers, hyaline degeneration, and calcification (Figure 4 and Table 1).



DOI: 10.12998/wjcc.v10.i21.7577 Copyright ©The Author(s) 2022.

Figure 1 Echocardiographic examinations before pericardiocentesis. A: The left atrium was significantly enlarged, with an anteroposterior diameter of 6.2 cm; B: The diameters of the left and right atrium were 5.9 cm × 6.1 cm and 5.0 cm × 6.0 cm, respectively. A moderate pericardial effusion that was predominantly along the apical wall, measuring up to 2.0 cm. LA: Left atrium; RA: Right atrium.



DOI: 10.12998/wjcc.v10.i21.7577 Copyright ©The Author(s) 2022.

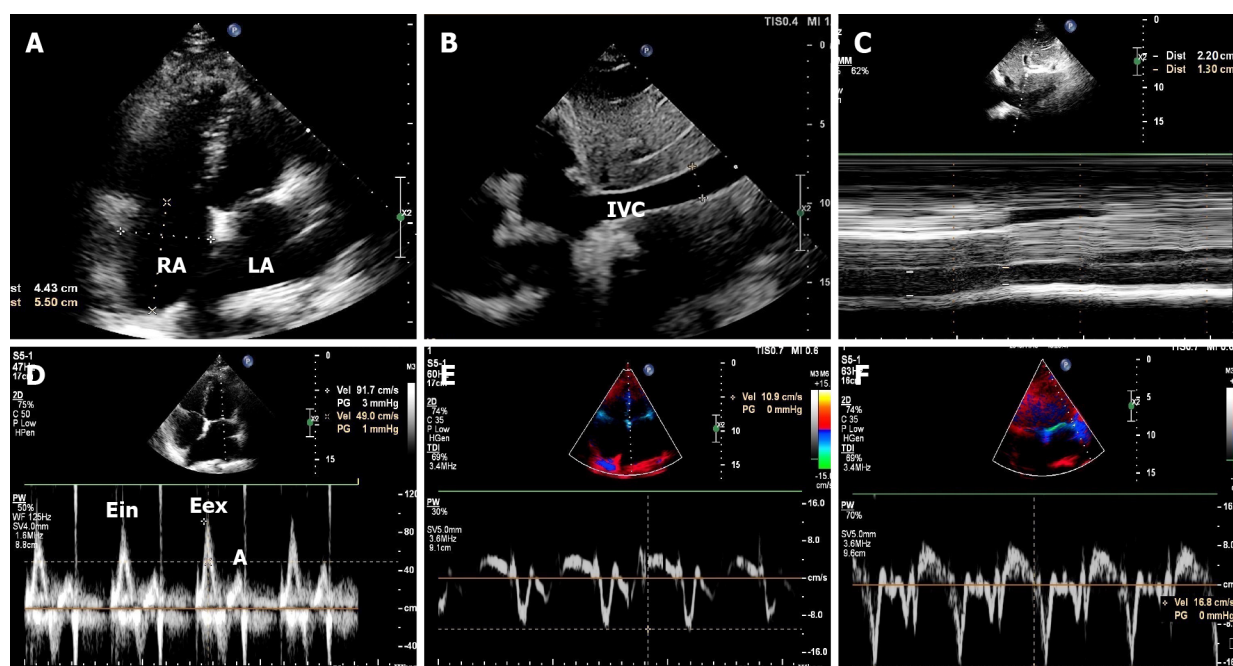
Figure 2 Echocardiographic examinations after pericardiocentesis. A: Right atrial (50 mm × 62 mm) and left atrial (61 mm × 61 mm) enlargement, increased pericardial thickness, and pericardial effusion that was located predominantly along the apical wall (measuring up to 1.2 cm); B and C: Dilated inferior vena cava (up to 2.5 cm) almost without any aspiratory variation (20%), indicating an elevated right atrial pressure of approximately 20 mmHg; D: Pulsed wave doppler of the mitral valve showed that the peak mitral E and A inflow velocity were 90 cm/s and 38 cm/s, respectively. The E/A ratio was > 2, indicating restricted mitral inflow velocity. Respiratory variation in the peak mitral E inflow velocity was 28% (peak E velocity during expiration and inspiration were 90 cm/s and 65 cm/s, respectively); E and F: Tissue Doppler imaging showed “annulus reversus” with the lateral mitral e' velocity (12.9 cm/s) abnormally lower than the medial mitral e' velocity (14.9 cm/s). IVC: Inferior vena cava; LA: Left atrium; RA: Right atrium.

FINAL DIAGNOSIS

ECP caused by *P. aeruginosa* infection.

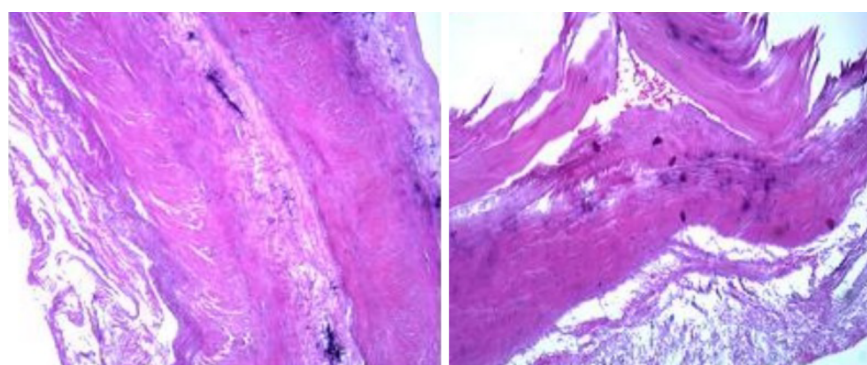
TREATMENT

Emergency surgical pericardial drainage was performed to relieve the clinical presentation by removing 500 mL purulent fluid according to the initial diagnosis of moderate pericardial effusion established by echocardiography. Antibiotics and diuretics were subsequently administered to relieve the symptoms. After the diagnosis of ECP was established *via* follow-up echocardiography, pericardectomy was



DOI: 10.12998/wjcc.v10.i21.7577 Copyright ©The Author(s) 2022.

Figure 3 The follow-up echocardiography 1 wk after pericardectomy. A: The diameters of the left and right atrium were 5.4 cm × 6.1 cm and 4.4 cm × 5.5 cm, respectively. The localized pericardial effusion disappeared; B and C: The diameter of the inferior vena cava (2.2 cm) and aspiratory variation were still lower than 50% (41%). The calculated right atrial pressure was lower than that before pericardectomy (12 mmHg); D: Pulsed-wave Doppler of the mitral valve showed that the peak mitral E and A inflow velocities were 92 cm/s and 49 cm/s, respectively. Respiratory variation in the peak mitral inflow velocity (E) was 15% (peak E velocity during expiration and inspiration were 92 cm/s and 78 cm/s, respectively); E and F: Tissue Doppler imaging revealed that the medial mitral e' velocity (10.9 cm/s) was lower than the lateral mitral e' velocity (16.8 cm/s). IVC: Inferior vena cava; LA: Left atrium; RA: Right atrium.



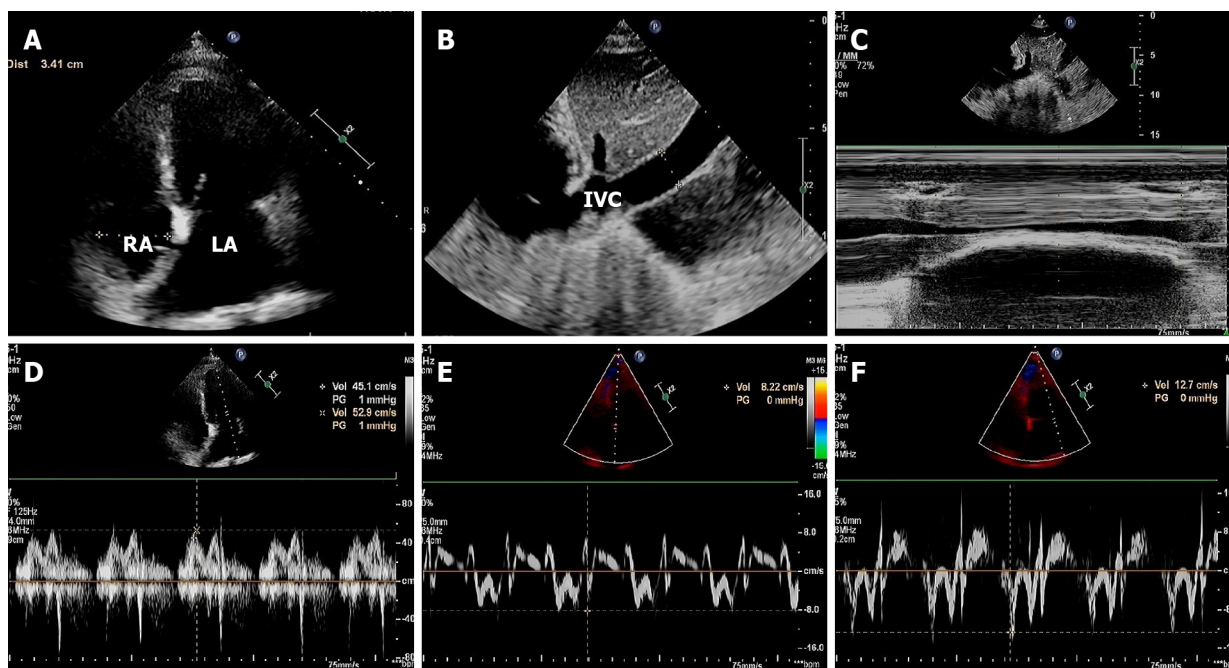
DOI: 10.12998/wjcc.v10.i21.7577 Copyright ©The Author(s) 2022.

Figure 4 Histologic examination performed on the pericardial tissue revealed increased thickening with the proliferation of collagen fibers, hyaline degeneration, and calcification.

performed. During pericardectomy, we observed that the heart was covered by a 2 mm inflammatory membrane, which eventually led to the loss of elasticity of the pericardium, external compression, and diastolic restriction of the heart. Antibiotic therapy was administered to the patient after surgery (Table 1).

OUTCOME AND FOLLOW-UP

It was only after the careful removal of the constricted visceral pericardium that a reduction in the right atrial pressure was observed, and the echocardiographic patterns of constrictive physiology improved. The patient's clinical symptoms were significantly relieved. Echocardiography performed 1 mo after surgery demonstrated an obvious improvement in the echocardiography data and hemodynamics. It showed that the pericardial effusion was resolved, the RAD and LAD decreased, and the right atrial pressure was also significantly decreased (Figure 5 and Table 1).



DOI: 10.12998/wjcc.v10.i21.7577 Copyright ©The Author(s) 2022.

Figure 5 The follow-up echocardiography 1 mo after discharge. A: The size of the left atrium was smaller than before (5.3 cm × 5.5 cm), and the right atrium was approximately normal (3.4 cm × 4.2 cm) in the absence of pericardial effusion; B and C: The diameter of the inferior vena cava (1.9 cm) and aspiratory variation (greater than 50%) were normalized, based on which the calculated right atrial pressure was within the normal range, approximately 5 mmHg; D: Pulsed-wave Doppler of the mitral valve showed that the peak mitral E and A inflow velocities were 45 cm/s and 53 cm/s, respectively. The E/A ratio was < 1; E and F: Tissue Doppler imaging showed that the medial mitral e' velocity (8.2 cm/s) was lower than the lateral mitral e' velocity (12.7 cm/s). IVC: Inferior vena cava; LA: Left atrium; RA: Right atrium.

DISCUSSION

ECP is a rare pericardial disease characterized by the coexistence of pericardial constriction and effusion. Its characteristic feature is a persistently elevated right atrial pressure of > 10 mmHg or a reduction of less than 50% from baseline despite pericardiocentesis[3]. The etiology of ECP varies, including idiopathic origin, viral origin, post-procedural origin, radiation, drug-induced, connective tissue disease, malignancy, and tuberculosis. *P. aeruginosa* is a rare etiological agent of ECP. Given the growth of *P. aeruginosa* in the pericardial fluid and tissue, this was a case of ECP induced by *P. aeruginosa*, which is rarely reported in the literature. Infections with *P. aeruginosa* occur mainly in immunocompromised and neutropenic patients and are associated with the presence of indwelling catheters and disruption of the mucocutaneous barriers. Prior hospitalization and prior use of antibiotics were the most significant risk factors for the acquisition of antibiotic-resistant *P. aeruginosa* [4]. *P. aeruginosa* causes a polymorphonuclear reaction that may progress to fibrotic thickening of the pericardium, fibrin deposition and non-specific inflammation, eventually leading to constrictive pericarditis and purulent pericardial effusion[5].

The prevalence of ECP varies from 1.4% to 14% in patients presenting with pericardial effusion[6]. Most pericardial effusions are accurately recognized using echocardiography and do not require drainage with pericardiocentesis; pericardiocentesis is urgently needed to relieve symptoms only in symptomatic patients with cardiac tamponade. For patients with ECP, the clinical condition cannot be improved by drainage of the pericardial effusion alone, and pericardiectomy is a life-saving intervention. Therefore, sensitive identification of pure pericardial effusion and ECP is of vital significance for clinical treatment.

The gold standard for the diagnosis of ECP is invasive hemodynamic evaluation using cardiac catheterization. Echocardiography can provide a potential non-invasive diagnostic tool with high sensitivity and specificity, which shows the coexistence of effusive and constrictive pericardial features[2]. Identification of ECP using echocardiography requires comprehensive observation with 2D, Doppler, and M-mode echocardiography[7]. 2D imaging has an excellent ability to detect effusion, enlarged atrial size, interventricular septum bounce, and a dilated IVC, which are sensitive and specific signs for the initial diagnosis of ECP. The echo-Doppler findings are diagnostically helpful, and it has been proposed that the presence of constrictive pericarditis echocardiographic Doppler features after pericardiocentesis would help clarify the diagnosis of ECP[8,9]. The key characteristic performance features of ECP include “annulus reversus,” restrictive mitral inflow (E/A > 2), greater than 25% respiratory variation in the peak mitral inflow velocity (E)[10]. The M-mode echocardiography can demonstrate a persistently

dilated IVC and the posterior motion of the septum during early diastole on inspiration[7,11], providing additional diagnostic information. In the present case, echocardiographic signs of pericardial effusion were observed during the initial examination. However, ECP is relatively rare and cannot be easily diagnosed. As one of the most notable characteristics of pericardial constriction, pericardial thickness was ignored because of a lack of comprehensive understanding of ECP echocardiographic features, leading to a misdiagnosis of localized pericardial effusion. Although pericardial effusion decreased after pericardiocentesis, repeat echocardiography demonstrated that the right atrial pressure evaluated using echocardiography remained high, and the characteristics of pericardial constriction were present, providing sufficient evidence for the appropriate diagnosis of ECP.

The present case of ECP associated with *P. aeruginosa* infection demonstrated that in patients with localized pericardial effusion who have typical risk factors, such as infection, prior use of antibiotics, and prior hospitalization, the presence of ECP should be highly suspected[3]. Additionally, this case highlighted the significance of sensitive recognition of the echocardiographic features of ECP, including pericardial effusion combined with atrial enlargement, which is the most intuitive feature of constrictive pericarditis. A comprehensive study with 2D imaging, Doppler, and M-mode echocardiography is required to avoid misdiagnosis. More importantly, for patients initially diagnosed with pericardial effusion, the echocardiographic features of constrictive pericarditis after pericardiocentesis should raise a suspicion of ECP[12]. Therefore, when a localized pericardial effusion is detected, follow-up echocardiographic examinations may assist in clinical diagnosis and treatment.

CONCLUSION

We highlight a rare case of ECP associated with *P. aeruginosa* infection that was initially misdiagnosed as pericardial effusion using echocardiography. Comprehensive echocardiography, including 2D, M-mode, and Doppler echocardiography, should help avoid misdiagnosis, especially during the follow-up after pericardiocentesis.

FOOTNOTES

Author contributions: Chen JL designed the report and revised the manuscript; Mei DE analyzed the data, reviewed the literature and drafted the manuscript; Yu CG and Zhao ZY collected the patient's clinical data; all authors have read and approved the final manuscript.

Informed consent statement: Informed written consent was obtained from the patient for publication of this report and any accompanying images.

Conflict-of-interest statement: The authors declare that they have no conflicts of interest to report.

CARE Checklist (2016) statement: The authors have read the CARE Checklist (2016), and the manuscript was prepared and revised according to the CARE Checklist (2016).

Open-Access: This article is an open-access article that was selected by an in-house editor and fully peer-reviewed by external reviewers. It is distributed in accordance with the Creative Commons Attribution NonCommercial (CC BY-NC 4.0) license, which permits others to distribute, remix, adapt, build upon this work non-commercially, and license their derivative works on different terms, provided the original work is properly cited and the use is non-commercial. See: <https://creativecommons.org/licenses/by-nc/4.0/>

Country/Territory of origin: China

ORCID number: Jin-Ling Chen 0000-0001-5997-131X; Dan-E Mei 0000-0002-8910-0395; Cai-Gui Yu 0000-0003-2690-588X; Zhi-Yu Zhao 0000-0002-1619-5258.

S-Editor: Yan JP

L-Editor: A

P-Editor: Yan JP

REFERENCES

- 1 Chetrit M, Jain V, Cremer PC, Johnston D, Klein AL. Chronic calcific effusive constrictive pericarditis: a rare entity within the spectrum of pericardial diseases-a case report. *Eur Heart J Case Rep* 2020; 4: 1-3 [PMID: 33629021 DOI: 10.1093/ehjcr/ytaa322]
- 2 Miranda WR, Oh JK. Effusive-Constrictive Pericarditis. *Cardiol Clin* 2017; 35: 551-558 [PMID: 29025546 DOI: 10.1016/j.ccl.2017.05.001]

[10.1016/j.ccl.2017.07.008](https://doi.org/10.1016/j.ccl.2017.07.008)

- 3 **Al-Saiegh Y**, Spears J, Barry T, Lee C, Haber H, Goldberg S. Diagnosis and treatment of effusive-constrictive pericarditis: a case report. *Eur Heart J Case Rep* 2021; **5**: ytab174 [PMID: [34109293](https://pubmed.ncbi.nlm.nih.gov/34109293/) DOI: [10.1093/ehjcr/ytab174](https://doi.org/10.1093/ehjcr/ytab174)]
- 4 **Raman G**, Avendano EE, Chan J, Merchant S, Puzniak L. Risk factors for hospitalized patients with resistant or multidrug-resistant *Pseudomonas aeruginosa* infections: a systematic review and meta-analysis. *Antimicrob Resist Infect Control* 2018; **7**: 79 [PMID: [29997889](https://pubmed.ncbi.nlm.nih.gov/29997889/) DOI: [10.1186/s13756-018-0370-9](https://doi.org/10.1186/s13756-018-0370-9)]
- 5 **El Hassan N**, Dbaiibo G, Diab K, Musallam S, Haidar R, Obeid M, Bitar F. Pseudomonas pericarditis in an immunocompetent newborn: unusual presentation with review of the literature. *J Infect* 2002; **44**: 49-51 [PMID: [11972421](https://pubmed.ncbi.nlm.nih.gov/11972421/) DOI: [10.1053/j.jinf.2001.0894](https://doi.org/10.1053/j.jinf.2001.0894)]
- 6 **Paiardi S**, Pellegrino M, Cannata F, Bocciolone M, Voza A. Transitory effusive-constrictive pericarditis. *Am J Emerg Med* 2018; **36**: 524.e1-524.e6 [PMID: [29169889](https://pubmed.ncbi.nlm.nih.gov/29169889/) DOI: [10.1016/j.ajem.2017.11.047](https://doi.org/10.1016/j.ajem.2017.11.047)]
- 7 **Kalra AG**, Sharp AJ, Dinkha L, Gore R. Effusive-Constrictive Pericarditis in a Young Active Duty Male. *Cureus* 2020; **12**: e9997 [PMID: [32983696](https://pubmed.ncbi.nlm.nih.gov/32983696/) DOI: [10.7759/cureus.9997](https://doi.org/10.7759/cureus.9997)]
- 8 **Diaconu R**, Popescu L, Voicu A, Donoiu I. Subacute effusive-constrictive pericarditis in a patient with COVID-19. *BMJ Case Rep* 2021; **14** [PMID: [34116993](https://pubmed.ncbi.nlm.nih.gov/34116993/) DOI: [10.1136/bcr-2021-242443](https://doi.org/10.1136/bcr-2021-242443)]
- 9 **Kim KH**, Miranda WR, Sinak LJ, Syed FF, Melduni RM, Espinosa RE, Kane GC, Oh JK. Effusive-Constrictive Pericarditis After Pericardiocentesis: Incidence, Associated Findings, and Natural History. *JACC Cardiovasc Imaging* 2018; **11**: 534-541 [PMID: [28917680](https://pubmed.ncbi.nlm.nih.gov/28917680/) DOI: [10.1016/j.jcmg.2017.06.017](https://doi.org/10.1016/j.jcmg.2017.06.017)]
- 10 **Miranda WR**, Newman DB, Oh JK. Effusive-Constrictive Pericarditis: Doppler Findings. *Curr Cardiol Rep* 2019; **21**: 144 [PMID: [31758271](https://pubmed.ncbi.nlm.nih.gov/31758271/) DOI: [10.1007/s11886-019-1243-4](https://doi.org/10.1007/s11886-019-1243-4)]
- 11 **Ohsawa N**, Nakaoka Y, Kubokawa SI, Kubo T, Yamasaki N, Kitaoka H, Kawai K, Hamashige N, Doi Y. Subacute effusive-constrictive pericarditis: Echocardiography-guided diagnosis and management. *J Cardiol Cases* 2017; **16**: 14-17 [PMID: [30279787](https://pubmed.ncbi.nlm.nih.gov/30279787/) DOI: [10.1016/j.jccase.2017.03.007](https://doi.org/10.1016/j.jccase.2017.03.007)]
- 12 **Giordani AS**, De Gaspari M, Baritussio A, Rizzo S, Carturan E, Basso C, Napodano M, Testolin L, Marcolongo R, Caforio ALP. A rare cause of effusive-constrictive pericarditis. *ESC Heart Fail* 2021; **8**: 4313-4317 [PMID: [34173727](https://pubmed.ncbi.nlm.nih.gov/34173727/) DOI: [10.1002/ehf2.13470](https://doi.org/10.1002/ehf2.13470)]



Published by **Baishideng Publishing Group Inc**
7041 Koll Center Parkway, Suite 160, Pleasanton, CA 94566, USA

Telephone: +1-925-3991568

E-mail: bpgoffice@wjgnet.com

Help Desk: <https://www.f6publishing.com/helpdesk>

<https://www.wjgnet.com>

