

World Journal of *Clinical Cases*

World J Clin Cases 2022 August 6; 10(22): 7620-8056



Contents

Thrice Monthly Volume 10 Number 22 August 6, 2022

OPINION REVIEW

- 7620 Whipple's operation with a modified centralization concept: A model in low-volume Caribbean centers
Cawich SO, Pearce NW, Naraynsingh V, Shukla P, Deshpande RR

REVIEW

- 7631 Role of micronutrients in Alzheimer's disease: Review of available evidence
Fei HX, Qian CF, Wu XM, Wei YH, Huang JY, Wei LH

MINIREVIEWS

- 7642 Application of imaging techniques in pancreaticobiliary maljunction
Wang JY, Mu PY, Xu YK, Bai YY, Shen DH
- 7653 Update on gut microbiota in gastrointestinal diseases
Nishida A, Nishino K, Ohno M, Sakai K, Owaki Y, Noda Y, Imaeda H
- 7665 Vascular complications of pancreatitis
Kalas MA, Leon M, Chavez LO, Canalizo E, Surani S

ORIGINAL ARTICLE

Clinical and Translational Research

- 7674 Network pharmacology and molecular docking reveal zedoary turmeric-trisomes in Inflammatory bowel disease with intestinal fibrosis
Zheng L, Ji YY, Dai YC, Wen XL, Wu SC

Case Control Study

- 7686 Comprehensive proteomic signature and identification of CDKN2A as a promising prognostic biomarker and therapeutic target of colorectal cancer
Wang QQ, Zhou YC, Zhou Ge YJ, Qin G, Yin TF, Zhao DY, Tan C, Yao SK

Retrospective Cohort Study

- 7698 Is anoplasty superior to scar revision surgery for post-hemorrhoidectomy anal stenosis? Six years of experience
Weng YT, Chu KJ, Lin KH, Chang CK, Kang JC, Chen CY, Hu JM, Pu TW

Retrospective Study

- 7708 Short- (30-90 days) and mid-term (1-3 years) outcomes and prognostic factors of patients with esophageal cancer undergoing surgical treatments
Shi MK, Mei YQ, Shi JL

- 7720** Effectiveness of pulsed radiofrequency on the medial cervical branches for cervical facet joint pain
Chang MC, Yang S
- 7728** Clinical performance evaluation of O-Ring Halcyon Linac: A real-world study
Wang GY, Zhu QZ, Zhu HL, Jiang LJ, Zhao N, Liu ZK, Zhang FQ
- 7738** Correlation between the warning symptoms and prognosis of cardiac arrest
Zheng K, Bai Y, Zhai QR, Du LF, Ge HX, Wang GX, Ma QB
- 7749** Serum ferritin levels in children with attention deficit hyperactivity disorder and tic disorder
Tang CY, Wen F
- 7760** Application of metagenomic next-generation sequencing in the diagnosis of infectious diseases of the central nervous system after empirical treatment
Chen YY, Guo Y, Xue XH, Pang F
- 7772** Prognostic role of multiple abnormal genes in non-small-cell lung cancer
Yan LD, Yang L, Li N, Wang M, Zhang YH, Zhou W, Yu ZQ, Peng XC, Cai J
- 7785** Prospective single-center feasible study of innovative autorelease bile duct supporter to delay adverse events after endoscopic papillectomy
Liu SZ, Chai NL, Li HK, Feng XX, Zhai YQ, Wang NJ, Gao Y, Gao F, Wang SS, Linghu EQ

Clinical Trials Study

- 7794** Performance of Dexcom G5 and FreeStyle Libre sensors tested simultaneously in people with type 1 or 2 diabetes and advanced chronic kidney disease
Ólafsdóttir AF, Andelin M, Saeed A, Sofizadeh S, Hamoodi H, Jansson PA, Lind M

Observational Study

- 7808** Complications of chronic pancreatitis prior to and following surgical treatment: A proposal for classification
Murruste M, Kirsimägi Ü, Kase K, Veršinina T, Talving P, Lepner U
- 7825** Effects of comprehensive nursing on postoperative complications, mental status and quality of life in patients with glioma
Dong H, Zhang XL, Deng CX, Luo B

Prospective Study

- 7832** Predictors of long-term anxiety and depression in discharged COVID-19 patients: A follow-up study
Boyraz RK, Şahan E, Boylu ME, Kırpınar İ

META-ANALYSIS

- 7844** Same-day single-dose vs large-volume split-dose regimens of polyethylene glycol for bowel preparation: A systematic review and meta-analysis
Pan H, Zheng XL, Fang CY, Liu LZ, Chen JS, Wang C, Chen YD, Huang JM, Zhou YS, He LP

- 7859** Rectal nonsteroidal anti-inflammatory drugs, glyceryl trinitrate, or combinations for prophylaxis of post-endoscopic retrograde cholangiopancreatography pancreatitis: A network meta-analysis

Shi QQ, Huang GX, Li W, Yang JR, Ning XY

- 7872** Effect of celecoxib on improving depression: A systematic review and meta-analysis

Wang Z, Wu Q, Wang Q

CASE REPORT

- 7883** Rectal mature teratoma: A case report

Liu JL, Sun PL

- 7890** Antibiotic and glucocorticoid-induced recapitulated hematological remission in acute myeloid leukemia: A case report and review of literature

Sun XY, Yang XD, Yang XQ, Ju B, Xiu NN, Xu J, Zhao XC

- 7899** Non-secretory multiple myeloma expressed as multiple extramedullary plasmacytoma with an endobronchial lesion mimicking metastatic cancer: A case report

Lee SB, Park CY, Lee HJ, Hong R, Kim WS, Park SG

- 7906** Latamoxef-induced severe thrombocytopenia during the treatment of pulmonary infection: A case report

Zhang RY, Zhang JJ, Li JM, Xu YY, Xu YH, Cai XJ

- 7913** Multicentric reticulohistiocytosis with prominent skin lesions and arthritis: A case report

Xu XL, Liang XH, Liu J, Deng X, Zhang L, Wang ZG

- 7924** Brainstem abscesses caused by *Listeria monocytogenes*: A case report

Wang J, Li YC, Yang KY, Wang J, Dong Z

- 7931** Primary hypertension in a postoperative paraganglioma patient: A case report

Wei JH, Yan HL

- 7936** Long-term survival of gastric mixed neuroendocrine-non-neuroendocrine neoplasm: Two case reports

Woo LT, Ding YF, Mao CY, Qian J, Zhang XM, Xu N

- 7944** Percutaneous transforaminal endoscopic decompression combined with percutaneous vertebroplasty in treatment of lumbar vertebral body metastases: A case report

Ran Q, Li T, Kuang ZP, Guo XH

- 7950** Atypical imaging features of the primary spinal cord glioblastoma: A case report

Liang XY, Chen YP, Li Q, Zhou ZW

- 7960** Resection with limb salvage in an Asian male adolescent with Ewing's sarcoma: A case report

Lai CY, Chen KJ, Ho TY, Li LY, Kuo CC, Chen HT, Fong YC

- 7968** Early detection of circulating tumor DNA and successful treatment with osimertinib in thr790met-positive leptomeningeal metastatic lung cancer: A case report

Xu LQ, Wang YJ, Shen SL, Wu Y, Duan HZ

- 7973** Delayed arterial symptomatic epidural hematoma on the 14th day after posterior lumbar interbody fusion: A case report
Hao SS, Gao ZF, Li HK, Liu S, Dong SL, Chen HL, Zhang ZF
- 7982** Clinical and genetic analysis of nonketotic hyperglycinemia: A case report
Ning JJ, Li F, Li SQ
- 7989** Ectopic Cushing's syndrome in a patient with metastatic Merkel cell carcinoma: A case report
Ishay A, Touma E, Vornicova O, Dodiuk-Gad R, Goldman T, Bisharat N
- 7994** Occurrence of MYD88L265P and CD79B mutations in diffuse large b cell lymphoma with bone marrow infiltration: A case report
Huang WY, Weng ZY
- 8003** Rare case of compartment syndrome provoked by inhalation of polyurethane agent: A case report
Choi JH, Oh HM, Hwang JH, Kim KS, Lee SY
- 8009** Acute ischemic Stroke combined with Stanford type A aortic dissection: A case report and literature review
He ZY, Yao LP, Wang XK, Chen NY, Zhao JJ, Zhou Q, Yang XF
- 8018** Compound-honeysuckle-induced drug eruption with special manifestations: A case report
Zhou LF, Lu R
- 8025** Spontaneous internal carotid artery pseudoaneurysm complicated with ischemic stroke in a young man: A case report and review of literature
Zhong YL, Feng JP, Luo H, Gong XH, Wei ZH
- 8034** Microcystic adnexal carcinoma misdiagnosed as a "recurrent epidermal cyst": A case report
Yang SX, Mou Y, Wang S, Hu X, Li FQ
- 8040** Accidental discovery of appendiceal carcinoma during gynecological surgery: A case report
Wang L, Dong Y, Chen YH, Wang YN, Sun L
- 8045** Intra-ampullary papillary-tubular neoplasm combined with ampullary neuroendocrine carcinoma: A case report
Zavrtanik H, Luzar B, Tomažič A

LETTER TO THE EDITOR

- 8054** Commentary on "Primary orbital monophasic synovial sarcoma with calcification: A case report"
Tokur O, Aydin S, Karavas E

ABOUT COVER

Editorial Board Member of *World Journal of Clinical Cases*, Bennete Aloysius Fernandes, MDS, Professor, Faculty of Dentistry, SEGi University, Kota Damansara 47810, Selangor, Malaysia. drben17@yahoo.com

AIMS AND SCOPE

The primary aim of *World Journal of Clinical Cases* (WJCC, *World J Clin Cases*) is to provide scholars and readers from various fields of clinical medicine with a platform to publish high-quality clinical research articles and communicate their research findings online.

WJCC mainly publishes articles reporting research results and findings obtained in the field of clinical medicine and covering a wide range of topics, including case control studies, retrospective cohort studies, retrospective studies, clinical trials studies, observational studies, prospective studies, randomized controlled trials, randomized clinical trials, systematic reviews, meta-analysis, and case reports.

INDEXING/ABSTRACTING

The WJCC is now abstracted and indexed in Science Citation Index Expanded (SCIE, also known as SciSearch®), Journal Citation Reports/Science Edition, Current Contents®/Clinical Medicine, PubMed, PubMed Central, Scopus, Reference Citation Analysis, China National Knowledge Infrastructure, China Science and Technology Journal Database, and Superstar Journals Database. The 2022 Edition of Journal Citation Reports® cites the 2021 impact factor (IF) for WJCC as 1.534; IF without journal self cites: 1.491; 5-year IF: 1.599; Journal Citation Indicator: 0.28; Ranking: 135 among 172 journals in medicine, general and internal; and Quartile category: Q4. The WJCC's CiteScore for 2021 is 1.2 and Scopus CiteScore rank 2021: General Medicine is 443/826.

RESPONSIBLE EDITORS FOR THIS ISSUE

Production Editor: *Xu Guo*; Production Department Director: *Xiang Li*; Editorial Office Director: *Jin-Lei Wang*.

NAME OF JOURNAL

World Journal of Clinical Cases

ISSN

ISSN 2307-8960 (online)

LAUNCH DATE

April 16, 2013

FREQUENCY

Thrice Monthly

EDITORS-IN-CHIEF

Bao-Gan Peng, Jerzy Tadeusz Chudek, George Kontogeorgos, Maurizio Serati, Ja Hyeon Ku

EDITORIAL BOARD MEMBERS

<https://www.wjgnet.com/2307-8960/editorialboard.htm>

PUBLICATION DATE

August 6, 2022

COPYRIGHT

© 2022 Baishideng Publishing Group Inc

INSTRUCTIONS TO AUTHORS

<https://www.wjgnet.com/bpg/gerinfo/204>

GUIDELINES FOR ETHICS DOCUMENTS

<https://www.wjgnet.com/bpg/GerInfo/287>

GUIDELINES FOR NON-NATIVE SPEAKERS OF ENGLISH

<https://www.wjgnet.com/bpg/gerinfo/240>

PUBLICATION ETHICS

<https://www.wjgnet.com/bpg/GerInfo/288>

PUBLICATION MISCONDUCT

<https://www.wjgnet.com/bpg/gerinfo/208>

ARTICLE PROCESSING CHARGE

<https://www.wjgnet.com/bpg/gerinfo/242>

STEPS FOR SUBMITTING MANUSCRIPTS

<https://www.wjgnet.com/bpg/GerInfo/239>

ONLINE SUBMISSION

<https://www.f6publishing.com>



Spontaneous internal carotid artery pseudoaneurysm complicated with ischemic stroke in a young man: A case report and review of literature

Yu-Lin Zhong, Jia-Ping Feng, Hui Luo, Xue-Hao Gong, Zhang-Hong Wei

Specialty type: Radiology, nuclear medicine and medical imaging

Provenance and peer review:

Unsolicited article; Externally peer reviewed.

Peer-review model: Single blind

Peer-review report's scientific quality classification

Grade A (Excellent): 0
Grade B (Very good): B, B, B
Grade C (Good): C, C
Grade D (Fair): 0
Grade E (Poor): 0

P-Reviewer: Soliman MA, Egypt; Umana GE; Velnar T, Slovenia; Yap RVC, Philippines

Received: February 20, 2022

Peer-review started: February 20, 2022

First decision: March 24, 2022

Revised: April 4, 2022

Accepted: June 22, 2022

Article in press: June 22, 2022

Published online: August 6, 2022



Yu-Lin Zhong, Hui Luo, Zhang-Hong Wei, Department of Ultrasound, The Second Clinical College of Jinan University, Shenzhen People's Hospital, Shenzhen 518020, Guangdong Province, China

Yu-Lin Zhong, Hui Luo, Zhang-Hong Wei, Department of Ultrasound, The First Affiliated Hospital of Southern University of Science and Technology, Shenzhen People's Hospital, Shenzhen 518020, Guangdong Province, China

Jia-Ping Feng, Xue-Hao Gong, Department of Ultrasound, Shenzhen Second People's Hospital, The First Affiliated Hospital of Shenzhen University, Shenzhen 518035, Guangdong Province, China

Jia-Ping Feng, Xue-Hao Gong, Graduate School, Guangzhou Medical University, Guangzhou 510180, Guangdong Province, China

Corresponding author: Zhang-Hong Wei, MM, Doctor, Department of Ultrasound, The Second Clinical College of Jinan University, Shenzhen People's Hospital, No. 1017 Dongmen North Road, Luohu District, Shenzhen 518020, Guangdong Province, China. weizhhsz@126.com

Abstract

BACKGROUND

Carotid artery pseudoaneurysm (PSA) is infrequently encountered in clinical settings. Internal carotid artery (ICA) PSA complicated with ischemic stroke is rare. PSAs are typically caused by iatrogenic injury, trauma, or infection. The underlying mechanisms of spontaneous PSA formation are not well characterized. We report a healthy young man who presented with stroke as a complication of spontaneous PSA of the left ICA.

CASE SUMMARY

A 30-year-old man working as a ceiling decoration worker was hospitalized due to sudden-onset speech disorder and right lower extremity weakness. Medical history was unremarkable. Brain computed tomography revealed ischemic stroke. Digital subtraction angiography showed a left ICA PSA with mild stenosis. The patient was conservatively managed with oral anticoagulation and antiplatelet therapy. He recovered well and was discharged. The patient was in good condition during follow-up.

CONCLUSION

The occupational history of patient should be taken into consideration while evaluating the etiology of spontaneous ICA PSA in young people with stroke.

Key Words: Pseudoaneurysm; Carotid artery injury; Ischemic stroke; Case report

©The Author(s) 2022. Published by Baishideng Publishing Group Inc. All rights reserved.

Core Tip: In a previously healthy youngster with stroke, it is counterintuitive to make a connection between stroke and pseudoaneurysm (PSA), especially if there is no obvious cause. To best of our knowledge, this is the first report of spontaneous carotid artery PSA with stroke in a young adult. This case report may provide insights for diagnosis of carotid artery PSA in youngsters. Conservative therapy is a viable alternative for young patients with small carotid PSA.

Citation: Zhong YL, Feng JP, Luo H, Gong XH, Wei ZH. Spontaneous internal carotid artery pseudoaneurysm complicated with ischemic stroke in a young man: A case report and review of literature. *World J Clin Cases* 2022; 10(22): 8025-8033

URL: <https://www.wjgnet.com/2307-8960/full/v10/i22/8025.htm>

DOI: <https://dx.doi.org/10.12998/wjcc.v10.i22.8025>

INTRODUCTION

Arterial wall has a three-layered structure comprising of intima, media, and adventitia[1]. Rupture of the arterial wall may occur due to several reasons, such as iatrogenic injury, trauma, infection, or tumor invasion[2]. Disruption of the arterial wall following injury leads to formation of hematoma adjacent to the artery; subsequent proliferation of peripheral fibroblasts may result in encapsulation and organization of the hematoma leading to the formation of pseudoaneurysm (PSA)[3]. A previous study has shown that PSA formation is the most common complication of endovascular intervention with the incidence rates ranging from 0.7% to 6.25%. Femoral arteries and cardiovascular is the most common site of formation of PSA[4]. Traumatic internal carotid artery (ICA) PSA is a rare entity, with an incidence of approximately 9% in cases with head and neck trauma[5]. The clinical manifestations depend on the size, site, and etiology of the PSAs; however, the development of PSA can cause severe complications such as rupture, stroke, or asphyxia[6,7]. Digital subtraction angiography (DSA) has a high sensitivity and specificity for the diagnosis of ICA PSA and is considered as the diagnostic gold standard of PSA[8].

In this case report, we describe a case of a 30-year-old male who suffered speech disorders and right lower extremity weakness and review the previously reported cases.

CASE PRESENTATION

Chief complaints

A 30-year-old man was admitted to the Neurology department of our hospital because of the chief complaints of speech disorder and right lower extremity weakness five days ago.

History of present illness

Five days ago, the patient developed sudden-onset speech disorder and right lower extremity weakness at work and was admitted to a local hospital. The condition of the patient showed gradual improvement after administration of thrombolytic treatment. The etiology of stroke was still unknown. In order to seek more comprehensive diagnosis and treatment, the patient was referred to the Neurology department of our hospital.

History of past illness

The patient had no history of hypertension, diabetes, or coronary artery disease. Furthermore, there was no history of acute trauma or iatrogenic injury.

Personal and family history

The patient was a ceiling decoration worker. He had no history of smoking and alcohol consumption.

Personal and family history was unremarkable. There was no family history of connective tissue disease, such as Marfan syndrome.

Physical examination

On physical examination, the patient was found to have a hemiparetic gait. The muscle strength of right upper and lower limbs was grade 4 and the light touch sensation was attenuated on the right side. Babinski sign was found in the sole of his right foot. Other physical findings were unremarkable.

Laboratory examinations

Routine blood parameters were as follows: Leukocyte count $11.37 \times 10^9/L$; platelet count $344 \times 10^9/L$; neutrophils 84.9%; plasma fibrinogen 4.12 g/L; lactic dehydrogenase 287 U/L. Renal function and liver function tests were normal.

Imaging examinations

Cerebral computed tomography showed low-density foci in the left frontotemporal and centroparietal regions, which were indicative of left ischemic stroke. Ultrasonography of the carotid arteries exhibited a mixed echogenic mass at the origin of the left ICA (Figure 1). Computed tomography angiography (CTA) revealed a nodular mass with mural thrombus in continuity with the adjacent left ICA lumen; the size of the mass was approximately 10 mm \times 7 mm (Figure 2). DSA indicated a PSA at the origin of the left ICA with mild stenosis.

FINAL DIAGNOSIS

Left ICA PSA complicated with ischemic stroke.

TREATMENT

Low-dose alteplase and oral anticoagulation and antiplatelet therapy. For ischemic stroke, the local hospital evaluated the condition of patient and opted for low-dose alteplase to maintain the benefits of treatment while reducing the risk of systemic or intracerebral hemorrhage[9]. As for carotid PSA, the patient failed the ICA temporary occlusion test, which implied that his cerebral arteries could not develop sufficient cerebral collateral circulation. Therefore, we intended to use a combination of endovascular stent placement and coil embolization to treat the PSA. However, the patient refused this treatment option because of the costs and the associated risks. Therefore, he was conservatively managed with oral anticoagulation and antiplatelet therapy.

OUTCOME AND FOLLOW-UP

The patient recovered satisfactorily and was discharged from hospital on day 8. In order to prevent recurrence of ischemic stroke, he was prescribed oral aspirin for one month[9]. The patient was found to be in a good condition on follow-up evaluation performed at 3 and 6 months. Cerebral computed tomography (CTA) showed a large encephalomalacia focus in the left temporal-basal region, which indicated that the patient was at the convalescent stage of ischemic stroke. On cervical CTA, the size of PSA at the origin of the left carotid artery was significantly smaller than before, which was consistent with the results of DSA (Figure 3). However, we did not obtain further follow-up data for patients beyond 6 months.

DISCUSSION

The incidence of stroke in young people has increased over the past decades, reaching 221 per 100000 by the end of 2019. Underlying cardiovascular disease is the main cause of stroke in this population, while aneurysms or PSA are not common causes of stroke[10,11]. PSA typically occurs due to iatrogenic injury, trauma, infection, and tumor invasion[3,12]. Spontaneous PSA are rare entities. Spontaneous PSA associated with stroke are exceedingly rare[13]. A comprehensive search of the literature was performed using the PubMed, Embase, Cochran Library and Web of Science databases to retrieve studies published before December 2021 (Supplementary material). In the 16 cases reviewed by us, the etiology of 5 cases (31%) was trauma[14-18] and 4 cases (25%) had iatrogenic injury[19-22], while only 2 cases (13%) were spontaneous; however, both spontaneous cases had a history of hypertension and hyperlipidemia[23,24] (Table 1). Our patient was a young adult with no personal or family history of

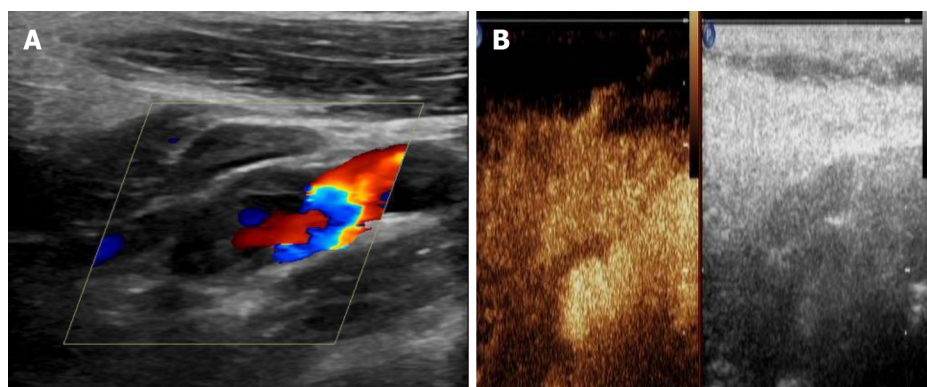
Table 1 Literature review of pseudoaneurysm with the clinical presentation of stroke

Case No.	Ref.	Year	Age	Sex	Site	Etiology	Imaging modality	Treatments	Outcome	Follow-up
1	[14]	2000	19	M	R CCA	Traumatic	CT, US, MRA, DSA	Surgical resection	REC	NA
2	[35]	2005	62	M	L INA	Infectious	US, MRI	Surgical resection	REC	1 mo
3	[19]	2007	60	M	R ICA	Iatrogenic	MRI, DSA	Endovascular stenting	REC	NA
4	[15]	2007	31	M	R ICA	Traumatic	MRI, CT, DSA	Endovascular stenting	REC	NA
5	[24]	2008	51	M	L ICA	Spontaneous	MRI, CT, DSA	Endovascular stenting	REC	NA
6	[43]	2014	71	M	L ICA	Radioactive	US, CT, MRI, DSA	Endovascular occlusion	REC	NA
7	[16]	2013	46	M	L ICA	Traumatic	CT, DSA	Endovascular stenting	REC	14 mo
8	[44]	2017	2	M	L ICA	Infectious	MRI, CT, DSA	Endovascular occlusion	REC	1 mo
9	[23]	2018	85	M	L ECA	Spontaneous	US, CT, MRI, DSA	Conservative therapy	Death	7 mo
10	[45]	2019	60	F	L ECA	Congenital	MRI, CT, DSA	Endovascular stenting	REC	NA
11	[22]	2019	45	M	L CCA	Iatrogenic	CT, CTA	NA	REC	NA
12	[20]	2019	57	F	L CCA	Iatrogenic	CT, CTA	Endovascular occlusion	REC	6 mo
13	[21]	2019	79	M	R FA	Iatrogenic	CT, MRI, CTA	Endovascular stenting	NA	NA
14	[46]	2020	53	M	SA	Infectious	CT, DSA	Conservative therapy	REC	NA
15	[17]	2020	31	F	L VA	Traumatic	CT, CTA, DSA	Conservative therapy	REC	6 mo
16	[18]	2021	35	M	L ICA	Traumatic	US, MRI, MRA	Endovascular occlusion	REC	3 mo
Present case		2022	30	M	L ICA	Spontaneous	US, CT, CTA, DSA	Conservative therapy	REC	6 mo

CCA: Common carotid artery; CT: Computed tomography; CTA: Computed tomography angiography; DSA: Digital subtraction angiography; ECA: External carotid artery; F: Female; FA: Femoral artery; ICA: Internal carotid artery; INA: Innominate artery; L: Left; M: Male; MRA: Magnetic resonance angiography; MRI: Magnetic resonance imaging; NA: Not available; R: Right; REC: Recovery; SA: Splenic artery; US: Ultrasound; VA: Vertebral artery.

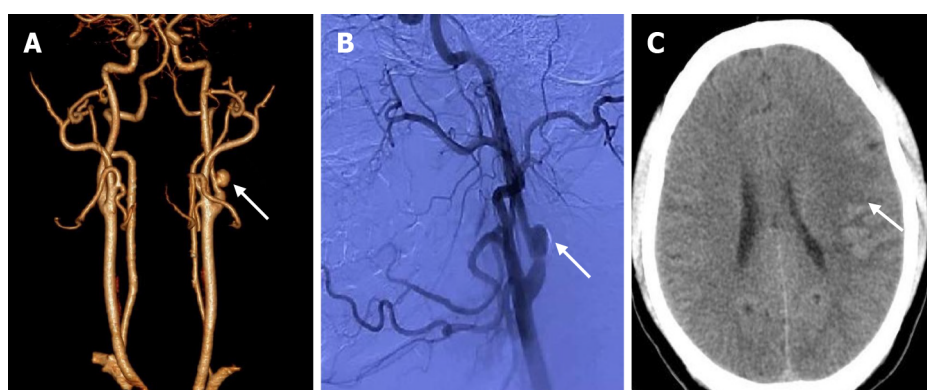
cardiovascular disease. Moreover, there was no history of neck trauma or surgery on the neck. We speculated that the etiology was related to the nature of the patient's job. The patient worked as a ceiling decorator, whose daily work entailed prolonged extension of the neck for working on the ceiling. The prolonged neck extension may have caused damage to the wall of the ICA, which contributed to the formation of PSA. Moreover, PSAs are more prone to thrombosis due to vortex in the PSAs[25]. The patient developed sudden weakness of the right lower limb and speech disorder at work, which may be due to the hemodynamic changes at the thrombus site caused by the change in head posture. Subsequently, the thrombus embolized to the M1 segment of the left middle cerebral artery, resulting in ischemic stroke of the temporoparietal lobe[26]. Our experience suggests that carotid PSA should be considered when evaluating a patient presenting with stroke. what's more, it is necessary to perfect the relevant examinations.

Carotid ultrasonography, a noninvasive, cost-effective, and radiation-free method, is currently the first-line imaging modality for screening carotid artery PSA. Doppler sonography can help distinguish a PSA from an aneurysm and/or other cervical mass[27]. It typically shows a neck mass with the typical features of PSA, including spontaneously echogenic swirling flow in the lumen and "to-and-fro" waveforms at the neck[28]. However, the "to-and-fro" waveforms were not observed in our patient, probably because of the relatively small tumor size. Furthermore, it is difficult to directly detect an ICA PSA that is located about 20 mm above the bifurcation of the common carotid artery[29]. In our patient,



DOI: 10.12998/wjcc.v10.i22.8025 Copyright ©The Author(s) 2022.

Figure 1 Ultrasonography and contrast-enhanced ultrasound of the carotid artery. A: Conventional carotid artery ultrasonography showing a connection of the mass with the left internal carotid artery (ICA); B: Contrast-enhanced ultrasound of the carotid artery showing contrast agent filling in the distended area of the left ICA, but no enhancement in the low echo area of the mural.

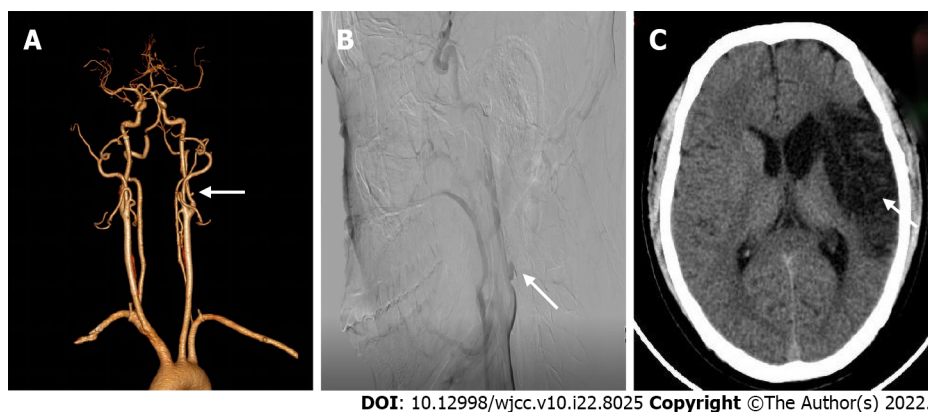


DOI: 10.12998/wjcc.v10.i22.8025 Copyright ©The Author(s) 2022.

Figure 2 Left internal carotid artery pseudoaneurysm with acute ischemic stroke. A: Computed tomography (CT) angiography reconstruction shows a nodular mass with mural thrombus in continuity with the adjacent left internal carotid artery lumen; B: Digital subtraction angiography indicates a pseudoaneurysm at the origin of the left internal carotid artery with mild stenosis; C: Cerebral CT showing an area of low-density foci in the left frontotemporal and centroparietal regions, which indicates left ischemic stroke.

although this PSA was located 17 mm above the common carotid artery bifurcation, when we found a mass in the initial part of the ICA, we performed contrast-enhanced ultrasound (CEUS) of the carotid artery. CEUS showed contrast agent filling in the distended area of the left ICA, but no enhancement in the low echo area of the mural (Video 1). This finding suggests that the combination of ultrasonography and CEUS of the carotid artery may facilitate the diagnosis of PSA located at a relatively high position. CTA can effectively depict the localization, size, and mural thrombus of PSA[30]; furthermore, CTA with 3D reconstruction maps can delineate the outer wall of PSA and its relationship with peri-PSA vascular structures, which can provide surgeons with intuitive 3D image guidance[8]. In our case, CTA reconstruction revealed a nodular mass with mural thrombus in continuity with the adjacent left ICA lumen, which was an important anatomical information. The gold standard for the diagnosis of PSA is DSA with > 99% sensitivity and 100% specificity[8,31]. Out of the 16 reported cases, DSA was used as a diagnostic method in 11 cases (69%). In the present case, angiography showed the contrast agent entering the tumor cavity along with changes in eddy currents, which indicated rupture of the left ICA wall and the formation of PSA. Furthermore, the parent artery was localized with delayed distal development, which indicated compression of ICA. Although the diagnostic performance of DSA is pretty good, it is difficult to detect PSA that is filled with thrombus at the early stage[32].

Surgery and endovascular therapy are two main treatment modalities for carotid PSA[33]. Because of the severe complications of surgery and the rapid advances in the field of endovascular intervention, endovascular therapy has emerged as the preferred treatment for carotid PSA, especially for patients with PSA who present with stroke[34]. Surgical resection is used as an alternative to endovascular treatment. In addition, the choice of endovascular therapy depends on the lesion site and the performance status of patient[14]. Out of the 16 reviewed cases, only 3 patients (13%) were treated with surgical resection[14,35]. Endovascular therapy mainly includes use of covered stent grafts, micro-coil embolization, and detachable balloon embolization[36]. Choice of endovascular treatment depends on



DOI: 10.12998/wjcc.v10.i22.8025 Copyright ©The Author(s) 2022.

Figure 3 Follow-up imaging examinations. A: On computed tomography angiography reconstruction, the size of pseudoaneurysm at the origin of the left carotid artery is 4 mm × 3 mm which was significantly smaller than that observed 6 mo ago; B: On digital subtraction angiography, the size of pseudoaneurysm at the origin of the left internal carotid artery is 6 mm × 5 mm, which was smaller than that observed 3 mo ago; C: Cerebral computed tomography shows a large encephalomalacia foci in the left temporal-basal region, which was consistent with the convalescent stage of ischemic stroke.

multiple factors, mainly the site of PSA, age of patient, and intracranial collateral circulation[37]. ICA temporary occlusion test should be performed first for PSAs occurring in the extracranial ICA[38]. If the test is successful, the ICA can be permanently occluded using a detachable balloon. If the test fails, the patient can be treated with covered stent grafts and accessory micro-coil embolization[39]. Our patient failed the ICA temporary occlusion test, which indicated the lack of adequate cerebral collateral circulation. Therefore, we intended to combine endovascular stent placement and coil embolization to treat the PSA; however, the patient opted for conservative management owing to the high cost of treatment and the associated risks. At 6-mo follow-up, the patient was in a relatively good condition and cervical CTA showed significant reduction in the size of PSA. Anticoagulant and antiplatelet agents may decrease mortality related to carotid PSA; however, such conservative management alone is not recommended owing to the risk of delayed rupture of PSA of the carotid artery, which is a life-threatening condition[40]. Out of the 16 cases reviewed, only 3 patients (19%) were conservatively managed. Budincevic *et al*[25] reported an 85-year-old man who died after receiving conservative therapy. However, Xue *et al*[17] reported a 31-year-old woman who showed satisfactory outcome with conservative treatment, which is consistent with our present case. Our patient may have shown better efficacy of conservative treatment owing to the relatively small size of the aneurysm. In addition, previous studies have shown that the choice of endovascular therapy should depend on the etiology of PSAs and that endovascular therapy is not necessary for all types of PSAs[41,42]. Thus, it is important to select appropriate treatment according to the etiology. Our report may provide an alternative therapy for young patients with small carotid PSA, nevertheless, the length of follow-up in our report was relatively short, which is its limitation.

CONCLUSION

We report a young man with clinical presentation of ischemic stroke that was triggered by thrombosis of PSA. The etiology of spontaneous ICA PSA in this case remains unknown. We inferred that the etiology may be related to the characteristics of the patient's occupation. Therefore, history of trauma, infection, and occupational history should be carefully elicited in young patients with acute ischemic stroke who have no history of cardiovascular disease. DSA is the gold standard for the diagnosis of carotid PSA; however, the combination of CEUS and conventional ultrasonography of the carotid artery may facilitate the diagnosis of PSA that is located at a relatively high position. Last but not least, although endovascular therapy is the recommended treatment for carotid PSA, the treatment strategy should be personalized based on the patient characteristics. Conservative therapy may be a viable alternative for young patients with small carotid PSA.

FOOTNOTES

Author contributions: Zhong YL and Feng JP contributed equally to this manuscript; Zhong YL and Feng JP were responsible for collecting the medical history of the patient and drafting the report; Luo H reviewed the literature; Gong XH revised the manuscript; Wei ZH reviewed and edited the manuscript; all authors issued final approval for the version to be submitted.

Supported by Key Disciplines of Shenzhen, No. SZXK052.

Informed consent statement: All study participants, or their legal guardian, provided informed written consent prior to study enrollment.

Conflict-of-interest statement: The authors declare having no conflicts of interest in relation to these cases and their treatment or publication.

CARE Checklist (2016) statement: The authors have read the CARE Checklist (2016), and the manuscript was prepared and revised according to the CARE Checklist (2016).

Open-Access: This article is an open-access article that was selected by an in-house editor and fully peer-reviewed by external reviewers. It is distributed in accordance with the Creative Commons Attribution NonCommercial (CC BY-NC 4.0) license, which permits others to distribute, remix, adapt, build upon this work non-commercially, and license their derivative works on different terms, provided the original work is properly cited and the use is non-commercial. See: <https://creativecommons.org/licenses/by-nc/4.0/>

Country/Territory of origin: China

ORCID number: Yu-Lin Zhong 0000-0003-0860-758X; Jia-Ping Feng 0000-0002-8016-4843; Hui Luo 0000-0002-0325-2620; Xue-Hao Gong 0000-0003-2401-5656; Zhang-Hong Wei 0000-0002-9361-5893.

S-Editor: Yan JP

L-Editor: A

P-Editor: Yan JP

REFERENCES

- Nadig S, Barnwell S, Wax MK. Pseudoaneurysm of the external carotid artery--review of literature. *Head Neck* 2009; **31**: 136-139 [PMID: 18642284 DOI: 10.1002/hed.20855]
- Béjot Y, Daubail B, Debette S, Durier J, Giroud M. Incidence and outcome of cerebrovascular events related to cervical artery dissection: the Dijon Stroke Registry. *Int J Stroke* 2014; **9**: 879-882 [PMID: 24148660 DOI: 10.1111/ijss.12154]
- Mahmoud MZ, Al-Saadi M, Abuderman A, Alzimami KS, Alkhorayef M, Almagli B, Sulieman A. "To-and-fro" waveform in the diagnosis of arterial pseudoaneurysms. *World J Radiol* 2015; **7**: 89-99 [PMID: 26029351 DOI: 10.4329/wjr.v7.i5.89]
- Oweida SW, Roubin GS, Smith RB 3rd, Salam AA. Postcatheterization vascular complications associated with percutaneous transluminal coronary angioplasty. *J Vasc Surg* 1990; **12**: 310-315 [PMID: 2398588 DOI: 10.1016/0741-5214(90)90153-2]
- Cox MW, Whittaker DR, Martinez C, Fox CJ, Feuerstein IM, Gillespie DL. Traumatic pseudoaneurysms of the head and neck: early endovascular intervention. *J Vasc Surg* 2007; **46**: 1227-1233 [PMID: 18154999 DOI: 10.1016/j.jvs.2007.08.021]
- Fankhauser GT, Stone WM, Fowl RJ, O'Donnell ME, Bower TC, Meyer FB, Money SR. Surgical and medical management of extracranial carotid artery aneurysms. *J Vasc Surg* 2015; **61**: 389-393 [PMID: 25151599 DOI: 10.1016/j.jvs.2014.07.092]
- Li Z, Chang G, Yao C, Guo L, Liu Y, Wang M, Liu D, Wang S. Endovascular stenting of extracranial carotid artery aneurysm: a systematic review. *Eur J Vasc Endovasc Surg* 2011; **42**: 419-426 [PMID: 21646029 DOI: 10.1016/j.ejvs.2011.05.008]
- Nomura M, Mori K, Tamase A, Kamide T, Seki S, Iida Y, Nakano T, Kawabata Y, Kitabatake T, Nakajima T, Yasutake K, Egami K, Takahashi T, Takahashi M, Yanagimoto K. Pseudoaneurysm formation due to rupture of intracranial aneurysms: Case series and literature review. *Neuroradiol J* 2017; **30**: 129-137 [PMID: 28059632 DOI: 10.1177/1971400916684667]
- Powers WJ, Rabinstein AA, Ackerson T, Adeoye OM, Bambakidis NC, Becker K, Biller J, Brown M, Demerschalk BM, Hoh B, Jauch EC, Kidwell CS, Leslie-Mazwi TM, Ovbiagele B, Scott PA, Sheth KN, Southerland AM, Summers DV, Tirschwell DL. Guidelines for the Early Management of Patients With Acute Ischemic Stroke: 2019 Update to the 2018 Guidelines for the Early Management of Acute Ischemic Stroke: A Guideline for Healthcare Professionals From the American Heart Association/American Stroke Association. *Stroke* 2019; **50**: e344-e418 [PMID: 31662037 DOI: 10.1161/STR.0000000000000211]
- Hathidara MY, Saini V, Malik AM. Stroke in the Young: a Global Update. *Curr Neurol Neurosci Rep* 2019; **19**: 91 [PMID: 31768660 DOI: 10.1007/s11910-019-1004-1]
- Sun T, Chen S, Wu K, Sun M, Zhang X, You C. Trends in Incidence and Mortality of Stroke in China From 1990 to 2019. *Front Neurol* 2021; **12**: 759221 [PMID: 34880825 DOI: 10.3389/fneur.2021.759221]
- Umana GE, Cristaudo C, Scalia G, Passanisi M, Corsale G, Tomarchio L, Nicoletti G, Cicero S, Fricia M. Chronic Epidural Hematoma Caused by Traumatic Intracranial Pseudoaneurysm of the Middle Meningeal Artery: Review of the Literature with a Focus on this Unique Entity. *World Neurosurg* 2020; **136**: 198-204 [PMID: 31927123 DOI: 10.1016/j.wneu.2019.12.179]
- Aghoutane N, Lyazidi Y, Zoulati M, Bakkali T, Chtata H, Taberkant M. [Spontaneous false aneurysm of the extracranial

- internal carotid artery - during pregnancy]. *J Med Vasc* 2019; **44**: 233-236 [PMID: [31029280](#) DOI: [10.1016/j.jdmv.2019.02.001](#)]
- 14 **Sommer A**, Meairs S, Gueckel F, Cornelius A, Schwartz A. Traumatic brachiocephalic pseudoaneurysm presenting with delayed stroke: case report. *Neuroradiology* 2000; **42**: 742-745 [PMID: [11110077](#) DOI: [10.1007/s002340000365](#)]
 - 15 **Wasay M**, Dai A, Dubey N, Kamran S. Acute stroke secondary to internal carotid artery pseudoaneurysm: MRI findings and treatment with endovascular coiling. *J Pak Med Assoc* 2007; **57**: 377-378 [PMID: [17867266](#)]
 - 16 **Zeleňák K**, Zeleňáková J, DeRiggo J, Kurča E, Kantorová E, Poláček H. Treatment of cervical internal carotid artery spontaneous dissection with pseudoaneurysm and unilateral lower cranial nerves palsy by two silk flow diverters. *Cardiovasc Intervent Radiol* 2013; **36**: 1147-1150 [PMID: [23070099](#) DOI: [10.1007/s00270-012-0472-3](#)]
 - 17 **Xue S**, Shi H, Du X, Ma X. Bow Hunter's syndrome combined with ipsilateral vertebral artery dissection/pseudoaneurysm: case study and literature review. *Br J Neurosurg* 2020; 1-5 [PMID: [32009470](#) DOI: [10.1080/02688697.2020.1718604](#)]
 - 18 **Chavan R**, Ichaporia N, Vhora S, Aurangabadkar K, Kamekar D, Hardas S, Ratta BS. Endovascular management of internal carotid artery pseudoaneurysms: Retrospective observational study. *Interdiscip Neurosurg* 2021; **24** [DOI: [10.1016/j.inat.2020.101042](#)]
 - 19 **Bogaerde MV**, Viaene P, Thijs V. Iatrogenic perforation of the internal carotid artery by a transarticular screw: an unusual case of repetitive ischemic stroke. *Clin Neurol Neurosurg* 2007; **109**: 466-469 [PMID: [17383088](#) DOI: [10.1016/j.clineuro.2007.02.008](#)]
 - 20 **Helou E**, Sweid A, Tjoumakaris S, Herial N, Gooch MR, Rosenwasser RH, Jabbour P. Case Report of De Novo Cavernous Carotid Artery Aneurysm After an Acute Stroke Intervention for a Carotid Occlusion. *World Neurosurg* 2019; **128**: 336-339 [PMID: [31121371](#) DOI: [10.1016/j.wneu.2019.05.097](#)]
 - 21 **Jeon SH**, Kang HG, Kim HJ, Seo MW, Shin BS. Femoral artery pseudoaneurysm after carotid artery stenting: Two case reports. *Medicine (Baltimore)* 2019; **98**: e15309 [PMID: [31027097](#) DOI: [10.1097/MD.00000000000015309](#)]
 - 22 **Béres-Molnár KA**, Szabó PT, Al-Muhanna N. Drug addiction. repetitive injections into carotid arteries. a rare case of stroke in young adults. *Eur Stroke J* 2019; **4**: 591 [DOI: [10.1177/2396987319845581](#)]
 - 23 **Budinčević H**, Milošević M, Pavlović T. Giant pseudoaneurysm of the external carotid artery causing stroke: A case report. *J Clin Ultrasound* 2018; **46**: 269-272 [PMID: [28940564](#) DOI: [10.1002/jcu.22524](#)]
 - 24 **Hoque R**, Gonzalez-Toledo E, Minagar A, Kelley RE. Circuitous embolic hemorrhagic stroke: carotid pseudoaneurysm to fetal posterior cerebral artery conduit: a case report. *J Med Case Rep* 2008; **2**: 61 [PMID: [18298860](#) DOI: [10.1186/1752-1947-2-61](#)]
 - 25 **Budinčević H**, Piršić A, Bohm T, Trajbar T, Ivkošić A, Pavlović T, Bielen I, Soldo-Butković S. Carotid Body Tumor as a Cause of Stroke. *Intern Med* 2016; **55**: 295-298 [PMID: [26831027](#) DOI: [10.2169/internalmedicine.55.5350](#)]
 - 26 **Grigorian A**, Kabutay NK, Schubl S, de Virgilio C, Joe V, Dolich M, Elfenbein D, Nahmias J. Blunt cerebrovascular injury incidence, stroke-rate, and mortality with the expanded Denver criteria. *Surgery* 2018; **164**: 494-499 [PMID: [29884478](#) DOI: [10.1016/j.surg.2018.04.032](#)]
 - 27 **Henry JC**, Franz RW. Pseudoaneurysms of the Peripheral Arteries. *Int J Angiol* 2019; **28**: 20-24 [PMID: [30880887](#) DOI: [10.1055/s-0039-1677676](#)]
 - 28 **Abu-Yousef MM**, Wiese JA, Shamma AR. The "to-and-fro" sign: duplex Doppler evidence of femoral artery pseudoaneurysm. *AJR Am J Roentgenol* 1988; **150**: 632-634 [PMID: [3277354](#) DOI: [10.2214/ajr.150.3.632](#)]
 - 29 **Güner A**, Pala S, Gündüz S, Külahcıoğlu Ş, Güner EG. Pseudoaneurysm after carotid stenting: A case report and review of the literature. *Türk Kardiyol Dern Ars* 2020; **48**: 613-618 [PMID: [32955027](#) DOI: [10.5543/tkda.2020.34609](#)]
 - 30 **Ogura T**, Mineharu Y, Todo K, Kohara N, Sakai N. Carotid Artery Dissection Caused by an Elongated Styloid Process: Three Case Reports and Review of the Literature. *NMC Case Rep J* 2015; **2**: 21-25 [PMID: [28663957](#) DOI: [10.2176/nmccrj.2014-0179](#)]
 - 31 **Rathlev NK**. Penetrating neck trauma: mandatory versus selective exploration. *J Emerg Med* 1990; **8**: 75-78 [PMID: [2191031](#) DOI: [10.1016/0736-4679\(90\)90392-9](#)]
 - 32 **Song Y**, Fu MY, Chen Y, Chen GP, Pan Z. [Clinical characteristics of patients with cervical vascular pseudoaneurysm after radiotherapy for nasopharyngeal carcinoma]. *Lin Chung Er Bi Yan Hou Tou Jing Wai Ke Za Zhi* 2019; **33**: 746-748 [PMID: [31446731](#) DOI: [10.13201/j.issn.1001-1781.2019.08.015](#)]
 - 33 **Chen WL**, Xu LF, Tang QL, Zhang DM. Management of carotid body tumor and pseudoaneurysm after blunt dissection. *J Craniofac Surg* 2015; **26**: 477-480 [PMID: [25692893](#) DOI: [10.1097/SCS.0000000000001466](#)]
 - 34 **DuBose J**, Recinos G, Teixeira PG, Inaba K, Demetriades D. Endovascular stenting for the treatment of traumatic internal carotid injuries: expanding experience. *J Trauma* 2008; **65**: 1561-1566 [PMID: [19077655](#) DOI: [10.1097/TA.0b013e31817fd954](#)]
 - 35 **Kaushal S**, Shake JG, Yuh DD. Mycotic innominate artery pseudoaneurysm presenting as an embolic stroke. *J Thorac Cardiovasc Surg* 2005; **129**: 945-946 [PMID: [15821672](#) DOI: [10.1016/j.jtcvs.2004.08.018](#)]
 - 36 **Rallo MS**, Narayan V, Majmundar N, Al-Mufti F, Sun H, Jumah F, Raju B, Roychowdhury S, Nanda A, Gupta G. Multi-modal endovascular management of traumatic pseudoaneurysm and arteriovenous fistula of the ascending cervical artery: A technical report and review of literature. *Clin Neurol Neurosurg* 2021; **202**: 106539 [PMID: [33601270](#) DOI: [10.1016/j.clineuro.2021.106539](#)]
 - 37 **Kumar A**, Prabhakar A, Gupta V, Khandelwal N, Ahuja CK, Singhal M, Vyas S, Panda NK, Vaidhya PC. Endovascular management of internal carotid artery pseudoaneurysms: A single-centre experience of 20 patients. *Neurol India* 2018; **66**: 1067-1074 [PMID: [30038096](#) DOI: [10.4103/0028-3886.236958](#)]
 - 38 **Phogat V**, Gandhi A, Srivastava T, Mishva K. Endovascular management of intracranial pseudoaneurysm: an institutional experience. *J Cerebrovasc Endovasc Neurosurg* 2020; **22**: 211-215 [PMID: [33207401](#) DOI: [10.7461/jcen.2020.E2019.11.001](#)]
 - 39 **Zhong J**, Islim F, Sundararajan S, Tahir N, Goddard T, Patel J. Endovascular Treatment of a Giant Extracranial Carotid Artery Pseudoaneurysm in a Child Using Vascular Plugs. *Ear Nose Throat J* 2020; **99**: NP119-NP121 [PMID: [31288533](#) DOI: [10.1177/0145561319859308](#)]
 - 40 **Nariai Y**, Kawamura Y, Takigawa T, Hyodo A, Suzuki K. Pipeline embolization for an iatrogenic intracranial internal

- carotid artery pseudoaneurysm after transsphenoidal pituitary tumor surgery: Case report and review of the literature. *Interv Neuroradiol* 2020; **26**: 74-82 [PMID: [31505983](#) DOI: [10.1177/1591019919874943](#)]
- 41 **Marnat G**, Lapergue B, Sibon I, Gariel F, Bourcier R, Kyheng M, Labreuche J, Dargazanli C, Consoli A, Blanc R, Piotin M, Mazighi M, Richard S, Gory B; TITAN and ETIS Investigators*. Safety and Outcome of Carotid Dissection Stenting During the Treatment of Tandem Occlusions: A Pooled Analysis of TITAN and ETIS. *Stroke* 2020; **51**: 3713-3718 [PMID: [33167809](#) DOI: [10.1161/STROKEAHA.120.030038](#)]
 - 42 **Da Ros V**, Scaggiante J, Pitocchi F, Sallustio F, Lattanzi S, Umana GE, Chaurasia B, Bandettini di Poggio M, Toscano G, Rolla Bigliani C, Ruggiero M, Haznedari N, Sgreccia A, Sanfilippo G, Diomedes M, Finocchi C, Floris R. Mechanical thrombectomy in acute ischemic stroke with tandem occlusions: impact of extracranial carotid lesion etiology on endovascular management and outcome. *Neurosurg Focus* 2021; **51**: E6 [PMID: [34198245](#) DOI: [10.3171/2021.4.FOCUS21111](#)]
 - 43 **Hsiao CL**, Tsai YH, Lin SK. Massive Epistaxis from Internal Carotid Pseudoaneurysm during Acute Ischemic Stroke in a Patient with Nasopharyngeal Carcinoma. *Acta Neurol Taiwan* 2014; **23**: 113-118 [PMID: [26077184](#)]
 - 44 **Ruff MW**, Nasr DM, Klaas JP, Renaud DL. Internal Carotid Artery Pseudoaneurysm and Ischemic Stroke Secondary to Retropharyngeal and Parapharyngeal Abscess. *J Child Neurol* 2017; **32**: 230-236 [PMID: [27888269](#) DOI: [10.1177/0883073816678556](#)]
 - 45 **Kronlage C**, Lorscheider J, Wagner B, Lyrer P, Peters N. Case-report: Recurrent embolic stroke from non-traumatic pseudoaneurysm of the extracranial internal carotid artery in a 60-year old woman. *Eur Stroke J* 2019; **4**: 214
 - 46 **Rigual R**, Ruiz-Ares G, Rodriguez-Pardo J, Fernández-Prieto A, Navia P, Novo JR, Alonso de Leciñana M, Alonso-Singer P, Fuentes B, Díez-Tejedor E. Concurrent Cerebral, Splenic, and Renal Infarction in a Patient With COVID-19 Infection. *Neurologist* 2022; **27**: 143-146 [PMID: [34855656](#) DOI: [10.1097/NRL.0000000000000403](#)]



Published by **Baishideng Publishing Group Inc**
7041 Koll Center Parkway, Suite 160, Pleasanton, CA 94566, USA

Telephone: +1-925-3991568

E-mail: bpgoffice@wjgnet.com

Help Desk: <https://www.f6publishing.com/helpdesk>

<https://www.wjgnet.com>

