

World Journal of *Clinical Cases*

World J Clin Cases 2022 July 26; 10(21): 7187-7619



Contents

Thrice Monthly Volume 10 Number 21 July 26, 2022

OPINION REVIEW

- 7187 Effects of glucocorticoids on leukocytes: Genomic and non-genomic mechanisms
Jia WY, Zhang JJ

MINIREVIEWS

- 7195 Apheresis: A cell-based therapeutic tool for the inflammatory bowel disease
Yasmin F, Najeeb H, Naeem U, Moeed A, Koritala T, Surani S
- 7209 *Helicobacter pylori* infection and small intestinal bacterial overgrowth—more than what meets the eye
Dharan M, Wozny D
- 7215 Anatomy of the anterolateral ligament of the knee joint
Park JG, Han SB, Rhim HC, Jeon OH, Jang KM

ORIGINAL ARTICLE

Clinical and Translational Research

- 7224 Molecular mechanisms of Biyu decoction as treatment for psoriasis: A network pharmacology and molecular docking study
Wang Z, Zhang HM, Guo YR, Li LL
- 7242 Expression of hepatocyte nuclear factor 4 alpha, wingless-related integration site, and β -catenin in clinical gastric cancer
Hu Q, Li LL, Peng Z, Yi P

Case Control Study

- 7256 Improved Pittsburgh Sleep Quality Index scores on first postoperative night achieved by propofol anesthesia in patients undergoing ambulatory gynecologic surgery
Hu CH, Chou WY
- 7265 Efficacy of Guhong injection *versus* Butylphthalide injection for mild ischemic stroke: A multicenter controlled study
Zhang WW, Xin J, Zhang GY, Zhai QJ, Zhang HM, Wu CS

Retrospective Study

- 7275 Clinical values of Barcelona Clinic Liver Cancer subgroup and up-to-7 criteria in intermediate stage hepatocellular carcinoma with transcatheter arterial chemoembolization
Lee SW, Peng YC, Lien HC, Ko CW, Tung CF, Chang CS
- 7285 Intervention effect of encouraging mental and programmed nursing of patients in interventional operating room on their compliance and bad moods
Chi RB, Cai YY, Mao HP

- 7293** Preoperative neoadjuvant chemotherapy in patients with breast cancer evaluated using strain ultrasonic elastography
Pan HY, Zhang Q, Wu WJ, Li X
- 7302** Risk factors for delayed intracranial hemorrhage secondary to ventriculoperitoneal shunt: A retrospective study
Chen JC, Duan SX, Xue ZB, Yang SY, Li Y, Lai RL, Tan DH
- 7314** Sequential treatment of severe pneumonia with respiratory failure and its influence on respiratory mechanical parameters and hemodynamics
Niu BY, Wang G, Li B, Zhen GS, Weng YB
- 7324** Effects of alendronate sodium combined with InterTan on osteoporotic femoral intertrochanteric fractures and fracture recurrence
Wang KM, Wei SP, Yin XY, Meng QJ, Kong YM
- 7333** Correlation of magnetic resonance imaging quantitative parameters and apparent diffusion coefficient value with pathological breast cancer
Wang Z, Ren GY, Yin Q, Wang Q
- 7341** Risk factors for delirium after surgery for craniocerebral injury in the neurosurgical intensive care unit
Chen RY, Zhong CH, Chen W, Lin M, Feng CF, Chen CN

Observational Study

- 7348** Effect of osteoarthritic knee flexion deformity correction by total knee arthroplasty on sagittal spinopelvic alignment in Indian population
Puthiyapura LK, Jain M, Tripathy SK, Puliappadamb HM
- 7356** Imaging characteristics of orbital peripheral nerve sheath tumors: Analysis of 34 cases
Dai M, Wang T, Wang JM, Fang LP, Zhao Y, Thakur A, Wang D

Randomized Controlled Trial

- 7365** Comparison of involved-field intensity-modulated radiotherapy combined with S-1 *vs* radiotherapy alone for elderly patients with esophageal cancer
Liu LH, Yan MH, Di YP, Fu ZG, Zhang XD, Li HQ

Randomized Clinical Trial

- 7376** Dexmedetomidine in pediatric unilateral internal inguinal ring ligation
Liu G, Zhang L, Wang HS, Lin Y, Jin HQ, Wang XD, Qiao WN, Zhang YT, Sun JQ, Liu ZN

META-ANALYSIS

- 7386** Impact of cancer on mortality rates in patients with sepsis: A meta-analysis and meta-regression of current studies
Xiang MJ, Chen GL

CASE REPORT

- 7397 Updated clinical and glycomic features of mannosyl-oligosaccharide glucosidase deficiency: Two case reports
Abuduxikuer K, Wang L, Zou L, Cao CY, Yu L, Guo HM, Liang XM, Wang JS, Chen L
- 7409 Solitary necrotic nodules of the liver with "ring"-like calcification: A case report
Bao JP, Tian H, Wang HC, Wang CC, Li B
- 7415 Corticosteroid-induced bradycardia in multiple sclerosis and maturity-onset diabetes of the young due to hepatocyte nuclear factor 4-alpha mutation: A case report
Sohn SY, Kim SY, Joo IS
- 7422 Essential thrombocythemia with non-ST-segment elevation myocardial infarction as the first manifestation: A case report
Wang ZM, Chen WH, Wu YM, Wang LQ, Ye FL, Yin RL
- 7429 Extranasopharyngeal angiofibroma in children: A case report
Yan YY, Lai C, Wu L, Fu Y
- 7438 Deep Sylvian fissure meningiomas: A case report
Wang A, Zhang X, Sun KK, Li C, Song ZM, Sun T, Wang F
- 7445 Acute pulmonary embolism originating from upper limb venous thrombosis following breast cancer surgery: Two case reports
Duan Y, Wang GL, Guo X, Yang LL, Tian FG
- 7451 Managing spondylitis tuberculosis in a patient with underlying diabetes and hypothyroidism: A case report
Novita BD, Muliono AC, Wijaya S, Theodora I, Tjahjono Y, Supit VD, Willianto VM
- 7459 Ovarian mucinous tumor with mural nodules of anaplastic carcinoma: Three case reports
Wang XJ, Wang CY, Xi YF, Bu P, Wang P
- 7467 Transcatheter arterial infusion chemotherapy and embolization for primary lacrimal sac squamous cell carcinoma: A case report
Sun MH, Yi WD, Shen L, Zhou L, Lu JX
- 7474 Programmed cell death-1 inhibitor combination treatment for recurrent proficient mismatch repair/microsatellite-stable type endometrial cancer: A case report
Zhai CY, Yin LX, Han WD
- 7483 Novel compound heterozygous mutation of *SLC12A3* in Gitelman syndrome co-existent with hyperthyroidism: A case report and literature review
Qin YZ, Liu YM, Wang Y, You C, Li LN, Zhou XY, Lv WM, Hong SH, Xiao LX
- 7495 Successful treatment of hyperglycemia with liraglutide in a hospitalized 27-year-old patient with schizophrenia: A case report
Zhang L, Yu WJ, Zhu H, Li HF, Qiao J

- 7502** Refractory lymphoma treated with chimeric antigen receptor T cells combined with programmed cell death-1 inhibitor: A case report
Zhang CJ, Zhang JY, Li LJ, Xu NW
- 7509** Median arcuate ligament syndrome with retroperitoneal haemorrhage: A case report
Lu XC, Pei JG, Xie GH, Li YY, Han HM
- 7517** Novel frameshift mutation in the *AHDC1* gene in a Chinese global developmental delay patient: A case report
Lin SZ, Xie HY, Qu YL, Gao W, Wang WQ, Li JY, Feng XC, Jin CQ
- 7523** Selective nerve block for the treatment of neuralgia in Kummell's disease: A case report
Zhang X, Li ZX, Yin LJ, Chen H
- 7531** Traditional Chinese medicine manipulative reduction combined with percutaneous vertebroplasty for treating type III Kummell's disease: A case report
Hao SS, Zhang RJ, Dong SL, Li HK, Liu S, Li RF, Ren HH, Zhang LY
- 7539** Differential diagnosis and treatment of foot drop caused by an extraneural ganglion cyst above the knee: A case report
Won KH, Kang EY
- 7545** Effect of hydrogen intervention on refractory wounds after radiotherapy: A case report
Zhao PX, Luo RL, Dang Z, Wang YB, Zhang XJ, Liu ZY, Wen XH, Liu MY, Zhang MZ, Adzavon YM, Ma XM
- 7553** Chronic urticaria associated with lung adenocarcinoma — a paraneoplastic manifestation: A case report and literature review
Jiménez LF, Castellón EA, Marengo JD, Mejía JM, Rojas CA, Jiménez FT, Coronell L, Osorio-Llanes E, Mendoza-Torres E
- 7565** Spinal giant cell-rich osteosarcoma-diagnostic dilemma and treatment strategy: A case report
Tseng CS, Wong CE, Huang CC, Hsu HH, Lee JS, Lee PH
- 7571** Primary clear cell sarcoma of soft tissue in the posterior cervical spine invading the medulla oblongata: A case report
Liu CC, Huang WP, Gao JB
- 7577** *Pseudomonas aeruginosa*-related effusive-constrictive pericarditis diagnosed with echocardiography: A case report
Chen JL, Mei DE, Yu CG, Zhao ZY
- 7585** Maternal peripartum bacteremia caused by intrauterine infection with *Comamonas kerstersii*: A case report
Qu H, Zhao YH, Zhu WM, Liu L, Zhu M
- 7592** Considerations of single-lung ventilation in neonatal thoracoscopic surgery with cardiac arrest caused by bilateral pneumothorax: A case report
Zhang X, Song HC, Wang KL, Ren YY

- 7599** Rare primary rectal mucosa-associated lymphoid tissue lymphoma with curative resection by endoscopic submucosal dissection: A case report and review of literature

Tao Y, Nan Q, Lei Z, Miao YL, Niu JK

- 7609** Differences in examination results of small anastomotic fistula after radical gastrectomy with afterward treatments: A case report

Lu CY, Liu YL, Liu KJ, Xu S, Yao HL, Li L, Guo ZS

LETTER TO THE EDITOR

- 7617** Baseline differences may impact on relationship between dietary tryptophan and risk of obesity and type 2 diabetes

Ren XH, Ye YW, He LP

ABOUT COVER

Editorial Board Member of *World Journal of Clinical Cases*, Rajesh Kumar Rajnish, MBBS, MS, Assistant Professor, Department of Orthopaedics, All India Institute of Medical Sciences, Bilaspur, Bilaspur 174001, Himachal Pradesh, India. duktiraj@gmail.com

AIMS AND SCOPE

The primary aim of *World Journal of Clinical Cases* (WJCC, *World J Clin Cases*) is to provide scholars and readers from various fields of clinical medicine with a platform to publish high-quality clinical research articles and communicate their research findings online.

WJCC mainly publishes articles reporting research results and findings obtained in the field of clinical medicine and covering a wide range of topics, including case control studies, retrospective cohort studies, retrospective studies, clinical trials studies, observational studies, prospective studies, randomized controlled trials, randomized clinical trials, systematic reviews, meta-analysis, and case reports.

INDEXING/ABSTRACTING

The WJCC is now abstracted and indexed in Science Citation Index Expanded (SCIE, also known as SciSearch®), Journal Citation Reports/Science Edition, Current Contents®/Clinical Medicine, PubMed, PubMed Central, Scopus, Reference Citation Analysis, China National Knowledge Infrastructure, China Science and Technology Journal Database, and Superstar Journals Database. The 2022 Edition of Journal Citation Reports® cites the 2021 impact factor (IF) for WJCC as 1.534; IF without journal self cites: 1.491; 5-year IF: 1.599; Journal Citation Indicator: 0.28; Ranking: 135 among 172 journals in medicine, general and internal; and Quartile category: Q4. The WJCC's CiteScore for 2021 is 1.2 and Scopus CiteScore rank 2021: General Medicine is 443/826.

RESPONSIBLE EDITORS FOR THIS ISSUE

Production Editor: *Ying-Yi Yuan*; Production Department Director: *Xiang Li*; Editorial Office Director: *Jin-Lei Wang*.

NAME OF JOURNAL

World Journal of Clinical Cases

ISSN

ISSN 2307-8960 (online)

LAUNCH DATE

April 16, 2013

FREQUENCY

Thrice Monthly

EDITORS-IN-CHIEF

Bao-Gan Peng, Jerzy Tadeusz Chudek, George Kontogeorgos, Maurizio Serati, Ja Hyeon Ku

EDITORIAL BOARD MEMBERS

<https://www.wjnet.com/2307-8960/editorialboard.htm>

PUBLICATION DATE

July 26, 2022

COPYRIGHT

© 2022 Baishideng Publishing Group Inc

INSTRUCTIONS TO AUTHORS

<https://www.wjnet.com/bpg/gerinfo/204>

GUIDELINES FOR ETHICS DOCUMENTS

<https://www.wjnet.com/bpg/GerInfo/287>

GUIDELINES FOR NON-NATIVE SPEAKERS OF ENGLISH

<https://www.wjnet.com/bpg/gerinfo/240>

PUBLICATION ETHICS

<https://www.wjnet.com/bpg/GerInfo/288>

PUBLICATION MISCONDUCT

<https://www.wjnet.com/bpg/gerinfo/208>

ARTICLE PROCESSING CHARGE

<https://www.wjnet.com/bpg/gerinfo/242>

STEPS FOR SUBMITTING MANUSCRIPTS

<https://www.wjnet.com/bpg/GerInfo/239>

ONLINE SUBMISSION

<https://www.f6publishing.com>

Differences in examination results of small anastomotic fistula after radical gastrectomy with afterward treatments: A case report

Chen-Yang Lu, Ya-Li Liu, Kui-Jie Liu, Shu Xu, Hong-Liang Yao, Lun Li, Zhu-Shu Guo

Specialty type: Surgery

Provenance and peer review:

Unsolicited article; Externally peer reviewed.

Peer-review model: Single blind

Peer-review report's scientific quality classification

Grade A (Excellent): A

Grade B (Very good): 0

Grade C (Good): 0

Grade D (Fair): D

Grade E (Poor): 0

P-Reviewer: Moshref L, Saudi Arabia; Tsoulfas G, Greece

Received: March 17, 2022

Peer-review started: March 17, 2022

First decision: May 9, 2022

Revised: May 18, 2022

Accepted: June 15, 2022

Article in press: June 15, 2022

Published online: July 26, 2022



Chen-Yang Lu, Department of Pulmonary and Critical Care Medicine, The Second Xiangya Hospital of Central South University, Central South University, Changsha 410011, Hunan Province, China

Ya-Li Liu, Kui-Jie Liu, Shu Xu, Hong-Liang Yao, Lun Li, Zhu-Shu Guo, Department of General Surgery, The Second Xiangya Hospital of Central South University, Central South University, Changsha 410011, Hunan Province, China

Ya-Li Liu, Zhu-Shu Guo, Clinical Nursing Teaching and Research Section, The Second Xiangya Hospital of Central South University, Central South University, Changsha 410011, Hunan Province, China

Corresponding author: Zhu-Shu Guo, MNurs, Chief Nurse, Clinical Nursing Teaching and Research Section, The Second Xiangya Hospital of Central South University, Central South University, No. 139 Renmin Middle Road, Furong District, Changsha 410011, Hunan Province, China. guozhushu@csu.edu.cn

Abstract

BACKGROUND

Gastrografin swallow, methylthioninium chloride test, and computed tomography (CT) are the main methods for postoperative anastomotic fistula detection. Correct selection and application of examinations and therapies are significant for the early diagnosis and treatment of small anastomotic fistulas after radical gastrectomy, which are conducive to postoperative recovery.

CASE SUMMARY

A 44-year-old woman underwent radical total gastrectomy for laparoscopic gastric cancer. The patient developed a fever after surgery. The methylthioninium chloride test and early CT suggested no anastomotic fistula, but gastrografin swallow and late CT showed the opposite result. The fistula was successfully closed using an endoscopic clip. The methylthioninium chloride test, gastrografin, and CT performed on different postoperative dates for small esophagojejunostomy fistulas are different. The size of the anastomotic fistula is an important factor for the success of endoscopic treatment.

CONCLUSION

The advantages and limitations of the diagnosis of different examinations of small esophagojejunostomy fistulas are noteworthy. The size of the leakage of the anastomosis is an important basis for selecting the repair method.

Key Words: Laparoscopic; Gastrectomy; Anastomotic leak; Methylthioninium chloride; Gastrografin; Esophagojejunal anastomotic fistula; Case report

©The Author(s) 2022. Published by Baishideng Publishing Group Inc. All rights reserved.

Core Tip: Gastrointestinal anastomotic fistula is one of the major complications after gastrointestinal anastomosis. The early diagnosis of small anastomotic fistulas and the choice of treatment are particularly important. We reported a case of a gastrointestinal anastomotic fistula that was not easily diagnosed at an early stage and discussed the advantages and limitations of the current main methods of examination in the context of medical imaging. In addition, we discussed the appropriate treatment for different anastomotic fistulas.

Citation: Lu CY, Liu YL, Liu KJ, Xu S, Yao HL, Li L, Guo ZS. Differences in examination results of small anastomotic fistula after radical gastrectomy with afterward treatments: A case report. *World J Clin Cases* 2022; 10(21): 7609-7616

URL: <https://www.wjgnet.com/2307-8960/full/v10/i21/7609.htm>

DOI: <https://dx.doi.org/10.12998/wjcc.v10.i21.7609>

INTRODUCTION

Esophagojejunal anastomotic fistula (EJF) is a major complication of radical gastrectomy. Mediastinal and lung infections are often seen in patients with EJF, which seriously endanger the health of patients [1]. The reported rates of the EJF after radical gastrectomy vary from 0% to 5.8%, with 0% to 5.8% after laparoscopic, 0% to 3.4% after robotic surgery, and 0% to 5.8% after open surgery [2-6]. The mortality rate was 26.32% [7]. Gastrografin swallow, methylthioninium chloride test, and computed tomography (CT) are currently the main means of postoperative anastomotic fistula detection at present. The treatment of anastomotic fistula mainly includes endoscopic clamping, stent placement, tissue sealant filling, and surgical re-operation if necessary [8]. Correct selection and application of examinations and therapies are significant for the early diagnosis and treatment of small anastomotic fistulas after radical gastrectomy, which are conducive to postoperative recovery.

Based on the diagnosis and treatment process of a patient with anastomotic fistula after radical gastrectomy for gastric cancer, we discuss the main diagnosis and treatment methods of anastomotic fistulas in depth, which is conducive to the timely diagnosis and accurate treatment of postoperative anastomotic fistula.

CASE PRESENTATION

Chief complaints

A 44-year-old woman presented to the Department of Gastrointestinal Surgery of our hospital complaining of upper epigastric pain.

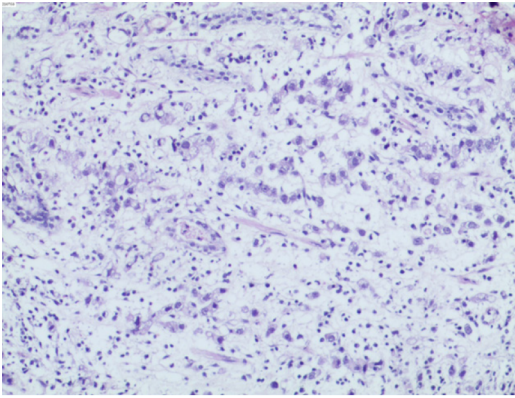
History of present illness

Patient's symptoms started 2 months ago, usually between meals. Acid burps or acid belching can occasionally occur. Antacids usually resolve her symptoms. Gastroscopy and biopsy were performed 10 days ago, and gastroscopy revealed a stage A1 gastric ulcer with bleeding. In addition, biopsy showed abnormal cell proliferation and infiltration between the inherent glands of the gastric mucosa, which indicated a poorly differentiated adenocarcinoma (Figure 1). A contrast-enhanced abdomen CT scan showed local thickening of the gastric wall along the greater curvature of the gastric body, enlarged small lymph nodes around the stomach, and multiple enlarged lymph nodes enlarged in the mesentery.

The patient underwent laparoscopic radical gastrectomy (total gastrectomy Roux-en-Y anastomotic regional lymph node dissection) + jejunostomy + cholecystectomy + splenic hilar lymph node dissection. Side-to-side anastomosis between the oesophagus and jejunum was performed. She developed a persistent fever after surgery, which meant she started having a fever on t postoperative day 1 and was unable to reduce it to a normal temperature on her own.

History of past illness

The patient had a free previous medical history.



DOI: 10.12998/wjcc.v10.i21.7609 Copyright ©The Author(s) 2022.

Figure 1 Biopsy of the gastric body.

Personal and family history

The patient had no personal or family history related to gastric cancer and anastomotic fistula.

Physical examination

Physical examination revealed mild tenderness in the upper abdomen without rebound pain. She developed a persistent fever after surgery, which cannot be completely cured by physical cooling and the use of antibiotics (Figure 2).

Laboratory examinations

A severe leukocytosis $25.69 \times 10^9/L$ appeared on postoperative day 1, with predominant neutrophils (90.20%), which indicated a possible bacterial infection. A similar situation persisted until postoperative day 4, which was the third day after Cefoperazone Sodium and Sulbactam Sodium was given to the patient. Since then, blood analysis has consistently revealed a mild leukocytosis. Ciprofloxacin was applied on postoperative day 15, after which the infection indicators dropped to normal.

Imaging examinations

On postoperative day 4, CT showed dilatation of the esophagus, duodenum, and jejunum with effusion. A small amount of ascites was found around the spleen, and pleural effusion was observed. On postoperative day 6, after the patient received oral methylthioninium chloride, there was no blue fluid draining from the tube. The CT and oral methylthioninium chloride results suggest that the anastomosis appears to be well closed (Figure 3A). However, despite the use of various anti-inflammatory treatments over the following few days, the patient's symptoms were not relieved. Therefore, CT was performed again on the postoperative day 13, and showed that the anastomotic site at the lower end of the oesophagus was thickened and blurred, and the right parastinastinal cystoid air cavity was connected to the anastomotic site (Figure 3B).

Further diagnostic work-up

Gastrografin swallow on postoperative day 13 was used to confirm the diagnosis of anastomotic fistula (Figure 4A).

Microbiological identification of the causative agent

Sputum culture was performed on postoperative day 9. The *Ralstonia mannitolilytica* infection was reported on postoperative day 14, which was sensitive for Ciprofloxacin.

FINAL DIAGNOSIS

The possibility of anastomotic fistula was highly considered.

TREATMENT

After ciprofloxacin had controlled the infection, endoscopic metal clip therapy was performed on postoperative day 23 to clamp the anastomotic fistula. And meglumine diatrizoate esophagogram showed no anastomotic fistula (Figure 4B).

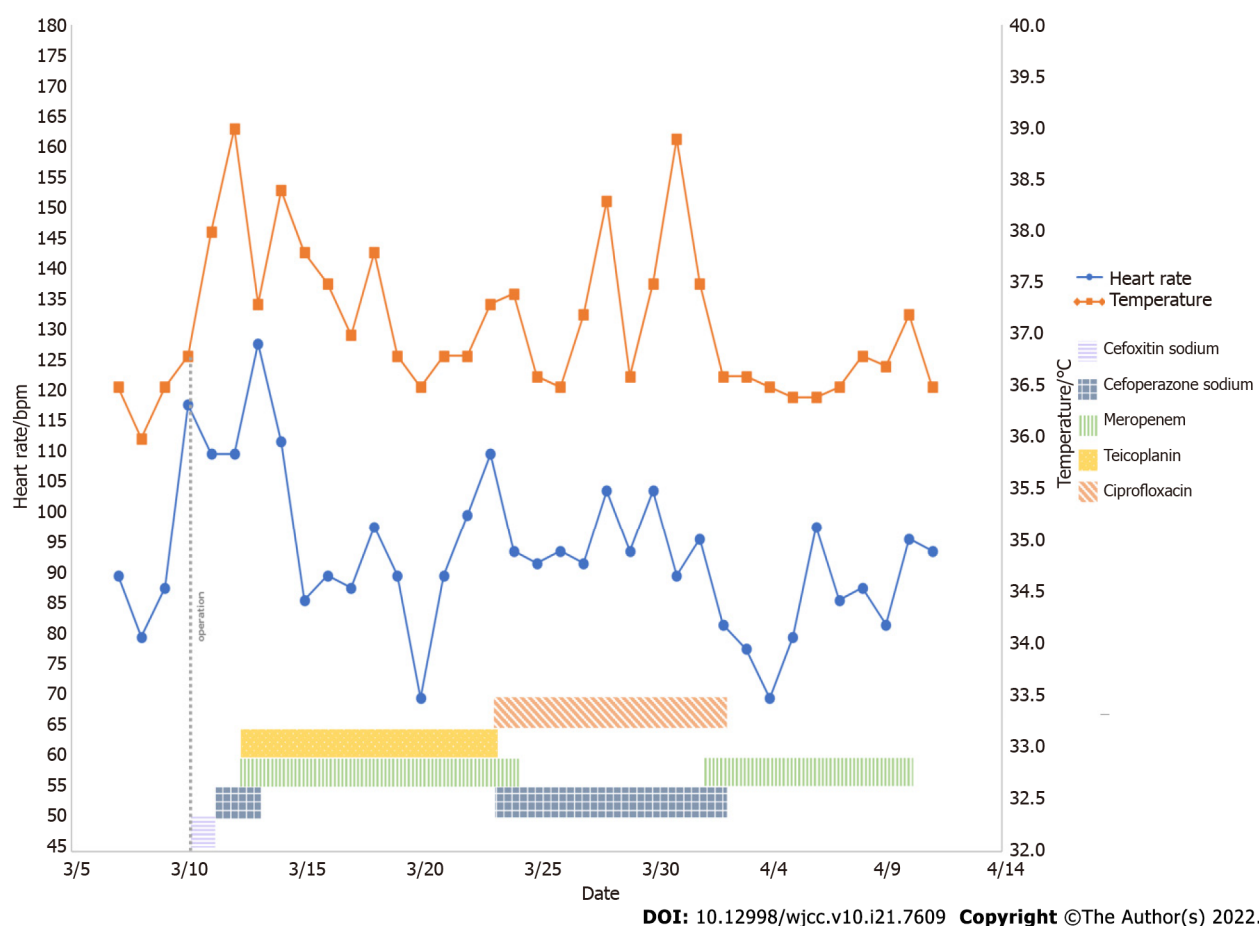


Figure 2 Basic information of the patients and the application of antibiotics during treatment. bpm, beats per minutes.

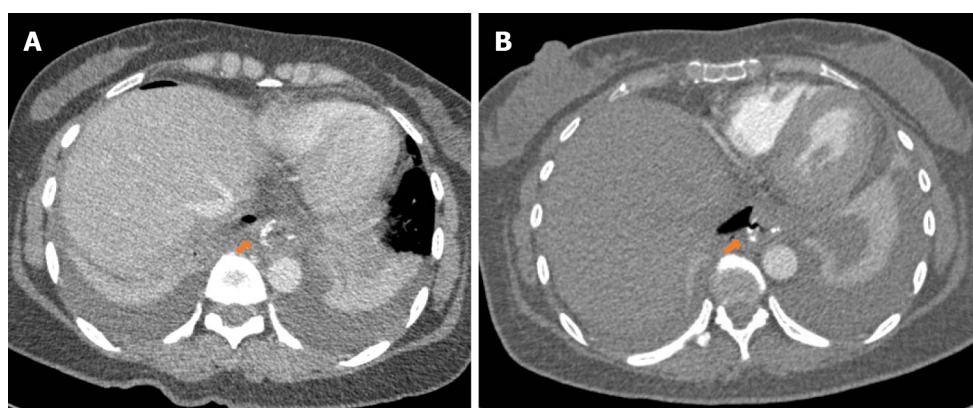
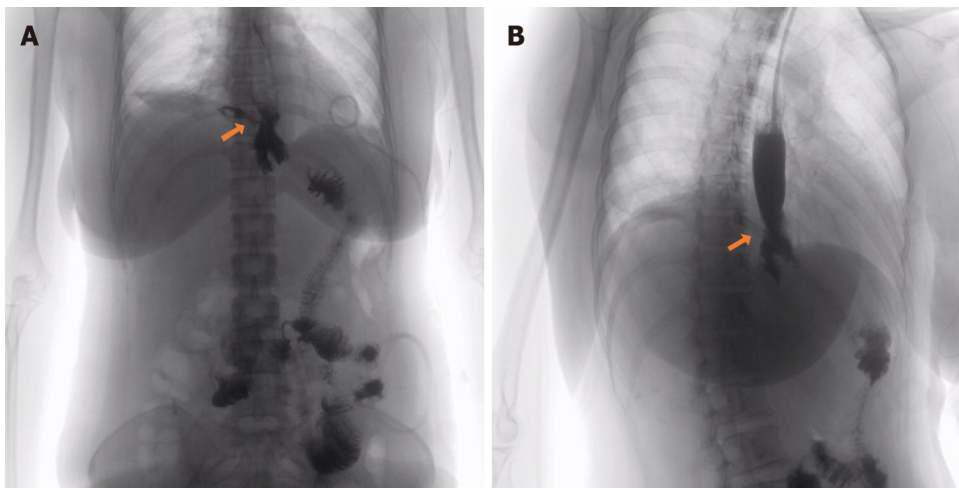


Figure 3 Postoperative anastomosis computed tomography image. A: Computed tomography (CT) on postoperative day 6 showed changes consistent with postoperative gastrointestinal tract. The red arrow showed the position of the anastomosis; B: CT on postoperative day 13 showed anastomosis at the lower end of the esophagus. Red arrow showed the cystic air-containing cavity in the right mediastinum appears to be connected to the anastomosis and the possibility of an anastomotic fistula is considered.

OUTCOME AND FOLLOW-UP

After the application of antibiotics and clamping of the anastomotic fistula, the infection of the patient was gradually controlled on the postoperative day 24. Since then, anastomotic fistulas related signs did not appear again.



DOI: 10.12998/wjcc.v10.i21.7609 Copyright ©The Author(s) 2022.

Figure 4 Radiography of gastrografin swallow. A: Radiography of gastrografin swallow before the anastomotic fistula repair. The lower esophagus was anastomosed with jejunum after radical total gastrectomy for gastric cancer and contrast agent leakage was seen at the upper end of anastomosis; B: Radiography of gastrografin swallow after the anastomotic fistula repair. Arrow shows contrast agent leakage.

DISCUSSION

A 44-year-old woman developed a persistent fever after laparoscopic radical total gastrectomy for gastric cancer. The methylthioninium chloride test and early CT suggested no anastomotic fistula; however, gastrografin swallow and late CT showed the opposite result. The fistula was successfully closed using an endoscopic clip. The methylthioninium chloride test, gastrografin, and CT performed on different postoperative dates for small esophagojejunostomy fistulas are different. The size of the anastomotic fistula is an important factor for the success of endoscopic treatment.

The reported rates of the EJF after radical gastrectomy vary from 0% to 5.8% [2-6], and with a mortality rate of 26.32% [7], which is one of the main causes of postoperative sepsis [9]. EJF usually occurs near the suture line. Cardiovascular disease, age, smoking, malnutrition, operative hormones, local blood supply, and inflammatory reactions to suture materials are the risk factors for anastomotic fistulas [6]. However, the effect of tumour stage and the timing of lymph node dissection on the incidence of anastomotic fistula remains controversial [10,11]. Anastomotic fistulas can be classified based on the time of onset, clinical presentation, site of anastomotic fistula, radio-appearance, and mixed factors [12] (Table 1), which are critical for selecting diagnosis and treatment.

There is no gold standard for the diagnosing anastomotic fistulas. The most common manifestations of intraperitoneal complications of anastomotic fistula include signs of sepsis and laboratory signs (leukocytosis and elevated C-reactive protein levels) postoperative 7 to 10 [13]. In this case, the persistent postoperative fever suggested a possible anastomotic fistula. To detect anastomotic fistula, air leak testing and transgastric methylthioninium chloride injection were used during the surgery, but Sethi *et al* [14] believed that intraoperative leak testing has no correlation with leak due to laparoscopic sleeve gastrectomy. Postoperative examination of the anastomotic fistula is important. Gastrografin swallow, methylthioninium chloride test, and CT are the main means of postoperative anastomotic fistula detection at present [15,16]. Many studies have shown that postoperative gastrografin swallow and methylthioninium chloride test were effective in confirming clinical evidence of anastomotic fistula [15]. The methylthioninium chloride test was performed on the postoperative day 6 and showed a negative result, while the result of gastrografin swallow on postoperative day 22 was positive. Although the sensitivity of gastrografin swallow was higher than that of the methylthioninium chloride test, it had a high false-negative rate [16]. Some studies found that CT had more advantages in diagnosing anastomotic fistulas than gastrografin swallow and methylthioninium chloride test [17]. Oral contrast agents may also be used to increase the sensitivity to CT [18]. Factors associated with the CT-based diagnosis of anastomotic fistula include mediastinal fluid, mediastinal air, wall discontinuity, and fistula. However, isolated mediastinal gas can be observed in patients without any leakage, which is a common finding after surgery and the diagnostic value of CT in different postoperative periods for anastomotic fistulas is also different [17]. In this case, CT was performed on postoperative days 4 and 14. Notably, the examination result indicated anastomotic leakage on postoperative day 14. Although some studies have discussed the CT-based diagnostic score for anastomotic fistula and the diagnostic value of radiographic image details, such as the differences in the number of bubbles around the anastomosis and the mediastinal space, CT cannot completely replace other diagnostic methods [17,19].

The treatment of anastomotic fistulas mainly includes endoscopic clamping, stent placement, and tissue sealant filling. The use of fibrin to promote the healing of anastomotic fistulas had a good clinical

Table 1 Classification of anastomotic fistula

Basis of classification	Classification	Definition
The time of anastomotic fistula	Early leaks	Early leaks appear 1 to 4 days after surgery
	Intermediate leaks	Intermediate leaks appear 5 to 9 days after surgery
	Late leaks	Late leaks appear 10 or more days after surgery
Clinical relevance and extent of dissemination	Type I leaks	Type I leaks are well localized, have no pleural or peritoneal spread, do not induce systemic clinical manifestations, and are usually readily treatable with medication
	Type II leaks	Type II leak spread to the abdominal cavity or pleura, or the drainage tube, followed by severe systemic clinical manifestations
Clinical and radiological findings	Type A leaks	Type A leaks have no clinical or radiological evidence
	Type B leaks	Type B leaks can be detected by radiological studies but without any clinical finding
	Type C leaks	Type C leaks have both radiological and clinical evidence

effect, while other researchers believed that it was only due to the mechanical sealing[20,21]. The actual therapeutic gold standard for postoperative oesophageal anastomotic fistulas is stent implantation[22]. Endoscopic clipping is another treatment for postoperative anastomotic fistula, which is suitable for anastomotic fistulas with small circumferences and ineffective conservative treatment. Two types of clips, through-the-scope clip (TTSC) and over-the-scope clip (OTSC), were used for endoscopic clipping. Anastomotic fistulas less than 10 mm in diameter are recommended to be clipped using a single TTSC [23]. Meanwhile, TTSCs and OTSCs have a high clipping success rate in anastomotic fistulas with a diameter of 10 to 20 mm[24,25]. Due to the limitation of the clip arm width and grasping force, TTSC is only applicable to anastomotic fistulas of less than 20 mm in diameter with healthy non-everted regular edges[26]. However, OTSCs have high clinical success rates for large anastomotic fistulas of up to 30 mm in diameter[24]. Anastomotic fistulas larger than 30mm in diameter are difficult to be clipped by endoscopy[27]. Endoscopic vacuum therapy (EVT) was introduced 10 years ago to treat anastomotic fistulas, and it has a higher closure rate than stent implantation[28]. Anastomotic fistula associated with fluid collection is a common indication for EVT, and EVT has a higher cure rate than stents for this type of anastomotic fistulas[27,29]. However, EVT requires frequent replacement of endoscopic devices, which means a higher risk for recurrent sedation. Hence, the correct choice of repair method is helpful in avoiding repeated surgeries. The European Society of Gastrointestinal Endoscopy (ESGE) recommends to consider endoscopic closure based on the type and size of the anastomotic fistula, the presence and characteristics of leaking fluid, the general situation of the patient, and the endoscopy expertise available at the center[27].

CONCLUSION

Early diagnosis of the small anastomotic fistulas is particularly important for the patient prognosis. Current studies suggest that the sensitivity of CT is higher than that of Gastrografin swallow and methylthioninium chloride tests; however, it cannot be used as the gold standard for the diagnosis of anastomotic fistula. Accurate diagnosis of anastomotic fistula should be combined with clinical manifestations and appropriate examination methods should be selected to avoid false results. The selection of anastomotic fistula repair should be conducted according to the ESGE recommendations. Endoscopic therapy, including stent placement, endoscopic clipping, and vacuum therapy, is preferred for patients with stable leakage and without peritonitis.

ACKNOWLEDGEMENTS

We thank the patient and her family who participated in this study. And we wish to thank the timely help given by Jiachen Ji, Ningyu Qin, Zhilan Yin and Ke Gong in taking part in revising and critically reviewing the article.

FOOTNOTES

Author contributions: Lu CY and Guo ZS performed the literature review and collected all the data related to the

case report; Liu YL, Liu KJ, Xu S, Yao HL and Li L did the surgical appraisal; all authors have read and approved the final manuscript.

Informed consent statement: Informed written consent was obtained from the patient for publication of this report and any accompanying images.

Conflict-of-interest statement: The authors declare that they have no conflict of interest.

CARE Checklist (2016) statement: The authors have read the CARE Checklist (2016), and the manuscript was prepared and revised according to the CARE Checklist (2016).

Open-Access: This article is an open-access article that was selected by an in-house editor and fully peer-reviewed by external reviewers. It is distributed in accordance with the Creative Commons Attribution NonCommercial (CC BY-NC 4.0) license, which permits others to distribute, remix, adapt, build upon this work non-commercially, and license their derivative works on different terms, provided the original work is properly cited and the use is non-commercial. See: <https://creativecommons.org/licenses/by-nc/4.0/>

Country/Territory of origin: China

ORCID number: Chen-Yang Lu 0000-0003-2515-5378; Ya-Li Liu 0000-0001-8207-0536; Kui-Jie Liu 0000-0002-9628-6116; Shu Xu 0000-0002-9498-8552; Hong-Liang Yao 0000-0002-8085-3876; Zhu-Shu Guo 0000-0003-4491-5483.

S-Editor: Ma YJ

L-Editor: A

P-Editor: Ma YJ

REFERENCES

- 1 **Gil-Rendo A**, Hernández-Lizoain JL, Martínez-Regueira F, Sierra Martínez A, Rotellar Sastre F, Cervera Delgado M, Valentí Azcarate V, Pastor Idoate C, Alvarez-Cienfuegos J. Risk factors related to operative morbidity in patients undergoing gastrectomy for gastric cancer. *Clin Transl Oncol* 2006; **8**: 354-361 [PMID: 16760011 DOI: 10.1007/s12094-006-0182-x]
- 2 **Kostakis ID**, Alexandrou A, Armeni E, Damaskos C, Kouraklis G, Diamantis T, Tsigris C. Comparison Between Minimally Invasive and Open Gastrectomy for Gastric Cancer in Europe: A Systematic Review and Meta-analysis. *Scand J Surg* 2017; **106**: 3-20 [PMID: 26929289 DOI: 10.1177/1457496916630654]
- 3 **Inokuchi M**, Otsuki S, Fujimori Y, Sato Y, Nakagawa M, Kojima K. Systematic review of anastomotic complications of esophagojejunostomy after laparoscopic total gastrectomy. *World J Gastroenterol* 2015; **21**: 9656-9665 [PMID: 26327774 DOI: 10.3748/wjg.v21.i32.9656]
- 4 **Hyodo M**, Hosoya Y, Hirashima Y, Haruta H, Kurashina K, Saito S, Yokoyama T, Arai W, Zuiki T, Yasuda Y, Nagai H. Minimum leakage rate (0.5%) of stapled esophagojejunostomy with sacrifice of a small part of the jejunum after total gastrectomy in 390 consecutive patients. *Dig Surg* 2007; **24**: 169-172 [PMID: 17476107 DOI: 10.1159/000102100]
- 5 **Haga Y**, Wada Y, Takeuchi H, Ikejiri K, Ikenaga M. Prediction of anastomotic leak and its prognosis in digestive surgery. *World J Surg* 2011; **35**: 716-722 [PMID: 21184072 DOI: 10.1007/s00268-010-0922-5]
- 6 **Barchi LC**, Ramos MFKP, Pereira MA, Dias AR, Ribeiro-Júnior U, Zilberstein B, Cecconello I. Esophagojejunal anastomotic fistula: a major issue after radical total gastrectomy. *Updates Surg* 2019; **71**: 429-438 [PMID: 31161587 DOI: 10.1007/s13304-019-00659-8]
- 7 **Aurello P**, Magistri P, D'Angelo F, Valabrega S, Sirimarco D, Tierno SM, Nava AK, Ramacciato G. Treatment of esophagojejunal anastomosis leakage: a systematic review from the last two decades. *Am Surg* 2015; **81**: 450-453 [PMID: 25975326]
- 8 **Cereatti F**, Grassia R, Drago A, Conti CB, Donatelli G. Endoscopic management of gastrointestinal leaks and fistulae: What option do we have? *World J Gastroenterol* 2020; **26**: 4198-4217 [PMID: 32848329 DOI: 10.3748/wjg.v26.i29.4198]
- 9 **Gagner M**, Buchwald JN. Comparison of laparoscopic sleeve gastrectomy leak rates in four staple-line reinforcement options: a systematic review. *Surg Obes Relat Dis* 2014; **10**: 713-723 [PMID: 24745978 DOI: 10.1016/j.soard.2014.01.016]
- 10 **Barchi LC**, Charruf AZ, de Oliveira RJ, Jacob CE, Cecconello I, Zilberstein B. Management of postoperative complications of lymphadenectomy. *Transl Gastroenterol Hepatol* 2016; **1**: 92 [PMID: 28138657 DOI: 10.21037/tgh.2016.12.05]
- 11 **Barchi LC**, Ramos MFKP, Dias AR, Yagi OK, Ribeiro-Júnior U, Zilberstein B, Cecconello I. TOTAL OMENTECTOMY IN GASTRIC CANCER SURGERY: IS IT ALWAYS NECESSARY? *Arq Bras Cir Dig* 2019; **32**: e1425 [PMID: 30758473 DOI: 10.1590/0102-672020180001e1425]
- 12 **Abou Rached A**, Basile M, El Masri H. Gastric leaks post sleeve gastrectomy: review of its prevention and management. *World J Gastroenterol* 2014; **20**: 13904-13910 [PMID: 25320526 DOI: 10.3748/wjg.v20.i38.13904]
- 13 **Tonolini M**, Bracchi E. Early postoperative imaging after non-bariatric gastric resection: a primer for radiologists. *Insights Imaging* 2017; **8**: 393-404 [PMID: 28631148 DOI: 10.1007/s13244-017-0559-0]
- 14 **Sethi M**, Zagzag J, Patel K, Magrath M, Somoza E, Parikh MS, Saunders JK, Ude-Welcome A, Schwack BF, Kurian MS, Fielding GA, Ren-Fielding CJ. Intraoperative leak testing has no correlation with leak after laparoscopic sleeve gastrectomy. *Surg Endosc* 2016; **30**: 883-891 [PMID: 26092015 DOI: 10.1007/s00464-015-4286-7]
- 15 **Sakran N**, Goitein D, Raziell A, Keidar A, Beglaibter N, Grinbaum R, Matter I, Alfici R, Mahajna A, Waksman I,

- Shimonov M, Assalia A. Gastric leaks after sleeve gastrectomy: a multicenter experience with 2,834 patients. *Surg Endosc* 2013; **27**: 240-245 [PMID: [22752283](#) DOI: [10.1007/s00464-012-2426-x](#)]
- 16 **Terterov D**, Leung PH, Twells LK, Gregory DM, Smith C, Boone D, Pace D. The usefulness and costs of routine contrast studies after laparoscopic sleeve gastrectomy for detecting staple line leaks. *Can J Surg* 2017; **60**: 335-341 [PMID: [28742012](#) DOI: [10.1503/cjs.015216](#)]
- 17 **Goense L**, Stassen PMC, Wessels FJ, van Rossum PSN, Ruurda JP, van Leeuwen MS, van Hillegersberg R. Diagnostic performance of a CT-based scoring system for diagnosis of anastomotic leakage after esophagectomy: comparison with subjective CT assessment. *Eur Radiol* 2017; **27**: 4426-4434 [PMID: [28357496](#) DOI: [10.1007/s00330-017-4802-3](#)]
- 18 **Kim TH**, Kim JH, Shin CI, Kim SH, Han JK, Choi BI. CT findings suggesting anastomotic leak and predicting the recovery period following gastric surgery. *Eur Radiol* 2015; **25**: 1958-1966 [PMID: [25708962](#) DOI: [10.1007/s00330-015-3608-4](#)]
- 19 **Shoji Y**, Takeuchi H, Fukuda K, Nakamura R, Wada N, Kawakubo H, Kitagawa Y. Air Bubble Sign: A New Screening Method for Anastomotic Leakage After Esophagectomy for Esophageal Cancer. *Ann Surg Oncol* 2018; **25**: 1061-1068 [PMID: [29318416](#) DOI: [10.1245/s10434-017-6327-z](#)]
- 20 **Kotzampassi K**, Eleftheriadis E. Tissue sealants in endoscopic applications for anastomotic leakage during a 25-year period. *Surgery* 2015; **157**: 79-86 [PMID: [25444220](#) DOI: [10.1016/j.surg.2014.06.002](#)]
- 21 **Tashiro K**, Takeno S, Kawano F, Kitamura E, Hamada R, Ikenoue M, Munakata S, Nanashima A, Nakamura K. Endoscopic filling with polyglycolic acid sheets and fibrin glue of persistent fistula after esophagectomy. *Endoscopy* 2021; **53**: 288-292 [PMID: [32544956](#) DOI: [10.1055/a-1200-8199](#)]
- 22 **Persson S**, Rouvelas I, Irino T, Lundell L. Outcomes following the main treatment options in patients with a leaking esophagus: a systematic literature review. *Dis Esophagus* 2017; **30**: 1-10 [PMID: [28881894](#) DOI: [10.1093/dote/dox108](#)]
- 23 **Chan SM**, Auyeung KKY, Lam SF, Chiu PWY, Teoh AYW. Current status in endoscopic management of upper gastrointestinal perforations, leaks and fistulas. *Dig Endosc* 2022; **34**: 43-62 [PMID: [34115407](#) DOI: [10.1111/den.14061](#)]
- 24 **Voermans RP**, Le Moine O, von Renteln D, Ponchon T, Giovannini M, Bruno M, Weusten B, Seewald S, Costamagna G, Deprez P, Fockens P; CLIPPER Study Group. Efficacy of endoscopic closure of acute perforations of the gastrointestinal tract. *Clin Gastroenterol Hepatol* 2012; **10**: 603-608 [PMID: [22361277](#) DOI: [10.1016/j.cgh.2012.02.005](#)]
- 25 **Magdeburg R**, Collet P, Post S, Kaehler G. Endoclippping of iatrogenic colonic perforation to avoid surgery. *Surg Endosc* 2008; **22**: 1500-1504 [PMID: [18071812](#) DOI: [10.1007/s00464-007-9682-1](#)]
- 26 **de Moura DTH**, Sachdev AH, Thompson CC. Endoscopic Full-Thickness Defects and Closure Techniques. *Curr Treat Options Gastroenterol* 2018; **16**: 386-405 [PMID: [30382572](#) DOI: [10.1007/s11938-018-0199-6](#)]
- 27 **Paspatis GA**, Arvanitakis M, Dumonceau JM, Barthet M, Saunders B, Turino SY, Dhillon A, Fragaki M, Gonzalez JM, Repici A, van Wanrooij RLJ, van Hooft JE. Diagnosis and management of iatrogenic endoscopic perforations: European Society of Gastrointestinal Endoscopy (ESGE) Position Statement - Update 2020. *Endoscopy* 2020; **52**: 792-810 [PMID: [32781470](#) DOI: [10.1055/a-1222-3191](#)]
- 28 **Scognamiglio P**, Reeh M, Karstens K, Bellon E, Kantowski M, Schön G, Zapf A, Chon SH, Izbicki JR, Tachezy M. Endoscopic vacuum therapy vs stenting for postoperative esophago-enteric anastomotic leakage: systematic review and meta-analysis. *Endoscopy* 2020; **52**: 632-642 [PMID: [32316043](#) DOI: [10.1055/a-1149-1741](#)]
- 29 **Rausa E**, Asti E, Aiolfi A, Bianco F, Bonitta G, Bonavina L. Comparison of endoscopic vacuum therapy vs endoscopic stenting for esophageal leaks: systematic review and meta-analysis. *Dis Esophagus* 2018; **31** [PMID: [29939229](#) DOI: [10.1093/dote/doy060](#)]



Published by **Baishideng Publishing Group Inc**
7041 Koll Center Parkway, Suite 160, Pleasanton, CA 94566, USA

Telephone: +1-925-3991568

E-mail: bpgoffice@wjgnet.com

Help Desk: <https://www.f6publishing.com/helpdesk>

<https://www.wjgnet.com>

