

World Journal of *Clinical Cases*

World J Clin Cases 2022 August 26; 10(24): 8432-8807



Contents

Thrice Monthly Volume 10 Number 24 August 26, 2022

EDITORIAL

- 8432** Evolution of *World Journal of Clinical Cases* over the past 5 years
Muthu S

OPINION REVIEW

- 8436** NF- κ B: A novel therapeutic pathway for gastroesophageal reflux disease?
Zhang ML, Ran LQ, Wu MJ, Jia QC, Qin ZM, Peng YG

MINIREVIEWS

- 8443** Obligate aerobic, gram-positive, weak acid-fast, nonmotile bacilli, *Tsukamurella tyrosinosolvens*: Minireview of a rare opportunistic pathogen
Usuda D, Tanaka R, Suzuki M, Shimozawa S, Takano H, Hotchi Y, Tokunaga S, Osugi I, Katou R, Ito S, Mishima K, Kondo A, Mizuno K, Takami H, Komatsu T, Oba J, Nomura T, Sugita M
- 8450** Diffusion tensor imaging pipeline measures of cerebral white matter integrity: An overview of recent advances and prospects
Safri AA, Nassir CMNCM, Iman IN, Mohd Taib NH, Achuthan A, Mustapha M
- 8463** Graft choices for anterolateral ligament knee reconstruction surgery: Current concepts
Chalidis B, Pitsilos C, Kitridis D, Givissis P
- 8474** Overview of the anterolateral complex of the knee
Garcia-Mansilla I, Zicaro JP, Martinez EF, Astoul J, Yacuzzi C, Costa-Paz M
- 8482** Complication of lengthening and the role of post-operative care, physical and psychological rehabilitation among fibula hemimelia
Salimi M, Sarallah R, Javanshir S, Mirghaderi SP, Salimi A, Khanzadeh S

ORIGINAL ARTICLE

Clinical and Translational Research

- 8490** Pyroptosis-related genes play a significant role in the prognosis of gastric cancer
Guan SH, Wang XY, Shang P, Du QC, Li MZ, Xing X, Yan B

Retrospective Study

- 8506** Effects of propofol combined with lidocaine on hemodynamics, serum adrenocorticotrophic hormone, interleukin-6, and cortisol in children
Shi S, Gan L, Jin CN, Liu RF
- 8514** Correlation analysis of national elite Chinese male table tennis players' shoulder proprioception and muscle strength
Shang XD, Zhang EM, Chen ZL, Zhang L, Qian JH

- 8525** Clinical value of contrast-enhanced ultrasound in early diagnosis of small hepatocellular carcinoma (≤ 2 cm)

Mei Q, Yu M, Chen Q

- 8535** Identification of predictive factors for post-transarterial chemoembolization liver failure in hepatocellular carcinoma patients: A retrospective study

Yuan M, Chen TY, Chen XR, Lu YF, Shi J, Zhang WS, Ye C, Tang BZ, Yang ZG

- 8547** Clinical significance of half-hepatic blood flow occlusion technology in patients with hepatocellular carcinoma with cirrhosis

Liu D, Fang JM, Chen XQ

- 8556** Which octogenarian patients are at higher risk after cholecystectomy for symptomatic gallstone disease? A single center cohort study

D'Acapito F, Solaini L, Di Pietrantonio D, Tauceri F, Mirarchi MT, Antelmi E, Flamini F, Amato A, Framarini M, Ercolani G

Clinical Trials Study

- 8568** Computed tomography combined with gastroscopy for assessment of pancreatic segmental portal hypertension

Wang YL, Zhang HW, Lin F

Observational Study

- 8578** Psychological needs of parents of children with complicated congenital heart disease after admitting to pediatric intensive care unit: A questionnaire study

Zhu JH, Jin CD, Tang XM

Prospective Study

- 8587** Quantitative differentiation of malignant and benign thyroid nodules with multi-parameter diffusion-weighted imaging

Zhu X, Wang J, Wang YC, Zhu ZF, Tang J, Wen XW, Fang Y, Han J

Randomized Controlled Trial

- 8599** Application of unified protocol as a transdiagnostic treatment for emotional disorders during COVID-19: An internet-delivered randomized controlled trial

Yan K, Yusufi MH, Nazari N

- 8615** High-flow nasal cannula oxygen therapy during anesthesia recovery for older orthopedic surgery patients: A prospective randomized controlled trial

Li XN, Zhou CC, Lin ZQ, Jia B, Li XY, Zhao GF, Ye F

SYSTEMATIC REVIEWS

- 8625** Assessment tools for differential diagnosis of neglect: Focusing on egocentric neglect and allocentric neglect

Lee SH, Lim BC, Jeong CY, Kim JH, Jang WH

CASE REPORT

- 8634** Exome analysis for Cronkhite-Canada syndrome: A case report
Li ZD, Rong L, He YJ, Ji YZ, Li X, Song FZ, Li XA
- 8641** Discrepancy between non-invasive prenatal testing result and fetal karyotype caused by rare confined placental mosaicism: A case report
Li Z, Lai GR
- 8648** Paroxysmal speech disorder as the initial symptom in a young adult with anti-N-methyl-D-aspartate receptor encephalitis: A case report
Hu CC, Pan XL, Zhang MX, Chen HF
- 8656** Anesthetics management of a renal angiomyolipoma using pulse pressure variation and non-invasive cardiac output monitoring: A case report
Jeon WJ, Shin WJ, Yoon YJ, Park CW, Shim JH, Cho SY
- 8662** Traumatic giant cell tumor of rib: A case report
Chen YS, Kao HW, Huang HY, Huang TW
- 8667** Analysis of two naval pilots' ejection injuries: Two case reports
Zeng J, Liu XP, Yi JC, Lu X, Liu DD, Jiang YQ, Liu YB, Tian JQ
- 8673** Beware of the DeBakey type I aortic dissection hidden by ischemic stroke: Two case reports
Chen SQ, Luo WL, Liu W, Wang LZ
- 8679** Unilateral lichen planus with Blaschko line distribution: A case report
Dong S, Zhu WJ, Xu M, Zhao XQ, Mou Y
- 8686** Clinical features and progress of ischemic gastritis with high fatalities: Seven case reports
Shionoya K, Sasaki A, Moriya H, Kimura K, Nishino T, Kubota J, Sumida C, Tasaki J, Ichita C, Makazu M, Masuda S, Koizumi K, Kawachi J, Tsukiyama T, Kako M
- 8695** Retinoblastoma in an older child with secondary glaucoma as the first clinical presenting symptom: A case report
Zhang Y, Tang L
- 8703** Recurrent herpes zoster in a rheumatoid arthritis patient treated with tofacitinib: A case report and review of the literature
Lin QX, Meng HJ, Pang YY, Qu Y
- 8709** Intra-abdominal ectopic bronchogenic cyst with a mucinous neoplasm harboring a *GNAS* mutation: A case report
Murakami T, Shimizu H, Yamazaki K, Nojima H, Usui A, Kosugi C, Shuto K, Obi S, Sato T, Yamazaki M, Koda K
- 8718** Effects of intravascular photobiomodulation on motor deficits and brain perfusion images in intractable myasthenia gravis: A case report
Lan CH, Wu YC, Chiang CC, Chang ST

- 8728** Spontaneous acute epidural hematoma secondary to skull and dural metastasis of hepatocellular carcinoma: A case report
Ly GZ, Li GC, Tang WT, Zhou D, Yang Y
- 8735** Malignant melanotic nerve sheath tumors in the spinal canal of psammomatous and non-psammomatous type: Two case reports
Yeom JA, Song YS, Lee IS, Han IH, Choi KU
- 8742** When should endovascular gastrointestinal anastomosis transection Glissonean pedicle not be used in hepatectomy? A case report
Zhao J, Dang YL
- 8749** VARS2 gene mutation leading to overall developmental delay in a child with epilepsy: A case report
Wu XH, Lin SZ, Zhou YQ, Wang WQ, Li JY, Chen QD
- 8755** Junctional bradycardia in a patient with COVID-19: A case report
Aedh AI
- 8761** Application of 3 dimension-printed injection-molded polyether ether ketone lunate prosthesis in the treatment of stage III Kienböck's disease: A case report
Yuan CS, Tang Y, Xie HQ, Liang TT, Li HT, Tang KL
- 8768** High scored thyroid storm after stomach cancer perforation: A case report
Baik SM, Pae Y, Lee JM
- 8775** Cholecystitis-an uncommon complication following thoracic duct embolization for chylothorax: A case report
Dung LV, Hien MM, Tra My TT, Luu DT, Linh LT, Duc NM
- 8782** Endometrial squamous cell carcinoma originating from the cervix: A case report
Shu XY, Dai Z, Zhang S, Yang HX, Bi H
- 8788** Type 2 autoimmune pancreatitis associated with severe ulcerative colitis: Three case reports
Ghali M, Bensted K, Williams DB, Ghaly S
- 8797** Diffuse uterine leiomyomatosis: A case report and review of literature
Ren HM, Wang QZ, Wang JN, Hong GJ, Zhou S, Zhu JY, Li SJ

LETTER TO THE EDITOR

- 8805** Comment on "Posterior reversible encephalopathy syndrome in a patient with metastatic breast cancer: A case report"
Kunić S, Ibrahimagić OČ, Kojić B, Džananović D

ABOUT COVER

Editorial Board Member of *World Journal of Clinical Cases*, Ahmed Mohamed Ahmed Al-Emam, PhD, Associate Professor, Department of Pathology, King Khalid University, Abha 62521, Saudi Arabia. amalemam@kku.edu.sa

AIMS AND SCOPE

The primary aim of *World Journal of Clinical Cases* (WJCC, *World J Clin Cases*) is to provide scholars and readers from various fields of clinical medicine with a platform to publish high-quality clinical research articles and communicate their research findings online.

WJCC mainly publishes articles reporting research results and findings obtained in the field of clinical medicine and covering a wide range of topics, including case control studies, retrospective cohort studies, retrospective studies, clinical trials studies, observational studies, prospective studies, randomized controlled trials, randomized clinical trials, systematic reviews, meta-analysis, and case reports.

INDEXING/ABSTRACTING

The WJCC is now abstracted and indexed in Science Citation Index Expanded (SCIE, also known as SciSearch®), Journal Citation Reports/Science Edition, Current Contents®/Clinical Medicine, PubMed, PubMed Central, Scopus, Reference Citation Analysis, China National Knowledge Infrastructure, China Science and Technology Journal Database, and Superstar Journals Database. The 2022 Edition of Journal Citation Reports® cites the 2021 impact factor (IF) for WJCC as 1.534; IF without journal self cites: 1.491; 5-year IF: 1.599; Journal Citation Indicator: 0.28; Ranking: 135 among 172 journals in medicine, general and internal; and Quartile category: Q4. The WJCC's CiteScore for 2021 is 1.2 and Scopus CiteScore rank 2021: General Medicine is 443/826.

RESPONSIBLE EDITORS FOR THIS ISSUE

Production Editor: *Ying-Yi Yuan*; Production Department Director: *Xu Guo*; Editorial Office Director: *Jin-Lei Wang*.

NAME OF JOURNAL

World Journal of Clinical Cases

ISSN

ISSN 2307-8960 (online)

LAUNCH DATE

April 16, 2013

FREQUENCY

Thrice Monthly

EDITORS-IN-CHIEF

Bao-Gan Peng, Jerzy Tadeusz Chudek, George Kontogeorgos, Maurizio Serati, Ja Hyeon Ku

EDITORIAL BOARD MEMBERS

<https://www.wjgnet.com/2307-8960/editorialboard.htm>

PUBLICATION DATE

August 26, 2022

COPYRIGHT

© 2022 Baishideng Publishing Group Inc

INSTRUCTIONS TO AUTHORS

<https://www.wjgnet.com/bpg/gerinfo/204>

GUIDELINES FOR ETHICS DOCUMENTS

<https://www.wjgnet.com/bpg/GerInfo/287>

GUIDELINES FOR NON-NATIVE SPEAKERS OF ENGLISH

<https://www.wjgnet.com/bpg/gerinfo/240>

PUBLICATION ETHICS

<https://www.wjgnet.com/bpg/GerInfo/288>

PUBLICATION MISCONDUCT

<https://www.wjgnet.com/bpg/gerinfo/208>

ARTICLE PROCESSING CHARGE

<https://www.wjgnet.com/bpg/gerinfo/242>

STEPS FOR SUBMITTING MANUSCRIPTS

<https://www.wjgnet.com/bpg/GerInfo/239>

ONLINE SUBMISSION

<https://www.f6publishing.com>

Retrospective Study

Identification of predictive factors for post-transarterial chemoembolization liver failure in hepatocellular carcinoma patients: A retrospective study

Min Yuan, Tian-You Chen, Xiao-Rong Chen, Yun-Fei Lu, Jia Shi, Wen-Si Zhang, Chen Ye, Bo-Zong Tang, Zong-Guo Yang

Specialty type: Gastroenterology and hepatology

Provenance and peer review: Unsolicited article; Externally peer reviewed.

Peer-review model: Single blind

Peer-review report's scientific quality classification

Grade A (Excellent): 0
Grade B (Very good): B
Grade C (Good): C, C
Grade D (Fair): 0
Grade E (Poor): E

P-Reviewer: Adhoute X, France; Borzio M, Italy; Kumar R, India

Received: March 23, 2022

Peer-review started: March 23, 2022

First decision: May 30, 2022

Revised: June 9, 2022

Accepted: July 16, 2022

Article in press: July 16, 2022

Published online: August 26, 2022



Min Yuan, Tian-You Chen, Department of Interventional Medicine, Shanghai Public Health Clinical Center, Fudan University, Shanghai 201508, China

Xiao-Rong Chen, Yun-Fei Lu, Jia Shi, Wen-Si Zhang, Chen Ye, Bo-Zong Tang, Zong-Guo Yang, Department of Integrative Medicine, Shanghai Public Health Clinical Center, Fudan University, Shanghai 201508, China

Bo-Zong Tang, Department of Internal Medicine of Traditional Chinese Medicine, Shanghai East Hospital, Tongji University School of Medicine, Shanghai 201200, China

Corresponding author: Bo-Zong Tang, MD, PhD, Attending Doctor, Department of Internal Medicine of Traditional Chinese Medicine, Shanghai East Hospital, Tongji University School of Medicine, No. 150 Jimo Road, Pudong New District, Shanghai 201200, China.
tangbozong@shphc.org.cn

Abstract

BACKGROUND

Post-transarterial chemoembolization (TACE) liver failure occurs frequently in hepatocellular carcinoma (HCC) patients. The identification of predictors for post-TACE liver failure is of great importance for clinical decision-making in this population.

AIM

To investigate the occurrence rate and predictive factors of post-TACE liver failure in this retrospective study to provide clues for decision-making regarding TACE procedures in HCC patients.

METHODS

The clinical records of HCC patients treated with TACE therapy were reviewed. Baseline clinical characteristics and laboratory parameters of these patients were extracted. Logistic models were used to identify candidates to predict post-TACE liver failure.

RESULTS

A total of 199 HCC patients were enrolled in this study, and 70 patients (35.2%)

developed post-TACE liver failure. Univariate and multivariate logistic models indicated that microspheres plus gelatin embolization and main tumor size > 5 cm were risk predictors for post-TACE liver failure [odds ratio (OR): 4.4, 95% confidence interval (CI): 1.2-16.3, $P = 0.027$; OR: 2.3, 95% CI: 1.05-5.3, $P = 0.039$, respectively]. Conversely, HCC patients who underwent tumor resection surgery before the TACE procedure had a lower risk for post-TACE liver failure (OR: 0.4, 95% CI: 0.2-0.95, $P = 0.039$).

CONCLUSION

Microspheres plus gelatin embolization and main tumor size might be risk factors for post-TACE liver failure in HCC patients, while prior tumor resection could be a favorable factor reducing the risk of post-TACE liver failure.

Key Words: Transarterial chemoembolization; Liver failure; Hepatocellular carcinoma; Embolization; Tumor size

©The Author(s) 2022. Published by Baishideng Publishing Group Inc. All rights reserved.

Core Tip: Post-transarterial chemoembolization (TACE) liver failure occurs frequently in hepatocellular carcinoma (HCC) patients. Unfortunately, the incidence and risk factors for post-TACE liver failure are inconsistent worldwide. This study addressed the occurrence rate and potential risk factors for post-TACE liver failure according to a single-center retrospective report. The results of this study should attract the attention of relevant medical practitioners and provide predictive clues for the precise interventional treatment of HCC patients.

Citation: Yuan M, Chen TY, Chen XR, Lu YF, Shi J, Zhang WS, Ye C, Tang BZ, Yang ZG. Identification of predictive factors for post-transarterial chemoembolization liver failure in hepatocellular carcinoma patients: A retrospective study. *World J Clin Cases* 2022; 10(24): 8535-8546

URL: <https://www.wjgnet.com/2307-8960/full/v10/i24/8535.htm>

DOI: <https://dx.doi.org/10.12998/wjcc.v10.i24.8535>

INTRODUCTION

Hepatocellular carcinoma (HCC) is predicted to be one of the most lethal cancers worldwide[1,2]. According to the Surveillance, Epidemiology, and End Results (SEER) registration agency project research, the incidence of HCC will continue to increase by 2030[1]. In addition, the annual mortality rate associated with liver cancer has increased significantly in the past two decades[1], and the survival of HCC patients with intermediate-advanced tumor stages has progressively decreased[1,3,4]. Currently, transarterial chemoembolization (TACE) is recommended as a first-line treatment strategy for patients with unresectable HCC[1,5]. Although the benefits of the TACE procedure have been demonstrated[1,6], there is still a lack of reliable evidence showing that TACE has a clear superiority over bland embolization. Even worse, the incidence of severe adverse events significantly increased after TACE[7]. Thus, post-TACE liver failure that most commonly causes death after TACE should not be ignored[5].

Post-TACE liver failure is one of the most lethal complications in HCC patients. In South Korea, 12% to 15% of patients treated with TACE developed acute liver failure within 14 d[8,9]. A prospective study in Hong Kong showed that the incidence of liver failure after TACE was approximately 20%[10]. In India, the incidence of post-TACE liver failure was 23.8% to 28.8% in HCC patients[11,12]. In a randomized trial in Europe, the results illustrated that approximately 60% of patients had liver failure after TACE more than once[13]. According to the results of the meta-analysis, 7.5% (range 0-48.6%) of HCC patients developed liver failure after TACE. The mortality rate associated with TACE treatment is 2.4% (0-9.5%), which is mainly due to liver failure after TACE[9]. In the first year after TACE treatment, more than 90% of post-TACE liver failure cases died. Therefore, liver failure after TACE is an independent risk factor for the lower survival rate of liver cancer patients[8]. Hence, identifying the risk factors that can predict the occurrence of post-TACE liver failure in HCC patients is of great importance [8].

This retrospective study aimed to assess the potential clinical characteristics and laboratory parameters that could be predictors for post-TACE liver failure, in the hope that our findings might be helpful for the early detection and early intervention of post-TACE liver failure in HCC patients.

MATERIALS AND METHODS

Ethics statement

The study protocol was reviewed and approved by the Ethics Committee, Shanghai Public Health Clinical Center, Fudan University (approval No. 2021-S062-01). Written informed consent was waived for this retrospective study.

Patients

The diagnosis of HCC was determined by pathology or according to radiological standards, according to the "Guidelines for the Diagnosis and Treatment of Primary Liver Cancer in China (2019 edition)". Two imaging approaches, including computed tomography (CT) or magnetic resonance imaging (MRI) to show arterial enhancement quality or an imaging study (CT or MRI) showing arterial enhancement quality and alpha-fetoprotein (AFP) level greater than 400 ng/mL were used[14]. HCC patients undergoing TACE as part of standard therapy between January 2019 and May 2020 in Shanghai Public Health Clinical Center, Fudan University, were included. The inclusion criteria were age ≥ 18 years and Child-Turcotte-Pugh (CTP) stage A and B. HCC patients who were pregnant or CTP stage C or had uncontrolled encephalopathy, underlying kidney failure, acute coronary syndromes or valvular heart diseases were excluded from our study.

Treatment procedure for TACE

The China Liver Cancer Staging was used to determine the necessity for the TACE procedure[14]. All HCC patients fasted overnight. The femoral artery was catheterized with a 5F sheath under local anesthesia. A thorough angiographic examination depicting the anatomy of the hepatic artery, tumor blush, feeding arteries, and arteriovenous shunts was performed. Contrast-enhanced CT or MRI and indirect portography were performed during angiography to ensure stable flow in the portal vein. A microcatheter for the injection of chemotherapeutic drugs and embolic agents was placed selectively in the segment arteries or superselectively in the tumor supplying arteries, which feed the HCC lesions. Two types of microspheres, 300-500 μm and 500-700 μm , were used. Combined embolization of microspheres and gelatin sponge particles was applied for patients with larger tumor sizes (diameter > 5 cm). The volume of lipiodol ranged from 4 to 30 mL, pirarubicin ranged from 0 to 50 mg, and lobaplatin ranged from 0 to 200 mg. After confirming the correct position of the catheter tip, the chemotherapeutic and embolic agents were infused under radiographic guidance. To control the correct administration of drugs and the occlusion of tumor vessels with flow stasis, a final angiography was performed. TACE combined with radiofrequency ablation (RFA) treatment were applied for HCC patients with a single nodule > 3 cm and ≤ 5 cm or those with 2-3 nodules ≤ 3 cm.

Outcome definition

As in previous reports[8,10,11], post-TACE liver failure in our study was modified and defined as the presence of any of the following conditions within one week after TACE: Increase in total bilirubin ≥ 17.1 $\mu\text{mol/L}$, increase in prothrombin time ≥ 3 s, new onset hepatic encephalopathy, and increase in ascites.

Data collection

All patients underwent blood examinations including routine blood tests, liver and kidney function tests, coagulation function tests, serum tumor markers, HBsAg, HBeAg, hepatitis B virus (HBV) DNA and anti-hepatitis C virus (HCV) antibody, prior to the procedure. HCV RNA was measured if a positive anti-HCV antibody was detected. Post-TACE liver function tests and coagulation function tests were conducted every 3 d within the first week after TACE. The serum samples were collected, transported and tested following the standard operating procedures of the Department of Medical Laboratory, Shanghai Public Health Clinical Center.

The assessment of post-TACE liver failure was performed at 7 d or earlier. Abdominal CT/MRI and chest CT were also performed prior to TACE procedures to assess the clinicopathological characteristics including main tumor size, tumor number, cirrhosis status, metastasis, portal vein tumor thrombus, vascular invasion, ascites and pleural effusion. Other medical information, including disease history and treatment history, was also collected. All TACE procedures were assessed separately.

Statistical analysis

Based on the variable types, Student's *t* test and chi-square test were used to analyze the differences in variables between groups. The parameters related to the results were evaluated by univariate and multivariate logistic regression. The results are reported as odds ratios (OR) with 95% confidence intervals (CI). Parameters significantly associated with the outcomes in the multivariate logistic model were included in the risk prediction model by nomogram with the "rms" package in the R software program. A calibration plot was presented to evaluate the performance of the nomogram, which was also established in the "rms" package in the R program. The area under the receiver operating characteristic curve (AUROC) was computed to assess the prediction efficiency of the latent predictors. Stata

software version 16.0 (Stata Corp LLC, Texas, United States) was used. A two-sided $P < 0.05$ was considered significant.

RESULTS

Baseline characteristics and laboratory parameters

In total, 199 HCC patients who received TACE therapy were included in this study, and 70 patients (35.2%) developed post-TACE liver failure. As summarized in [Table 1](#), more patients in the post-TACE liver failure group received microspheres plus gelatin embolization than in the nonpost-TACE liver failure group (24.3% *vs* 3.9%, $P < 0.001$, [Table 1](#)). The frequency of patients with a main tumor size ≥ 5 cm was significantly higher in the post-TACE liver failure group than in the nonpost-TACE liver failure group (58.6% *vs* 40.3%, $P = 0.014$, [Table 1](#)). More patients received combination therapy with RFA and had a resection surgery treatment history in the nonpost-TACE liver failure group than in the post-TACE liver failure group ($P = 0.025$ and $P = 0.032$, respectively, [Table 1](#)). Patients who developed post-TACE liver failure had significantly higher hematocrit, alanine aminotransferase (ALT), aspartate aminotransferase (AST), total bilirubin (TbIL) and direct bilirubin (DBiL) levels than those without post-TACE liver failure (all $P < 0.05$, [Table 1](#)). However, patients who developed post-TACE liver failure had significantly lower serum cystatin C and creatinine levels and higher estimated glomerular filtration rate (eGFR) levels than those without post-TACE liver failure (all $P < 0.05$, [Table 1](#)). The other baseline clinical characteristics and laboratory parameters were not significantly distributed between these two groups (all $P > 0.05$, [Table 1](#)).

Predictors for post-TACE liver failure

Univariate logistic analysis revealed that microspheres plus gelatin embolization, RFA combination, main tumor size, resection history, diabetes, hematocrit, ALT, AST, gamma-glutamyl transferase, TbIL, DBiL, total bile acid, serum cystatin C, creatinine and eGFR levels were all potential predictors for post-TACE liver failure (all $P < 0.1$, [Table 2](#)). When these variables were included in the multivariate model, microspheres plus gelatin embolization and main tumor size > 5 cm were risk factors for the occurrence of post-TACE liver failure (OR: 4.4, 95%CI: 1.2-16.3, $P = 0.027$ and OR: 2.3, 95%CI: 1.05-5.3, $P = 0.039$, respectively, [Table 2](#)). Conversely, HCC patients who underwent tumor resection surgery before the TACE procedure had a lower risk for post-TACE liver failure (OR: 0.4, 95%CI: 0.2-0.95, $P = 0.039$, [Table 2](#)).

Nomogram and ROC models of predictors

Based on the multivariate logistic analysis, we included microspheres plus gelatin embolization, main tumor size and liver tumor resection history as predictors to establish a nomogram model, which is shown in [Figure 1A](#). The calibration curve of the nomogram model with internal bootstrapping was calculated and is presented in [Figure 1B](#).

ROC analysis was also performed to evaluate the predictive ability of the indicators. As shown in [Figure 2](#), the AUROCs of microspheres plus gelatin embolization, main tumor size, liver tumor resection history, and the nomogram model were 0.602, 0.591, 0.569 and 0.61, respectively ([Figure 2](#)). Unfortunately, all the AUROCs were less than 0.7, leading to an unsatisfactory discrimination ability of these parameters for screening post-TACE liver failure in HCC patients.

Frequency of post-TACE liver failure in subgroups

HCC patients who received microspheres plus gelatin embolization developed post-TACE liver failure more frequently than those without microspheres combined with gelatin embolization (17/22, 77.3% *vs* 53/177, 29.9%, $P < 0.001$, [Figure 3A](#)). Patients with a main tumor size ≥ 5 cm experienced post-TACE liver failure significantly more frequently than those with a main tumor size < 5 cm (41/93, 44.1% *vs* 29/106, 27.4%; $P = 0.014$, [Figure 3B](#)). The incidence of post-TACE liver failure was significantly lower in HCC patients with a tumor resection history than in those without a liver tumor surgery history (11/49, 22.4% *vs* 39.3%, $P = 0.032$, [Figure 3C](#)).

DISCUSSION

The greatest concerns for TACE procedures are toxicity and safety issues. Post-TACE liver failure is one of the most severe complications and can lead to significant morbidity and mortality[15]. According to previous reports[8-11,13], post-TACE liver failure occurs frequently in HCC patients. In our study, post-TACE liver failure occurred in approximately 35% of HCC patients, regardless of whether they were TACE naïve patients or patients who received TACE treatment several times. To avoid the risk of post-TACE liver failure, early detection and prediction are of great importance in addressing TACE approaches.

Table 1 Baseline characteristics and laboratory parameters of hepatocellular carcinoma patients received post-transarterial chemoembolization

| Variables | Total (n = 199) | None post-TACE liver failure (n = 129) | Post-TACE liver failure (n = 70) | P value |
|--|-----------------|--|----------------------------------|---------|
| Age, yr, mean \pm SD | 59.4 \pm 10.9 | 59.7 \pm 11.1 | 58.9 \pm 10.7 | 0.59 |
| Male, n (%) | 157 (78.9) | 105 (81.4) | 52 (74.3) | 0.24 |
| Metastasis, n (%) | | | | |
| Renal/adrenal | 5 (2.5) | 5 (3.9) | 0 (0) | 0.095 |
| Abdomen/pelvis | 6 (3.0) | 4 (3.1) | 2 (2.9) | 0.92 |
| Lymphnode | 5 (2.5) | 3 (2.3) | 2 (2.9) | 0.82 |
| Bone | 8 (4.0) | 7 (5.4) | 1 (1.4) | 0.17 |
| Lung | 10 (5.0) | 5 (3.9) | 5 (7.1) | 0.31 |
| Intrahepatic | 11 (5.5) | 5 (3.9) | 6 (8.6) | 0.17 |
| Pleural effusion, n (%) | 21 (10.6) | 15 (11.6) | 6 (8.6) | 0.50 |
| Ascites, n (%) | 59 (29.6) | 38 (29.5) | 21 (30.0) | 0.94 |
| PVTI, n (%) | 56 (28.1) | 33 (25.6) | 23 (32.9) | 0.28 |
| Vascular invasion, n (%) | 16 (8.0) | 13 (10.1) | 3 (4.3) | 0.15 |
| Tumor number, n (%) | | | | 0.81 |
| 1 | 71 (37.8) | 44 (36.1) | 27 (40.9) | |
| 2 | 27 (14.4) | 18 (14.8) | 9 (13.6) | |
| ≥ 3 | 90 (47.9) | 60 (49.2) | 30 (45.5) | |
| Times of TACE prior to inclusion, median (IQR) | 1 (0, 3) | 1 (0, 2) | 1 (0, 3) | 0.82 |
| Embolization, n (%) | | | | |
| Microspheres | 55 (27.6) | 33 (25.6) | 22 (31.4) | 0.378 |
| Gelatin | 20 (10.1) | 12 (9.3) | 8 (11.4) | 0.634 |
| Microspheres plus gelatin | 22 (11.1) | 5 (3.9) | 17 (24.3) | < 0.001 |
| Lipiodol, mL, median (IQR) | 10 (5, 10) | 8 (5, 10) | 10 (6, 10) | 0.17 |
| Pirarubicin, mg, n (%) | | | | 0.68 |
| 0 | 55 (27.6) | 37 (28.7) | 18 (25.7) | |
| 10 | 36 (18.1) | 25 (19.4) | 11 (15.7) | |
| 20 | 99 (49.7) | 63 (48.8) | 36 (51.4) | |
| 30 | 4 (2.0) | 2 (1.6) | 2 (2.9) | |
| 40 | 4 (2.0) | 2 (1.6) | 2 (2.9) | |
| 50 | 1 (0.5) | 0 (0) | 1 (1.4) | |
| Lobaplatin, mg, n (%) | | | | 0.46 |
| 0 | 45 (22.6) | 28 (21.7) | 17 (24.3) | |
| 25 | 1 (0.5) | 1 (0.8) | 0 (0) | |
| 50 | 152 (76.4) | 100 (77.5) | 52 (74.3) | |
| 200 | 1 (0.5) | 0 (0) | 1 (1.4) | |
| Combination with RFA, n (%) | 22 (11.1) | 19 (14.7) | 3 (4.3) | 0.025 |
| Main tumor size ≥ 5 cm, n (%) | 93 (46.7) | 52 (40.3) | 41 (58.6) | 0.014 |
| CNLC, n (%) | | | | 0.071 |
| I | 93 (46.7) | 66 (51.2) | 27 (38.6) | |

| | | | | |
|---|---------------------|---------------------|---------------------|--------------|
| II | 50 (25.1) | 26 (20.2) | 24 (34.3) | |
| III | 39 (19.6) | 28 (21.7) | 11 (15.7) | |
| NA | 17 (8.5) | 9 (7.0) | 8 (11.4) | |
| Cirrhosis, <i>n</i> (%) | 185 (93.0) | 121 (93.8) | 64 (91.4) | 0.53 |
| CTP score, median (IQR) | 5 (5, 6) | 5 (5, 6) | 6 (5, 6) | 0.438 |
| MELD score, median (IQR) | 29.6 (27.3, 32.2) | 29.7 (27.4, 32.3) | 29.5 (27.1, 32.0) | 0.463 |
| Treatment history, <i>n</i> (%) | | | | |
| Sorafenib | 21 (10.6) | 14 (10.9) | 7 (10.0) | 0.85 |
| Resection | 49 (24.6) | 38 (29.5) | 11 (15.7) | 0.032 |
| Radiology | 72 (36.2) | 45 (34.9) | 27 (38.6) | 0.61 |
| Hypertension, <i>n</i> (%) | 43 (21.6) | 27 (20.9) | 16 (22.9) | 0.75 |
| Diabetes, <i>n</i> (%) | 29 (14.6) | 23 (17.8) | 6 (8.6) | 0.077 |
| Blood routine tests, median (IQR) | | | | |
| WBC, 10 ³ /mm ³ | 4.7 (3.5, 6.0) | 4.6 (3.4, 6.1) | 5.0 (3.8, 5.9) | 0.41 |
| RBC, 10 ⁴ /mm ³ | 4.1 (3.6, 4.6) | 4.1 (3.6, 4.5) | 4.3 (3.7, 4.6) | 0.13 |
| Hemoglobin, g/L | 127 (112, 141) | 124 (109, 140.5) | 132.5 (116, 144) | 0.069 |
| Hematocrit, % | 37.0 (6.3) | 36.3 (6.6) | 38.3 (5.7) | 0.032 |
| PLT, 10 ³ /mm ³ | 123.5 (80, 163) | 127 (82.5, 167) | 115 (75, 160) | 0.42 |
| Neutrophils, 10 ³ /mm ³ | 2.9 (2.0, 3.9) | 2.9 (1.9, 3.8) | 2.9 (2.0, 3.9) | 0.53 |
| Lymphocytes, 10 ³ /mm ³ | 1.1 (0.8, 1.4) | 1.1 (0.7, 1.4) | 1.1 (0.8, 1.4) | 0.44 |
| Monocytes, 10 ³ /mm ³ | 0.4 (0.3, 0.6) | 0.4 (0.3, 0.5) | 0.4 (0.3, 0.6) | 0.61 |
| Hypersensitive CRP, mg/L | 3.0 (0.7, 23.5) | 3.6 (0.7, 23.5) | 2.6 (0.6, 23.7) | 0.77 |
| Liver functions, median (IQR) | | | | |
| ALT, U/L | 29 (20, 44) | 26 (19, 38) | 37 (25, 54) | 0.002 |
| AST, U/L | 38 (26, 61) | 32 (25, 53) | 45.5 (32, 69) | < 0.001 |
| GGT, U/L | 78 (41, 175) | 63 (40, 156) | 115 (54, 210) | 0.057 |
| AKP, U/L | 137 (97, 197) | 129 (94, 192) | 154.5 (115, 207) | 0.068 |
| TBiL, μmol/L | 19 (13.1, 28.7) | 17.3 (12.2, 25.2) | 21.9 (15.6, 30.9) | 0.010 |
| DBiL, μmol/L | 8.5 (5.9, 12.7) | 7.9 (5.4, 11.5) | 9.9 (6.5, 15.6) | 0.007 |
| TBA, μmol/L | 17.7 (8.2, 40.5) | 15 (7.8, 32.8) | 22.1 (8.5, 44.9) | 0.091 |
| Albumin, g/L | 37.8 (33.7, 42.1) | 37.7 (33.7, 42.2) | 38.2 (34.4, 41.7) | 0.93 |
| Cholinesterase, U/L | 5224 (3698, 6826) | 5056 (3745, 6814) | 5297.5 (3493, 6917) | 0.73 |
| Kidney functions, median (IQR) | | | | |
| Serum cystatin C, mg/L | 0.97 (0.8, 1.13) | 0.99 (0.8, 1.19) | 0.89 (0.77, 1.04) | 0.021 |
| Urea, mmol/L | 4.8 (4.0, 5.9) | 5.0 (4.0, 6.17) | 4.47 (4, 5.7) | 0.28 |
| Creatinine, μmol/L | 62.4 (52.7, 74.5) | 64.5 (54.0, 81.2) | 59.7 (51, 68) | 0.025 |
| eGFR, mL/(min·1.73 m ²) | 116.1 (93.6, 137.9) | 111.6 (87.8, 135.7) | 127 (104.8, 140.3) | 0.039 |
| Serum ammonia, median (IQR) | 45 (34, 60) | 43.5 (34, 57) | 48 (35, 62) | 0.27 |
| Coagulation function tests, median (IQR) | | | | |
| PTA, % | 84 (73.5, 93) | 83 (73, 92) | 86 (74, 95) | 0.34 |
| Prothrombin time, s | 14.4 (13.8, 15.5) | 14.5 (13.8, 15.5) | 14.3 (13.5, 15.4) | 0.40 |
| INR | 1.11 (1.04, 1.22) | 1.12 (1.05, 1.22) | 1.1 (1.03, 1.21) | 0.31 |
| APTT, s | 39.3 (36.4, 42.1) | 38.9 (36.7, 42) | 39.4 (36.3, 42.9) | 1.00 |

| | | | | |
|-----------------------------------|-------------------|-------------------|-------------------|-------|
| TT, s | 17.7 (17, 18.7) | 17.6 (16.9, 18.6) | 17.7 (17.2, 18.8) | 0.34 |
| Fibrinogen, g/L | 2.9 (2.4, 3.7) | 2.9 (2.4, 3.7) | 3.0 (2.4, 3.7) | 0.99 |
| Serum tumor markers, median (IQR) | | | | |
| CA125, U/L | 21.8 (12.3, 59.1) | 21.8 (12.3, 62.8) | 22.3 (12.9, 54.3) | 0.86 |
| CA153, U/L | 12.9 (9.7, 18.6) | 12.4 (9.0, 18.5) | 13.7 (10.7, 18.7) | 0.40 |
| CA199, U/L | 19 (10.8, 38.5) | 18.5 (10.7, 34.6) | 21.1 (12.5, 41.4) | 0.42 |
| AFP, ng/mL | 26.8 (5.2, 745.1) | 20.3 (5.3, 639.1) | 58.2 (5, 1210) | 0.46 |
| CEA, ng/mL | 2.7 (1.9, 4.2) | 3.1 (2.0, 5.1) | 2.5 (1.8, 3.8) | 0.082 |

TACE: Post-transarterial chemoembolization; ALT: Alanine aminotransferase; AST: Aspartate aminotransferase; CNLC: China Liver Cancer Staging; CRP: C-reactive protein; CTP: Child-Turcotte-Pugh; DBiL: Direct bilirubin; eGFR: Estimated glomerular filtration rate; ESR: Erythrocyte sedimentation rate; GGT: Gamma-glutamyl transferase; INR: International normalized ratio; LDH: Lactate dehydrogenase; MELD: Mode for End-stage Liver Disease; PTA: Prothrombin activity; PVT: Portal vein tumor thrombus; RBC: Red blood cells; RFA: Radiofrequency ablation; TBA: Total bile acid; TBiL: Total bilirubin; WBC: White blood cells; IQR: Interquartile range; NA: Not available.

Table 2 Univariate and multivariate logistic models for identifying risk factors of post-transarterial chemoembolization liver failure¹

| Variables | Univariate | | P value | Multivariate | | P value |
|---|------------|----------|---------|--------------|------------|--------------|
| | OR | 95%CI | | OR | 95%CI | |
| Microsphere plus gelatin embolization, yes <i>vs</i> no | 8.0 | 2.8-22.7 | < 0.001 | 4.4 | 1.2-16.3 | 0.027 |
| Combination with RFA, yes <i>vs</i> no | 0.3 | 0.1-0.9 | 0.035 | 0.3 | 0.1-1.2 | 0.094 |
| Main tumor size ≥ 5 cm, yes <i>vs</i> no | 2.1 | 1.2-3.8 | 0.014 | 2.3 | 1.05-5.3 | 0.039 |
| Resection history, yes <i>vs</i> no | 0.4 | 0.2-0.9 | 0.034 | 0.4 | 0.2-0.95 | 0.039 |
| Diabetes, yes <i>vs</i> no | 0.4 | 0.2-1.1 | 0.084 | 0.3 | 0.1-1.03 | 0.056 |
| Hematocrit, per increase 1% | 1.1 | 1.0-1.1 | 0.034 | 1.1 | 0.997-1.1 | 0.06 |
| ALT, per increase 1 U/L | 1.01 | 1.0-1.03 | 0.026 | 1.01 | 0.99-1.03 | 0.262 |
| AST, per increase 1 U/L | 1.0 | 1.0-1.01 | 0.074 | 0.99 | 0.98-1.004 | 0.177 |
| GGT, per increase 1 U/L | 1.0 | 1.0-1.0 | 0.08 | 1.0 | 1.0-1.0 | 0.499 |
| TBiL, μmol/L | | | | | | |
| Normal | Reference | - | 1.0 | Reference | - | 1.0 |
| 1-2 ULN | 1.8 | 1.0-3.5 | 0.065 | 1.8 | 0.8-4.2 | 0.163 |
| ≥ 2 ULN | 2.3 | 1.0-5.3 | 0.062 | 2.1 | 0.6-7.5 | 0.269 |
| DBiL, per increase 1 μmol/L | 1.8 | 1.0-3.2 | 0.054 | 0.99 | 0.96-1.02 | 0.718 |
| TBA ≥ 17.7 μmol/L, yes <i>vs</i> no | 1.8 | 1.0-3.3 | 0.044 | 1.6 | 0.7-3.5 | 0.263 |
| Serum cystatin C, per increase 1 mg/L | 0.4 | 0.1-1.0 | 0.041 | 0.6 | 0.1-3.6 | 0.584 |
| Creatinine, per increase 1 μmol/L | 0.98 | 0.97-1.0 | 0.048 | 0.99 | 0.95-1.02 | 0.499 |
| eGFR, per increase 1 ml/(min·1.73 m ²) | 1.01 | 1.0-1.02 | 0.033 | 1.0 | 0.98-1.02 | 0.81 |

¹Only variables significantly associated with post-transarterial chemoembolization liver failure in univariate analysis ($P < 0.10$) were presented.

ALT: Alanine aminotransferase; AST: Aspartate aminotransferase; direct bilirubin; eGFR: Estimated glomerular filtration rate; GGT: Gamma-glutamyl transferase; RFA: Radiofrequency ablation; TBA: Total bile acid; TBiL: Total bilirubin; ULN: Upper limit of normal; OR: Odds ratio; CI: Confidence interval.

This study indicated that microspheres plus gelatin embolization beyond chemotherapy drugs might contribute to a higher risk of post-TACE liver failure. Microsphere embolization is recommended because their controllable size distribution and spherical shape may improve and strengthen the embolization effect[16]. The microsphere embolization strategy for vascular catheter calibration can maximize tumor necrosis[17]. Gelatin embolization also demonstrated beneficial clinical outcomes in the

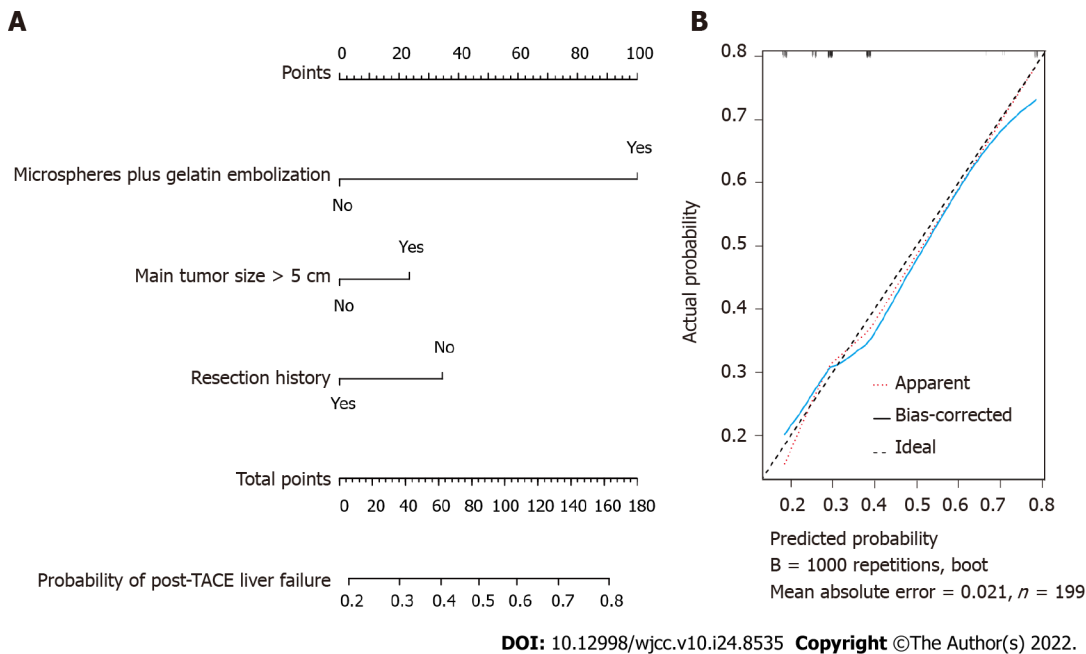


Figure 1 Nomogram for probability of post-transarterial chemoembolization liver failure in hepatocellular carcinoma patients. A: The nomogram model; B: The calibration curve of the nomogram model with internal validation through bootstrapping. TACE: Transarterial chemoembolization.

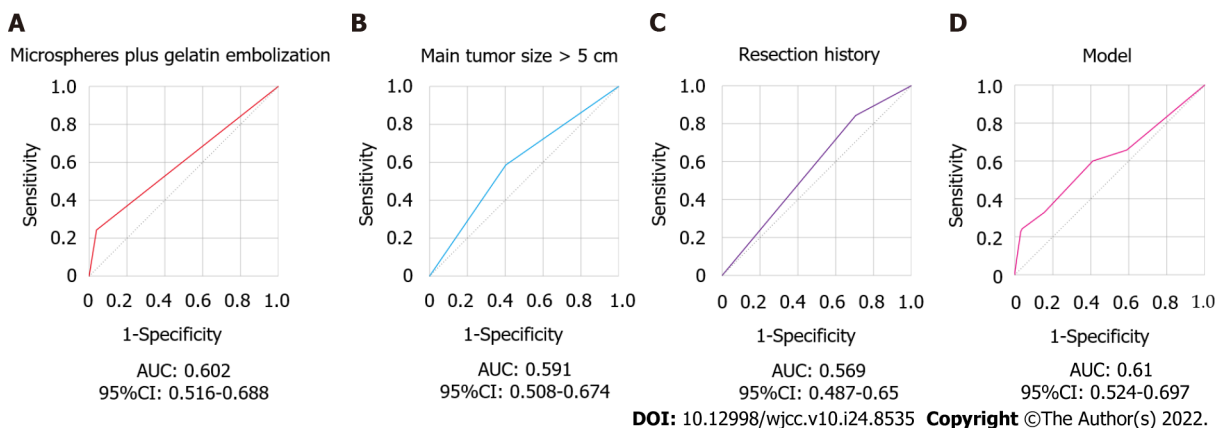


Figure 2 Receiver operating characteristic curves of predictors for post-transarterial chemoembolization liver failure. A: Receiver operating characteristic (ROC) of microspheres plus gelatin embolization; B: ROC of main tumor size > 5 cm; C: ROC of resection history; D: ROC of the nomogram model. AUC: Area under the curve; CI: Confidence interval.

treatment of HCC[18]. However, TACE includes hepatic artery infusion chemotherapy and embolization. Therefore, arterial infusion of chemotherapy drugs and embolization agents could be the main causes of liver failure after TACE[19]. The fragmentation of microspheres under pressure may cause nontargeted embolization and cause tissue necrosis[20]. The combination of microspheres and gelatin could induce more arterial trauma than the single use of microspheres or gelatin sponge particles. The reduction in arterial blood supply by arterial trauma may induce liver injury and inhibit the recovery of liver dysfunction after embolization[21]. Thus, the properties of the microspheres should be fully evaluated, including size distribution, compressibility, suspension evaluation, catheter transferability, and failure stress. In addition, gelatin-based embolization may lead to early recovery of blood flow or can lead to permanent occlusion due to its unpredictable enzymatic degradation profile[22]. Cautious investigation of the risks and benefits of gelatin-based embolization is suggested for TACE procedures.

In line with a previous report, TACE in patients with tumors larger than 5 cm predicts postprocedure liver failure[23]. Tumor size is a vital parameter that should be considered in the selection of multidisciplinary treatment strategies[24]. Multiple studies have demonstrated that a larger tumor size correlates with worse survival in HCC patients who receive TACE treatment[25-27]. There is consensus that a larger tumor size increases treatment difficulties, aggravates complications and deteriorates outcomes in HCC patients. Current evidence indicates that TACE plus sorafenib significantly improves

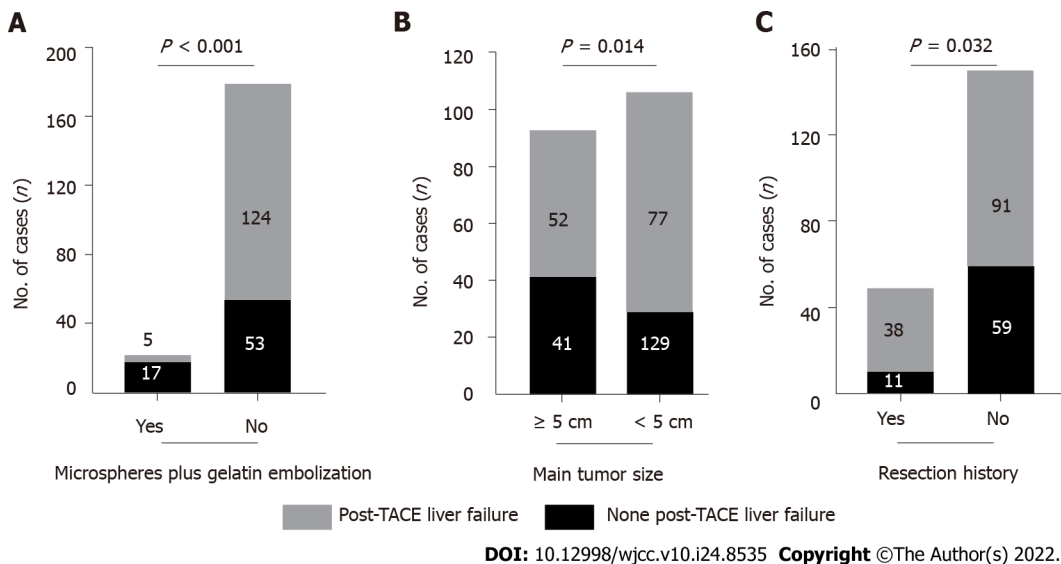


Figure 3 Frequency of post-transarterial chemoembolization (TACE) liver failure. A: Occurrence of post-transarterial chemoembolization (TACE) liver failure by microspheres plus gelatin embolization; B: Occurrence of post-TACE liver failure by main tumor size; C: Occurrence of post-TACE liver failure by resection history. TACE: Transarterial chemoembolization.

progression-free survival over TACE alone in patients with unresectable HCC[28]. According to these findings, it is essential to avoid combined embolization with microspheres and gelatin during the TACE procedure in unresected HCC patients with tumors larger than 5 cm in size. Unfortunately, no alternative solution has been envisaged to treat these large lesions in the current report.

The current guidelines recommend that surgical therapies, including resection and transplantation are the first-line choice for early-stage HCC patients[14,29]. This study revealed that patients who received liver tumor resection had a lower risk for post-TACE liver failure when they received TACE therapy in the late stages. Undoubtedly, the hepatic functional reserve of patients who received liver tumor resection was relatively better than that of HCC patients who had not undergone tumor resection. Inadequate hepatic functional reserve is one of the determining factors for post-hepatectomy liver failure[30,31]. Hepatic functional reserve has been proven to be associated with treatment selection, tumor recurrence and survival in patients with advanced HCC[32,33]. In clinical practice, preoperative assessment of hepatic functional reserve is of great importance for prevention of post-TACE liver failure, regardless of liver tumor resection history. Previous reports indicate that poor hepatic functional reserve, high-dose chemotherapy drug infusion, portal vein thrombosis, ascites, gastrointestinal bleeding, elevated AFP, and history of multiple embolization operations are risk factors for predicting post-TACE liver failure[8,10,11,13,15,21,34]. In addition, several models, including the CTP score, Barcelona Clinic Liver Cancer staging, Mode for End-stage Liver Disease score, and the Hepatoma Arterial-embolisation Prognostic score, were helpful for avoiding the post chemoembolization toxicity and treatment decision-making[3,35-37]. Considering the various definitions of post-TACE liver failure in these studies and our analysis, future research is still urgently needed to investigate candidates that could predict the occurrence of post-TACE liver failure.

This study has some limitations. The primary limitation is that this study had a relatively short follow up period, leading to no observations of recovery or irreversible post-TACE liver failure. Second, the retrospective design with a relatively small sample size in a single center might reduce its representativeness, and there was no calculation or justification of the sample size selected in this study. Third, the assessment of ascites increases in the definition of post-TACE liver failure brought subjectivity, and potential biases such as information bias and selection bias existed in this retrospective study. Fourth, the predictive performance of the risk factors and nomogram model for post-TACE liver failure is not promising enough for clinical application. However, our results indicate that post-TACE liver failure commonly occurred, especially in HCC patients who received microspheres plus gelatin embolization therapy, and those with larger main tumor sizes. A good hepatic functional reserve should be favorable for the occurrence of post-TACE liver failure.

CONCLUSION

Post-TACE liver failure occurs frequently in HCC patients. However, there is no uniform definition of post-TACE liver failure. The incidence of post-TACE liver failure varies from 0 to 60% globally. This retrospective study concluded that microspheres plus gelatin embolization and large tumor size might

be involved in the increased risk of post-TACE liver failure. Cautious preprocedure investigation of the risks and benefits of TACE therapy in HCC patients with large tumors is suggested. Embolization approaches should also be evaluated to avoid the risk of post-TACE liver failure. In addition, HCC patients who had undergone liver tumor resection had a lower risk for post-TACE liver failure when they received TACE therapy in the late stages. Moreover, early detection and prediction of post-TACE liver failure by monitoring the hepatic functional reserve should be addressed. Conclusively, it is essential to avoid combined embolization with microspheres and gelatin during the TACE procedure in unresected HCC patients with large tumor sizes.

ARTICLE HIGHLIGHTS

Research background

Post-transarterial chemoembolization (TACE) liver failure occurs frequently in hepatocellular carcinoma (HCC) patients received TACE procedure.

Research motivation

Identification of risk factors for post-TACE liver failure is important for TACE treatment decision-making.

Research objectives

The aim of this retrospective study was to assess the occurrence rate and predictive factors of post-TACE liver failure in HCC patients.

Research methods

Baseline characteristics and laboratory parameters of HCC patients received TACE therapy were assessed.

Research results

A total of 35.2% (70/199) HCC patients occurred post-TACE liver failure after TACE therapy. Logistic models indicated that microspheres plus gelatin embolization and main tumor size > 5 cm were risk predictors for the occurrence of post-TACE liver failure. Conversely, HCC patients who underwent tumor resection surgery before the TACE procedure had a lower risk for post-TACE liver failure.

Research conclusions

Microspheres plus gelatin embolization and main tumor size might be risk factors for the occurrence of post-TACE liver failure in HCC patients, while tumor resection history could be a favorable factor for post-TACE liver failure.

Research perspectives

Pre-TACE assessment including embolization strategy, tumor size, and hepatic functional reserve is of great importance for avoiding post-TACE liver failure. More studies need to be done to confirm these findings.

FOOTNOTES

Author contributions: Yang ZG and Tang BZ conceived and designed the study; Yuan M wrote the manuscript; Chen TY, Chen XR, Lu YF, Shi J, Zhang WS, Tang BZ, and Ye C analyzed and interpreted the data; Yang ZG and Tang BZ were responsible for revising the manuscript for important intellectual content; and all authors read and approved the final version.

Supported by Shanghai Science and Technology Committee, No. 19401931600; Shanghai Municipal Health Commission, No. 2020LZ001; and Health Commission of Pudong New District, Shanghai, No. PDZY-2021-0706.

Institutional review board statement: The study was reviewed and approved by the Ethics Committee, Shanghai Public Health Clinical Center, Fudan University (approval No.2021-S062-01).

Conflict-of-interest statement: All the authors declare that there are no conflicts of interest related to this study.

Data sharing statement: No additional data are available.

Open-Access: This article is an open-access article that was selected by an in-house editor and fully peer-reviewed by external reviewers. It is distributed in accordance with the Creative Commons Attribution NonCommercial (CC BY-

NC 4.0) license, which permits others to distribute, remix, adapt, build upon this work non-commercially, and license their derivative works on different terms, provided the original work is properly cited and the use is non-commercial. See: <https://creativecommons.org/licenses/by-nc/4.0/>

Country/Territory of origin: China

ORCID number: Min Yuan 0000-0002-4419-5546; Tian-You Chen 0000-0002-8668-6650; Xiao-Rong Chen 0000-0001-7202-9636; Yun-Fei Lu 0000-0002-9292-2517; Jia Shi 0000-0002-9936-6939; Wen-Si Zhang 0000-0002-9081-773X; Chen Ye 0000-0001-9500-4730; Bo-Zong Tang 0000-0002-1871-4760; Zong-Guo Yang 0000-0002-6623-4841.

S-Editor: Wang DM

L-Editor: A

P-Editor: Wang DM

REFERENCES

- 1 **Omata M**, Cheng AL, Kokudo N, Kudo M, Lee JM, Jia J, Tateishi R, Han KH, Chawla YK, Shiina S, Jafri W, Payawal DA, Ohki T, Ogasawara S, Chen PJ, Lesmana CRA, Lesmana LA, Gani RA, Obi S, Dokmeci AK, Sarin SK. Asia-Pacific clinical practice guidelines on the management of hepatocellular carcinoma: a 2017 update. *Hepatol Int* 2017; **11**: 317-370 [PMID: 28620797 DOI: 10.1007/s12072-017-9799-9]
- 2 **Villanueva A**. Hepatocellular Carcinoma. *N Engl J Med* 2019; **380**: 1450-1462 [PMID: 30970190 DOI: 10.1056/NEJMra1713263]
- 3 **Giannini EG**, Moscatelli A, Pellegatta G, Vitale A, Farinati F, Ciccarese F, Piscaglia F, Rapaccini GL, Di Marco M, Caturelli E, Zoli M, Borzio F, Cabibbo G, Felder M, Sacco R, Morisco F, Missale G, Foschi FG, Gasbarrini A, Baroni GS, Virdone R, Masotto A, Trevisani F; Italian Liver Cancer (ITA. LI.CA) Group; Italian Liver Cancer ITA LI CA Group. Application of the Intermediate-Stage Subclassification to Patients With Untreated Hepatocellular Carcinoma. *Am J Gastroenterol* 2016; **111**: 70-77 [PMID: 26729544 DOI: 10.1038/ajg.2015.389]
- 4 **Yang Z**, Zhuang L, Szatmary P, Wen L, Sun H, Lu Y, Xu Q, Chen X. Upregulation of heat shock proteins (HSPA12A, HSP90B1, HSPA4, HSPA5 and HSPA6) in tumour tissues is associated with poor outcomes from HBV-related early-stage hepatocellular carcinoma. *Int J Med Sci* 2015; **12**: 256-263 [PMID: 25798051 DOI: 10.7150/ijms.10735]
- 5 **Lencioni R**, de Baere T, Soulen MC, Rilling WS, Geschwind JF. Lipiodol transarterial chemoembolization for hepatocellular carcinoma: A systematic review of efficacy and safety data. *Hepatology* 2016; **64**: 106-116 [PMID: 26765068 DOI: 10.1002/hep.28453]
- 6 **Heimbach JK**, Kulik LM, Finn RS, Sirlin CB, Abecassis MM, Roberts LR, Zhu AX, Murad MH, Marrero JA. AASLD guidelines for the treatment of hepatocellular carcinoma. *Hepatology* 2018; **67**: 358-380 [PMID: 28130846 DOI: 10.1002/hep.29086]
- 7 **Facciorusso A**, Bellanti F, Villani R, Salvatore V, Muscatiello N, Piscaglia F, Vendemiale G, Serviddio G. Transarterial chemoembolization vs bland embolization in hepatocellular carcinoma: A meta-analysis of randomized trials. *United European Gastroenterol J* 2017; **5**: 511-518 [PMID: 28588882 DOI: 10.1177/2050640616673516]
- 8 **Hsin IF**, Hsu CY, Huang HC, Huang YH, Lin HC, Lee RC, Chiang JH, Lee FY, Huo TI, Lee SD. Liver failure after transarterial chemoembolization for patients with hepatocellular carcinoma and ascites: incidence, risk factors, and prognostic prediction. *J Clin Gastroenterol* 2011; **45**: 556-562 [PMID: 21666547 DOI: 10.1097/MCG.0b013e318210ff17]
- 9 **Marelli L**, Stigliano R, Triantos C, Senzolo M, Cholongitas E, Davies N, Tibbals J, Meyer T, Patch DW, Burroughs AK. Transarterial therapy for hepatocellular carcinoma: which technique is more effective? *Cardiovasc Intervent Radiol* 2007; **30**: 6-25 [PMID: 17103105 DOI: 10.1007/s00270-006-0062-3]
- 10 **Chan AO**, Yuen MF, Hui CK, Tso WK, Lai CL. A prospective study regarding the complications of transcatheter intraarterial lipiodol chemoembolization in patients with hepatocellular carcinoma. *Cancer* 2002; **94**: 1747-1752 [PMID: 11920537 DOI: 10.1002/cncr.10407]
- 11 **Shalimar**, Jain S, Gamanagatti SR, Kedia S, Thakur B, Nayak B, Kaur H, Gunjan D, Paul SB, Acharya SK. Role of Indocyanine Green in Predicting Post-Transarterial Chemoembolization Liver Failure in Hepatocellular Carcinoma. *J Clin Exp Hepatol* 2018; **8**: 28-34 [PMID: 29743794 DOI: 10.1016/j.jceh.2017.05.012]
- 12 **Khisti R**, Patidar Y, Garg L, Mukund A, Thomas SS, Sarin SK. Correlation of baseline Portal pressure (hepatic venous pressure gradient) and Indocyanine Green Clearance Test With Post-transarterial Chemoembolization Acute Hepatic Failure. *J Clin Exp Hepatol* 2019; **9**: 447-452 [PMID: 31516260 DOI: 10.1016/j.jceh.2018.09.004]
- 13 **Groupe d'Etude et de Traitement du Carcinome Hépatocellulaire**. A comparison of lipiodol chemoembolization and conservative treatment for unresectable hepatocellular carcinoma. *N Engl J Med* 1995; **332**: 1256-1261 [PMID: 7708069 DOI: 10.1056/NEJM199505113321903]
- 14 **Department of Medical Administration, National Health and Health Commission of the People's Republic of China**. [Guidelines for diagnosis and treatment of primary liver cancer in China (2019 edition)]. *Zhonghua Gan Zang Bing Za Zhi* 2020; **28**: 112-128 [PMID: 32164061 DOI: 10.3760/cma.j.issn.1007-3418.2020.02.004]
- 15 **Min YW**, Kim J, Kim S, Sung YK, Lee JH, Gwak GY, Paik YH, Choi MS, Koh KC, Paik SW, Yoo BC. Risk factors and a predictive model for acute hepatic failure after transcatheter arterial chemoembolization in patients with hepatocellular carcinoma. *Liver Int* 2013; **33**: 197-202 [PMID: 23295052 DOI: 10.1111/liv.12023]
- 16 **Hu J**, Albadawi H, Chong BW, Deipolyi AR, Sheth RA, Khademhosseini A, Oklu R. Advances in Biomaterials and Technologies for Vascular Embolization. *Adv Mater* 2019; **31**: e1901071 [PMID: 31168915 DOI: 10.1002/adma.201901071]

- 17 **Alvarez MM**, Aizenberg J, Analoui M, Andrews AM, Bisker G, Boyden ES, Kamm RD, Karp JM, Mooney DJ, Oklu R, Peer D, Stolzoff M, Strano MS, Trujillo-de Santiago G, Webster TJ, Weiss PS, Khademhosseini A. Emerging Trends in Micro- and Nanoscale Technologies in Medicine: From Basic Discoveries to Translation. *ACS Nano* 2017; **11**: 5195-5214 [PMID: 28524668 DOI: 10.1021/acsnano.7b01493]
- 18 **Wáng YX**, De Baere T, Idée JM, Ballet S. Transcatheter embolization therapy in liver cancer: an update of clinical evidences. *Chin J Cancer Res* 2015; **27**: 96-121 [PMID: 25937772 DOI: 10.3978/j.issn.1000-9604.2015.03.03]
- 19 **Buijs M**, Vossen JA, Frangakis C, Hong K, Georgiades CS, Chen Y, Liapi E, Geschwind JF. Nonresectable hepatocellular carcinoma: long-term toxicity in patients treated with transarterial chemoembolization--single-center experience. *Radiology* 2008; **249**: 346-354 [PMID: 18796686 DOI: 10.1148/radiol.2483071902]
- 20 **Cui DC**, Lu WL, Sa EA, Gu MJ, Lu XJ, Fan TY. Poly(acrylic acid) microspheres loaded with lidocaine: preparation and characterization for arterial embolization. *Int J Pharm* 2012; **436**: 527-535 [PMID: 22820132 DOI: 10.1016/j.ijpharm.2012.07.020]
- 21 **Katsushima S**, Inokuma T, Oi H, Okamura J, Higashi T, Takeuchi R, Hidaka A, Shigeno C, Iida Y, Konishi J. Acute hepatic failure following transcatheter arterial embolization for the treatment of hepatocellular carcinoma. *Digestion* 1997; **58**: 189-195 [PMID: 9144310 DOI: 10.1159/000201443]
- 22 **Tian L**, Lu L, Feng J, Melancon MP. Radiopaque nano and polymeric materials for atherosclerosis imaging, embolization and other catheterization procedures. *Acta Pharm Sin B* 2018; **8**: 360-370 [PMID: 29881675 DOI: 10.1016/j.apsb.2018.03.002]
- 23 **Siriwardana RC**, Niriella MA, Dassanayake AS, Liyanage CA, Upasena A, Sirigampala C, de Silva HJ. Factors affecting post-embolization fever and liver failure after trans-arterial chemo-embolization in a cohort without background infective hepatitis- a prospective analysis. *BMC Gastroenterol* 2015; **15**: 96 [PMID: 26239844 DOI: 10.1186/s12876-015-0329-8]
- 24 **O'Leary C**, Mahler M, Soulen MC. Liver-directed therapy for hepatocellular carcinoma. *Chin Clin Oncol* 2021; **10**: 8 [PMID: 32527111 DOI: 10.21037/cco-20-51]
- 25 **Liu L**, Zhang Q, Geng J, Li S, Zhao S, Zhang X, Hu J, Feng D. Comparison of radiofrequency ablation combined with sorafenib or sorafenib alone in patients with ECOG performance score 1: identifying optimal candidates. *Ann Transl Med* 2020; **8**: 583 [PMID: 32566610 DOI: 10.21037/atm.2020.03.71]
- 26 **Nam JY**, Choe AR, Sinn DH, Lee JH, Kim HY, Yu SJ, Kim YJ, Yoon JH, Lee JM, Chung JW, Choi SY, Lee JK, Baek SY, Lee HA, Kim TH, Yoo K. A differential risk assessment and decision model for Transarterial chemoembolization in hepatocellular carcinoma based on hepatic function. *BMC Cancer* 2020; **20**: 504 [PMID: 32487089 DOI: 10.1186/s12885-020-06975-2]
- 27 **Zhao S**, Zhang X, Wang M, Tan K, Dou W, Fan Q, Li H, Du X, Liu L. Identifying optimal candidates for liver resection or transarterial chemoembolisation in patients with unresectable hepatocellular carcinoma. *Ann Transl Med* 2020; **8**: 586 [PMID: 32566613 DOI: 10.21037/atm.2020.02.83]
- 28 **Kudo M**, Ueshima K, Ikeda M, Torimura T, Tanabe N, Aikata H, Izumi N, Yamasaki T, Nojiri S, Hino K, Tsumura H, Kuzuya T, Isoda N, Yasui K, Aino H, Ido A, Kawabe N, Nakao K, Wada Y, Yokosuka O, Yoshimura K, Okusaka T, Furuse J, Kokudo N, Okita K, Johnson PJ, Arai Y; TACTICS study group. Randomised, multicentre prospective trial of transarterial chemoembolisation (TACE) plus sorafenib as compared with TACE alone in patients with hepatocellular carcinoma: TACTICS trial. *Gut* 2020; **69**: 1492-1501 [PMID: 31801872 DOI: 10.1136/gutjnl-2019-318934]
- 29 **Hester CA**, Yopp AC. Surgical Therapies in Hepatocellular Carcinoma. 2019 Aug 6. In: *Hepatocellular Carcinoma: Translational Precision Medicine Approaches* [Internet]. Cham (CH): Humana Press; 2019- [PMID: 32078277]
- 30 **Lin WH**, Li K. [Recent advances in preoperative assessment of hepatic functional reserve for hepatectomy]. *Zhonghua Wai Ke Za Zhi* 2021; **59**: 392-396 [PMID: 33915630 DOI: 10.3760/cma.j.cn112139-20200506-00362]
- 31 **Li M**, Wang J, Song J, Shen F, Song L, Ni X, Suo T, Liu H, Zhong M. Preoperative ICG Test to Predict Posthepatectomy Liver Failure and Postoperative Outcomes in Hilar Cholangiocarcinoma. *Biomed Res Int* 2021; **2021**: 8298737 [PMID: 33681380 DOI: 10.1155/2021/8298737]
- 32 **Ochi H**, Hiraoka A, Hirooka M, Koizumi Y, Amano M, Azemoto N, Watanabe T, Yoshida O, Tokumoto Y, Mashiba T, Yokota T, Abe M, Michitaka K, Hiasa Y, Joko K. Direct-acting antivirals improve survival and recurrence rates after treatment of hepatocellular carcinoma within the Milan criteria. *J Gastroenterol* 2021; **56**: 90-100 [PMID: 33278003 DOI: 10.1007/s00535-020-01747-y]
- 33 **Uchikawa S**, Kawaoka T, Ando Y, Yamaoka K, Kosaka Y, Suehiro Y, Fujii Y, Morio K, Nakahara T, Murakami E, Tsuge M, Hiramatsu A, Imamura M, Takahashi S, Chayama K, Aikata H. Trends in Hepatic Functional Reserve of Patients with Hepatocellular Carcinoma Treated with Tyrosine Kinase Inhibitors. *Oncology* 2020; **98**: 727-733 [PMID: 32712613 DOI: 10.1159/000507815]
- 34 **Jeon SH**, Park KS, Kim YH, Shin YS, Kang MK, Jang BK, Chung WJ, Cho KB, Hwang JS. [Incidence and risk factors of acute hepatic failure after transcatheter arterial chemoembolization for hepatocellular carcinoma]. *Korean J Gastroenterol* 2007; **50**: 176-182 [PMID: 17885283]
- 35 **Kadalayil L**, Benini R, Pallan L, O'Beirne J, Marelli L, Yu D, Hackshaw A, Fox R, Johnson P, Burroughs AK, Palmer DH, Meyer T. A simple prognostic scoring system for patients receiving transarterial embolisation for hepatocellular cancer. *Ann Oncol* 2013; **24**: 2565-2570 [PMID: 23857958 DOI: 10.1093/annonc/mdt247]
- 36 **Vogeler M**, Mohr I, Pfeifferberger J, Sprengel SD, Klauss M, Teufel A, Chang DH, Springfield C, Longerich T, Merle U, Mehrabi A, Weiss KH, Mieth M. Applicability of scoring systems predicting outcome of transarterial chemoembolization for hepatocellular carcinoma. *J Cancer Res Clin Oncol* 2020; **146**: 1033-1050 [PMID: 32107625 DOI: 10.1007/s00432-020-03135-8]
- 37 **Reig M**, Forner A, Rimola J, Ferrer-Fàbrega J, Burrel M, Garcia-Criado Á, Kelley RK, Galle PR, Mazzaferro V, Salem R, Sangro B, Singal AG, Vogel A, Fuster J, Ayuso C, Bruix J. BCLC strategy for prognosis prediction and treatment recommendation: The 2022 update. *J Hepatol* 2022; **76**: 681-693 [PMID: 34801630 DOI: 10.1016/j.jhep.2021.11.018]



Published by **Baishideng Publishing Group Inc**
7041 Koll Center Parkway, Suite 160, Pleasanton, CA 94566, USA

Telephone: +1-925-3991568

E-mail: bpgoffice@wjgnet.com

Help Desk: <https://www.f6publishing.com/helpdesk>

<https://www.wjgnet.com>

