

World Journal of *Clinical Cases*

World J Clin Cases 2022 November 6; 10(31): 11214-11664



Contents

Thrice Monthly Volume 10 Number 31 November 6, 2022

REVIEW

- 11214** Diabetes and skin cancers: Risk factors, molecular mechanisms and impact on prognosis
Dobrică EC, Banciu ML, Kipkorir V, Khazeei Tabari MA, Cox MJ, Simhachalam Kutikuppala LV, Găman MA
- 11226** Endocrine disruptor chemicals as obesogen and diabetogen: Clinical and mechanistic evidence
Kurşunoğlu NE, Sarer Yurekli BP
- 11240** Intestinal microbiota in the treatment of metabolically associated fatty liver disease
Wang JS, Liu JC

MINIREVIEWS

- 11252** Lactation mastitis: Promising alternative indicators for early diagnosis
Huang Q, Zheng XM, Zhang ML, Ning P, Wu MJ
- 11260** Clinical challenges of glycemic control in the intensive care unit: A narrative review
Sreedharan R, Martini A, Das G, Aftab N, Khanna S, Ruetzler K
- 11273** Concise review on short bowel syndrome: Etiology, pathophysiology, and management
Lakkasani S, Seth D, Khokhar I, Touza M, Dacosta TJ
- 11283** Role of nickel-regulated small RNA in modulation of *Helicobacter pylori* virulence factors
Freire de Melo F, Marques HS, Fellipe Bueno Lemos F, Silva Luz M, Rocha Pinheiro SL, de Carvalho LS, Souza CL, Oliveira MV
- 11292** Surgical intervention for acute pancreatitis in the COVID-19 era
Su YJ, Chen TH

ORIGINAL ARTICLE

Clinical and Translational Research

- 11299** Screening of traditional Chinese medicine monomers as ribonucleotide reductase M2 inhibitors for tumor treatment
Qin YY, Feng S, Zhang XD, Peng B

Case Control Study

- 11313** Covered transjugular intrahepatic portosystemic stent-shunt *vs* large volume paracentesis in patients with cirrhosis: A real-world propensity score-matched study
Dhaliwal A, Merhzad H, Karkhanis S, Tripathi D

Retrospective Cohort Study

- 11325** Endoscopic submucosal tunnel dissection for early esophageal squamous cell carcinoma in patients with cirrhosis: A propensity score analysis
Zhu LL, Liu LX, Wu JC, Gan T, Yang JL

Retrospective Study

- 11338** Nomogram for predicting overall survival in Chinese triple-negative breast cancer patients after surgery
Lin WX, Xie YN, Chen YK, Cai JH, Zou J, Zheng JH, Liu YY, Li ZY, Chen YX
- 11349** Early patellar tendon rupture after total knee arthroplasty: A direct repair method
Li TJ, Sun JY, Du YQ, Shen JM, Zhang BH, Zhou YG
- 11358** Coxsackievirus A6 was the most common enterovirus serotype causing hand, foot, and mouth disease in Shiyang City, central China
Li JF, Zhang CJ, Li YW, Li C, Zhang SC, Wang SS, Jiang Y, Luo XB, Liao XJ, Wu SX, Lin L
- 11371** Dynamic changes of estimated glomerular filtration rate are conversely related to triglyceride in non-overweight patients
Liu SQ, Zhang XJ, Xue Y, Huang R, Wang J, Wu C, He YS, Pan YR, Liu LG
- 11381** C-reactive protein as a non-linear predictor of prolonged length of intensive care unit stay after gastrointestinal cancer surgery
Yan YM, Gao J, Jin PL, Lu JJ, Yu ZH, Hu Y

Clinical Trials Study

- 11391** Dan Bai Xiao Formula combined with glucocorticoids and cyclophosphamide for pediatric lupus nephritis: A pilot prospective study
Cao TT, Chen L, Zhen XF, Zhao GJ, Zhang HF, Hu Y

Observational Study

- 11403** Relationship between lipids and sleep apnea: Mendelian randomization analysis
Zhang LP, Zhang XX
- 11411** Efficacy and safety profile of two-dose SARS-CoV-2 vaccines in cancer patients: An observational study in China
Cai SW, Chen JY, Wan R, Pan DJ, Yang WL, Zhou RG

Prospective Study

- 11419** Pressure changes in tapered and cylindrical shaped cuff after extension of head and neck: A randomized controlled trial
Seol G, Jin J, Oh J, Byun SH, Jeon Y

Randomized Controlled Trial

- 11427** Effect of intradermal needle therapy at combined acupoints on patients' gastrointestinal function following surgery for gastrointestinal tumors
Guo M, Wang M, Chen LL, Wei FJ, Li JE, Lu QX, Zhang L, Yang HX

SYSTEMATIC REVIEWS

- 11442** Video-assisted bystander cardiopulmonary resuscitation improves the quality of chest compressions during simulated cardiac arrests: A systemic review and meta-analysis

Pan DF, Li ZJ, Ji XZ, Yang LT, Liang PF

META-ANALYSIS

- 11454** Efficacy of the femoral neck system in femoral neck fracture treatment in adults: A systematic review and meta-analysis

Wu ZF, Luo ZH, Hu LC, Luo YW

- 11466** Prevalence of polymyxin-induced nephrotoxicity and its predictors in critically ill adult patients: A meta-analysis

Wang JL, Xiang BX, Song XL, Que RM, Zuo XC, Xie YL

CASE REPORT

- 11486** Novel compound heterozygous variants in the LHX3 gene caused combined pituitary hormone deficiency: A case report

Lin SZ, Ma QJ, Pang QM, Chen QD, Wang WQ, Li JY, Zhang SL

- 11493** Fatal bleeding due to an aorto-esophageal fistula: A case report and literature review

Ćeranić D, Nikolić S, Lučev J, Slanić A, Bujas T, Ocepek A, Skok P

- 11500** Tolvaptan ameliorated kidney function for one elderly autosomal dominant polycystic kidney disease patient: A case report

Zhou L, Tian Y, Ma L, Li WG

- 11508** Extensive right coronary artery thrombosis in a patient with COVID-19: A case report

Dall'Orto CC, Lopes RPF, Cancela MT, de Sales Padilha C, Pinto Filho GV, da Silva MR

- 11517** Yokoyama procedure for a woman with heavy eye syndrome who underwent multiple recession-resection operations: A case report

Yao Z, Jiang WL, Yang X

- 11523** Rectal cancer combined with abdominal tuberculosis: A case report

Liu PG, Chen XF, Feng PF

- 11529** Malignant obstruction in the ileocecal region treated by self-expandable stent placement under the fluoroscopic guidance: A case report

Wu Y, Li X, Xiong F, Bao WD, Dai YZ, Yue LJ, Liu Y

- 11536** Granulocytic sarcoma with long spinal cord compression: A case report

Shao YD, Wang XH, Sun L, Cui XG

- 11542** Aortic dissection with epileptic seizure: A case report

Zheng B, Huang XQ, Chen Z, Wang J, Gu GF, Luo XJ

- 11549** Multiple bilateral and symmetric C1-2 ganglioneuromas: A case report
Wang S, Ma JX, Zheng L, Sun ST, Xiang LB, Chen Y
- 11555** Acute myocardial infarction due to Kounis syndrome: A case report
Xu GZ, Wang G
- 11561** Surgical excision of a large retroperitoneal lymphangioma: A case report
Park JH, Lee D, Maeng YH, Chang WB
- 11567** Mass-like extragonadal endometriosis associated malignant transformation in the pelvis: A rare case report
Chen P, Deng Y, Wang QQ, Xu HW
- 11574** Gastric ulcer treated using an elastic traction ring combined with clip: A case report
Pang F, Song YJ, Sikong YH, Zhang AJ, Zuo XL, Li RY
- 11579** Novel liver vein deprivation technique that promotes increased residual liver volume (with video): A case report
Wu G, Jiang JP, Cheng DH, Yang C, Liao DX, Liao YB, Lau WY, Zhang Y
- 11585** Linear porokeratosis of the foot with dermoscopic manifestations: A case report
Yang J, Du YQ, Fang XY, Li B, Xi ZQ, Feng WL
- 11590** Primary hepatic angiosarcoma: A case report
Wang J, Sun LT
- 11597** Hemorrhagic shock due to ruptured lower limb vascular malformation in a neurofibromatosis type 1 patient: A case report
Shen LP, Jin G, Zhu RT, Jiang HT
- 11607** Gastric linitis plastica with autoimmune pancreatitis diagnosed by an endoscopic ultrasonography-guided fine-needle biopsy: A case report
Sato R, Matsumoto K, Kanzaki H, Matsumi A, Miyamoto K, Morimoto K, Terasawa H, Fujii Y, Yamazaki T, Uchida D, Tsutsumi K, Horiguchi S, Kato H
- 11617** Favorable response of primary pulmonary lymphoepithelioma-like carcinoma to sintilimab combined with chemotherapy: A case report
Zeng SY, Yuan J, Lv M
- 11625** Benign paroxysmal positional vertigo with congenital nystagmus: A case report
Li GF, Wang YT, Lu XG, Liu M, Liu CB, Wang CH
- 11630** Secondary craniofacial necrotizing fasciitis from a distant septic emboli: A case report
Lee DW, Kwak SH, Choi HJ
- 11638** Pancreatic paraganglioma with multiple lymph node metastases found by spectral computed tomography: A case report and review of the literature
Li T, Yi RQ, Xie G, Wang DN, Ren YT, Li K

- 11646** Apnea caused by retrobulbar anesthesia: A case report
Wang YL, Lan GR, Zou X, Wang EQ, Dai RP, Chen YX
- 11652** Unexplained septic shock after colonoscopy with polyethylene glycol preparation in a young adult: A case report
Song JJ, Wu CJ, Dong YY, Ma C, Gu Q
- 11658** Metachronous isolated penile metastasis from sigmoid colon adenocarcinoma: A case report
Yin GL, Zhu JB, Fu CL, Ding RL, Zhang JM, Lin Q

ABOUT COVER

Editorial Board Member of *World Journal of Clinical Cases*, Muhammad Hamdan Gul, MD, Assistant Professor, Department of Internal Medicine, University of Kentucky, Chicago, IL 60657, United States.
hamdan3802@hotmail.com

AIMS AND SCOPE

The primary aim of *World Journal of Clinical Cases* (WJCC, *World J Clin Cases*) is to provide scholars and readers from various fields of clinical medicine with a platform to publish high-quality clinical research articles and communicate their research findings online.

WJCC mainly publishes articles reporting research results and findings obtained in the field of clinical medicine and covering a wide range of topics, including case control studies, retrospective cohort studies, retrospective studies, clinical trials studies, observational studies, prospective studies, randomized controlled trials, randomized clinical trials, systematic reviews, meta-analysis, and case reports.

INDEXING/ABSTRACTING

The WJCC is now abstracted and indexed in Science Citation Index Expanded (SCIE, also known as SciSearch®), Journal Citation Reports/Science Edition, Current Contents®/Clinical Medicine, PubMed, PubMed Central, Scopus, Reference Citation Analysis, China National Knowledge Infrastructure, China Science and Technology Journal Database, and Superstar Journals Database. The 2022 Edition of Journal Citation Reports® cites the 2021 impact factor (IF) for WJCC as 1.534; IF without journal self cites: 1.491; 5-year IF: 1.599; Journal Citation Indicator: 0.28; Ranking: 135 among 172 journals in medicine, general and internal; and Quartile category: Q4. The WJCC's CiteScore for 2021 is 1.2 and Scopus CiteScore rank 2021: General Medicine is 443/826.

RESPONSIBLE EDITORS FOR THIS ISSUE

Production Editor: *Xu Guo*; Production Department Director: *Xiang Li*; Editorial Office Director: *Jin-Lei Wang*.

NAME OF JOURNAL

World Journal of Clinical Cases

ISSN

ISSN 2307-8960 (online)

LAUNCH DATE

April 16, 2013

FREQUENCY

Thrice Monthly

EDITORS-IN-CHIEF

Bao-Gan Peng, Jerzy Tadeusz Chudek, George Kontogeorgos, Maurizio Serati, Ja Hyeon Ku

EDITORIAL BOARD MEMBERS

<https://www.wjgnet.com/2307-8960/editorialboard.htm>

PUBLICATION DATE

November 6, 2022

COPYRIGHT

© 2022 Baishideng Publishing Group Inc

INSTRUCTIONS TO AUTHORS

<https://www.wjgnet.com/bpg/gerinfo/204>

GUIDELINES FOR ETHICS DOCUMENTS

<https://www.wjgnet.com/bpg/GerInfo/287>

GUIDELINES FOR NON-NATIVE SPEAKERS OF ENGLISH

<https://www.wjgnet.com/bpg/gerinfo/240>

PUBLICATION ETHICS

<https://www.wjgnet.com/bpg/GerInfo/288>

PUBLICATION MISCONDUCT

<https://www.wjgnet.com/bpg/gerinfo/208>

ARTICLE PROCESSING CHARGE

<https://www.wjgnet.com/bpg/gerinfo/242>

STEPS FOR SUBMITTING MANUSCRIPTS

<https://www.wjgnet.com/bpg/GerInfo/239>

ONLINE SUBMISSION

<https://www.f6publishing.com>



Malignant obstruction in the ileocecal region treated by self-expandable stent placement under the fluoroscopic guidance: A case report

Yu Wu, Xi Li, Fei Xiong, Wei-Dong Bao, Yong-Zhou Dai, Lin-Jun Yue, Yuan Liu

Specialty type: Oncology

Provenance and peer review:

Unsolicited article; Externally peer reviewed.

Peer-review model: Single blind

Peer-review report's scientific quality classification

Grade A (Excellent): 0
Grade B (Very good): 0
Grade C (Good): C
Grade D (Fair): D, D
Grade E (Poor): 0

P-Reviewer: Ferreira GSA, Brazil;
Tan JK, Malaysia

Received: June 26, 2022

Peer-review started: June 28, 2022

First decision: August 1, 2022

Revised: August 26, 2022

Accepted: September 29, 2022

Article in press: September 29, 2022

Published online: November 6, 2022



Yu Wu, Xi Li, Fei Xiong, Wei-Dong Bao, Yong-Zhou Dai, Lin-Jun Yue, Yuan Liu, Department of Interventional Oncology, Hospital of Chengdu University of Traditional Chinese Medicine, Chengdu 610072, Sichuan Province, China

Corresponding author: Yuan Liu, MD, Doctor, Surgical Oncologist, Teacher, Department of Interventional Oncology, Hospital of Chengdu University of Traditional Chinese Medicine, No. 39 Shierqiao Road, Chengdu 610072, Sichuan Province, China. liu_yuan2000@sina.com

Abstract

BACKGROUND

Malignant tumors of the ileocecal region often cause intestinal obstruction. Emergency surgery is the main treatment for patients presenting with an obstruction. However, this procedure is associated with a high mortality rate and frequent complications. The placement of colon stents is commonly performed for obstructions in the distal colon and is a less invasive and safer procedure. However, obstructions in the proximal colon are more challenging to treat by stent placement due to the increased distance from the anus.

CASE SUMMARY

This case report concerns an 88-year-old man with malignant intestinal obstruction in the ileocecal region. He was contraindicated for general anesthesia and surgical enterostomy. The placement of a self-expandable metallic stent seems an alternative to surgery, although stenting in this area is thought to be difficult and few studies have been reported so far. After three attempts at different interventional approaches, a stent was successfully placed in the obstructed segment under fluoroscopic guidance. After the procedure, the patient's abdominal distension and abdominal pain were significantly better than before.

CONCLUSION

For patients with proximal colonic obstruction, self-expandable metallic stent placement under fluoroscopic guidance could be considered as a feasible treatment to relieve abdominal distension and pain in patients with acute bowel obstruction. It has the characteristics of high safety and high patient tolerance. However, further study is still needed.

Key Words: Colon cancer; Ileocecal region; Intestinal obstruction; Stent placement;

Fluoroscopic guidance; Case report

©The Author(s) 2022. Published by Baishideng Publishing Group Inc. All rights reserved.

Core Tip: This report concerns the case of an 88-year-old man with malignant intestinal obstruction in the ileocecal region whose condition improved after successful the placement of the self-expandable metallic stent under fluoroscopic guidance.

Citation: Wu Y, Li X, Xiong F, Bao WD, Dai YZ, Yue LJ, Liu Y. Malignant obstruction in the ileocecal region treated by self-expandable stent placement under the fluoroscopic guidance: A case report. *World J Clin Cases* 2022; 10(31): 11529-11535

URL: <https://www.wjgnet.com/2307-8960/full/v10/i31/11529.htm>

DOI: <https://dx.doi.org/10.12998/wjcc.v10.i31.11529>

INTRODUCTION

The ileocecal region is the site of many common and frequent diseases, among which malignant tumors of the colon are one of the most prevalent. In turn, the tumors are highly susceptible to malignant colonic obstruction (MCO), with approximately 8%-29% of patients presenting with acute intestinal obstruction as a clinical symptom[1,2]. In recent years, placement of a self-expandable metallic stent (SEMS) under the guidance of fluoroscope or endoscope has been more widely used in treating intestinal malignant obstruction.

However, most colon stents were deployed in distal areas, such as the descending colon, sigmoid colon, and rectal colon. They were hardly used in proximal colonic obstructions due to the large distance from the anus and the tortuous colonic contours, making this procedure difficult for radiologists and endoscopists.

This report concerns the case of an 88-year-old man with intestinal obstruction in the ileocecal region whose condition improved after the successful placement of SEMS under fluoroscopic guidance. Few studies have been reported to date on the placement of stents in this region under fluoroscopy.

CASE PRESENTATION

Chief complaints

An 88-year-old male patient presented with abdominal distension for 10 d.

History of present illness

The patient complained of generalized abdominal pain and distension with associated nausea, vomiting, and constipation for 10 d. On admission, computed tomography (CT) of the abdomen suggested acute intestinal obstruction, otherwise no significant metastases were detected. To make a definite diagnosis, endoscopic examination was considered; however, the family members refused. In combination with the abdominal CT, the patient was considered to have a high probability of malignant obstruction and was recommended to undergo ileostomy. However, after a multidisciplinary discussion, the anesthesiologist advised against the surgical operation, in view of the patient's advanced age and underlying diseases, such as coronary heart disease and frequent premature atrial beats as suggested by an electrocardiogram. Furthermore, systemic chemotherapy was not recommended because the patient was weak, was bed-ridden, and Eastern Cooperative Oncology Group score was 3. Moreover, palliative treatment was the only choice to improve the patient's quality of survival. Therefore, SEMS placement was considered for this patient, although the distance from the anus to the obstruction site was long, and the procedure was considered extremely difficult.

History of past illness

He had been diagnosed with hypertension for 28 years, coronary heart disease for 20 years, and diabetes for 3 years. He had experienced previous occasional abdominal pain, change in stool pattern for 10 mo, and weight loss of 5 kg in the last 3 mo.

Personal and family history

The patient denied any family history of malignant tumors.

Physical examination

His vital signs were stable. The abdomen was distended, gastrointestinal type visible, and diffusely tender. There was no rebound tenderness, but abdominal auscultation revealed hyperactive bowel sounds.

Laboratory examinations

The blood work at admission showed moderate normocytic anemia. The levels of the following serum tumor markers were elevated: carcinoembryonic antigen, 50.9 ng/mL and carbohydrate antigen 19-9, < 2 U/mL.

Imaging examinations

An admission CT scan of the whole abdomen showed thickening of the wall of the ascending colon with significant dilatation of the small intestine with air-fluid flattening. The distal colon was empty, and a malignant colon tumor with acute intestinal obstruction was considered (Figure 1).

FINAL DIAGNOSIS

The patient's clinical diagnosis was considered to be malignant intestinal obstruction in the ileocecal region by the tumor board, according to the CT findings as well as the elevated serum tumor markers.

TREATMENT

The procedure was performed under fluoroscopic guidance without the assistance of a colonoscope. The patient was placed in the supine position. After lubrication and anesthesia of the anus with lidocaine slurry, a hydrophilic guide wire (0.035 inch by 260 cm, Radiation Focus, Terumo, Tokyo, Japan) and a vertebral angiographic catheter (5F, 100 cm, Terumo, Tokyo, Japan) were introduced through the anus coaxially.

A water-soluble contrast medium (Iodixanol, Hengrui, Jiangsu, China) and room air were injected through the catheter during the procedure to distend and outline the colon.

Under fluoroscopic guidance, the vertebral catheter was rotated, advanced, walked up, and intermittently traveled over the guidewire through the rectum into the sigmoid colon and, finally, to the hepatic flexure of the colon. The catheter was too short of reaching the ileocecal region. After the injection of contrast, the persistent occlusion of the ileocecal region was seen, with no apparent bowel movement on repeated observation. We managed to push the wire through the lesion but failed because the vertebral catheter was not close to the lesion, and the wire did not have enough backup.

Then, a colonic stent delivery system (WallFlex Colonic stent, Boston Scientific/Medical Technology, Watertown, MA, United States) was used as a support catheter and reached the ileocecal region under the fluoroscopic guidance. But the wire could not be freely moved ahead or back and rotated, and we failed to pass the obstructed segment after many tries (Figure 2A).

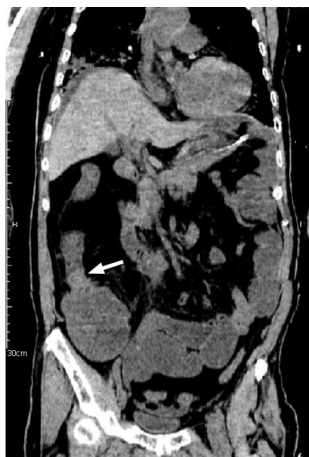The next day, an endoscopist managed to put the guide wire through the lesion under the guidance of a colonoscope in the endoscopy suite. However, the visibility was not good because of residual stool, and the procedure was not going well. Finally, it seemed successful. The patient was immediately transferred to the interventional suite to complete the next steps. To our surprise, the guide wire was located in the mid-transverse colon and far from the ileocecal region displayed by fluoroscopy image (Figure 2B).

On the third day, a Tandem contrast catheter (7F proximal and 5.5F distal, 120 cm, Boston Scientific/Medical Technology, Watertown, Mass. United States), which is usually used in Endoscopic retrograde cholangiopancreatography, was used in the procedure under the fluoroscopic guidance.

When the Tandem catheter reached the obstruction site, a multi-angle view was carried out, and the contrast medium was injected to outline and fill a thin line-like lumen (Figure 2C). The guidewire was easily pushed toward the direction indicated by this lumen, which passed through the occluded section and into the upper end of the obstructed bowel. Once the position was determined, a 25 mm × 90 mm uncovered stent (WallFlex Colonic stent, Boston Scientific/Medical Technology, Watertown, MA, United States) was introduced. After accurate positioning, the stent was slowly released (Figure 2D). The stent was fully dilated at both ends and stenosed in the middle by tumor compression in a satisfactory position. The procedure went well, and the patient returned to the ward safely.

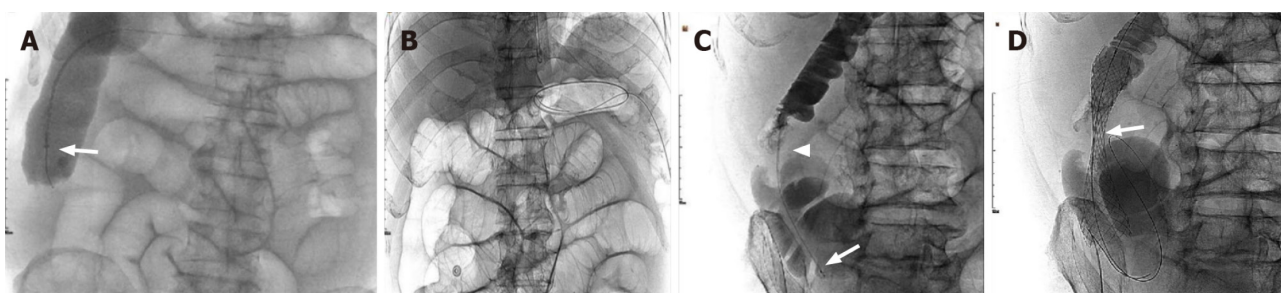
OUTCOME AND FOLLOW-UP

On postoperative day one, the patient's abdominal distension and abdominal pain were significantly better than before, the stool was clear, and the symptoms of intestinal obstruction were relieved. On the



DOI: 10.12998/wjcc.v10.i31.11529 Copyright ©The Author(s) 2022.

Figure 1 The patient's abdominal computed tomography coronary image before the procedure. It shows malignant obstruction (arrow) in the ileocecal region with diffuse small bowel dilation.



DOI: 10.12998/wjcc.v10.i31.11529 Copyright ©The Author(s) 2022.

Figure 2 The process of the three attempts at different interventional approaches. A: A single-curved catheter and a colonic stent release system (arrow) were successively used as a contrast catheter to reach the ileocecal region but failed to pass through the obstructed segment; B: On the second day, as shown by the plain film, the guidewire, which is assumed to have been pushed through the lesion with the assistance of colonoscopy, is located in the middle part of the transverse colon and still could not reach the obstructed segment; C: A tandem contrast catheter (proximal 7F, distal 5.5F, Boston Scientific) with the wire, was passed through the obstructed segment to reach the distal ileum, with the contrast media showing the obstructing lesion (arrow head) and dilated lumen; D: An uncovered stent is introduced and successfully deployed to the lesion segment (arrows) under fluoroscopic guidance alone.

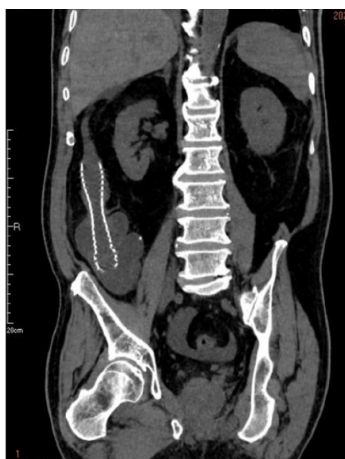second postoperative day, a repeat abdominal CT indicated changes after stent placement, and the stent was in place (Figure 3). On the fourth postoperative day, the patient was discharged from the hospital.

DISCUSSION

As we all know, MCO due to colorectal cancer (CRC) requires urgent decompression as a malignant gastrointestinal emergency. If not adequately treated, MCO can lead to fluid and electrolyte imbalance, colonic necrosis, bacterial translocation, and death[3]. It is generally accepted that right side obstructive CRC can best be treated by right hemicolectomy with ileocolic anastomosis[4]. Still, in this case, the patient was too old and had too many underlying diseases to tolerate emergency surgery. Internal stenting could be an alternative to relieve the patient's symptoms of intestinal obstruction in view of the following understanding.

SEMS insertion for obstructive colon cancer enables patients to avoid emergency surgery and to recover from the acute status with a reduced risk of postoperative complications and mortality. SEMS also enables mechanical bowel preparation, which lessens proximal bowel edema[5]. In addition, it avoids the inconvenience of temporary or permanent ileostomy and improves patients' quality of life. Implantation of a permanent internal stent to treat patients who are unable to undergo surgery or do not have surgical conditions can avoid the risk of palliative surgical treatment[6]. According to previous studies, SEMS as a bridge to surgery, has no deleterious effect on the long-term oncological prognosis of patients with CRC obstruction and can achieve similar results to direct surgery[7].

Many studies have been published within the last 20 years regarding the efficacy and safety of SEMS in colon cancer. Khot *et al*[8] reported a systematic review of case series between January 1990 and



DOI: 10.12998/wjcc.v10.i31.11529 Copyright ©The Author(s) 2022.

Figure 3 The computed tomography scan 2 d after the procedure. It shows the stent in its full expansion and in a good position, with the obstructed lumen completely recovered.

December 2000, in which 598 patients were analyzed. Technical success, expressed as stent placement and deployment, was achieved in 92% (551 stent placement attempts). Clinical success, defined as a colonic decompression within 96 h without surgical or endoscopic intervention, was attained in 88% ($n = 525$) [9]. Pattarajierapan *et al* [10] reported a systematic review of case series between 2009 and 2019. Although the patency of SEMS reported was shorter than for stoma creation; however, SEMS patency was not much different from that of stoma within the first year (88.9% *vs* 93.2% in 6 mo; 84.1% *vs* 90.5% in 12 mo). Furthermore, the 1-year re-intervention rates did not differ between SEMS insertion and stoma creation. Despite the lower SEMS patency rate after 1 year, 84% of the patients who underwent SEMS placement did not require any re-intervention until death. This finding suggests a short overall survival of patients with incurable metastatic disease. On the other hand, palliation for malignant gastro-intestinal and biliary obstruction with SEMS deployment show a long-term outcome of 70% stent patency until death [11,12], which is considered acceptable.

For patients with MCO who cannot undergo emergency surgery, stent installation should be performed under the assistance of colonoscopy. But, in this case, the site of malignant obstruction was located in the ileocecal region, which is a special anatomical and physiological location farthest from the anus for colonoscopy, and is not a relatively indicated area for colonic stenting. Since it has been reported that stents can be successfully placed in the ascending colon for malignant obstruction under fluoroscopic guidance [13], the procedure was elected for this patient.

Unlike the typical site of stent placement, the site of obstruction in this patient was exactly in the ileocecal region, which is far away from the anus; also, the catheter used was of normal length and could not reach this area. Under this circumstance, the catheter did not provide enough backup for the wire and could not pass through the obstructed bowel segment. Although the stent release system was long enough to reach the lesion, its lumen is tight and small, and would not allow the wire to move and rotate freely. Because the stent release system is not designed like a contrast catheter, the lumen of which is usually designed to be much larger; therefore, the above mentioned limits the operation of the guide wire during the procedure and prevented us from getting the wire through the lesion. The endoscope is often used in the implantation procedure in many medical centers. However, its application is limited mainly due to the pain experienced by the patients, unclear vision by the residual stool, tortuous bowel, and the low success rate. These were proved again in this case. Finally, with the help of the Tandem contrast catheter (7F proximal and 5.5F distal), which has a large enough lumen, the wire was rotated and controlled freely, to successfully get it through the obstructed lesion. Using the Tandem catheter allowed the procedure to proceed smoothly and provided a new way of thinking about stent placement for more distant bowel segments.

To the best of our knowledge, until now, few cases of malignant terminal ileal stricture with metallic stent placement have been reported. Compared with endoscopic stenting, fluoroscopic stenting has the characteristics of high safety and high patient tolerance. In addition, the site of obstruction, in this case, was just beyond the direct reach of colonoscopy in the ileocecal region, which provides a new direction for the future treatment of intestinal obstruction.

CONCLUSION

For patients with proximal colonic obstruction, SEMS placement under fluoroscopic guidance could be

considered as a feasible treatment to relieve abdominal distension and pain in patients with acute bowel obstruction. It has the characteristics of high safety and high patient tolerance. However, further study is still needed.

FOOTNOTES

Author contributions: Wu Y conceived the article; Wu Y and Li X collected the data; Xiong F, Bao WD, Dai YZ, and Yue LJ assembled the data; Wu Y and Liu Y provided the study materials, wrote the manuscript and approved the manuscript.

Informed consent statement: The participant consented to the submission of the case report to the journal. No information about the patient's privacy was revealed in this case or at any time.

Conflict-of-interest statement: All authors declare that they have no conflict of interest to disclose.

CARE Checklist (2016) statement: The authors have read the CARE Checklist (2016), and the manuscript was prepared and revised according to the CARE Checklist (2016).

Open-Access: This article is an open-access article that was selected by an in-house editor and fully peer-reviewed by external reviewers. It is distributed in accordance with the Creative Commons Attribution NonCommercial (CC BY-NC 4.0) license, which permits others to distribute, remix, adapt, build upon this work non-commercially, and license their derivative works on different terms, provided the original work is properly cited and the use is non-commercial. See: <https://creativecommons.org/licenses/by-nc/4.0/>

Country/Territory of origin: China

ORCID number: Yu Wu 0000-0002-1329-2917; Fei Xiong 0000-0002-1978-7945; Yuan Liu 0000-0002-9134-2545.

S-Editor: Liu JH

L-Editor: A

P-Editor: Liu JH

REFERENCES

- Makhejani KR, Haq MMU, Iqbal J, Zahid N. Self-expanding Metallic Stent Placement in Malignant Terminal Ileal Stricture. *J Coll Physicians Surg Pak* 2019; **29**: S89-S91 [PMID: 31779752 DOI: 10.29271/jcpsp.2019.12.S89]
- Deans GT, Krukowski ZH, Irwin ST. Malignant obstruction of the left colon. *Br J Surg* 1994; **81**: 1270-1276 [PMID: 7953385 DOI: 10.1002/bjs.1800810905]
- Saida Y. Current status of colonic stent for obstructive colorectal cancer in Japan; a review of the literature. *J Anus Rectum Colon* 2019; **3**: 99-105 [PMID: 31583324 DOI: 10.23922/jarc.2019-009]
- Atsushi I, Mitsuyoshi O, Kazuya Y, Syuhei K, Noriyuki K, Masashi M, Akira W, Kentaro S, Nobuyuki K, Natsuko S, Jun W, Yasushi I, Chikara K, Itaru E. Long-term outcomes and prognostic factors of patients with obstructive colorectal cancer: A multicenter retrospective cohort study. *World J Gastroenterol* 2016; **22**: 5237-5245 [PMID: 27298566 DOI: 10.3748/wjg.v22.i22.5237]
- Ji WB, Kwak JM, Kang DW, Kwak HD, Um JW, Lee SI, Min BW, Sung NS, Kim J, Kim SH. Clinical benefits and oncologic equivalence of self-expandable metallic stent insertion for right-sided malignant colonic obstruction. *Surg Endosc* 2017; **31**: 153-158 [PMID: 27194253 DOI: 10.1007/s00464-016-4946-2]
- Wang ZM, Gung K. Treatment of malignant obstruction of the left hemi-colon with self-expanding endoprosthesis. *Chinese Interv Imaging Ther* 2006; **3**: 278-279
- Haraguchi N, Ikeda M, Miyake M, Yamada T, Sakakibara Y, Mita E, Doki Y, Mori M, Sekimoto M. Colonic stenting as a bridge to surgery for obstructive colorectal cancer: advantages and disadvantages. *Surg Today* 2016; **46**: 1310-1317 [PMID: 27048552 DOI: 10.1007/s00595-016-1333-5]
- Khot UP, Lang AW, Murali K, Parker MC. Systematic review of the efficacy and safety of colorectal stents. *Br J Surg* 2002; **89**: 1096-1102 [PMID: 12190673 DOI: 10.1046/j.1365-2168.2002.02148.x]
- Feo L, Schaffzin DM. Colonic stents: the modern treatment of colonic obstruction. *Adv Ther* 2011; **28**: 73-86 [PMID: 21229339 DOI: 10.1007/s12325-010-0094-6]
- Pattarajirapan S, Manomayagoon C, Tipsuwannakul P, Khomvilai S. Comparison of colonic stenting and stoma creation as palliative treatment for incurable malignant colonic obstruction. *JGH Open* 2022 [DOI: 10.1002/jgh3.12800]
- Ishii T, Minaga K, Ogawa S, Ikenouchi M, Yoshikawa T, Akamatsu T, Seta T, Urai S, Uenoyama Y, Yamashita Y. Effectiveness and safety of metallic stent for ileocecal obstructive colon cancer: a report of 4 cases. *Endosc Int Open* 2017; **5**: E834-E838 [PMID: 28924586 DOI: 10.1055/s-0043-113560]
- ASGE Technology Committee, Varadarajulu S, Banerjee S, Barth B, Desilets D, Kaul V, Kethu S, Pedrosa M, Pfau P, Tokar J, Wang A, Song LM, Rodriguez S. Enteral stents. *Gastrointest Endosc* 2011; **74**: 455-464 [PMID: 21762904 DOI: 10.1016/j.gie.2011.04.011]
- Yoon J, Kwon SH, Lee CK, Park SJ, Oh JY, Oh JH. Radiologic Placement of Uncovered Stents for the Treatment of

Malignant Colonic Obstruction Proximal to the Descending Colon. *Cardiovasc Intervent Radiol* 2017; **40**: 99-105 [PMID: 27671155 DOI: 10.1007/s00270-016-1474-3]



Published by **Baishideng Publishing Group Inc**
7041 Koll Center Parkway, Suite 160, Pleasanton, CA 94566, USA

Telephone: +1-925-3991568

E-mail: bpgoffice@wjgnet.com

Help Desk: <https://www.f6publishing.com/helpdesk>

<https://www.wjgnet.com>

