

World Journal of *Clinical Cases*

World J Clin Cases 2022 October 6; 10(28): 9970-10390



Contents

Thrice Monthly Volume 10 Number 28 October 6, 2022

REVIEW

- 9970** COVID-19 and the heart
Xanthopoulos A, Bourazana A, Giamouzis G, Skoularigki E, Dimos A, Zagouras A, Papamichalis M, Leventis I, Magouliotis DE, Triposkiadis F, Skoularigis J
- 9985** Role of short chain fatty acids in gut health and possible therapeutic approaches in inflammatory bowel diseases
Caetano MAF, Castelucci P

MINIREVIEWS

- 10004** Review of the pharmacological effects of astragaloside IV and its autophagic mechanism in association with inflammation
Yang Y, Hong M, Lian WW, Chen Z

ORIGINAL ARTICLE

Clinical and Translational Research

- 10017** Effects of targeted-edited oncogenic insulin-like growth factor-1 receptor with specific-sgRNA on biological behaviors of HepG2 cells
Yao M, Cai Y, Wu ZJ, Zhou P, Sai WL, Wang DF, Wang L, Yao DF

Retrospective Study

- 10031** Analysis of the successful clinical treatment of 140 patients with parathyroid adenoma: A retrospective study
Peng ZX, Qin Y, Bai J, Yin JS, Wei BJ
- 10042** Efficacy of digital breast tomosynthesis combined with magnetic resonance imaging in the diagnosis of early breast cancer
Ren Y, Zhang J, Zhang JD, Xu JZ
- 10053** Prevention and management of adverse events following COVID-19 vaccination using traditional Korean medicine: An online survey of public health doctors
Kang B, Chu H, Youn BY, Leem J
- 10066** Clinical outcomes of targeted therapies in elderly patients aged ≥ 80 years with metastatic colorectal cancer
Jang HR, Lee HY, Song SY, Lim KH
- 10077** Endovascular treatment vs drug therapy alone in patients with mild ischemic stroke and large infarct cores
Kou WH, Wang XQ, Yang JS, Qiao N, Nie XH, Yu AM, Song AX, Xue Q

Clinical Trials Study

- 10085** One hundred and ninety-two weeks treatment of entecavir maleate for Chinese chronic hepatitis B predominantly genotyped B or C

Xu JH, Wang S, Zhang DZ, Yu YY, Si CW, Zeng Z, Xu ZN, Li J, Mao Q, Tang H, Sheng JF, Chen XY, Ning Q, Shi GF, Xie Q, Zhang XQ, Dai J

Observational Study

- 10097** Dementia-related contact experience, attitudes, and the level of knowledge in medical vocational college students

Liu DM, Yan L, Wang L, Lin HH, Jiang XY

SYSTEMATIC REVIEWS

- 10109** Link between COVID-19 vaccines and myocardial infarction

Zafar U, Zafar H, Ahmed MS, Khattak M

CASE REPORT

- 10120** Successful treatment of disseminated nocardiosis diagnosed by metagenomic next-generation sequencing: A case report and review of literature

Li T, Chen YX, Lin JJ, Lin WX, Zhang WZ, Dong HM, Cai SX, Meng Y

- 10130** Multiple primary malignancies – hepatocellular carcinoma combined with splenic lymphoma: A case report

Wu FZ, Chen XX, Chen WY, Wu QH, Mao JT, Zhao ZW

- 10136** Metastatic multifocal melanoma of multiple organ systems: A case report

Maksimaityte V, Reivytyte R, Milaknyte G, Mickys U, Razanskiene G, Stundys D, Kazenaite E, Valantinas J, Stundiene I

- 10146** Cavernous hemangioma of the ileum in a young man: A case report and review of literature

Yao L, Li LW, Yu B, Meng XD, Liu SQ, Xie LH, Wei RF, Liang J, Ruan HQ, Zou J, Huang JA

- 10155** Successful management of a breastfeeding mother with severe eczema of the nipple beginning from puberty: A case report

Li R, Zhang LX, Tian C, Ma LK, Li Y

- 10162** Short benign ileocolonic anastomotic strictures - management with bi-flanged metal stents: Six case reports and review of literature

Kasapidis P, Mavrogenis G, Mandrekas D, Bazerbachi F

- 10172** Simultaneous bilateral floating knee: A case report

Wu CM, Liao HE, Lan SJ

- 10180** Chemotherapy, transarterial chemoembolization, and nephrectomy combined treated one giant renal cell carcinoma (T3aN1M1) associated with Xp11.2/TFE3: A case report

Wang P, Zhang X, Shao SH, Wu F, Du FZ, Zhang JF, Zuo ZW, Jiang R

- 10186** Tislelizumab-related enteritis successfully treated with adalimumab: A case report

Chen N, Qian MJ, Zhang RH, Gao QQ, He CC, Yao YK, Zhou JY, Zhou H

- 10193** Treatment of refractory/relapsed extranodal NK/T cell lymphoma with decitabine plus anti-PD-1: A case report
Li LJ, Zhang JY
- 10201** Clinical analysis of pipeline dredging agent poisoning: A case report
Li YQ, Yu GC, Shi LK, Zhao LW, Wen ZX, Kan BT, Jian XD
- 10208** Follicular lymphoma with cardiac involvement in a 90-year-old patient: A case report
Sun YX, Wang J, Zhu JH, Yuan W, Wu L
- 10214** Twin reversed arterial perfusion sequence-a rare and dangerous complication form of monochorionic twins: A case report
Anh ND, Thu Ha NT, Sim NT, Toan NK, Thuong PTH, Duc NM
- 10220** Potential otogenic complications caused by cholesteatoma of the contralateral ear in patients with otogenic abscess secondary to middle ear cholesteatoma of one ear: A case report
Zhang L, Niu X, Zhang K, He T, Sun Y
- 10227** Myeloid sarcoma with ulnar nerve entrapment: A case report
Li DP, Liu CZ, Jeremy M, Li X, Wang JC, Nath Varma S, Gai TT, Tian WQ, Zou Q, Wei YM, Wang HY, Long CJ, Zhou Y
- 10236** Alpha-fetoprotein-producing hepatoid adenocarcinoma of the lung responsive to sorafenib after multiline treatment: A case report
Xu SZ, Zhang XC, Jiang Q, Chen M, He MY, Shen P
- 10244** Acute mesenteric ischemia due to percutaneous coronary intervention: A case report
Ding P, Zhou Y, Long KL, Zhang S, Gao PY
- 10252** Persistent diarrhea with petechial rash - unusual pattern of light chain amyloidosis deposition on skin and gastrointestinal biopsies: A case report
Bilton SE, Shah N, Dougherty D, Simpson S, Holliday A, Sahebjam F, Grider DJ
- 10260** Solitary splenic tuberculosis: A case report
Guo HW, Liu XQ, Cheng YL
- 10266** Coronary artery aneurysms caused by Kawasaki disease in an adult: A case report and literature review
He Y, Ji H, Xie JC, Zhou L
- 10273** Double filtration plasmapheresis for pregnancy with hyperlipidemia in glycogen storage disease type Ia: A case report
Wang J, Zhao Y, Chang P, Liu B, Yao R
- 10279** Treatment of primary tracheal schwannoma with endoscopic resection: A case report
Shen YS, Tian XD, Pan Y, Li H
- 10286** Concrecence of maxillary second molar and impacted third molar: A case report
Su J, Shao LM, Wang LC, He LJ, Pu YL, Li YB, Zhang WY

- 10293** Rare leptin in non-alcoholic fatty liver cirrhosis: A case report
Nong YB, Huang HN, Huang JJ, Du YQ, Song WX, Mao DW, Zhong YX, Zhu RH, Xiao XY, Zhong RX
- 10301** One-stage resection of four genotypes of bilateral multiple primary lung adenocarcinoma: A case report
Zhang DY, Liu J, Zhang Y, Ye JY, Hu S, Zhang WX, Yu DL, Wei YP
- 10310** Ectopic pregnancy and failed oocyte retrieval during *in vitro* fertilization stimulation: Two case reports
Zhou WJ, Xu BF, Niu ZH
- 10317** Malignant peritoneal mesothelioma with massive ascites as the first symptom: A case report
Huang X, Hong Y, Xie SY, Liao HL, Huang HM, Liu JH, Long WJ
- 10326** Subperiosteal orbital hematoma concomitant with abscess in a patient with sinusitis: A case report
Hu XH, Zhang C, Dong YK, Cong TC
- 10332** Postpartum posterior reversible encephalopathy syndrome secondary to preeclampsia and cerebrospinal fluid leakage: A case report and literature review
Wang Y, Zhang Q
- 10339** Sudden extramedullary and extranodal Philadelphia-positive anaplastic large-cell lymphoma transformation during imatinib treatment for CML: A case report
Wu Q, Kang Y, Xu J, Ye WC, Li ZJ, He WF, Song Y, Wang QM, Tang AP, Zhou T
- 10346** Relationship of familial cytochrome P450 4V2 gene mutation with liver cirrhosis: A case report and review of the literature
Jiang JL, Qian JF, Xiao DH, Liu X, Zhu F, Wang J, Xing ZX, Xu DL, Xue Y, He YH
- 10358** COVID-19-associated disseminated mucormycosis: An autopsy case report
Kyuno D, Kubo T, Tsujiwaki M, Sugita S, Hosaka M, Ito H, Harada K, Takasawa A, Kubota Y, Takasawa K, Ono Y, Magara K, Narimatsu E, Hasegawa T, Osanai M
- 10366** Thalidomide combined with endoscopy in the treatment of Cronkhite-Canada syndrome: A case report
Rong JM, Shi ML, Niu JK, Luo J, Miao YL
- 10375** Thoracolumbar surgery for degenerative spine diseases complicated with tethered cord syndrome: A case report
Wang YT, Mu GZ, Sun HL

LETTER TO THE EDITOR

- 10384** Are pregnancy-associated hypertensive disorders so sweet?
Thomopoulos C, Ilias I
- 10387** Tumor invasion front in oral squamous cell carcinoma
Cuevas-González JC, Cuevas-González MV, Espinosa-Cristobal LF, Donohue Cornejo A

ABOUT COVER

Editorial Board Member of *World Journal of Clinical Cases*, Kaleem Ullah, FCPS, MBBS, Assistant Professor, Solid Organ Transplantation and Hepatobiliary Surgery, Pir Abdul Qadir Shah Jeelani Institute of Medical Sciences, Gambat 66070, Sindh, Pakistan. drkaleempk@gmail.com

AIMS AND SCOPE

The primary aim of *World Journal of Clinical Cases* (WJCC, *World J Clin Cases*) is to provide scholars and readers from various fields of clinical medicine with a platform to publish high-quality clinical research articles and communicate their research findings online.

WJCC mainly publishes articles reporting research results and findings obtained in the field of clinical medicine and covering a wide range of topics, including case control studies, retrospective cohort studies, retrospective studies, clinical trials studies, observational studies, prospective studies, randomized controlled trials, randomized clinical trials, systematic reviews, meta-analysis, and case reports.

INDEXING/ABSTRACTING

The WJCC is now abstracted and indexed in Science Citation Index Expanded (SCIE, also known as SciSearch®), Journal Citation Reports/Science Edition, Current Contents®/Clinical Medicine, PubMed, PubMed Central, Scopus, Reference Citation Analysis, China National Knowledge Infrastructure, China Science and Technology Journal Database, and Superstar Journals Database. The 2022 Edition of Journal Citation Reports® cites the 2021 impact factor (IF) for WJCC as 1.534; IF without journal self cites: 1.491; 5-year IF: 1.599; Journal Citation Indicator: 0.28; Ranking: 135 among 172 journals in medicine, general and internal; and Quartile category: Q4. The WJCC's CiteScore for 2021 is 1.2 and Scopus CiteScore rank 2021: General Medicine is 443/826.

RESPONSIBLE EDITORS FOR THIS ISSUE

Production Editor: *Xu Guo*; Production Department Director: *Xiang Li*; Editorial Office Director: *Jin-Lei Wang*.

NAME OF JOURNAL

World Journal of Clinical Cases

ISSN

ISSN 2307-8960 (online)

LAUNCH DATE

April 16, 2013

FREQUENCY

Thrice Monthly

EDITORS-IN-CHIEF

Bao-Gan Peng, Jerzy Tadeusz Chudek, George Kontogeorgos, Maurizio Serati, Ja Hyeon Ku

EDITORIAL BOARD MEMBERS

<https://www.wjnet.com/2307-8960/editorialboard.htm>

PUBLICATION DATE

October 6, 2022

COPYRIGHT

© 2022 Baishideng Publishing Group Inc

INSTRUCTIONS TO AUTHORS

<https://www.wjnet.com/bpg/gerinfo/204>

GUIDELINES FOR ETHICS DOCUMENTS

<https://www.wjnet.com/bpg/GerInfo/287>

GUIDELINES FOR NON-NATIVE SPEAKERS OF ENGLISH

<https://www.wjnet.com/bpg/gerinfo/240>

PUBLICATION ETHICS

<https://www.wjnet.com/bpg/GerInfo/288>

PUBLICATION MISCONDUCT

<https://www.wjnet.com/bpg/gerinfo/208>

ARTICLE PROCESSING CHARGE

<https://www.wjnet.com/bpg/gerinfo/242>

STEPS FOR SUBMITTING MANUSCRIPTS

<https://www.wjnet.com/bpg/GerInfo/239>

ONLINE SUBMISSION

<https://www.f6publishing.com>



Subperiosteal orbital hematoma concomitant with abscess in a patient with sinusitis: A case report

Xi-Hao Hu, Chi Zhang, Yu-Ke Dong, Tie-Chuan Cong

Specialty type:

Otorhinolaryngology

Provenance and peer review:

Unsolicited article; Externally peer reviewed.

Peer-review model:

Single blind

Peer-review report's scientific quality classification

Grade A (Excellent): 0
Grade B (Very good): 0
Grade C (Good): C, C
Grade D (Fair): 0
Grade E (Poor): 0

P-Reviewer: Cerwenka H, Austria;
Lim SC, South Korea

Received: May 29, 2022

Peer-review started: May 29, 2022

First decision: June 27, 2022

Revised: July 10, 2022

Accepted: August 25, 2022

Article in press: August 25, 2022

Published online: October 6, 2022



Xi-Hao Hu, Chi Zhang, Yu-Ke Dong, Tie-Chuan Cong, Department of Otolaryngology-Head & Neck Surgery, Peking University First Hospital, Beijing 100034, China

Yu-Ke Dong, Department of Otolaryngology-Head & Neck Surgery, Zhengzhou Central Hospital, Zhengzhou 450007, Henan Province, China

Corresponding author: Tie-Chuan Cong, MD, Associate Chief Physician, Department of Otolaryngology-Head & Neck Surgery, Peking University First Hospital, No. 1 Xi'anmen Street, West District, Beijing 100034, China. cong tiechuan@bjmu.edu.cn

Abstract

BACKGROUND

Sinusitis-derived subperiosteal orbital collection is uncommon and is usually diagnosed as subperiosteal orbital abscess or, rarely, as hematoma. We report a unique and even rarer case of subperiosteal orbital collection, which is actually a complication of hematoma and abscess.

CASE SUMMARY

A 26-year-old female presented with left eyeball pain and ipsilateral chemosis. She had no history of head trauma or upper respiratory infection. Her blood cell count showed an increase in leukocytes. Fiberoptic rhinolaryngoscopy revealed only mucosal edema of the left olfactory crest without apparent discharge. The computed tomography scan results showed an opaque left posterior ethmoid cell with a thickened bony shell and fusiform changes in the periosteal elevation of the medial wall of the left orbit. Emergent surgery revealed an ethmoid mucocoele complicated with subperiosteal orbital hematoma and abscess. The pathology of the lamina papyracea between the mucocoele and subperiosteal collection was necrotic, and the overlying mucosa was de-epithelialized.

CONCLUSION

Subperiosteal orbital hematoma with abscess in a patient with sinusitis adds to the current knowledge of orbital complications of sinusitis.

Key Words: Subperiosteal orbital hematoma; Abscess; Sinusitis; Mucocoele; Surgery; Case report

©The Author(s) 2022. Published by Baishideng Publishing Group Inc. All rights reserved.

Core Tip: As a differential diagnosis of subperiosteal orbital collection, subperiosteal orbital hematoma concomitant with abscess needs to be taken into consideration. Surgery is advocated for the diagnosis and treatment of such pathology. This report adds to current knowledge regarding the orbital complications of sinusitis.

Citation: Hu XH, Zhang C, Dong YK, Cong TC. Subperiosteal orbital hematoma concomitant with abscess in a patient with sinusitis: A case report. *World J Clin Cases* 2022; 10(28): 10326-10331

URL: <https://www.wjgnet.com/2307-8960/full/v10/i28/10326.htm>

DOI: <https://dx.doi.org/10.12998/wjcc.v10.i28.10326>

INTRODUCTION

Subperiosteal orbital collection caused by sinus infection is usually diagnosed with subperiosteal orbital abscess (SPOA). In recent years, another diagnostic entity of subperiosteal orbital hematoma that shows clinical manifestations similar to those of SPOA has been sporadically reported in patients with sinusitis or sinus mucocele, and it is believed that the disease could be misdiagnosed as an SPOA if only medically treated[1,2]. Additionally, subperiosteal orbital hematoma mixed with abscess is logically possible when infection spreads to the subperiosteal hematoma. Here, we report a rare condition that was identified in a patient with ethmoid mucocele and subperiosteal orbital collection.

CASE PRESENTATION

Chief complaints

A 26-year-old female presented with left eyeball pain for 2 d (the timeline is shown in Table 1).

History of present illness

The patient had a left-sided headache two days before the eyeball pain. She was afebrile and did not display diplopia, visual loss, or any discomfort related to her nose.

History of past illness

The patient was otherwise healthy and had no history of head trauma, upper respiratory infection, vascular disease, or coagulation disorder.

Personal and family history

The patient had no relevant personal or family history.

Physical examination

Ophthalmologic examination showed periorbital edema and conjunctival chemosis in the left eye. Ocular movements of the same eye were normal in all directions. Funduscopy examination yielded results within the normal range. Fiberoptic rhinolaryngoscopy revealed congestion of the left olfactory mucosa without purulent discharge.

Laboratory examinations

The patient's white blood cell count was 10400/mm³, and her C-reactive protein level was within the normal range.

Imaging examinations

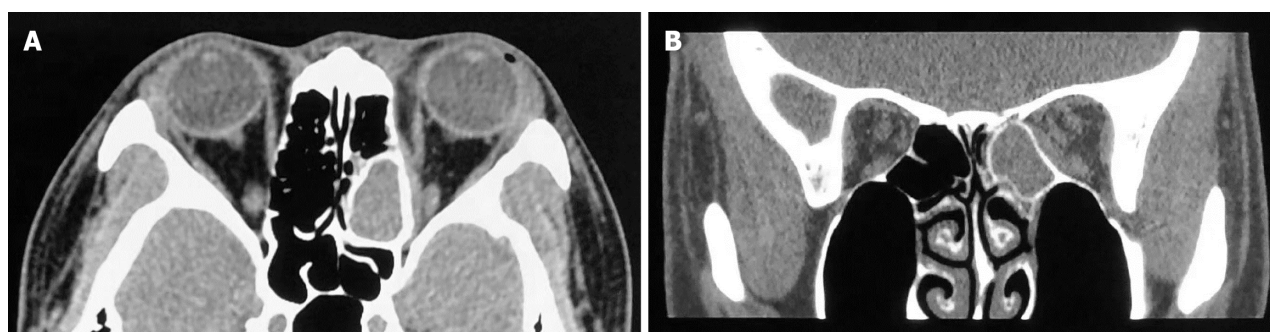
Computed tomography with a soft window showed an opaque left posterior ethmoid cell with a thickened bony shell (Figure 1). In contrast to the cell, the orbital periosteum of the lamina papyracea exhibited fusiform changes with isodensity. The lamina papyracea *per se* showed no sign of erosion. The medial rectus was oppressed and shifted outwards (Figure 1B).

FINAL DIAGNOSIS

The final diagnosis of the case was infection of the ethmoid mucocele complicated with subperiosteal orbital collection.

Table 1 Timeline of events

Event	Timeline
Presented with left eyeball pain	-2 d
Computed tomography showed an opaque left posterior ethmoid cell with thickened bony shell	-1 d
Admitted to our department and received endoscopic endonasal sinus surgery	0 d
Free of symptoms	1 d
Patient was discharged	5 d
Surgical cavity was completely epithelialized	2 mo



DOI: 10.12998/wjcc.v10.i28.10326 Copyright ©The Author(s) 2022.

Figure 1 Axial and coronal noncontrast computed tomography scans with soft windows showing an opacified left posterior ethmoidal cell with a thickened bony shell. Across the lamina papyracea was a lesion with a fusiform change and isodensity. A: Axial plane; B: Coronal plane.

TREATMENT

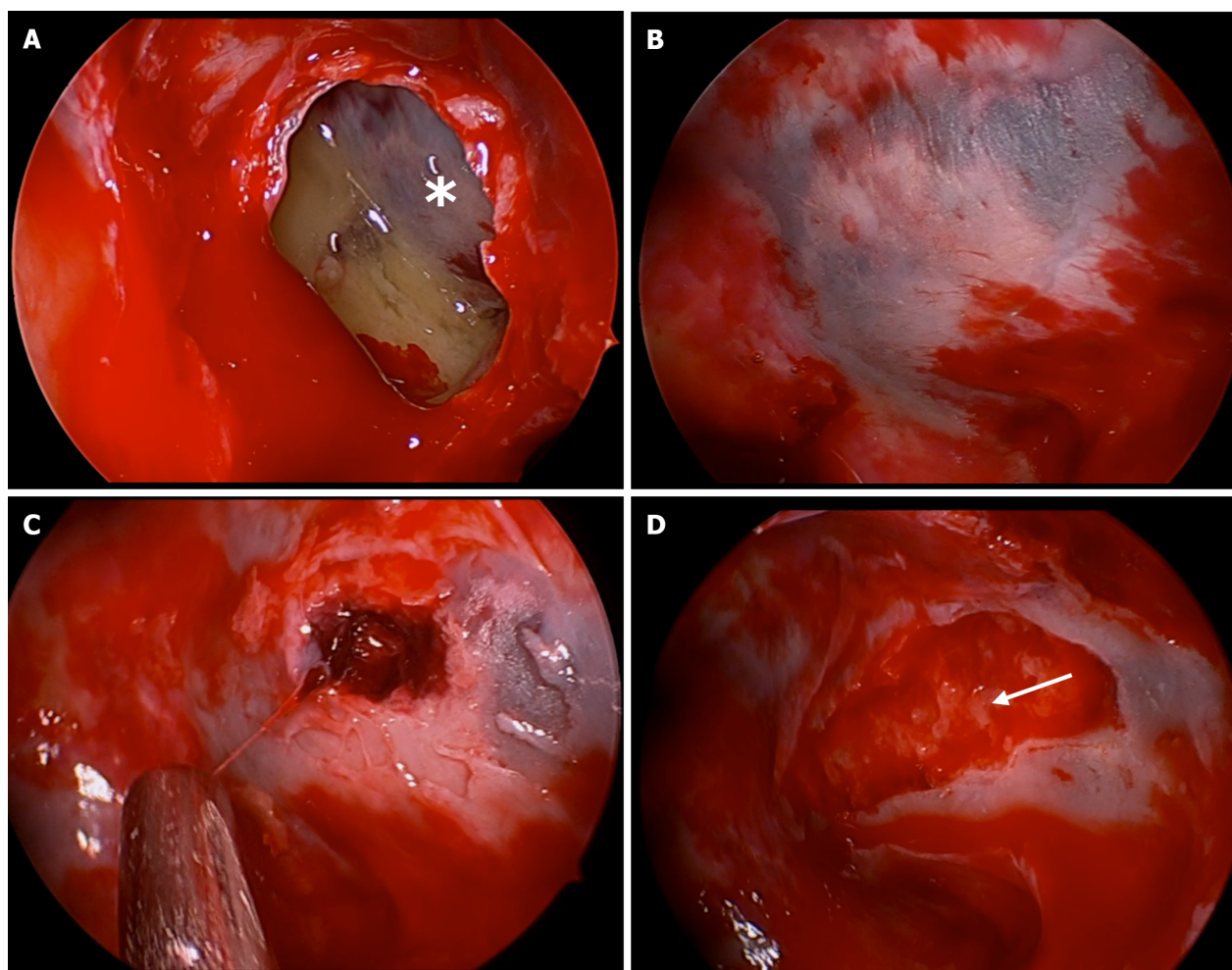
Ceftriaxone was administered intravenously followed by endoscopic endonasal sinus surgery. Mucocele was ascertained, and purulent discharge with some caseous material was aspirated after marsupialization of the opacified posterior ethmoid sinus (Figure 2). The lamina papyracea exposed in the mucocele cavity, surprisingly, showed an altered blue and white area in which the mucosal lining was devascularized (Figure 2A and B). Medial orbital wall decompression was then performed, and a dark blood clot surrounded and even partially covered by pus appeared inside the exposed subperiosteal space, causing the papyracea to take on the specific blue and white hue. The clot appeared to be partially lysed, and it was easily shaped into threads when aspirated (Figure 2C). During the process of decompression, pus mixed with blood subsequently oozed into the ethmoid cavity from around the blood clot (Figure 2D). Complete drainage of the collection was ensured by applying external pressure to the orbit.

OUTCOME AND FOLLOW-UP

The patient was free of symptoms within 24 h after surgery. Magnetic resonance imaging on postoperative day 5 showed no sign of liquid accumulation in the medial wall of the left orbit (Figure 3A), and the patient was discharged on the same day. Histopathological examination demonstrated de-epithelialized mucosa with bone necrosis of the lamina papyracea. No microorganisms grew from either the subperiosteal orbital or ethmoidal discharges. At two-month follow-up, the surgical cavity was completely epithelialized, and the patient recovered fully (Figure 3B and C).

DISCUSSION

Orbital complications of sinusitis, according to Chandler's modified classification, are divided into five groups: preseptal cellulitis, orbital cellulitis, subperiosteal abscess, orbital abscess, and cavernous sinus thrombosis. The most common sinogenic orbital complications appear to originate in the ethmoid sinuses[3-5] and are mainly related to rhinosinusitis or, uncommonly, a mucocele. If not treated in a timely manner, mucocele of the paranasal sinus can induce cranial and/or orbital complications. In



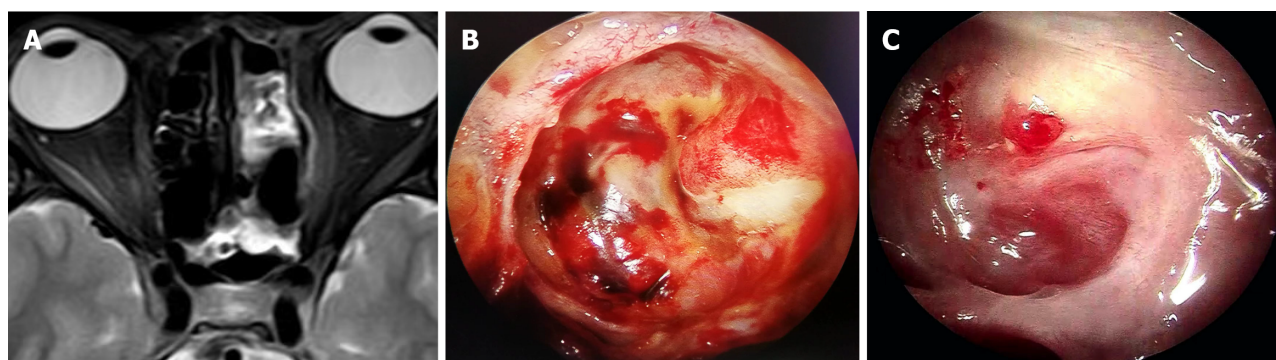
DOI: 10.12998/wjcc.v10.i28.10326 Copyright ©The Author(s) 2022.

Figure 2 Endoscopic views of the mucocoele and the subperiosteal orbital collection. A: Marsupialization of the mucocoele of the left posterior ethmoid sinus. An asterisk indicates the lamina papyracea; B: The lamina papyracea is covered with thin devitalized mucosa and has a blue and white appearance with a geographic pattern. The surrounding mucosa rapidly became hyperemic after the cavity pressure was eliminated; C: A blood clot was uncovered under the blue area of the lamina papyracea, and the periorbita was subsequently exposed; D: Pus (white arrow) oozed from around the blood clot.

addition to direct expansion and compression to the orbit, orbital complications of complicated mucocoele can also be caused by infection directly through congenital or acquired bony dehiscence or *via* the neurovascular foramina or through the local valveless veins of the thin lamina papyracea resulting from thrombophlebitic or embolic conditions[6]. Subperiosteal abscess develops between the orbital bone and periorbita, and up to 90% of SPOA cases are caused by complicated sinusitis[7]. The diagnosis of subperiosteal abscess is mainly based on clinical manifestation and radiographic imaging and is generally confirmed by surgical drainage.

SPOA, however, is only one form of subperiosteal orbital fluid collection that can also present as subperiosteal orbital hematoma. Subperiosteal orbital hematoma is mostly caused by trauma. Nontraumatic subperiosteal orbital hematoma, mostly associated with increased intracranial pressure and bleeding disorders that cause rupture and bleeding of subperiosteal venules[8], is occasionally described in the literature. Sinus infection-related subperiosteal hematoma occurs even more rarely. To date, just over 20 cases of subperiosteal hematoma associated with sinusitis have been surgically identified in the literature, including 4 cases of sinus mucocoele[1,2,8,9]. Some authors believed subperiosteal hematoma was an unusual complication of sinusitis. In patients with subperiosteal hematoma associated with sinusitis, no pus was detected, and the results of the hematoma culture were mainly negative.

To the best of our knowledge, this is the first report of subperiosteal orbital hematoma concomitant with abscess occurring in the same potential anatomical space in an adult patient with complicated sinus infection. We postulate that the pathogenesis of this condition probably involves the rupture of small veins crossing between the orbital bony wall and the periorbita due to adjacent sinus inflammation and the subsequent formation of hematoma, the early spread of pathogenic microorganisms directly through the lamina papyracea to involve the subperiosteal orbital space, and the formation of a localized abscess surrounding the blood clot prior to its complete lysis. Concomitant hematoma and



DOI: 10.12998/wjcc.v10.i28.10326 Copyright ©The Author(s) 2022.

Figure 3 Postoperative magnetic resonance imaging and follow-up with endoscopy. A: T2 magnetic resonance imaging scan on the 5th postoperative day shows hyperintensity of the involved medial periorbital of the left orbit on T2-weighted imaging, revealing sufficient drainage of the subperiosteal orbital abscess; B: Endoscopic examination on the 11th postoperative day shows a slightly bulging periorbital that was apparently healthy; C: Endoscopic reevaluation two months after the operation revealed nearly complete epithelization of the lamina papyracea with a small cherry granuloma.

abscess in the same area are probably transitory conditions and show the process through which the hematoma evolves completely into an abscess. In our case, the de-epithelialized mucosa of the mucocoele and the necrotic change in the lamina papyracea involved might indicate a role of direct extension in the development of a subperiosteal abscess.

Several studies have shown that the age of the patient is an independent risk factor with respect to the choice of treatment for SPOA. Harris found that for patients less than 9 years old without visual impairment, emergent or even urgent surgery was not mandatory as the first-line treatment. Conversely, these patients could be initially administered medical treatment concomitantly with watchful observation. However, in cases of mixed infection with aerobes and anaerobes, which are common in patients more than 9 years old, operative intervention should be initially performed[10,11]. For adult patients with SPOA, endoscopic endonasal sinus surgery is currently advocated as the first choice of treatment due to its advantages of minimal invasion, no facial scarring, and shortened hospital course compared with the external orbital approach. Ethmoidectomy usually suffices when obvious dehiscence of the lamina papyracea is apparent[12]. If dehiscence is not detected during the surgery, the lamina papyracea should be opened for drainage. However, there is controversy regarding the extent of removal of the lamina papyracea. In the early days of endoscopic sinus surgical practice, the lamina papyracea was cracked but not removed[12], or swung back and then medialized in a “swing door” pattern[13], or partially resected[14]. Recently, wide removal of the lamina papyracea with complete ethmoidectomy was performed with satisfactory results[15]. The rationale for wide resection was supported by a report by Ragab *et al*[6]. In their report, bone sequestrum was identified in all eight cases with the presence of cocci in half; this explained the failure of medical treatment and the necessity for surgery.

In the case reported here, sequestrum was observed histologically with no pathogens identified, in concordance with the cases reported by Eviatar *et al*[5], who observed bone destruction and resorption in the lamina papyracea in five of nine children with acute rhinosinusitis and SPOA. These pathological findings strengthen the theory of direct spread for the pathogenesis of SPOA.

As an approach to diagnosing and treating subperiosteal abscess in patients with sinus mucocoele, surgical intervention is advocated, consistent with the treatment modality recommended for cases of subperiosteal orbital hematoma caused by sinus infection. The recovery from subperiosteal hematoma and abscess in the case reported here was uneventful after the surgery.

CONCLUSION

Subperiosteal orbital hematoma concomitant with abscess in patients with sinusitis has not been reported previously. It can cause necrotic bony changes, indicating a need for timely surgical intervention.

ACKNOWLEDGEMENTS

We thank the patient for participating in the report.

FOOTNOTES

Author contributions: Cong TC was the patient's surgeon and drafted the manuscript; Hu XH, Zhang C, and Dong YK attributed to the data collection and critically revised the manuscript; all authors read and approved the final manuscript.

Informed consent statement: Informed written consent was obtained from the patients for the publication of this report and any accompanying images.

Conflict-of-interest statement: The authors declare that they have no conflict of interest.

CARE Checklist (2016) statement: The authors have read the CARE Checklist (2016), and the manuscript was prepared and revised according to the CARE Checklist (2016).

Open-Access: This article is an open-access article that was selected by an in-house editor and fully peer-reviewed by external reviewers. It is distributed in accordance with the Creative Commons Attribution NonCommercial (CC BY-NC 4.0) license, which permits others to distribute, remix, adapt, build upon this work non-commercially, and license their derivative works on different terms, provided the original work is properly cited and the use is non-commercial. See: <https://creativecommons.org/licenses/by-nc/4.0/>

Country/Territory of origin: China

ORCID number: Xi-Hao Hu 0000-0002-9872-0510; Chi Zhang 0000-0003-0944-1761; Yu-Ke Dong 0000-0002-3502-6353; Tie-Chuan Cong 0000-0001-8748-5992.

S-Editor: Chen YL

L-Editor: A

P-Editor: Chen YL

REFERENCES

- 1 **Park HW**, Lee BJ, Chung YS. Orbital subperiosteal hematoma associated with sinus infection. *Rhinology* 2010; **48**: 117-122 [PMID: 20502746 DOI: 10.4193/Rhin09.008]
- 2 **Mozaffari M**, Boyd E, Whiteside O. Subperiosteal haematoma of the orbit secondary to frontal sinusitis. *BMJ Case Rep* 2018; **2018** [PMID: 30232074 DOI: 10.1136/bcr-2018-226476]
- 3 **Sciarretta V**, Demattè M, Farneti P, Fornaciari M, Corsini I, Piccin O, Saggese D, Fernandez JJ. Management of orbital cellulitis and subperiosteal orbital abscess in pediatric patients: A ten-year review. *Int J Pediatr Otorhinolaryngol* 2017; **96**: 72-76 [PMID: 28390618 DOI: 10.1016/j.ijporl.2017.02.031]
- 4 **Schulte DL**, Kasperbauer JL. Safety of paranasal sinus surgery in patients with cystic fibrosis. *Laryngoscope* 1998; **108**: 1813-1815 [PMID: 9851496 DOI: 10.1097/00005537-199812000-00009]
- 5 **Eviatar E**, Sandbank J, Kleid S, Gavriel H. The role of osteitis of the lamina papyracea in the formation of subperiosteal orbital abscess in young children. *Int J Pediatr Otorhinolaryngol* 2014; **78**: 2267-2270 [PMID: 25465453 DOI: 10.1016/j.ijporl.2014.10.031]
- 6 **Ragab A**, Samaka RM. Is pyogenic ethmoidal osteitis the cause of complicated rhinosinusitis with subperiosteal orbital abscess? *Eur Arch Otorhinolaryngol* 2010; **267**: 1231-1237 [PMID: 20069309 DOI: 10.1007/s00405-009-1197-z]
- 7 **Erickson BP**, Lee WW. Orbital Cellulitis and Subperiosteal Abscess: A 5-year Outcomes Analysis. *Orbit* 2015; **34**: 115-120 [PMID: 25867948 DOI: 10.3109/01676830.2014.950286]
- 8 **McNab AA**. Nontraumatic orbital hemorrhage. *Surv Ophthalmol* 2014; **59**: 166-184 [PMID: 24359805 DOI: 10.1016/j.survophthal.2013.07.002]
- 9 **Woo KI**, Kim YD. Subperiosteal hematoma of the orbit associated with sinusitis. *Korean J Ophthalmol* 1997; **11**: 118-122 [PMID: 9510655 DOI: 10.3341/kjo.1997.11.2.118]
- 10 **Liao JC**, Harris GJ. Subperiosteal abscess of the orbit: evolving pathogens and the therapeutic protocol. *Ophthalmology* 2015; **122**: 639-647 [PMID: 25439602 DOI: 10.1016/j.ophtha.2014.09.009]
- 11 **Garcia GH**, Harris GJ. Criteria for nonsurgical management of subperiosteal abscess of the orbit: analysis of outcomes 1988-1998. *Ophthalmology* 2000; **107**: 1454-6; discussion 1457 [PMID: 10919887 DOI: 10.1016/s0161-6420(00)00242-6]
- 12 **Manning SC**. Endoscopic management of medial subperiosteal orbital abscess. *Arch Otolaryngol Head Neck Surg* 1993; **119**: 789-791 [PMID: 8318211 DOI: 10.1001/archotol.1993.01880190085018]
- 13 **Malik V**, Khwaja S, De Carpentier J. Immediate lamina papyracea reconstruction during endoscopic sinus surgery for surgically managed subperiosteal abscess in children. *Laryngoscope* 2006; **116**: 835-838 [PMID: 16652100 DOI: 10.1097/01.mlg.0000204757.91014.81]
- 14 **Froehlich P**, Pransky SM, Fontaine P, Stearns G, Morgon A. Minimal endoscopic approach to subperiosteal orbital abscess. *Arch Otolaryngol Head Neck Surg* 1997; **123**: 280-282 [PMID: 9076233 DOI: 10.1001/archotol.1997.01900030054006]
- 15 **Gavriel H**, Jabarin B, Israel O, Eviatar E. Conservative Management for Subperiosteal Orbital Abscess in Adults: A 20-Year Experience. *Ann Otol Rhinol Laryngol* 2018; **127**: 162-166 [PMID: 29298507 DOI: 10.1177/0003489417751155]



Published by **Baishideng Publishing Group Inc**
7041 Koll Center Parkway, Suite 160, Pleasanton, CA 94566, USA

Telephone: +1-925-3991568

E-mail: bpgoffice@wjgnet.com

Help Desk: <https://www.f6publishing.com/helpdesk>

<https://www.wjgnet.com>

