

August 10, 2022

Editors and reviewers,

World Journal of Clinical Cases

Re: Manuscript Ref. No.: 78590

Editorial Office's Comments

(1) Science editor:

The manuscript has been peer-reviewed, and it's ready for the first decision.

Language Quality: Grade B (Minor language polishing)

Scientific Quality: Grade C (Good)

Response: Dear Science Editor, thank you for your review of this manuscript. About the language polishing, we had sent this manuscript to AJE (American Journal Experts) for secondary language editing. The point-by-point answers to each reviewer's comments are addressed as follows. Thank you again.

(2) Company editor-in-chief:

I have reviewed the Peer-Review Report, the full text of the manuscript, and the relevant ethics documents, all of which have met the basic publishing requirements of the World Journal of Clinical Cases, and the manuscript is conditionally accepted. I have sent the manuscript to the author(s) for its revision according to the Peer-Review Report, Editorial Office's comments and the Criteria for Manuscript Revision by Authors. Before final acceptance, uniform presentation should be used for figures showing the same or similar contents; for example, "Figure 1 Pathological changes of atrophic gastritis after treatment. A: ...; B: ...; C: ...; D: ...; E: ...; F: ...; G: ...". Please provide the original figure documents. Please prepare and arrange the figures using PowerPoint to ensure that all graphs or arrows or text portions can be reprocessed by the editor. In order to respect and protect the author's intellectual property rights and prevent others from misappropriating figures without the author's authorization or abusing figures without indicating the source, we will indicate the author's copyright for figures originally generated by the author, and if the author has used a figure published elsewhere or that is copyrighted, the author needs to be authorized by the previous publisher or the copyright holder and/or indicate the reference source and copyrights. Please check and confirm whether the figures are original (i.e. generated de novo by the author(s) for this paper). If the picture is 'original', the author needs to add the following copyright information to the bottom right-hand side of the picture in PowerPoint

(PPT): Copyright ©The Author(s) 2022. Authors are required to provide standard three-line tables, that is, only the top line, bottom line, and column line are displayed, while other table lines are hidden. The contents of each cell in the table should conform to the editing specifications, and the lines of each row or column of the table should be aligned. Do not use carriage returns or spaces to replace lines or vertical lines and do not segment cell content. Please upload the approved grant application form(s) or funding agency copy of any approval document(s). Before final acceptance, when revising the manuscript, the author must supplement and improve the highlights of the latest cutting-edge research results, thereby further improving the content of the manuscript. To this end, authors are advised to apply a new tool, the RCA. RCA is an artificial intelligence technology-based open multidisciplinary citation analysis database. In it, upon obtaining search results from the keywords entered by the author, "Impact Index Per Article" under "Ranked by" should be selected to find the latest highlight articles, which can then be used to further improve an article under preparation/peer-review/revision. Please visit our RCA database for more information at: <https://www.referencecitationanalysis.com/>.

Response: Dear Editor-in-Chief, many thanks for your endeavor on this manuscript.

1. Our figures use uniform presentation for showing similar contents. Figure 1(A.B.C.D.E.F): A. Preoperative scrotal lipoma image; B, C, D The CT images showed liposis of the lower abdomen, perineum and thigh but no liposis in the chest wall or pelvic cavity. E, F MRI image showing the same findings. Figure 2(A.B.C.D.E.F): A. Incision of the scrotum: the testis and spermatic cord were squeezed, the boundary between the tumour and the tumour was clear, and slight adherence was evident; B. Right scrotal lipoma. C. Left scrotal lipoma. D, E. Bilateral scrotal lipoma postoperative specimen and weighing (approximately 995 g). F. HE staining (40 ×).
2. Our figures are all original, we have added the copyright information and uploaded the original PPT file. We had add the following copyright information to the bottom right-hand side of the picture in PowerPoint (PPT): Copyright ©The Author(s) 2022.
3. We had provided standard three-line tables. The contents of each cell in the table is conformed to the editing specifications, and the lines of each row or column of the table is aligned.
4. We already had upload the approved grant application form(s) or funding agency copy of any approval document(s), Including 3 fund documents.

Point-by-point response to reviewer's comments:

Reviewer #1:

Scientific Quality: Grade B (Very good)

Language Quality: Grade B (Minor language polishing)

Conclusion: Accept (General priority)

Specific Comments to Authors:

1) Comments: The authors described a rare case with Giant bilateral scrotal lipoma with abnormal somatic fat distribution. You also reviewed the literature.

Response: Thank you for your valuable comments. A 66-year-old male with a giant scrotal mass was evaluated in this manuscript. B-ultrasound, computed tomography (CT) and magnetic resonance imaging (MRI) examinations showed typical lipoma-like changes. Surgical treatment was performed. The tumor squeezed the bilateral testis, epididymis and spermatic cord tightly against the inner wall of the scrotum, and the boundary between the tumor and the tumor was obvious. The capsules of both tumors were intact, lobulated, light yellow, and soft. The cut surface was off-white and slightly tough. The total weight of bilateral scrotal tumors reached 995 g. Bilateral scrotal lipomas were confirmed by postoperative pathology. Abnormal somatic fat distribution was confirmed by image findings. The published English literature was reviewed, and a history of inguinal or pelvic surgery was reported in 6 studies (total 21 cases). These articles were published between 1927 to 2021, in which we couldn't find that there was giant bilateral scrotal lipoma with abnormal fat distribution. From this case, it will be helpful for the search for the etiology and treatment of this type of disease.

2) Comments: This paper presents a case with the heaviest bilateral scrotal lipoma and the longest postoperative follow-up time in English literature.

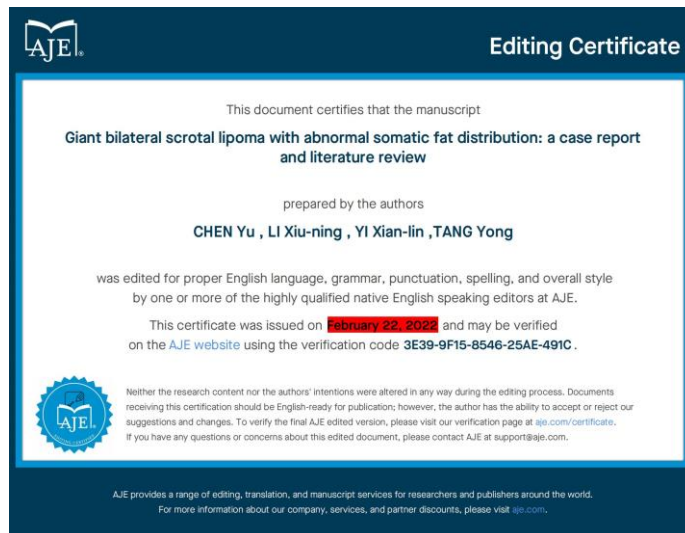
Response: Scrotal lipoma are very rare, and only 6 studies (total 21 cases) have been reported in English-language. A large right scrotal mass that weighed 1100 g was reported (unilateral scrotum). The lesion described in the current report is the heaviest bilateral scrotal lipoma in the English literature, which was 995 g in weight. The patient was followed up to August 8, 2022, for more than two years, and still alive with no recurrence was observed. To our knowledge, this is the longest reported postoperative follow-up time.

3) Comments: The paper is well written and the quality is excellent. However, you should correct some minor spelling mistakes in your paper.

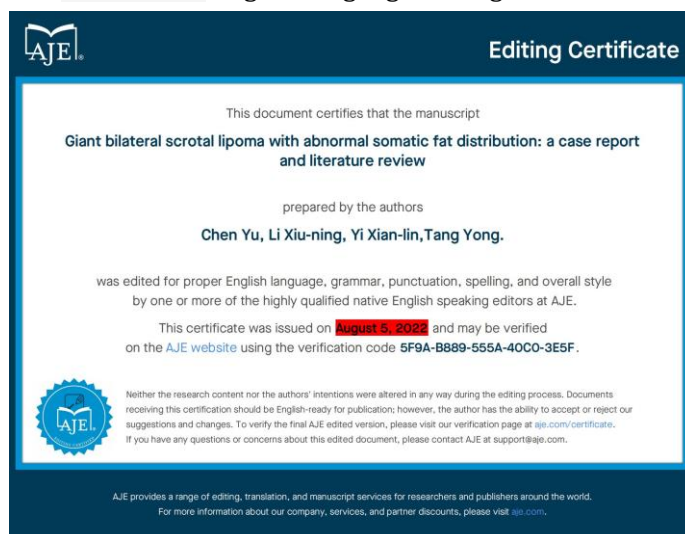
Response: This manuscript was edited for proper English language, grammar, punctuation, spelling, and overall style by one or more of the highly qualified native English speaking

editors at AJE(American Journal Experts) on february 22, 2022.When we submitted this manuscript to the World Journal of Clinical Cases,still had some minor spelling mistakes.Now, we submit it again to AJE for secondary editing at August 5, 2022.If the manuscript still has spelling or other mistakes,we will submit it for editing again.

The first time English language editing



The second time English language editing



Reviewer #2:

Scientific Quality: Grade C (Good)

Language Quality: Grade B (Minor language polishing)

Conclusion: Accept (General priority)

Specific Comments to Authors: Dear Authors, interesting manuscript. Well written and good quality of images. Congratulations

Response: Thank you very much. The main defect of this study is case report and there is no genomic data(Line177-178/Page8,Manuscript). We are aware of this defect and intend to analyze it further.