

World Journal of *Clinical Cases*

World J Clin Cases 2022 December 6; 10(34): 12462-12803



Contents

Thrice Monthly Volume 10 Number 34 December 6, 2022

FIELD OF VISION

- 12462 Problematics of neurosurgical service during the COVID-19 pandemic in Slovenia
Munda M, Bosnjak R, Velnar T

MINIREVIEWS

- 12470 Circulating angiotensin converting enzyme 2 and COVID-19
Leowattana W, Leowattana T, Leowattana P
- 12484 Evaluation of gut dysbiosis using serum and fecal bile acid profiles
Monma T, Iwamoto J, Ueda H, Tamamushi M, Kakizaki F, Konishi N, Yara S, Miyazaki T, Hirayama T, Ikegami T, Honda A
- 12494 Pediatric kidney transplantation during the COVID-19 pandemic
Tamura H

ORIGINAL ARTICLE

Clinical and Translational Research

- 12500 *Coptis*, *Pinellia*, and *Scutellaria* as a promising new drug combination for treatment of *Helicobacter pylori* infection
Yu Z, Sheng WD, Yin X, Bin Y

Case Control Study

- 12515 Effects of illness perception on negative emotions and fatigue in chronic rheumatic diseases: Rumination as a possible mediator
Lu Y, Jin X, Feng LW, Tang C, Neo M, Ho RC

Retrospective Study

- 12532 Significance of incidental focal fluorine-18 fluorodeoxyglucose uptake in colon/rectum, thyroid, and prostate: With a brief literature review
Lee H, Hwang KH
- 12543 Follow-up study on ThinPrep cytology test-positive patients in tropical regions
Chen YC, Liang CN, Wang XF, Wang MF, Huang XN, Hu JD
- 12551 Effect of teach-back health education combined with structured psychological nursing on adverse emotion and patient cooperation during ^{99m}Tc -3PRGD2.SPECT/CT
Gong WN, Zhang YH, Niu J, Li XB
- 12559 Nosocomial infection and spread of SARS-CoV-2 infection among hospital staff, patients and caregivers
Cheng CC, Fann LY, Chou YC, Liu CC, Hu HY, Chu D

Observational Study

- 12566** Effectiveness and safety of generic and brand direct acting antivirals for treatment of chronic hepatitis C
Abdulla M, Al Ghareeb AM, Husain HAHY, Mohammed N, Al Qamish J
- 12578** Influence of group B *streptococcus* and vaginal cleanliness on the vaginal microbiome of pregnant women
Liao Q, Zhang XF, Mi X, Jin F, Sun HM, Wang QX

Randomized Controlled Trial

- 12587** Clinical study on tri-tongue acupuncture combined with low-frequency electrical stimulation for treating post-stroke dysarthria
Man B, Li WW, Xu JF, Wang Q

META-ANALYSIS

- 12594** Three-dimensional time-of-flight magnetic resonance angiography combined with high resolution T2-weighted imaging in preoperative evaluation of microvascular decompression
Liang C, Yang L, Zhang BB, Guo SW, Li RC

CASE REPORT

- 12605** Acute cytomegalovirus hepatitis in an immunocompetent patient: A case report
Wang JP, Lin BZ, Lin CL, Chen KY, Lin TJ
- 12610** Long-term results of extended Boari flap technique for management of complete ureteral avulsion: A case report
Zhong MZ, Huang WN, Huang GX, Zhang EP, Gan L
- 12617** Amyloid β -related angiitis of the central nervous system occurring after COVID-19 vaccination: A case report
Kizawa M, Iwasaki Y
- 12623** Pseudoileus caused by primary visceral myopathy in a Han Chinese patient with a rare *MYH11* mutation: A case report
Li N, Song YM, Zhang XD, Zhao XS, He XY, Yu LF, Zou DW
- 12631** Emergent use of tube tip in pharynx technique in "cannot intubate cannot oxygenate" situation: A case report
Lin TC, Lai YW, Wu SH
- 12637** Inflammatory myofibroblastic tumor of the central nervous system: A case report
Su ZJ, Guo ZS, Wan HT, Hong XY
- 12648** Atypical aggressive vertebral hemangioma of the sacrum with postoperative recurrence: A case report
Wang GX, Chen YQ, Wang Y, Gao CP
- 12654** Closed reduction of hip dislocation associated with ipsilateral lower extremity fractures: A case report and review of the literature
Xu Y, Lv M, Yu SQ, Liu GP

- 12665** Repair of a large patellar cartilage defect using human umbilical cord blood-derived mesenchymal stem cells: A case report
Song JS, Hong KT, Song KJ, Kim SJ
- 12671** Abdominal bronchogenic cyst: A rare case report
Li C, Zhang XW, Zhao CA, Liu M
- 12678** Malignant fibrous histiocytoma of the axilla with breast cancer: A case report
Gao N, Yang AQ, Xu HR, Li L
- 12684** Rapid hemostasis of the residual inguinal access sites during endovascular procedures: A case report
Kim H, Lee K, Cho S, Joh JH
- 12690** Formation of granulation tissue on bilateral vocal cords after double-lumen endotracheal intubation: A case report
Xiong XJ, Wang L, Li T
- 12696** Giant cellular leiomyoma in the broad ligament of the uterus: A case report
Yan J, Li Y, Long XY, Li DC, Li SJ
- 12703** Pomolidomide for relapsed/refractory light chain amyloidosis after resistance to both bortezomib and daratumumab: A case report
Li X, Pan XH, Fang Q, Liang Y
- 12711** Ureteral- artificial iliac artery fistula: A case report
Feng T, Zhao X, Zhu L, Chen W, Gao YL, Wei JL
- 12717** How to manage isolated tension non-surgical pneumoperitoneum during bronchoscopy? A case report
Baima YJ, Shi DD, Shi XY, Yang L, Zhang YT, Xiao BS, Wang HY, He HY
- 12726** Amiodarone-induced muscle tremor in an elderly patient: A case report
Zhu XY, Tang XH, Yu H
- 12734** Surgical treatment of Pitt-Hopkins syndrome associated with strabismus and early-onset myopia: Two case reports
Huang Y, Di Y, Zhang XX, Li XY, Fang WY, Qiao T
- 12742** Massive low-grade myxoid liposarcoma of the floor of the mouth: A case report and review of literature
Kugimoto T, Yamagata Y, Ohsako T, Hirai H, Nishii N, Kayamori K, Ikeda T, Harada H
- 12750** Gingival enlargement induced by cyclosporine in Medullary aplasia: A case report
Victory Rodríguez G, Ruiz Gutiérrez ADC, Gómez Sandoval JR, Lomeli Martínez SM
- 12761** Compound heterozygous mutations in PMFBP1 cause acephalic spermatozoa syndrome: A case report
Deng TQ, Xie YL, Pu JB, Xuan J, Li XM
- 12768** Colonic tubular duplication combined with congenital megacolon: A case report
Zhang ZM, Kong S, Gao XX, Jia XH, Zheng CN

- 12775** Perforated duodenal ulcer secondary to deferasirox use in a child successfully managed with laparoscopic drainage: A case report
Alshehri A, Alsinan TA
- 12781** Complication after nipple-areolar complex tattooing performed by a non-medical person: A case report
Byeon JY, Kim TH, Choi HJ
- 12787** Interventional urethral balloon dilatation before endoscopic visual internal urethrotomy for post-traumatic bulbous urethral stricture: A case report
Ha JY, Lee MS
- 12793** Regression of gastric endoscopic submucosal dissection induced polypoid nodular scar after *Helicobacter pylori* eradication: A case report
Jin BC, Ahn AR, Kim SH, Seo SY
- 12799** Congenital absence of the right coronary artery: A case report
Zhu XY, Tang XH

ABOUT COVER

Editorial Board Member of *World Journal of Clinical Cases*, Giuseppe Lanza, MD, MSc, PhD, Associate Professor, Department of Surgery and Medical-Surgical Specialties, University of Catania, Catania 95123, Italy.
glanza@oasi.en.it

AIMS AND SCOPE

The primary aim of *World Journal of Clinical Cases* (WJCC, *World J Clin Cases*) is to provide scholars and readers from various fields of clinical medicine with a platform to publish high-quality clinical research articles and communicate their research findings online.

WJCC mainly publishes articles reporting research results and findings obtained in the field of clinical medicine and covering a wide range of topics, including case control studies, retrospective cohort studies, retrospective studies, clinical trials studies, observational studies, prospective studies, randomized controlled trials, randomized clinical trials, systematic reviews, meta-analysis, and case reports.

INDEXING/ABSTRACTING

The WJCC is now abstracted and indexed in Science Citation Index Expanded (SCIE, also known as SciSearch®), Journal Citation Reports/Science Edition, Current Contents®/Clinical Medicine, PubMed, PubMed Central, Scopus, Reference Citation Analysis, China National Knowledge Infrastructure, China Science and Technology Journal Database, and Superstar Journals Database. The 2022 Edition of Journal Citation Reports® cites the 2021 impact factor (IF) for WJCC as 1.534; IF without journal self cites: 1.491; 5-year IF: 1.599; Journal Citation Indicator: 0.28; Ranking: 135 among 172 journals in medicine, general and internal; and Quartile category: Q4. The WJCC's CiteScore for 2021 is 1.2 and Scopus CiteScore rank 2021: General Medicine is 443/826.

RESPONSIBLE EDITORS FOR THIS ISSUE

Production Editor: Si Zhao; Production Department Director: Xu Guo; Editorial Office Director: Jin-Lei Wang.

NAME OF JOURNAL

World Journal of Clinical Cases

ISSN

ISSN 2307-8960 (online)

LAUNCH DATE

April 16, 2013

FREQUENCY

Thrice Monthly

EDITORS-IN-CHIEF

Bao-Gan Peng, Jerzy Tadeusz Chudek, George Kontogeorgos, Maurizio Serati, Ja Hyeon Ku

EDITORIAL BOARD MEMBERS

<https://www.wjgnet.com/2307-8960/editorialboard.htm>

PUBLICATION DATE

December 6, 2022

COPYRIGHT

© 2022 Baishideng Publishing Group Inc

INSTRUCTIONS TO AUTHORS

<https://www.wjgnet.com/bpg/gerinfo/204>

GUIDELINES FOR ETHICS DOCUMENTS

<https://www.wjgnet.com/bpg/GerInfo/287>

GUIDELINES FOR NON-NATIVE SPEAKERS OF ENGLISH

<https://www.wjgnet.com/bpg/gerinfo/240>

PUBLICATION ETHICS

<https://www.wjgnet.com/bpg/GerInfo/288>

PUBLICATION MISCONDUCT

<https://www.wjgnet.com/bpg/gerinfo/208>

ARTICLE PROCESSING CHARGE

<https://www.wjgnet.com/bpg/gerinfo/242>

STEPS FOR SUBMITTING MANUSCRIPTS

<https://www.wjgnet.com/bpg/GerInfo/239>

ONLINE SUBMISSION

<https://www.f6publishing.com>



Amiodarone-induced muscle tremor in an elderly patient: A case report

Xiao-Yong Zhu, Xin-Hu Tang, Hua Yu

Specialty type: Medicine, research and experimental

Provenance and peer review: Unsolicited article; Externally peer reviewed.

Peer-review model: Single blind

Peer-review report's scientific quality classification

Grade A (Excellent): 0
Grade B (Very good): B
Grade C (Good): C
Grade D (Fair): D
Grade E (Poor): 0

P-Reviewer: Sun P, China;
Watanabe T, Japan

Received: September 3, 2022

Peer-review started: September 3, 2022

First decision: September 27, 2022

Revised: October 9, 2022

Accepted: November 4, 2022

Article in press: November 4, 2022

Published online: December 6, 2022



Xiao-Yong Zhu, Xin-Hu Tang, Hua Yu, Department of Cardiology, Jiujiang University Affiliated Hospital, Jiujiang 332000, Jiangxi Province, China

Corresponding author: Xin-Hu Tang, PhD, Professor, Department of Cardiology, Jiujiang University Affiliated Hospital, No. 57 Road, Xunyang District, Jiujiang 332000, Jiangxi Province, China. 18879292198@163.com

Abstract

BACKGROUND

Amiodarone is a Class III antiarrhythmic drug, which has been adopted for the treatment of atrial fibrillation and ventricular arrhythmia. However, the use of amiodarone can cause lower limb muscle tremors, which is recognized as a rare side effect of this medication.

CASE SUMMARY

An 84-year-old female was administrated with amiodarone for paroxysmal supraventricular tachycardia and frequent ventricular tachycardia. The patient developed a bilateral gastrocnemius tremor in the course of medication, and the strength of the patient's bilateral knee flexor and extensor reached 4/5 and 3/5, respectively. After the use of amiodarone was stopped, and the patient was given a small dose of levetiracetam, the lower limb tremor symptoms were significantly mitigated, along with activity and function.

CONCLUSION

Attention should be paid to the significance of the side effects of drugs in the elderly, which may be atypical in the elderly. The relevant side effects of drugs may not be as rare as reported due to individual differences and different pharmacokinetics. If the side effects are generated, the medication should be adjusted in time, and the progress of the side effects should be intervened.

Key Words: Adverse reaction; Arrhythmia; Muscle disease; Amiodarone; Levetiracetam; Case report

©The Author(s) 2022. Published by Baishideng Publishing Group Inc. All rights reserved.

Core Tip: A patient who developed lower limb muscle tremors after the use of amiodarone was administered with supraventricular tachycardia and frequent ventricular tachycardia. The symptoms was mitigated continuously. After the use of amiodarone was stopped, and the patient was given levetiracetam, the symptoms were gradually mitigated. This type of adverse reaction to amiodarone has been rare. The adverse reaction caused by amiodarone should be considered when similar symptoms occur during diagnosis and treatment.

Citation: Zhu XY, Tang XH, Yu H. Amiodarone-induced muscle tremor in an elderly patient: A case report. *World J Clin Cases* 2022; 10(34): 12726-12733

URL: <https://www.wjgnet.com/2307-8960/full/v10/i34/12726.htm>

DOI: <https://dx.doi.org/10.12998/wjcc.v10.i34.12726>

INTRODUCTION

Conventional doses of drugs may be accompanied by adverse reactions during the treatment of diseases, many of which can affect the neuromuscular system[1]. Amiodarone is an antiarrhythmic drug with numerous relevant side effects. Muscle tremors, which are characterized by marked weakness at the proximal and distal ends, loss of distal sensation, and weakening of muscle stretch reflex, with the lower limbs being more susceptible than the upper[1]. It is a rare side effect of this drug. Amiodarone is considered to interact with lipid membranes to produce complexes that resist lysosomal digestion[2].

This study reports an 84-year-old woman who developed bilateral lower limb muscle pain and tremor, a rare adverse reaction, under amiodarone treatment. We wish to emphasize the significance of drug side effects, which can be typical or atypical, in the elderly. Due to the changes in pharmacodynamics and pharmacokinetics of an aging body, rare adverse reactions may occur more frequently in this group of people. Therefore, in the elderly, the advantages and disadvantages of certain medications must be carefully evaluated before use.

CASE PRESENTATION

Chief complaints

An 84-year-old female suffering from repeated palpitations for three days and aggravated for 5 h went to the Jiujiang University Affiliated Hospital on August 9, 2022.

History of present illness

Three days ago, the patient complained that there was no obvious inducement for repeated palpitation attacks, and each attack was mitigated for one hour. The attacks were characterized by sudden arrest, and no active diagnosis and treatment were made. The patient complained that there was no obvious cause for the re-occurrence of palpitations 5 h ago. The symptoms persisted and were not mitigated. Admission electrocardiogram (ECG): Paroxysmal supraventricular tachycardia with frequent ventricular premature beats. The patient was administered with 150 mg amiodarone intravenously. It was observed that the patient's heart rhythm did not revert to sinus rhythm, and frequent ventricular premature beats were observed. Subsequently, the patient was given amiodarone 1 mg/min for continuous pumping.

At 8:20 on August 10, 2022, the patient started to have lower extremity gastrocnemius tremor, accompanied by pain (muscle fiber necrosis) at a frequency of about 6 Hz. The patient was given an intravenous injection of calcium gluconate 1 mg, the symptoms were not mitigated significantly, the tremor symptoms persisted, and the tremor occurred after lower extremity activity. It was aggravated and mitigated slightly after rest, but the tremor still persisted. It was considered to be drug-induced tremor. The patient only added drugs such as amiodarone. It was considered to be lower extremity muscle tremor caused by amiodarone. The tachycardia and frequent premature ventricular tachycardia persisted, combined with burst ventricular tachycardia, such that amiodarone was continued to be used, whereas the dose of amiodarone was adjusted from 1 mg/min to 0.5 mg/min. After 3 h, the patient complained. The pain and tremor of the lower extremities persisted and became unbearable, such that amiodarone was discontinued, and the patient was administered with propafenone 70 mg intravenously, and sinus rhythm was well restored. However, the patient's lower extremity muscle tremors remained.

History of past illness

The patient had a history of hypertension for 20 years. She took amlodipine besylate 5 mg qd regularly

to control the patient's blood pressure, noting that the blood pressure level was controlled well. She did not take any other medications. The patient denied history of coronary heart disease, cerebral infarction, diabetes, rheumatism, and immune system. She also denied history of trauma.

Personal and family history

The patient denied smoking, drinking history, and family disease history.

Physical examination

Body temperature, 36.5 °C; breathing, 20 breaths/min; blood pressure, 94/56 mmHg; heart rate, 170 beats/min. The gastrocnemius pain of lower limbs was accompanied by muscle tremors; the strength of bilateral knee flexors and extensors reached 4/5 and 3/5, respectively.

Laboratory examinations

Creatine kinase (CK) was 4504 μ/L after the onset of the disease. It evolved dynamically with the course of the disease (Figure 1). Blood routine, liver function, renal function, electrolyte, blood sugar, C-reactive protein, immune function, anti-nuclear antibody, anti-neutrophil cytoplasmic antibodies, and tumor indexes were not abnormal.

Imaging examinations

ECG: Paroxysmal supraventricular tachycardia and frequent ventricular premature beats (Figure 2). No significant abnormality was reported in lumbar magnetic resonance. The measurement result of nerve conduction velocity indicated that discharge was found in the bilateral tibial nerves after the F wave. The electromyography diagram indicated that the bundle fibrillation potential was seen when some muscles were relaxed (Figure 3). Lower limb muscle tremor image (Video 1). Disease development timeline (Figure 4).

FINAL DIAGNOSIS

Lower limb muscle tremors induced by amiodarone injection.

TREATMENT

The department of neurology was invited for consultation. At that time, the possibility of amiodarone was great since the cause of muscle tremor was to be investigated. The patient was given levetiracetam 250 mg twice a day to improve the symptoms of lower limb muscle tremors; the CK level of the patient was dynamically monitored. Active rehabilitation treatment included strength training, balance exercise, as well as targeted physical therapy.

OUTCOME AND FOLLOW-UP

The patient slowly began to recover the function of lower limbs, was able to walk independently, and was discharged home with the same activity ability before admission.

DISCUSSION

Amiodarone is a Class III antiarrhythmic drug that is adopted for the treatment of atrial fibrillation and ventricular arrhythmia. Neuromyopathy has been confirmed as a rare complication of amiodarone, with an incidence of 3%–30% (*e.g.*, tremors, ataxia, peripheral neuropathy, gait disorder, and myopathy[3-5]). Amiodarone-induced muscle tremors are rare in comparison with other drugs causing neuromyopathy (*e.g.*, statins[6]). Patients with neuromyopathy exhibit clinical features of proximal and distal muscle tremor, ataxia, and polymyotonic spasms, with electromyography showing low-amplitude, fast-twitch motor potentials in proximal muscles[7]. Although the mechanism of amiodarone-induced neurotoxicity remains unclear, amiodarone and its active metabolite desethylamiodarone are detectable in the central nervous system, thus suggesting that the drug is capable of crossing the blood-brain barrier[8]. The pathogenesis may be similar to that of chloroquine since amiodarone and desethylamiodarone contain separate hydrophilic and hydrophobic structures[9], are capable of interacting with anionic groups of membrane phospholipids, neutralizing the charge of phosphate groups and displacing calcium ions[10]. The above changes may result in necrosis of muscle fibers and muscle tremors in patients. In addition, amphiphilic drugs penetrate into lysosomes. Once in acidic lysosomes,

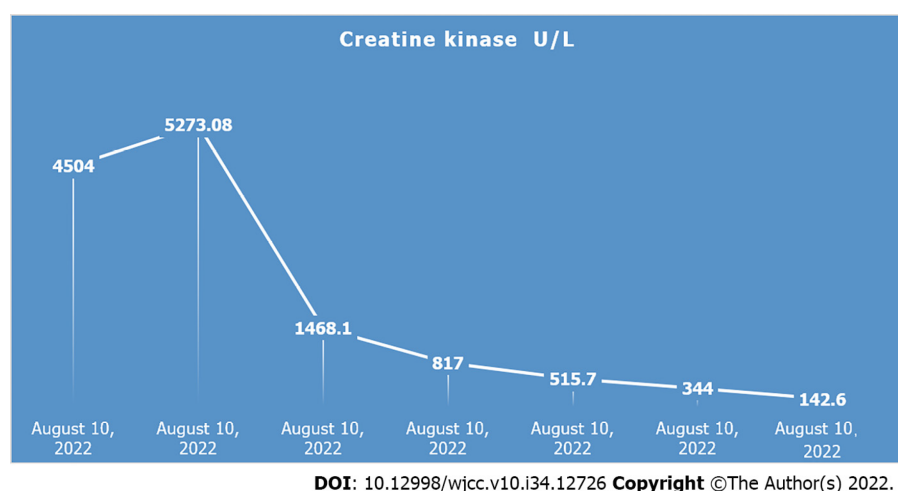


Figure 1 Dynamic evolution of creatine kinase level with the course of disease.

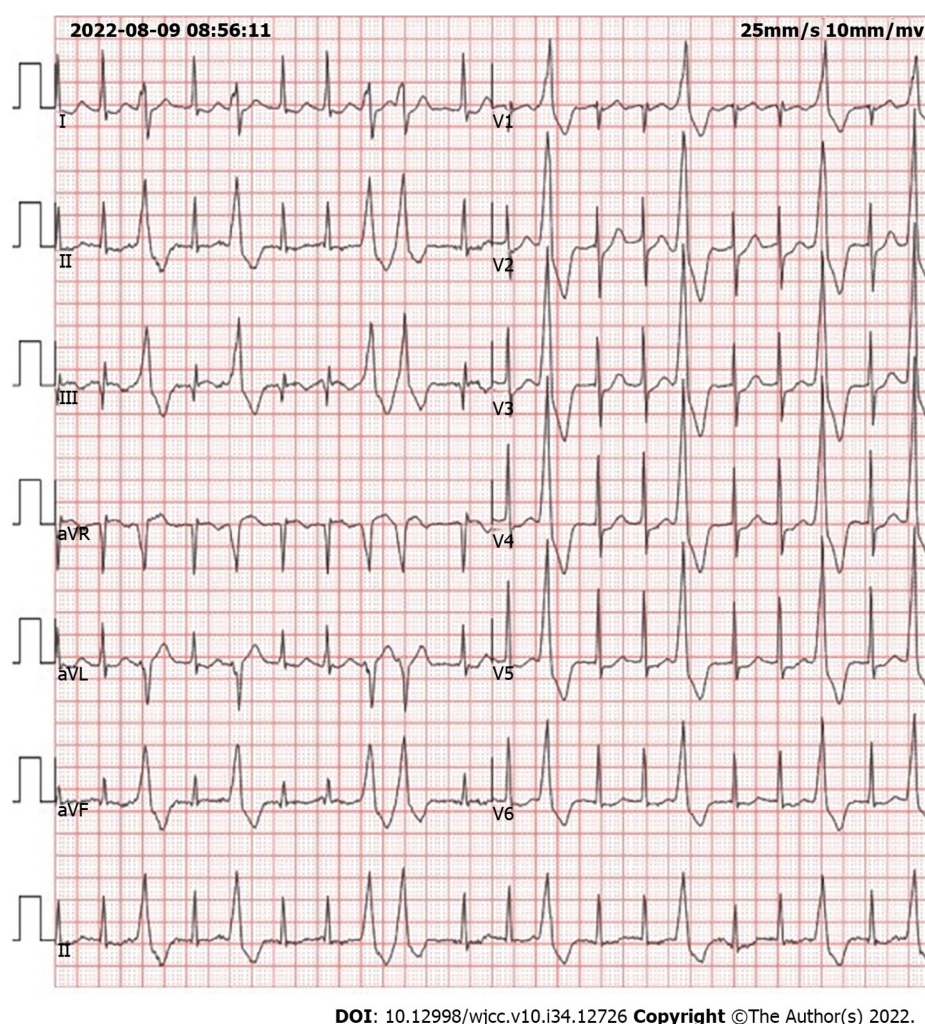
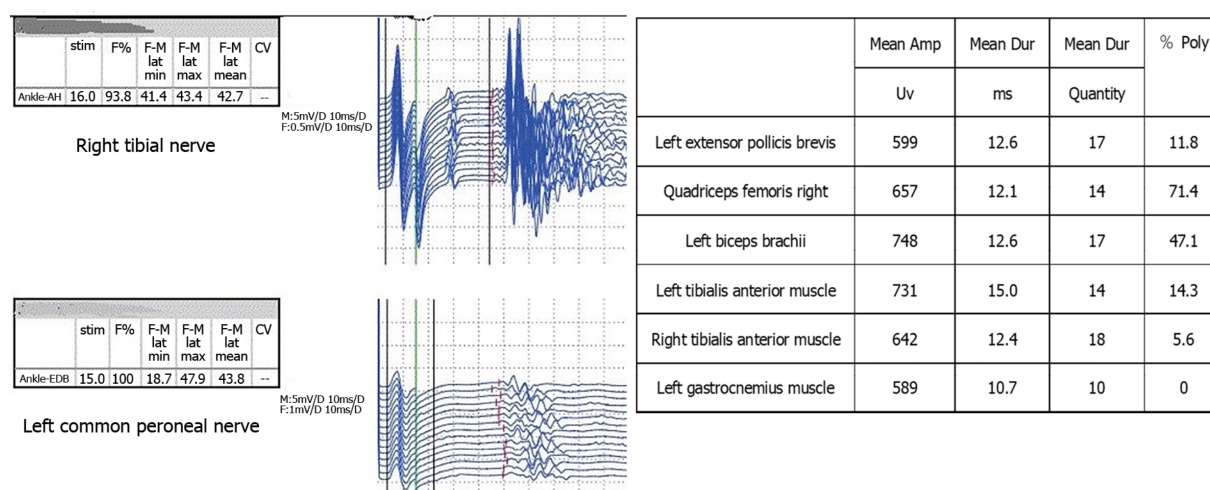


Figure 2 Electrocardiogram, paroxysmal supraventricular tachycardia with frequent ventricular premature beats.

amphiphilic molecules (*e.g.*, amiodarone and desethylamiodarone) are capable of facilitating aggregation of Schwann cells, fibroblasts, and perineural cells to form lysosomal phospholipid complexes, thus resulting in increased pH inside lysosomes and inhibition of lysosomal enzymes, which interfere with lysosomal protein degradation[10-12]. Autophagic vacuoles were formed, and muscle biopsy showed the features of necrotizing myopathy and vacuolar myopathy, with disorganized muscle fibers, and the patient showed peripheral neurological symptoms (*e.g.*, muscle twitching and muscle



Muscle	Action potential	Orthorhombic	Fibrillation	Fasciculation	Other	Retrenchment	Annotation
Left extensor pollicis brevis	Normal	—	—			Interference term	
Quadriceps femoris right	Normal	—	—			Interference term	
Left biceps brachii	Normal	A few	—			Mixed items	Can't finish it well
Left tibialis anterior muscle	Normal	A few	—	+		Mixed items	
Right tibialis anterior muscle	Normal	+	+	+		Interference term	
Leftgastrocnemius muscle	Normal	+	+			Mixed items	

DOI: 10.12998/wjcc.v10.i34.12726 Copyright ©The Author(s) 2022.

Figure 3 Bilateral tibial nerves show discharge after the F wave; bundle fibrillation potential can be seen.

weakness)[13]. The dose of amiodarone-induced muscle tremor remains unclear. Amiodarone-induced hypothyroidism, renal insufficiency, concomitant use of statins, and age all significantly increase the incidence of toxic neuromyopathy[7,14].

There are five reports related to amiodarone induced muscle tremor on PubMed, one of which reported two cases of amiodarone induced muscle tremor, for a total of six patients, and we summarize their data in Table 1, from which we can find that the median age of these patients at the onset of muscle tremor was 63.5 years (range 41-87), the median dose of amiodarone was 400 mg/d (range 200-600), the median duration of taking amiodarone at the onset of symptoms was 2 mo (range 2-10), the patients were instructed to discontinue amiodarone, two of them were given levetiracetam and the other four simply discontinued amiodarone, and the patients were closely observed for changes in their condition, and the final result was that the muscle tremor symptoms were effectively relieved in all six patients.

After admission, the patient improved the lumbar magnetic resonance, and no significant spinal stenosis was identified. We did not consider the correlation of nerve compression. The patient had never taken statins, and muscle injury caused by statins was not considered. The patient also had no history of diabetes; blood glucose and glycosylated hemoglobin were normal after admission, and diabetes neuropathy was not considered. After the onset of the disease, the rheumatic-immune-related disease was improved, and no abnormality was identified. Rheumatic disease was excluded. Blood calcium level was normal after admission and after onset; muscle tremors caused by hypocalcemia was not considered. Furthermore, electromyography examination was also performed, the result of which suggests that bundle fibrillation potential can be seen when some muscles are relaxed. If further diagnosis is required needed, muscle biopsy will be required.

However, after the patient's family was informed about the purpose and risk of this examination, the family members strongly refused the examination. In accordance with the patient's symptoms and onset characteristics, it is more consistent with lower limb tremors induced by amiodarone. In general, this symptom occurs 12 d to 12 mo after the initiation of amiodarone treatment[8]. Curiously, the patient of this study developed sustained tremors of the lower limb muscles after intravenous injection of amiodarone for one day. The pathophysiology of this phenomenon remains unclear. In most cases, the

Table 1 Summary of case data on amiodarone induced muscle tremor

Ref.	Name of journal	Age and gender	Primary disease	Amiodarone administration method	Dosage timing of appearance of side effects	Course of treatment for primary diseases	Timing of appearance of side effects	Outcome
Stanton <i>et al</i> [18], 2020	<i>BMJ Case Rep</i>	87- female	Atrial fibrillation	Oral administration	600 mg/d	3 mo	2 mo	Tremor improved
Celli <i>et al</i> [19], 2020	<i>HeartRhythm Case Rep</i>	60- male	Ventricular tachycardia	Oral administration	200 mg/d	3 yr	4 mo	Tremor improved
Itoh <i>et al</i> [20], 1998	<i>JAPANESE CIRCULATION JOURNAL</i>	41- male	Ventricular tachycardia	Oral administration	400 mg/d	6 yr	10 mo	Symptoms completely relieved
Flanagan <i>et al</i> [7], 2012	<i>Eur J Neurol</i>	67- male	Atrial tachycardia	Oral administration	400 mg/d	Unknown	2 mo	Symptoms completely relieved
Flanagan <i>et al</i> [7], 2012	<i>Eur J Neurol</i>	76- male	Atrial fibrillation	Oral administration	200 mg/d	Unknown	2 mo	Symptoms completely relieved
Arnaud <i>et al</i> [21], 1992	<i>La Revue de Médecine Interne</i>	45- male	Ventricular tachycardia	Oral administration	400 mg/d	Unknown	2 mo	Symptoms completely relieved

August 9, 2022 08:56
 Electrocardiogram suggests paroxysmal supraventricular tachycardia
 August 9, 2022 09:20
 Amiodarone injection 150 mg intravenously, not cardioverted
 August 9, 2022 09:42
 Amiodarone 1 mg/min continuous intravenously
 August 10, 2022 08:20
 The patient presents with lower extremity tremors
 August 10, 2022 08:30
 Calcium gluconate injection 1 mg intravenously
 August 10, 2022 10:00
 Amiodarone 0.5 mg/min continuous intravenously
 August 10, 2022 13:00
 If tremor persists, discontinue amiodarone
 August 10, 2022 13:05
 Propafenone injection 70 mg IV to restore sinus rhythm
 August 10, 2022 14:00
 Neurology Consultation
 August 10, 2022 14:30
 Levetiracetam 250 mg bid
 August 10, 2022 21:00
 The tremor has eased
 August 17, 2022 08:00
 Complete tremor relief

DOI: 10.12998/wjcc.v10.i34.12726 Copyright ©The Author(s) 2022.

Figure 4 Disease development timeline.

above symptoms are mitigated after the discontinuation of amiodarone or gradual reduction of amiodarone[15]. Muscle tremor is a movement disorder characterized by involuntary, rapid and sudden muscle movement, which is likely to be cortical, subcortical, spinal cord, or peripheral. The treatment varies with the classification. In the patient of this study, a muscle tremor was primarily concentrated in the gastrocnemius of the lower limb and presents continuous tremors, consistent with the classification of cortical myoclonus. The muscle spasm caused by drugs is usually cortical[16].

Lastly, after the patient was given levetiracetam, tremors in the patient's lower limb muscles subsided. Levetiracetam is a broad-spectrum antiepileptic drug binding to synaptic vesicle protein SV2A and regulating synaptic transmission by changing vesicle fusion. Levetiracetam has been confirmed as one of the first-line treatments for reflex cortical myoclonus, with the main aim of enhancing the inhibitory process in the sensorimotor cortex[17]. Levetiracetam is conducive to shortening the duration of amiodarone-induced muscle tremors, whereas it can cause changes in behavior and personality (*e.g.*, psychosis, irritability, hypertension, weakness, and lethargy). Accordingly, the patient was given a small dose of levetiracetam to reduce the adverse effects of the

drug.

CONCLUSION

A case of lower limb muscle tremors caused by amiodarone was introduced, which was improved after treatment. When elderly patients are administrated with amiodarone, cardiologists and pharmacists should carefully evaluate the long-term and short-term side effects, as well as whether combined use with other drugs will increase the adverse reactions of amiodarone. Changes in the patient's condition should be closely observed, and if there are signs of adverse reactions, immediate intervention (*e.g.*, changing the drug or reducing the dose of the drug) should be performed to reduce the adverse reactions of amiodarone.

FOOTNOTES

Author contributions: Zhu XY reviewed the literature and contributed to manuscript drafting and revising; Zhu XY was the patient's doctor and contributed to collecting the patient's medical data and making a revision to the manuscript; Tang XH and Yu H were responsible for the revision of the manuscript for important intellectual content; all authors issued final approval for the version to be submitted.

Informed consent statement: Informed written consent was obtained from the patient for publication of this report and any accompanying images.

Conflict-of-interest statement: All the authors report no relevant conflicts of interest for this article.

CARE Checklist (2016) statement: The authors have read the CARE Checklist (2016), and the manuscript was prepared and revised according to the CARE Checklist (2016).

Open-Access: This article is an open-access article that was selected by an in-house editor and fully peer-reviewed by external reviewers. It is distributed in accordance with the Creative Commons Attribution NonCommercial (CC BY-NC 4.0) license, which permits others to distribute, remix, adapt, build upon this work non-commercially, and license their derivative works on different terms, provided the original work is properly cited and the use is non-commercial. See: <https://creativecommons.org/licenses/by-nc/4.0/>

Country/Territory of origin: China

ORCID number: Xiao-Yong Zhu 0000-0003-1103-1227; Xin-Hu Tang 0000-0003-0175-3197; Hua Yu 0000-0001-5398-5016.

S-Editor: Wei ZH

L-Editor: A

P-Editor: Wei ZH

REFERENCES

- 1 Colunga Biancatelli RM, Congedo V, Calvosa L, Ciacciarelli M, Polidoro A, Iuliano L. Adverse reactions of Amiodarone. *J Geriatr Cardiol* 2019; **16**: 552-566 [PMID: 31447894 DOI: 10.11909/j.issn.1671-5411.2019.07.004]
- 2 Mammen AL. Toxic myopathies. *Continuum (Minneapolis Minn)* 2013; **19**: 1634-1649 [PMID: 24305451 DOI: 10.1212/01.CON.0000440663.26427.f4]
- 3 Mäntyjärvi M, Tuppurainen K, Ikäheimo K. Ocular side effects of amiodarone. *Surv Ophthalmol* 1998; **42**: 360-366 [PMID: 9493278 DOI: 10.1016/s0039-6257(97)00118-5]
- 4 Mansour AM, Puklin JE, O'Grady R. Optic nerve ultrastructure following amiodarone therapy. *J Clin Neuroophthalmol* 1988; **8**: 231-237 [PMID: 2977138]
- 5 Vorperian VR, Havighurst TC, Miller S, January CT. Adverse effects of low dose amiodarone: a meta-analysis. *J Am Coll Cardiol* 1997; **30**: 791-798 [PMID: 9283542 DOI: 10.1016/s0735-1097(97)00220-9]
- 6 Pasnoor M, Barohn RJ, Dimachkie MM. Toxic myopathies. *Curr Opin Neurol* 2018; **31**: 575-582 [PMID: 30080718 DOI: 10.1097/WCO.0000000000000606]
- 7 Flanagan EP, Harper CM, St Louis EK, Silber MH, Josephs KA. Amiodarone-associated neuromyopathy: a report of four cases. *Eur J Neurol* 2012; **19**: e50-e51 [PMID: 22507462 DOI: 10.1111/j.1468-1331.2012.03678.x]
- 8 Willis MS, Lugo AM. Amiodarone-induced neurotoxicity. *Am J Health Syst Pharm* 2009; **66**: 567-569 [PMID: 19265185 DOI: 10.2146/ajhp080196]
- 9 Pasnoor M, Barohn RJ, Dimachkie MM. Toxic myopathies. *Neurol Clin* 2014; **32**: 647-670, viii [PMID: 25037083 DOI: 10.1016/j.ncl.2014.04.009]
- 10 Kuncel RW, Wiggins WW. Toxic myopathies. *Neurol Clin* 1988; **6**: 593-619 [PMID: 3065603]
- 11 Borden MB, Parke AL. Antimalarial drugs in systemic lupus erythematosus: use in pregnancy. *Drug Saf* 2001; **24**: 1055-

- 1063 [PMID: [11735661](#) DOI: [10.2165/00002018-200124140-00004](#)]
- 12 **Sundelin SP**, Terman A. Different effects of chloroquine and hydroxychloroquine on lysosomal function in cultured retinal pigment epithelial cells. *APMIS* 2002; **110**: 481-489 [PMID: [12193209](#) DOI: [10.1034/j.1600-0463.2002.100606.x](#)]
 - 13 **Palakurthy PR**, Iyer V, Meckler RJ. Unusual neurotoxicity associated with amiodarone therapy. *Arch Intern Med* 1987; **147**: 881-884 [PMID: [3034178](#)]
 - 14 **Alsheikh-Ali AA**, Karas RH. Adverse events with concomitant amiodarone and statin therapy. *Prev Cardiol* 2005; **8**: 95-97 [PMID: [15860984](#) DOI: [10.1111/j.1520-037x.2005.4060.x](#)]
 - 15 **Deik AF**, Shanker VL. A case of amiodarone-associated myoclonus responsive to levetiracetam. *Can J Neurol Sci* 2012; **39**: 680-681 [PMID: [23066555](#) DOI: [10.1017/s0317167100018229](#)]
 - 16 **Kojovic M**, Cordivari C, Bhatia K. Myoclonic disorders: a practical approach for diagnosis and treatment. *Ther Adv Neurol Disord* 2011; **4**: 47-62 [PMID: [21339907](#) DOI: [10.1177/1756285610395653](#)]
 - 17 **Levy A**, Chen R. Myoclonus: Pathophysiology and Treatment Options. *Curr Treat Options Neurol* 2016; **18**: 21 [PMID: [27039330](#) DOI: [10.1007/s11940-016-0404-7](#)]
 - 18 **Stanton MM**, Samii L, Leung G, Pearce P. Amiodarone-induced neuromyopathy in a geriatric patient. *BMJ Case Rep* 2020; **13** [PMID: [33148598](#) DOI: [10.1136/bcr-2020-236620](#)]
 - 19 **Celli D**, Marquez A, Byer M, Colombo R. Levetiracetam for the treatment of myoclonic neurotoxicity induced by amiodarone. *HeartRhythm Case Rep* 2020; **6**: 488-490 [PMID: [32817824](#) DOI: [10.1016/j.hrcr.2020.04.010](#)]
 - 20 **Itoh K**, Kato R, Hotta N. A case report of myolysis during high-dose amiodarone therapy for uncontrolled ventricular tachycardia. *Jpn Circ J* 1998; **62**: 305-308 [PMID: [9583467](#) DOI: [10.1253/jcj.62.305](#)]
 - 21 **Arnaud A**, Neau JP, Rivasseau-Jonneaux T, Marechaud R, Gil R. [Neurological toxicity of amiodarone. 5 case reports]. *Rev Med Interne* 1992; **13**: 419-422 [PMID: [1344923](#)]



Published by **Baishideng Publishing Group Inc**
7041 Koll Center Parkway, Suite 160, Pleasanton, CA 94566, USA

Telephone: +1-925-3991568

E-mail: bpgoffice@wjgnet.com

Help Desk: <https://www.f6publishing.com/helpdesk>

<https://www.wjgnet.com>

