

Perforated jejunal ulcer associated with gastric mucosa in a jejunal diverticulum

John Bunni, Helen L Barrett, Tim A Cook

John Bunni, Tim A Cook, Department of Surgery, Gloucestershire Royal Hospital, Gloucester GL1 3NN, United Kingdom
 Helen L Barrett, Department of Pathology, Gloucestershire Royal Hospital, Gloucester GL1 3NN, United Kingdom
 Author contributions: Bunni J and Cook TA operated on the patient; Barrett HL assessed the pathology; Bunni J conceived and wrote the manuscript; all authors approved it.
 Correspondence to: John Bunni, MB, ChB (Hons), MRCS, Registrar in General Surgery, Department of Surgery, Gloucestershire Royal Hospital, Great Western Rd, Gloucester GL1 3NN, United Kingdom. johnbunni@hotmail.com
 Telephone: +44-84-54222222 Fax: +44-84-54225612
 Received: December 14, 2013 Revised: January 27, 2014
 Accepted: May 8, 2014
 Published online: June 16, 2014

Abstract

Jejunal diverticula are rare and subsequent complications even more so. The usual small bowel diverticulum encountered by general surgeons is a Meckel's. These are embryological remnants of the vitello-intestinal duct and are on the anti-mesenteric surface of the terminal ileum. They may contain heterotopic gastric or pancreatic mucosa. Herein we explore the case of a young girl who presented with features of peritonitis secondary to a complication from a jejunal diverticulum. The case, pathology, complications and treatment of jejunal diverticulosis and heterotopic gastric mucosa in the jejunum are explored.

© 2014 Baishideng Publishing Group Inc. All rights reserved.

Key words: Jejunum; Perforation; Heterotopic gastric mucosa; Meckel's gastrointestinal diverticulum

Core tip: Herein we describe a rare but important cause of peritonitis in children. We feel it will be of interest to surgeons and pathologists alike and is an important reminder of the basic anatomy and pathology of surgical disease.

Bunni J, Barrett HL, Cook TA. Perforated jejunal ulcer associated with gastric mucosa in a jejunal diverticulum. *World J Clin Cases* 2014; 2(6): 209-210 Available from: URL: <http://www.wjgnet.com/2307-8960/full/v2/i6/209.htm> DOI: <http://dx.doi.org/10.12998/wjcc.v2.i6.209>

INTRODUCTION

Jejunal diverticula are rare and subsequent complications even more so^[1]. The usual small bowel diverticulum encountered by general surgeons is a Meckel's. These are embryological remnants of the vitello-intestinal duct and are on the anti-mesenteric surface of the terminal ileum. They may contain heterotopic gastric or pancreatic mucosa.

Complications of true jejunal diverticula are rare particularly in young children. Herein we explore the case of a young girl who presented with features of peritonitis secondary to a complication from a jejunal diverticulum. Following surgery she made an excellent recovery. We explore the case, pathology, complications and treatment of jejunal diverticulosis and heterotopic gastric mucosa in the jejunum.

CASE REPORT

A previously fit and well 5 years old girl presented to the pediatricians with a two day history of worsening abdominal pain, anorexia and vomiting.

Clinical findings were of pyrexia and generalised peritonitis. Bloods tests showed a lymphocytosis of $29.2 \times 10^9/L$.

A working differential diagnosis was of acute perforated appendicitis or perforated Meckel's diverticulum and she was taken immediately to the operating theatre.

A 1 cm proximal jejunal perforation was identified on the antimesenteric border, directly opposite a mesenteric diverticulum, with a normal appendix. Small bowel re-

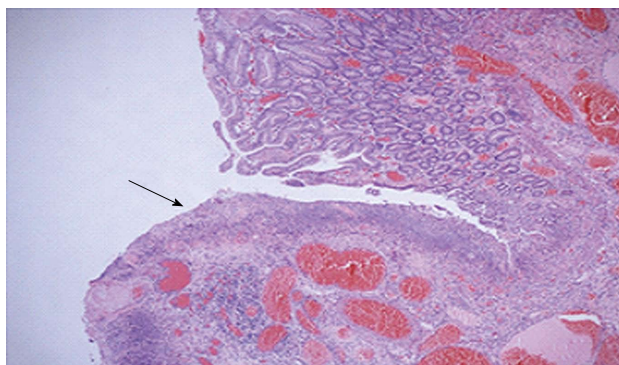


Figure 1 Ulcerated small bowel mucosa (arrow) adjacent to area of perforation.

section was performed with peritoneal toilet. She made a steady recovery and was discharged home on day four post-operatively.

DISCUSSION

Histology of the small bowel showed features of a true diverticulum with gastric mucosa lining the diverticulum. *Helicobacter*-like organisms were not identified. The adjacent small bowel showed transmural inflammation and degeneration of the wall at the site of perforation with an adjacent serosal exudate (Figure 1). There was no evidence of malignancy. Sections of the appendix showed a mild serosal exudate but no evidence of mucosal acute inflammation.

Jejunal diverticula, like all diverticula can be true, involving all three layers of the bowel wall or false - a herniation of mucosa and submucosa through the muscularis propria. True diverticula are usually congenital and false are acquired. The latter are more common and are pulsion diverticula which arise at the weak point on the jejunal mesenteric surface (the point where the mural vessels penetrate the bowel wall). They are more common in middle aged males.

Rarer are the true diverticula which are congenital in nature. These can be on either the mesenteric or antimesenteric surface. The mesenteric diverticula are thought to be primarily related to the neurenteric remnants and duplications, and can be lined by gastric; intestinal or respiratory type epithelium or contain heterotopic pancreatic tissue.

Complications from jejunal diverticula are varied. Though the majority are silent, they can present with chronic abdominal pain, malabsorption, acute gastrointestinal haemorrhage, occult bleeding, diverticulitis, perforation, bacterial overgrowth or small bowel obstruction due to jejunal volvulus. Complications warranting surgical intervention occur in 8% to 30% of patients^[2].

In the elective setting, if suspicious of jejunal diverticulosis there are different investigations that can be performed. These include small bowel follow through,

small bowel enteroclysis, capsule endoscopy, computed tomography scanning as well as in the case of bleeding, radionuclide scans and mesenteric angiography.

Jejunal heterotopic gastric mucosa is a very rare entity, and literature review revealed the usual presenting age to be 14 years^[3]. A common presentation is that of intermittent intussusception secondary to a small bowel (usually) polypoidal mass. This mass is predominantly located only a few centimetres distal to ligament of Treitz.

Management of jejunal diverticula depends on whether or not patients experience symptoms. Asymptomatic jejunal diverticula found incidentally rarely warrant treatment. In symptomatic cases small bowel resection and end-to-end anastomosis is advised.

Jejunal diverticula are rare and their complications even more so. There are subtle pathological differences and once responsible for complications the authors advise small bowel resection and end-to-end anastomosis so as to achieve a pathological diagnosis; cure the problem and ensure no remaining potential heterotopic mucosa of other organs remains.

COMMENTS

Case characteristics

This young patient presented with an acute abdomen and shock.

Clinical diagnosis

Diagnose with peritonitis. Lab tests showed a lymphocytosis.

Differential diagnosis

Acute appendicitis or perforated Meckel's diverticulum.

Laboratory diagnosis

She was taken to the operating room whereby a small bowel perforation was identified and resected.

Pathological diagnosis

Histopathological analysis revealed this to be a perforation secondary to heterotopic gastric mucosa.

Treatment

Small bowel resection was performed with peritoneal toilet and making a steady recovery.

Experiences and lessons

To rapidly identify the sick patient and not waste time on investigations that will not alter management. Awareness of the diversity of small bowel pathology.

Peer review

This is a short case report showing a pediatric patient with perforating jejunal diverticulum. The case is rare and may be worth publication.

REFERENCES

- 1 Zager JS, Garbus JE, Shaw JP, Cohen MG, Garber SM. Jejunal diverticulosis: a rare entity with multiple presentations, a series of cases. *Dig Surg* 2000; **17**: 643-645 [PMID: 11155015 DOI: 10.1159/000051978]
- 2 Wilcox RD, Shatney CH. Surgical significance of acquired ileal diverticulosis. *Am Surg* 1990; **56**: 222-225 [PMID: 2114067]
- 3 Boybeyi O, Karnak I, Güçer S, Orhan D, Senocak ME. Common characteristics of jejunal heterotopic gastric tissue in children: a case report with review of the literature. *J Pediatr Surg* 2008; **43**: e19-e22 [PMID: 18639669 DOI: 10.1016/j.jpedsurg.2008.02.072]

P- Reviewers: Kim BW, Kato J S- Editor: Ma YJ
L- Editor: A E- Editor: Wu HL





Published by **Baishideng Publishing Group Inc**

8226 Regency Drive, Pleasanton, CA 94588, USA

Telephone: +1-925-223-8242

Fax: +1-925-223-8243

E-mail: bpgoffice@wjgnet.com

Help Desk: <http://www.wjgnet.com/esps/helpdesk.aspx>

<http://www.wjgnet.com>

