

World Journal of *Clinical Cases*

World J Clin Cases 2023 March 6; 11(7): 1434-1668



Contents

Thrice Monthly Volume 11 Number 7 March 6, 2023

OPINION REVIEW

- 1434 Reconstruction surgery in head and neck cancer patients amidst the COVID-19 pandemic: Current practice and lessons for the future

Lizambri D, Giacalone A, Shah PA, Tovani-Palone MR

REVIEW

- 1442 Risk factors and digital interventions for anxiety disorders in college students: Stakeholder perspectives

Liu XQ, Guo YX, Xu Y

MINIREVIEWS

- 1458 Immune-related adverse events induced by programmed death protein-1 inhibitors from the perspective of lymphoma immunotherapy

Hou YZ, Zhang Q, Bai H, Wu T, Chen YJ

ORIGINAL ARTICLE

Clinical and Translational Research

- 1467 Analysis of differentially expressed genes related to cerebral ischaemia in young rats based on the Gene Expression Omnibus database

Xia Y, Liu H, Zhu R

Retrospective Study

- 1477 Deep learning-assisted diagnosis of femoral trochlear dysplasia based on magnetic resonance imaging measurements

Xu SM, Dong D, Li W, Bai T, Zhu MZ, Gu GS

- 1488 Facial basal cell carcinoma: A retrospective study of 67 cases

Khalil AA, Enezei HH, Aldelaimi TN, Al-Ani RM

CASE REPORT

- 1498 Successful multidisciplinary therapy for a patient with liver metastasis from ascending colon adenocarcinoma: A case report and review of literature

Tan XR, Li J, Chen HW, Luo W, Jiang N, Wang ZB, Wang S

- 1506 Accessory renal arteries - a source of hypertension: A case report

Calinoiu A, Guluta EC, Rusu A, Minca A, Minca D, Tomescu L, Gheorghita V, Minca DG, Negreanu L

- 1513 Synchronous multiple primary malignant neoplasms in breast, kidney, and bilateral thyroid: A case report

Jia MM, Yang B, Ding C, Yao YR, Guo J, Yang HB

- 1521** Invasive breast carcinoma with osteoclast-like stromal giant cells: A case report
Wang YJ, Huang CP, Hong ZJ, Liao GS, Yu JC
- 1528** Retroperitoneal and abdominal bleeding in anticoagulated COVID-19 hospitalized patients: Case series and brief literature review
Evrev D, Sekulovski M, Gulinac M, Dobrev H, Velikova T, Hadjidekov G
- 1549** Hyperthyroidism and severe bradycardia: Report of three cases and review of the literature
He YL, Xu WX, Fang TY, Zeng M
- 1560** Isolated cerebral mucormycosis that looks like stroke and brain abscess: A case report and review of the literature
Chen CH, Chen JN, Du HG, Guo DL
- 1569** Gastric ectopic pancreas combined with synchronous multiple early gastric cancer: A rare case report
Zhao ZY, Lai YX, Xu P
- 1576** Manifestation of the malignant progression of glioma following initial intracerebral hemorrhage: A case report
Xu EX, Lu SY, Chen B, Ma XD, Sun EY
- 1586** Four kinds of antibody positive paraneoplastic limbic encephalitis: A rare case report
Huang P, Xu M
- 1593** Spontaneous fracture of a titanium mesh cranioplasty implant in a child: A case report
Zhang R, Gao Z, Zhu YJ, Wang XF, Wang G, He JP
- 1600** Rheumatic valvular heart disease treated with traditional Chinese medicine: A case report
Chen WH, Tan Y, Wang YL, Wang X, Liu ZH
- 1607** Mucosa-associated lymphoid tissue lymphoma of the trachea treated with radiotherapy: A case report
Zhen CJ, Zhang P, Bai WW, Song YZ, Liang JL, Qiao XY, Zhou ZG
- 1615** Bow-and-arrow sign on point-of-care ultrasound for diagnosis of pacemaker lead-induced heart perforation: A case report and literature review
Chen N, Miao GX, Peng LQ, Li YH, Gu J, He Y, Chen T, Fu XY, Xing ZX
- 1627** Prostate lymphoma with renal obstruction; reflections on diagnosis and treatment: Two case reports
Chen TF, Lin WL, Liu WY, Gu CM
- 1634** Pulmonary nocardiosis with bloodstream infection diagnosed by metagenomic next-generation sequencing in a kidney transplant recipient: A case report
Deng ZF, Tang YJ, Yan CY, Qin ZQ, Yu N, Zhong XB
- 1642** Primary yolk sac tumor in the abdominal wall in a 20-year-old woman: A case report
Wang Y, Yang J

- 1650** Misdiagnosis of food-borne foreign bodies outside of the digestive tract on magnetic resonance imaging: Two case reports

Ji D, Lu JD, Zhang ZG, Mao XP

- 1656** IgG4-related kidney disease complicated with retroperitoneal fibrosis: A case report

He PH, Liu LC, Zhou XF, Xu JJ, Hong WH, Wang LC, Liu SJ, Zeng JH

LETTER TO THE EDITOR

- 1666** Commentary on a case report and literature review of acute carotid stent thrombosis

Willman M, Lucke-Wold B

ABOUT COVER

Editorial Board Member of *World Journal of Clinical Cases*, Baharudin Ibrahim, BPharm, PhD, Associate Professor, Pharmacist, Department of Clinical Pharmacy and Pharmacy Practice, Faculty of Pharmacy, Universiti Malaya, Kuala Lumpur 50603, Malaysia. baharudin.ibrahim@um.edu.my

AIMS AND SCOPE

The primary aim of *World Journal of Clinical Cases* (WJCC, *World J Clin Cases*) is to provide scholars and readers from various fields of clinical medicine with a platform to publish high-quality clinical research articles and communicate their research findings online.

WJCC mainly publishes articles reporting research results and findings obtained in the field of clinical medicine and covering a wide range of topics, including case control studies, retrospective cohort studies, retrospective studies, clinical trials studies, observational studies, prospective studies, randomized controlled trials, randomized clinical trials, systematic reviews, meta-analysis, and case reports.

INDEXING/ABSTRACTING

The WJCC is now abstracted and indexed in Science Citation Index Expanded (SCIE, also known as SciSearch®), Journal Citation Reports/Science Edition, Current Contents®/Clinical Medicine, PubMed, PubMed Central, Scopus, Reference Citation Analysis, China National Knowledge Infrastructure, China Science and Technology Journal Database, and Superstar Journals Database. The 2022 Edition of Journal Citation Reports® cites the 2021 impact factor (IF) for WJCC as 1.534; IF without journal self cites: 1.491; 5-year IF: 1.599; Journal Citation Indicator: 0.28; Ranking: 135 among 172 journals in medicine, general and internal; and Quartile category: Q4. The WJCC's CiteScore for 2021 is 1.2 and Scopus CiteScore rank 2021: General Medicine is 443/826.

RESPONSIBLE EDITORS FOR THIS ISSUE

Production Editor: Si Zhao; Production Department Director: Xiang Li; Editorial Office Director: Jin-Lei Wang.

NAME OF JOURNAL

World Journal of Clinical Cases

ISSN

ISSN 2307-8960 (online)

LAUNCH DATE

April 16, 2013

FREQUENCY

Thrice Monthly

EDITORS-IN-CHIEF

Bao-Gan Peng, Jerzy Tadeusz Chudek, George Kontogeorgos, Maurizio Serati, Ja Hyeon Ku

EDITORIAL BOARD MEMBERS

<https://www.wjgnet.com/2307-8960/editorialboard.htm>

PUBLICATION DATE

March 6, 2023

COPYRIGHT

© 2023 Baishideng Publishing Group Inc

INSTRUCTIONS TO AUTHORS

<https://www.wjgnet.com/bpg/gerinfo/204>

GUIDELINES FOR ETHICS DOCUMENTS

<https://www.wjgnet.com/bpg/GerInfo/287>

GUIDELINES FOR NON-NATIVE SPEAKERS OF ENGLISH

<https://www.wjgnet.com/bpg/gerinfo/240>

PUBLICATION ETHICS

<https://www.wjgnet.com/bpg/GerInfo/288>

PUBLICATION MISCONDUCT

<https://www.wjgnet.com/bpg/gerinfo/208>

ARTICLE PROCESSING CHARGE

<https://www.wjgnet.com/bpg/gerinfo/242>

STEPS FOR SUBMITTING MANUSCRIPTS

<https://www.wjgnet.com/bpg/GerInfo/239>

ONLINE SUBMISSION

<https://www.f6publishing.com>



Mucosa-associated lymphoid tissue lymphoma of the trachea treated with radiotherapy: A case report

Chan-Jun Zhen, Ping Zhang, Wen-Wen Bai, Yu-Zhi Song, Jun-Li Liang, Xue-Ying Qiao, Zhi-Guo Zhou

Specialty type: Medicine, research and experimental

Provenance and peer review: Unsolicited article; Externally peer reviewed.

Peer-review model: Single blind

Peer-review report's scientific quality classification

Grade A (Excellent): 0
Grade B (Very good): 0
Grade C (Good): C, C
Grade D (Fair): 0
Grade E (Poor): 0

P-Reviewer: Gursel B, Turkey; Sezer HF, Turkey

Received: November 11, 2022

Peer-review started: November 11, 2022

First decision: December 26, 2022

Revised: January 4, 2023

Accepted: February 10, 2023

Article in press: February 10, 2023

Published online: March 6, 2023



Chan-Jun Zhen, Ping Zhang, Wen-Wen Bai, Yu-Zhi Song, Xue-Ying Qiao, Zhi-Guo Zhou, Department of Radiation Oncology, The Fourth Hospital of Hebei Medical University, Shijiazhuang 050011, Hebei Province, China

Jun-Li Liang, Nursing Department, The Fourth Hospital of Hebei Medical University, Shijiazhuang 050011, Hebei Province, China

Corresponding author: Zhi-Guo Zhou, PhD, Chief Physician, Director, Doctor, Department of Radiation Oncology, The Fourth Hospital of Hebei Medical University, No. 12 Jiankang Road, Shijiazhuang 050011, Hebei Province, China. chenk777@126.com

Abstract

BACKGROUND

Mucosa-associated lymphoid tissue (MALT) lymphoma originates in the marginal zone of lymphoid tissue. Lung is one of the most frequent non-gastrointestinal organs involved, here known as bronchus-associated lymphoid tissue (BALT) lymphoma. BALT lymphoma of unknown etiology, and most patients are asymptomatic. The treatment of BALT lymphoma is controversial.

CASE SUMMARY

A 55-year-old man admitted to hospital had a three-month history of progressively coughing up yellow sputum, chest stuffiness, and shortness of breath. Fiberoptic bronchoscopy revealed mucosal visible beaded bumps 4 cm from the tracheal carina at 9 o'clock and 3 o'clock, the right main bronchus, and the right upper lobe bronchus. Biopsy specimens showed MALT lymphoma. Computed tomography virtual bronchoscopy (CTVB) showed uneven main bronchial wall thickening and multiple nodular protrusion. BALT lymphoma stage IE was diagnosed after a staging examination. We treated the patient with radiotherapy (RT) alone. A total dose of 30.6 Gy/17 f/25 d was given. The patient had no obvious adverse reactions during RT. The CTVB was repeated after RT and showed that the right side of the trachea was slightly thickened. CTVB was repeated 1.5 mo after RT and again showed that the right side of the trachea was slightly thickened. Annual CTVB showed no signs of recurrence. The patient now has no symptoms.

CONCLUSION

BALT lymphoma is an uncommon disease and shows good prognosis. The treatment of BALT lymphoma is controversial. In recent years, less invasive diagnostic and therapeutic approaches have been emerging. RT was effective and

safe in our case. The use of CTVB could provide a noninvasive, repeatable, and accurate method in diagnosis and follow-up.

Key Words: Mucosa-associated lymphoid tissue lymphoma; Computed tomography virtual bronchoscopy; Radiotherapy; Prognosis; Case Report

©The Author(s) 2023. Published by Baishideng Publishing Group Inc. All rights reserved.

Core Tip: The treatment of bronchus-associated lymphoid tissue (BALT) lymphoma is controversial. A patient with BALT lymphoma received radiotherapy (RT) alone. A total dose of 30.6 Gy/17 f/25 d was given. The patient had no obvious adverse reactions during RT. The computed tomography virtual bronchoscopy (CTVB) was repeated after RT and showed that the right side of the trachea was slightly thickened. CTVB was repeated 1.5 mo after RT and again showed that the right side of the trachea was slightly thickened. Annual CTVB showed no signs of recurrence.

Citation: Zhen CJ, Zhang P, Bai WW, Song YZ, Liang JL, Qiao XY, Zhou ZG. Mucosa-associated lymphoid tissue lymphoma of the trachea treated with radiotherapy: A case report. *World J Clin Cases* 2023; 11(7): 1607-1614

URL: <https://www.wjgnet.com/2307-8960/full/v11/i7/1607.htm>

DOI: <https://dx.doi.org/10.12998/wjcc.v11.i7.1607>

INTRODUCTION

Primary pulmonary non-Hodgkin's lymphomas are uncommon. They represent 3.6% of all extranodal lymphomas and 0.4% of all non-Hodgkin's lymphomas. Extranodal marginal zone lymphoma of the mucosa-associated lymphoid tissue (MALT) type is the most frequent[1]. MALT lymphoma originates in the marginal zone of lymphoid tissue. The gastrointestinal tract is associated with more than two-thirds of cases, but the lung is one of the most frequent non-gastrointestinal organs involved, here known as bronchus-associated lymphoid tissue (BALT) lymphoma. BALT lymphoma of unknown etiology, and most patients are asymptomatic. The treatment of BALT lymphoma is controversial. A patient with BALT lymphoma received radiotherapy (RT) alone, leading to complete remission of the tumor. A case description as follows.

CASE PRESENTATION

Chief complaints

A 55-year-old man had progressively cough up yellow sputum, chest stuffiness, and shortness of breath.

History of present illness

A 55-year-old man, had a three-month history of progressively coughing up yellow sputum, chest stuffiness, and shortness of breath. He had no chest pain, fever, night sweats, or weight loss.

History of past illness

No lymphadenopathy or chronic lung disease was present.

Personal and family history

The patient had no history of smoking or alcohol abuse. Without family history of carcinomas.

Physical examination

Physical examination did not show any signs of superficial lymph node enlargement. No rales, two lungs breathing clearly.

Laboratory examinations

Hematological and biochemical examination results largely normal.

Imaging examinations

An enhanced CT scan revealed the left upper lobe nodules, considered benign. Two-side pleural multiple heterogeneous hypertrophies with calcification was found. Fiberoptic bronchoscopy showed

mucosal visible beaded bumps 4 cm from the tracheal carina at 9 o'clock and 3 o'clock, the surface flow was rich, and the bronchus extended to the tracheal carina, the right main bronchus, and the right upper lobe bronchus (Figure 1). Biopsy specimens showed MALT lymphoma (Figure 2). Immunohistochemical staining was performed with Bcl-6 (-), CD10 (-), CD20 (+), CD21 (remaining FDC net), CD3 (-), CD56 (-), CKpan (lymphatic epithelial lesions), Ki67 (+ 5%), Syn (-), and TTF-1 (-) (Figure 3). Physical and laboratory examinations were normal. Bone marrow was not infiltrated by abnormal lymphocytes. Computed tomography virtual bronchoscopy (CTVB) showed uneven main bronchial wall thickening and multiple nodular protrusion (Figure 4A). No lymphadenopathy or chronic lung disease was present.

FINAL DIAGNOSIS

BALT lymphoma stage IE was diagnosed.

TREATMENT

We treated the patient with RT alone. Intensity-modulated radiation therapy was performed with Elekta linear accelerator. A total dose of 30.6 Gy/17 f/25 d was given. The process went well.

OUTCOME AND FOLLOW-UP

The patient had no obvious adverse reactions, and all symptoms disappeared. After completing RT, CTVB was repeated and showed the right side of the trachea was slightly thickened (Figure 4B). CTVB was repeated 1.5 mo after RT and showed again that the right side of the trachea was slightly thickened (Figure 4C). The case had been followed up for more than 3.5 years, and annual CTVB showed no signs of recurrence (Figure 4D-G). The patient now shows no symptoms. Long-term efficacy requires further follow-up.

DISCUSSION

BALT lymphoma is considered to be a consequence of long-term exposure to a variety of antigenic stimuli including smoking, inflammatory disorders, or autoimmune diseases[2-4]. BALT lymphoma tends to remain localized until late in the natural course. The histological progression from a low-grade BALT lymphoma to a high-grade lymphoma is rare, and they show a good prognosis. Many patients with this disease are asymptomatic. Symptomatic patients evidence some nonspecific pulmonary symptoms, such as cough, dyspnea, and chest pain. It is easy to misdiagnose and miss diagnoses[5,6].

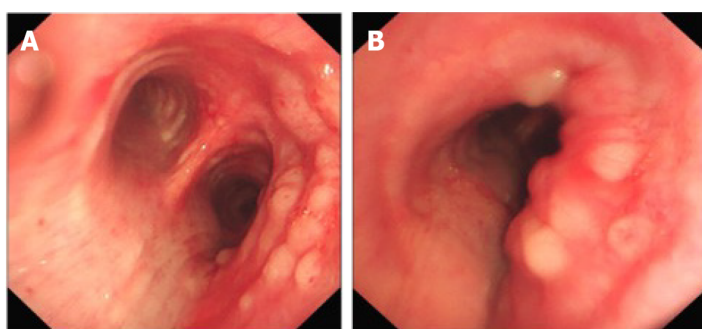
The diagnosis of BALT lymphoma should be based on comprehensive analysis *via* chest X-ray, computed tomography (CT), magnetic resonance imaging and other imaging, a bone marrow biopsy, bronchoscopy, and positron emission tomography/CT. Imaging is characterized by irregular tracheal or bronchial wall thickening and luminal stenosis, with or without accompanying atelectasis. Microscopic examination of the trachea is performed to diagnose the disease under larger values, mainly for nodules or mucosa hypertrophy.

Because the incidence and prevalence of this disease are rare, it is difficult for large randomized clinical trials to provide an "evidence-based" approach. There is no consensus for the treatment of BALT lymphoma. Surgery, single agent therapy, combination chemotherapy, radiation treatment, and the watchful waiting approach have all been used in single or very small series of cases[7-10]. Some scholars believe that localized disease could be resected, especially for diagnostic and therapeutic purposes. RT may play a role in the case of small localized lesions. If symptomatic, BALT lymphoma should be treated with combination chemotherapy or chemoimmunotherapy. For all other cases (asymptomatic/nonsurgical candidates), watchful waiting or single agent chemotherapy could be considered[11,12]. RT has been combined with surgery, chemotherapy, and immunotherapy applications and has been used as a salvage therapy after chemotherapy failure. Using RT alone is rare, but most patients with RT show positive responses. RT may be a reasonable alternative to surgical treatment, when resection of a localized tumor is not possible or appropriate[13]. However, the fields and doses of RT are rarely detailed in the literature (Table 1). Kawaguchi *et al*[14] described a patient treated by RT with a total dose of 50 Gy, resulting in a complete response of the tumor. In a case report by Hashemi *et al*[13], a total dose of 30 Gy was administered, also resulting in a complete response of the tumor. In a report by Girinsky *et al*[15], 10 patients were treated using small radiation doses (2 × 2 Gy) delivered exclusively to tumor sites. The median follow-up was 56 mo. All patients are now alive with no local progression.

Table 1 The literature review of bronchus-associated lymphoid tissue lymphoma

| Number | Treatment | Dose of radiation | Response | Outcome | Ref. |
|--------|--|-------------------|--|---|-----------------------------|
| 61 | Surgery (21), Surgery + chemotherapy (16), Surgery + radiation (3), Surgery + chemotherapy + radiation (2), Chemotherapy (16), Observation (3) | Not reported | Not reported | 5-year OS 93.6% | Cordier <i>et al</i> [5] |
| 19 | Chemotherapy (14), Surgery (2), Surgery + chemotherapy (2), Chemotherapy + radiation (1) | Not reported | 79% CR, 21% PR | Not reported | Zinzani <i>et al</i> [17] |
| 41 | Observation (5), Surgery (17), Chemotherapy (12), Surgery + chemotherapy (3), Surgery + radiation (1), Prednisone (2), Unknown (1) | Not reported | Not reported | Lymphoma-specific-survival was 71.7% at 10 years | Kurtin <i>et al</i> [18] |
| 22 | Observation (2), Chemotherapy alone (2), Rituximab alone (2), Systemic chemotherapy ± Rituximab (12), Chemotherapy with rituximab (8), Surgery (6), Radiotherapy (2) | Not reported | --, 2 PR, 2 PR, 2 CR, 9 PR, 1 SD, 2 CR, 5 PR, 1 SD, 6 CR, 1 CR, 1 PR | 53 mo median PFS | Ahmed <i>et al</i> [19] |
| 18 | Observation (1), Surgery (6), Surgery + chemotherapy (8), Surgery + radiotherapy (1), Surgery + chemotherapy + radiotherapy (2) | Not reported | Not reported | 6 years median time to disease recurrence or death | Graham <i>et al</i> [20] |
| 61 | Surgery alone (17), Surgery + Chemotherapy (3), Surgery + Radiotherapy (2), Chemotherapy (28), Radiotherapy (6), Observation (5) | Not reported | 15 CR, 2 PR, 3 CR, 2 CR, 7 CR, 12 PR, 5 SD, 2 PD, 2 not valuable, 3 CR, 2 PR, 1 SD, 5 not valuable | median time to progression was 5.6 years. 5-year OS 89.7% | Oh <i>et al</i> [21] |
| 10 | Radiotherapy ± surgery ± chemotherapy ± rituximab | 2 Gy × 2 | 6 CR, 4 PR | 87.5% 5-year progression-free survival rate | Girinsky <i>et al</i> [15] |
| 1 | Radiotherapy (1) | 30 Gy | CR | No signs of recurrence are found 4 years after radiotherapy | Hashemi <i>et al</i> [13] |
| 2 | Radiotherapy + rituximab (1), Observation (1) | 50 Gy | CR, -- | Not reported | Kawaguchi <i>et al</i> [14] |
| 1 | Radiotherapy (1) | 30.6 Gy | CR | Survive more than 3.5 years | Our case |

OS: Overall Survival; PFS: Progression-Free Survival; CR: Complete Response; PR: Partial Response; SD: Stable Disease; PD: Progressive Disease.



DOI: 10.12998/wjcc.v11.i7.1607 Copyright ©The Author(s) 2023.

Figure 1 Fiberoptic bronchoscopy. A: Fiberoptic bronchoscopy image at the tracheal carina; B: Fiberoptic bronchoscopy image at the right main bronchus.

The five-year progression-free survival rate was 87.5%, which include 6 complete response, and 4 partial response.

In our case, referring to the biological characteristics of MALT lymphoma and the radiation dose of digestive tract MALT lymphoma, a total dose of 30.6 Gy/17 f was given. There were no obvious symptoms, radioactive lung, or heart injury during and after RT. Until the time of follow-up, there were no signs of recurrence. RT was effective and safe for patients with BALT lymphoma. It also retained the normal physiological structure and improved quality of life. Annual CTVB showed no signs of recurrence. Long-term efficacy still requires further follow-up.

BALT lymphoma can manifest as solitary intraluminal nodules, a diffuse wall thickening, and several tiny nodular protrusions in CT scans. Chest CT alone is not usually sufficient to determine the scope of the lesions. A bronchoscope is important in diagnosis and therapy. In our case, the patient received CTVB before RT, at the end of RT, and 1.5 mo after RT to determine the scope of the lesions and

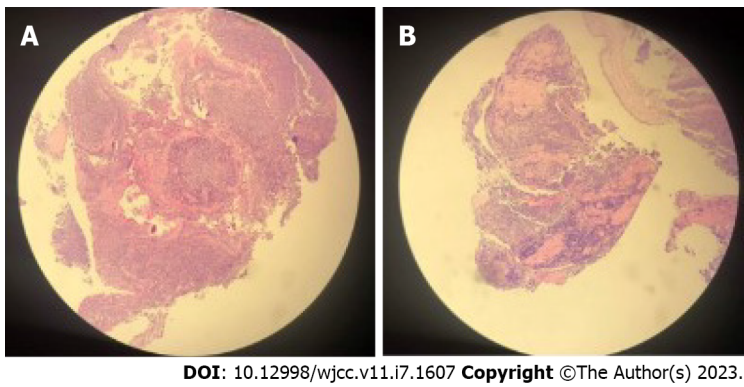


Figure 2 Hematoxylin-eosin staining (H&E) photomicrograph. A: Part1; B: Part2.

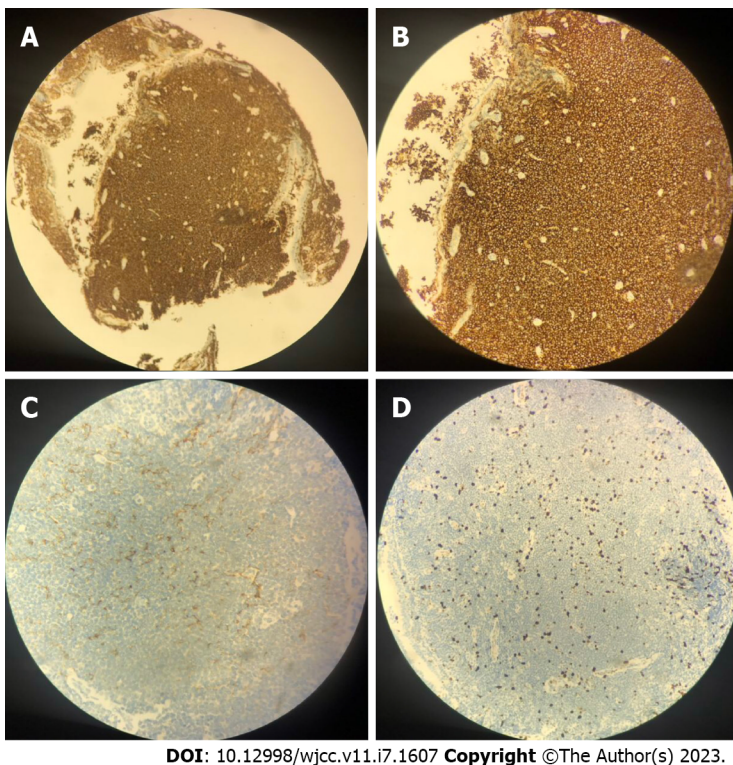
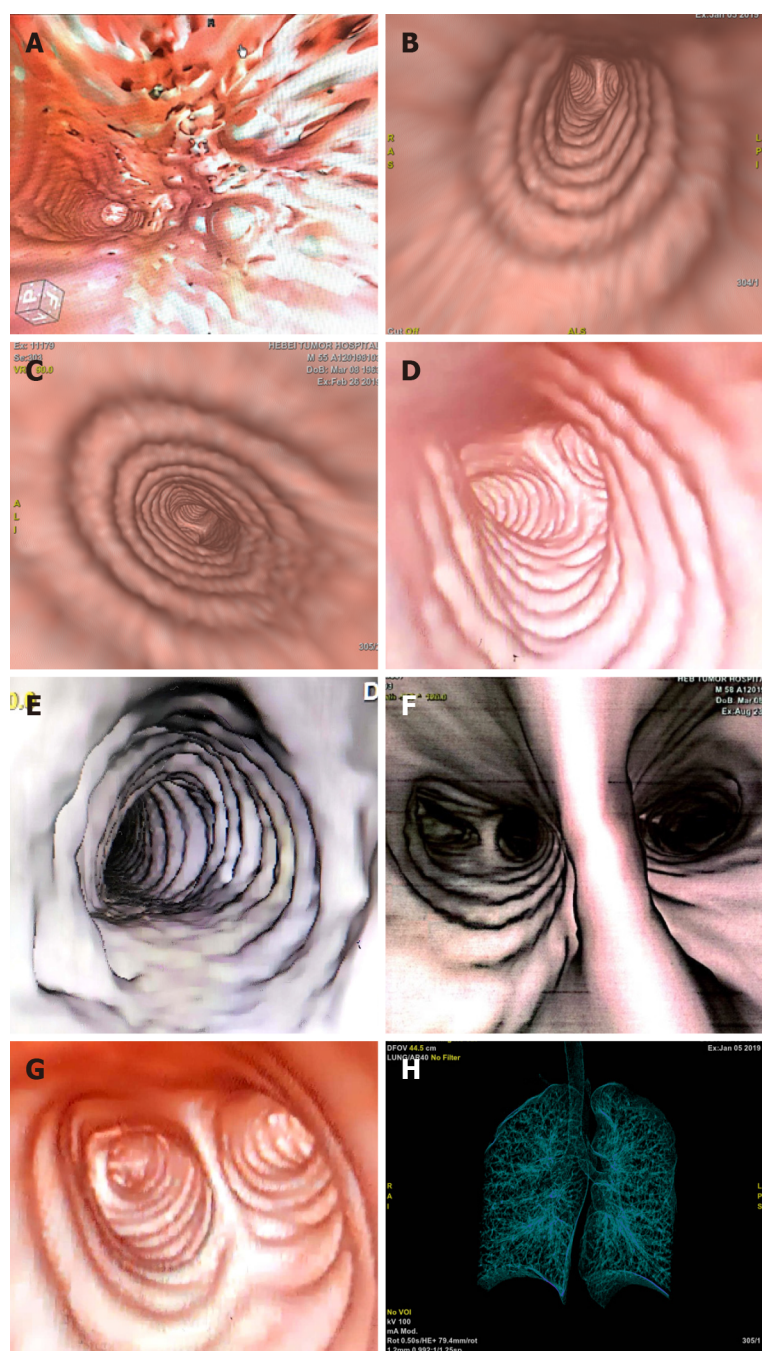


Figure 3 Immunohistochemical stain. A and B: CD20; C: CD21; D: Ki-67.

evaluate the effect. Annual CTVB was used for annual reviews. CTVB is a CT-based imaging technique that allows for a noninvasive intraluminal evaluation of the tracheobronchial tree. It can accurately show the lumen and the diameter of the trachea, the left and right main stem bronchi, and the bronchial tree down to the fourth order of bronchial orifices and branches (Figure 4H). The morphology of the carinas can be evaluated accurately, and the images look very similar to those recorded with fiberoptic bronchoscopy (FB)[16]. In contrast to FB, CTVB is noninvasive and repeatable. It can show the outside of the cavity of infringement and indicate its relationship with surrounding structures. It can also show the bronchial lumen across the narrow or blocked bronchial segment and can be used to observe the lumen, which FB cannot achieve. In this case, CTVB was applied for diagnosis, treatment, and follow-up and provided abundant information regarding the above-mentioned characteristics. It can be used in subsequent follow-up and in other cases.

CONCLUSION

BALT lymphoma is an uncommon disease and shows good prognosis. The treatment of BALT lymphoma is controversial. In recent years, less invasive diagnostic and therapeutic approaches have been emerging. RT was effective and safe in our case. The use of CTVB could provide a noninvasive,



DOI: 10.12998/wjcc.v11.i7.1607 Copyright ©The Author(s) 2023.

Figure 4 The images of computed tomography virtual bronchoscopy. A: The image of computed tomography virtual bronchoscopy (CTVB) before radiotherapy (RT); B: CTVB after RT; C: CTVB 1.5 mo after RT; D: CTVB 6 mo after RT; E: CTVB 1.5 years after RT; F: CTVB 2.5 years after RT; G: CTVB 3.5 years after RT; H: Displayed range of CTVB.

repeatable, and accurate method in diagnosis and follow-up.

FOOTNOTES

Author contributions: Zhen CJ and Zhang P contributed to conceptualization; Bai WW contributed to software; Song YZ contributed to formal analysis; Liang JL contributed to validation; Qiao XY contributed to visualization; Zhou ZG contributed to supervision; All authors have read and approve the final manuscript.

Informed consent statement: All study participants or their legal guardian provided informed written consent about personal and medical data collection prior to study enrolment.

Conflict-of-interest statement: All the authors report no relevant conflicts of interest for this article.

CARE Checklist (2016) statement: The authors have read the CARE Checklist (2016), and the manuscript was prepared and revised according to the CARE Checklist (2016).

Open-Access: This article is an open-access article that was selected by an in-house editor and fully peer-reviewed by external reviewers. It is distributed in accordance with the Creative Commons Attribution NonCommercial (CC BY-NC 4.0) license, which permits others to distribute, remix, adapt, build upon this work non-commercially, and license their derivative works on different terms, provided the original work is properly cited and the use is non-commercial. See: <https://creativecommons.org/licenses/by-nc/4.0/>

Country/Territory of origin: China

ORCID number: Chan-Jun Zhen 0000-0002-9246-0041; Ping Zhang 0000-0002-2476-2881; Wen-Wen Bai 0000-0002-0041-4305; Yu-Zhi Song 0000-0001-6231-111X; Xue-Ying Qiao 0000-0002-4528-0646; Zhi-Guo Zhou 0000-0002-5373-8098.

S-Editor: Liu GL

L-Editor: A

P-Editor: Liu GL

REFERENCES

- 1 **Isaacson PG**, Spencer J. Malignant lymphoma of mucosa-associated lymphoid tissue. *Histopathology* 1987; **11**: 445-462 [PMID: 3497084 DOI: 10.1111/j.1365-2559.1987.tb02654.x]
- 2 **Pabst R**, Gehrke I. Is the bronchus-associated lymphoid tissue (BALT) an integral structure of the lung in normal mammals, including humans? *Am J Respir Cell Mol Biol* 1990; **3**: 131-135 [PMID: 2378747 DOI: 10.1165/ajrcmb/3.2.131]
- 3 **Richmond I**, Pritchard GE, Ashcroft T, Avery A, Corris PA, Walters EH. Bronchus associated lymphoid tissue (BALT) in human lung: its distribution in smokers and non-smokers. *Thorax* 1993; **48**: 1130-1134 [PMID: 8296257 DOI: 10.1136/thx.48.11.1130]
- 4 **Tschernig T**, Pabst R. Bronchus-associated lymphoid tissue (BALT) is not present in the normal adult lung but in different diseases. *Pathobiology* 2000; **68**: 1-8 [PMID: 10859525 DOI: 10.1159/000028109]
- 5 **Cordier JF**, Chailleux E, Lauque D, Reynaud-Gaubert M, Dietemann-Molard A, Dalphin JC, Blanc-Jouvan F, Loire R. Primary pulmonary lymphomas. A clinical study of 70 cases in nonimmunocompromised patients. *Chest* 1993; **103**: 201-208 [PMID: 8417879 DOI: 10.1378/chest.103.1.201]
- 6 **Li G**, Hansmann ML, Zwingers T, Lennert K. Primary lymphomas of the lung: morphological, immunohistochemical and clinical features. *Histopathology* 1990; **16**: 519-531 [PMID: 2198222 DOI: 10.1111/j.1365-2559.1990.tb01157.x]
- 7 **Cadranel J**, Wislez M, Antoine M. Primary pulmonary lymphoma. *Eur Respir J* 2002; **20**: 750-762 [PMID: 12358356 DOI: 10.1183/09031936.02.00404102]
- 8 **Addis BJ**, Hyjek E, Isaacson PG. Primary pulmonary lymphoma: a re-appraisal of its histogenesis and its relationship to pseudolymphoma and lymphoid interstitial pneumonia. *Histopathology* 1988; **13**: 1-17 [PMID: 3209184 DOI: 10.1111/j.1365-2559.1988.tb02000.x]
- 9 **Wei Z**, Li J, Cheng Z, Yuan L, Liu P. A single center experience: rituximab plus cladribine is an effective and safe first-line therapy for unresectable bronchial-associated lymphoid tissue lymphoma. *J Thorac Dis* 2017; **9**: 1081-1092 [PMID: 28523163 DOI: 10.21037/jtd.2017.03.81]
- 10 **Isaacson PG**, Wotherspoon AC, Diss T, Pan LX. Follicular colonization in B-cell lymphoma of mucosa-associated lymphoid tissue. *Am J Surg Pathol* 1991; **15**: 819-828 [PMID: 1951841 DOI: 10.1097/0000478-199109000-00001]
- 11 **Arnautakis K**, Oo TH. Bronchus-associated lymphoid tissue lymphomas. *South Med J* 2009; **102**: 1229-1233 [PMID: 20016430 DOI: 10.1097/SMJ.0b013e3181bfdd2d]
- 12 **Sammasimo S**, Pruneri G, Andreola G, Montoro J, Steffanoni S, Nowakowski GS, Gandini S, Negri M, Habermann TM, Raderer M, Li ZM, Zinzani PL, Adam P, Zucca E, Martinelli G. A retrospective international study on primary extranodal marginal zone lymphoma of the lung (BALT lymphoma) on behalf of International Extranodal Lymphoma Study Group (IELSG). *Hematol Oncol* 2016; **34**: 177-183 [PMID: 26152851 DOI: 10.1002/hon.2243]
- 13 **Hashemi SM**, Heitbrink MA, Jiwa M, Boersma WG. A patient with endobronchial BALT lymphoma successfully treated with radiotherapy. *Respir Med* 2007; **101**: 2227-2229 [PMID: 17616383 DOI: 10.1016/j.rmed.2006.11.028]
- 14 **Kawaguchi T**, Himeji D, Kawano N, Shimao Y, Marutsuka K. Endobronchial Mucosa-associated Lymphoid Tissue Lymphoma: A Report of Two Cases and a Review of the Literature. *Intern Med* 2018; **57**: 2233-2236 [PMID: 29526933 DOI: 10.2169/internalmedicine.0150-17]
- 15 **Girinsky T**, Paumier A, Ferme C, Hanna C, Ribrag V, Leroy-Ladurie F, Ghalibafian M. Low-dose radiation treatment in pulmonary mucosa-associated lymphoid tissue lymphoma: a plausible approach? *Int J Radiat Oncol Biol Phys* 2012; **83**: e385-e389 [PMID: 22420970 DOI: 10.1016/j.ijrobp.2012.01.005]
- 16 **De Wever W**, Vandecaveye V, Lanciotti S, Verschakelen JA. Multidetector CT-generated virtual bronchoscopy: an illustrated review of the potential clinical indications. *Eur Respir J* 2004; **23**: 776-782 [PMID: 15176696 DOI: 10.1183/09031936.04.00099804]
- 17 **Zinzani PL**, Magagnoli M, Galieni P, Martelli M, Poletti V, Zaja F, Molica S, Zaccaria A, Cantonetti AM, Gentilini P, Guardigni L, Gherlinzoni F, Ribersani M, Bendandi M, Albertini P, Tura S. Nongastrointestinal low-grade mucosa-associated lymphoid tissue lymphoma: analysis of 75 patients. *J Clin Oncol* 1999; **17**: 1254 [PMID: 10561186 DOI: 10.1200/jco.1999.17.4.1254]

- 18 **Kurtin PJ**, Myers JL, Adlakha H, Strickler JG, Lohse C, Pankratz VS, Inwards DJ. Pathologic and clinical features of primary pulmonary extranodal marginal zone B-cell lymphoma of MALT type. *Am J Surg Pathol* 2001; **25**: 997-1008 [PMID: 11474283 DOI: 10.1097/00000478-200108000-00003]
- 19 **Ahmed S**, Kussick SJ, Siddiqui AK, Bhuiya TA, Khan A, Sarewitz S, Steinberg H, Sison CP, Rai KR. Bronchial-associated lymphoid tissue lymphoma: a clinical study of a rare disease. *Eur J Cancer* 2004; **40**: 1320-1326 [PMID: 15177490 DOI: 10.1016/j.ejca.2004.02.006]
- 20 **Graham BB**, Mathisen DJ, Mark EJ, Takvorian RW. Primary pulmonary lymphoma. *Ann Thorac Surg* 2005; **80**: 1248-1253 [PMID: 16181848 DOI: 10.1016/j.athoracsur.2005.04.014]
- 21 **Oh SY**, Kim WS, Kim JS, Kim SJ, Kwon HC, Lee DH, Won JH, Hwang IG, Kim MK, Lee SI, Chae YS, Yang DH, Lee GW, Choi CW, Park J, Suh C, Kim HJ. Pulmonary marginal zone B-cell lymphoma of MALT type--what is a prognostic factor and which is the optimal treatment, operation, or chemotherapy? *Ann Hematol* 2010; **89**: 563-568 [PMID: 20024551 DOI: 10.1007/s00277-009-0875-7]



Published by **Baishideng Publishing Group Inc**
7041 Koll Center Parkway, Suite 160, Pleasanton, CA 94566, USA

Telephone: +1-925-3991568

E-mail: bpgoffice@wjgnet.com

Help Desk: <https://www.f6publishing.com/helpdesk>

<https://www.wjgnet.com>

