

World Journal of *Diabetes*

World J Diabetes 2023 June 15; 14(6): 632-938



REVIEW

- 632 State of art on the mechanisms of laparoscopic sleeve gastrectomy in treating type 2 diabetes mellitus
Liu FS, Wang S, Guo XS, Ye ZX, Zhang HY, Li Z
- 656 Genetics of diabetes
Goyal S, Rani J, Bhat MA, Vanita V
- 680 What's old is new again: Insights into diabetic foot microbiome
Rajab AAH, Hegazy WAH
- 705 Food contaminants and potential risk of diabetes development: A narrative review
Milanović M, Milošević N, Milić N, Stojanoska MM, Petri E, Filipović JM
- 724 Targeting epicardial adipose tissue: A potential therapeutic strategy for heart failure with preserved ejection fraction with type 2 diabetes mellitus
Shi YJ, Dong GJ, Guo M
- 741 Issues and challenges in diabetic neuropathy management: A narrative review
Ismail CAN
- 758 Adiponectin as a therapeutic target for diabetic foot ulcer
Abdalla MMI, Mohanraj J, Somanath SD

MINIREVIEWS

- 783 Preoperative carbohydrate load to reduce perioperative glycemic variability and improve surgical outcomes: A scoping review
Canelli R, Louca J, Hartman C, Bilotta F
- 795 Diabetes and cognitive decline: Challenges and future direction
Ab-Hamid N, Omar N, Ismail CAN, Long I
- 808 Effect of resveratrol in gestational diabetes mellitus and its complications
Ma HZ, Chen Y, Guo HH, Wang J, Xin XL, Li YC, Liu YF

ORIGINAL ARTICLE

Basic Study

- 820 Comprehensive analysis of endoplasmic reticulum stress-related mechanisms in type 2 diabetes mellitus
Liang B, Chen SW, Li YY, Zhang SX, Zhang Y

- 846** *Lomatogonium rotatum* extract alleviates diabetes mellitus induced by a high-fat, high-sugar diet and streptozotocin in rats

Dai LL, Cho SB, Li HF, A LS, Ji XP, Pan S, Bao ML, Bai L, Ba GN, Fu MH

- 862** Alteration of intestinal microbiota is associated with diabetic retinopathy and its severity: Samples collected from southeast coast Chinese

Gu XM, Lu CY, Pan J, Ye JZ, Zhu QH

Retrospective Study

- 883** Application of urinary N-acetyl- β -D-glucosaminidase combined with serum retinol-binding protein in early detection of diabetic nephropathy

Lin ZH, Dai SF, Zhao JN, Jiang Y

SYSTEMATIC REVIEWS

- 892** Correlation between COVID-19 vaccination and diabetes mellitus: A systematic review

He YF, Ouyang J, Hu XD, Wu N, Jiang ZG, Bian N, Wang J

- 919** Insights on antioxidant therapeutic strategies in type 2 diabetes mellitus: A narrative review of randomized control trials

Shrivastav D, Dabla PK, Sharma J, Viswas A, Mir R

- 930** Usage of topical insulin for the treatment of diabetic keratopathy, including corneal epithelial defects

Leong CY, Naffi AA, Wan Abdul Halim WH, Bastion MLC

ABOUT COVER

Editorial Board Member of *World Journal of Diabetes*, Sanja Klobucar Majanovic, MD, PhD, Assistant Professor, Department of Endocrinology, Diabetes and Metabolic Diseases, University Hospital Rijeka, Faculty of Medicine, University of Rijeka, Rijeka 51000, Croatia. sanja.klobucarm@gmail.com

AIMS AND SCOPE

The primary aim of *World Journal of Diabetes* (*WJD*, *World J Diabetes*) is to provide scholars and readers from various fields of diabetes with a platform to publish high-quality basic and clinical research articles and communicate their research findings online.

WJD mainly publishes articles reporting research results and findings obtained in the field of diabetes and covering a wide range of topics including risk factors for diabetes, diabetes complications, experimental diabetes mellitus, type 1 diabetes mellitus, type 2 diabetes mellitus, gestational diabetes, diabetic angiopathies, diabetic cardiomyopathies, diabetic coma, diabetic ketoacidosis, diabetic nephropathies, diabetic neuropathies, Donohue syndrome, fetal macrosomia, and prediabetic state.

INDEXING/ABSTRACTING

The *WJD* is now abstracted and indexed in Science Citation Index Expanded (SCIE, also known as SciSearch®), Current Contents/Clinical Medicine, Journal Citation Reports/Science Edition, PubMed, PubMed Central, Reference Citation Analysis, China National Knowledge Infrastructure, China Science and Technology Journal Database, and Superstar Journals Database. The 2022 Edition of Journal Citation Reports® cites the 2021 impact factor (IF) for *WJD* as 4.560; IF without journal self cites: 4.450; 5-year IF: 5.370; Journal Citation Indicator: 0.62; Ranking: 62 among 146 journals in endocrinology and metabolism; and Quartile category: Q2.

RESPONSIBLE EDITORS FOR THIS ISSUE

Production Editor: *Yu-Xi Chen*; Production Department Director: *Xu Guo*; Editorial Office Director: *Jia-Ru Fan*.

NAME OF JOURNAL

World Journal of Diabetes

ISSN

ISSN 1948-9358 (online)

LAUNCH DATE

June 15, 2010

FREQUENCY

Monthly

EDITORS-IN-CHIEF

Lu Cai, Md. Shahidul Islam, Michael Horowitz

EDITORIAL BOARD MEMBERS

<https://www.wjnet.com/1948-9358/editorialboard.htm>

PUBLICATION DATE

June 15, 2023

COPYRIGHT

© 2023 Baishideng Publishing Group Inc

INSTRUCTIONS TO AUTHORS

<https://www.wjnet.com/bpg/gerinfo/204>

GUIDELINES FOR ETHICS DOCUMENTS

<https://www.wjnet.com/bpg/GerInfo/287>

GUIDELINES FOR NON-NATIVE SPEAKERS OF ENGLISH

<https://www.wjnet.com/bpg/gerinfo/240>

PUBLICATION ETHICS

<https://www.wjnet.com/bpg/GerInfo/288>

PUBLICATION MISCONDUCT

<https://www.wjnet.com/bpg/gerinfo/208>

ARTICLE PROCESSING CHARGE

<https://www.wjnet.com/bpg/gerinfo/242>

STEPS FOR SUBMITTING MANUSCRIPTS

<https://www.wjnet.com/bpg/GerInfo/239>

ONLINE SUBMISSION

<https://www.f6publishing.com>

Usage of topical insulin for the treatment of diabetic keratopathy, including corneal epithelial defects

Ching Yee Leong, Ainal Adlin Naffi, Wan Haslina Wan Abdul Halim, Mae-Lynn Catherine Bastion

Specialty type: Endocrinology and metabolism

Provenance and peer review:

Invited article; Externally peer reviewed.

Peer-review model: Single blind

Peer-review report's scientific quality classification

Grade A (Excellent): 0
Grade B (Very good): 0
Grade C (Good): C, C, C
Grade D (Fair): D
Grade E (Poor): 0

P-Reviewer: Lee KS, South Korea; Nassar M, United States; Setiyorini E, Indonesia; Horowitz M, Australia

Received: December 27, 2022

Peer-review started: December 27, 2022

First decision: February 8, 2023

Revised: March 14, 2023

Accepted: April 24, 2023

Article in press: April 24, 2023

Published online: June 15, 2023



Ching Yee Leong, Ainal Adlin Naffi, Wan Haslina Wan Abdul Halim, Mae-Lynn Catherine Bastion, Department of Ophthalmology, Universiti Kebangsaan Malaysia Medical Centre, Kuala Lumpur 56000, Wilayah Persekutuan, Malaysia

Corresponding author: Mae-Lynn Catherine Bastion, DO, FRCS, MBBS, Full Professor, Department of Ophthalmology, Universiti Kebangsaan Malaysia Medical Centre, Faculty of Medicine Universiti Kebangsaan Malaysia Jalan Yaacob Latif, Kuala Lumpur 56000, Wilayah Persekutuan, Malaysia. maelynnb2003@yahoo.com

Abstract

BACKGROUND

Diabetic keratopathy (DK) occurs in 46%-64% of patients with diabetes and requires serious attention. In patients with diabetes, the healing of corneal epithelial defects or ulcers takes longer than in patients without diabetes. Insulin is an effective factor in wound healing. The ability of systemic insulin to rapidly heal burn wounds has been reported for nearly a century, but only a few studies have been performed on the effects of topical insulin (TI) on the eye. Treatment with TI is effective in treating DK.

AIM

To review clinical and experimental animal studies providing evidence for the efficacy of TI to heal corneal wounds.

METHODS

National and international databases, including PubMed and Scopus, were searched using relevant keywords, and additional manual searches were conducted to assess the effectiveness of TI application on corneal wound healing. Journal articles published from January 1, 2000 to December 1, 2022 were examined. The relevancy of the identified citations was checked against predetermined eligibility standards, and relevant articles were extracted and reviewed.

RESULTS

A total of eight articles were found relevant to be discussed in this review, including four animal studies and four clinical studies. According to the studies conducted, TI is effective for corneal re-epithelialization in patients with diabetes based on corneal wound size and healing rate.

CONCLUSION

Available animal and clinical studies have shown that TI promotes corneal wound

healing by several mechanisms. The use of TI was not associated with adverse effects in any of the published cases. Further studies are needed to enhance our knowledge and understanding of TI in the healing of DK.

Key Words: Diabetes mellitus; Diabetic keratopathy; Topical insulin; Healing

©The Author(s) 2023. Published by Baishideng Publishing Group Inc. All rights reserved.

Core Tip: Diabetic keratopathy (DK) is a common complication of diabetes mellitus that is responsible for poor corneal wound healing. It also reduces quality of vision and quality of life. DK is the result of damage resulting from insulin deficiency, hyperglycemia and neuropathy. Topical insulin has been described as an effective and safe new treatment for DK that can normalize the ocular surface and healing rate of epithelial defects. This review examines the available evidence.

Citation: Leong CY, Naffi AA, Wan Abdul Halim WH, Bastion MLC. Usage of topical insulin for the treatment of diabetic keratopathy, including corneal epithelial defects. *World J Diabetes* 2023; 14(6): 930-938

URL: <https://www.wjgnet.com/1948-9358/full/v14/i6/930.htm>

DOI: <https://dx.doi.org/10.4239/wjd.v14.i6.930>

INTRODUCTION

Diabetes mellitus is an international public health concern with many complications, both microvascular and macrovascular. The International Diabetes Federation states that 451 million adults worldwide had diabetes in 2017, and this number is expected to increase to 693 million by 2045[1].

Diabetic keratopathy (DK) or diabetic corneal epitheliopathy is one of the complications of diabetes mellitus. It is a degenerative corneal disease that requires serious attention. DK occurs in 46%-64% of patients with diabetes, which affects their quality of life[2]. Ocular surgery, such as corneal transplantation, vitrectomy, and cataract surgery, is a risk factor for corneal epithelial injury in patients with diabetes. Most diabetic keratopathies are thought to occur in the corneal epithelium, but they can also occur in other layers of the cornea, including the corneal stroma, Descemet's membrane, and corneal endothelium[3]. DK may present clinically as punctate keratitis, delayed corneal re-epithelialization, corneal hypoesthesia, neurotrophic corneal ulcer and corneal edema. Diabetes increases susceptibility to spontaneous corneal trauma, including epithelial defects and corneal ulcers. In diabetic patients, any corneal epithelial defect or ulcer takes longer to heal and persists longer than in nondiabetic patients[2]. These clinical manifestations are mainly caused by glycation product deposition, corneal nerve ending damage, decreased tear secretion and oxidative stress caused by hyperglycemia. Studies have shown that tear secretion is lower in diabetic patients than in nondiabetic patients[4], and the mucin layer, which forms the innermost layer of tear film, is reduced due to the reduced density of conjunctival goblet cells[5]. In addition, decreased corneal nerve density, which impairs the tear reflex, results in decreased secretion of the aqueous component of tears. Chronic hyperglycemia leads to a decrease in insulin, which plays a role in the proliferation of the acinar cells of the corneal epithelial cells and lacrimal gland[6]. Diabetic microvasculopathy may affect tear secretion by damaging the lacrimal blood supply[7]. Susceptibility, lack of epithelial adherence, decreased corneal nerve plexus and sensitivity are part of the pathogenesis for the development of DK[8].

Insulin is a biologically active peptide closely related to insulin-like growth factor (IGF) that can stimulate the haptotactic migration of human epidermal keratinocytes and is involved in cell growth, proliferation, metabolism and wound healing[9]. The mechanism by which TI improves corneal wound healing is not yet fully understood. Insulin is found in the tear film of the eye. Insulin receptors are found in the corneal epithelium and ocular surface tissue[10]. The presence of insulin and insulin receptors on the cornea and lacrimal glands suggests that insulin may contribute to corneal wound healing[11]. Rocha *et al*[12] also detected insulin in tears and the expression of the insulin receptor and IGF-1 receptor (IGF-1R) on the human ocular surface. IGF-1 promotes corneal epithelial healing by increasing cell proliferation. The topical application of insulin can stimulate IGF-1R and treat DK[12].

MATERIALS AND METHODS

Search strategy

A literature search was conducted and completed on 10 December 2022. Two databases, namely,

PubMed and Scopus, were used to identify all studies concerning topical insulin (TI) treatment for DK. Articles were limited to journal articles with the keywords “topical insulin”, diabetes, and keratopathy in the field of the search. The following string was used: TITLE-ABS-KEY [“topical insulin” OR (“local” AND “insulin”) OR (“topical” AND “insulin”)] AND TITLE-ABS-KEY (“diabetes” OR “diabetic” OR “diabetes mellitus” OR “diabetics”) AND TITLE-ABS-KEY (“cornea” OR “corneal” OR “cornea wound healing” OR “corneal wound healing” OR “keratopathy” OR “diabetic keratopathy” OR “cornea wound” OR “corneal wound” OR “eye” OR “eyes”). The search was further supplemented by manual searching for relevant references and using reference citation analysis to find the latest research results. We only examined journal articles published from January 1, 2000 to December 1, 2022.

Inclusion and exclusion criteria

Studies that fulfilled the following criteria were included: (1) The experimental group (adults and animals) was diabetic; (2) The experimental group with DK was treated with TI or insulin-growth-factor; and (3) The effects on the cornea, such as the corneal epithelial defect healing rate, healing size, time to heal, ocular surface disease index score or tear break-up time, were compared between the experimental and control groups. Publications from case reports, letters, and studies without raw data were excluded. We would select either the article with the most recent publication date or with the largest sample size if multiple articles were published based on the same population and were based on one study. In addition, exclusion criteria included articles not published in English, nondiabetic experimental populations, reported effects that were not on the cornea and inadequate information in the article’s text.

Data extraction

In the first phase of the search, the first reviewer (Leong CY) reviewed the articles and studies that were duplicated and overlapping were excluded. Subsequently, two reviewers (Leong CY and Naffi AA) independently screened the titles and abstracts, and irrelevant abstract articles were excluded. The full texts of the remaining publications were reviewed by three reviewers (Leong CY, Naffi AA, and Wan Abdul Halim WH), and studies meeting the exclusion criteria were eliminated. Finally, the fourth reviewer (Bastion MLC) reviewed the articles for comprehensiveness and accuracy.

RESULTS

In the first phase of the search, a total of 588 related articles were found with the above strategy. A total of eight articles were found relevant to be discussed in this review, including four animal studies and four clinical studies. The flow chart is presented in [Figure 1](#). All articles in this review are listed in the reference sources. [Table 1](#) contains a list of characteristics of each animal study, and [Table 2](#) illustrates the characteristics of human clinical studies.

DISCUSSION

Animal studies

Nakamura *et al*[13] studied the effects of combining IGF-1 and a substance P-derived tetrapeptide (phenylalanine-glycine-leucine-methionine-amide, or FGLM-NH₂) on corneal epithelial wound healing in diabetic rats. The corneal epithelium was removed in both diabetic and nondiabetic rats from limbus to limbus and treated with eye drops containing 1 mmol/L FGLM-NH₂ (Peptide Institute, Osaka, Japan) and IGF-1 (1 µg/mL-1) (Becton Dickinson, Bedford, Mass., United States) 6 times daily for 3 d or vehicle alone as a control. The area of the corneal epithelial wound was measured several times for up to 72 h after treatment onset. A delay in wound closure was observed in diabetic rats compared with nondiabetic rats. Similar wound healing processes were observed in normal rats and diabetic rats treated with FGLM-NH₂ and IGF-1. However, wound closure was significantly faster in diabetic rats treated with FGLM-NH₂ and IGF-1 than in those treated with vehicle[13].

Zagon *et al*[14] performed an animal study and reported that the remaining corneal epithelial defects were 35% larger in rats with diabetes than in healthy animals. In diabetic rats that received TI, corneal healing was significantly enhanced compared to diabetic rats without TI. This study also compared 1, 2, or 5 U insulin in healthy and diabetic rats. Insulin concentrations with more than a 5-fold difference showed no difference in efficacy and safety for the cornea, as determined by corneal thickness, intraocular pressure and ocular surface morphological characteristics[14].

Chen *et al*[15] studied corneal nerve density depletion in patients with diabetes using corneal confocal microscopy and its relationship with TI. The effects of type 1 diabetes on corneal nerves were then studied over time using female Sprague-Dawley rats, whereas the impact of TI on corneal nerves was investigated using female Swiss Webster mice. In rats with diabetes, nerve occupancy in the subbasal plexus was significantly reduced at week 40. TI was applied (0.1 IU daily) to the eyes of diabetes

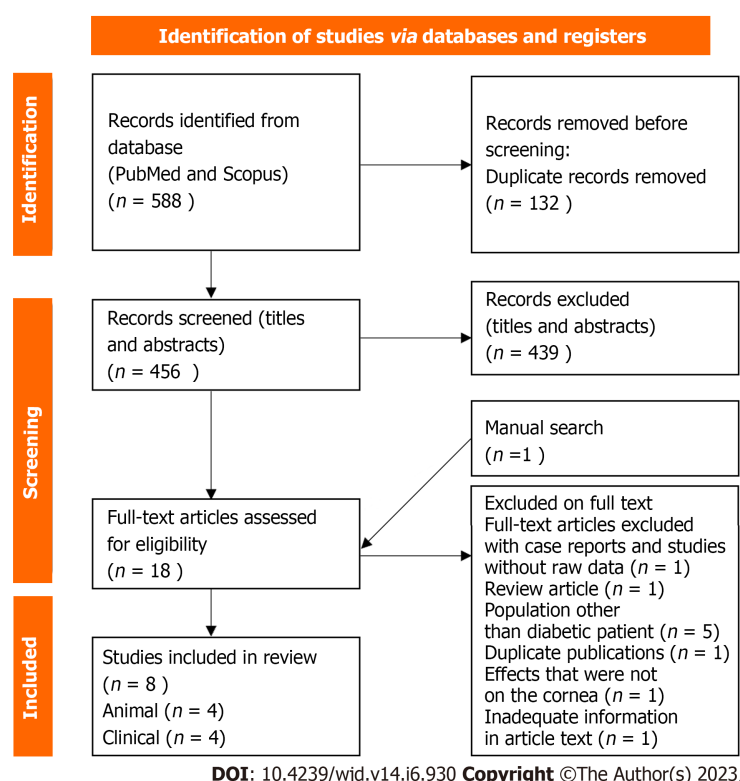


Figure 1 Flow diagram of the literature search.

mellitus rats for 4 wk prevented the depletion of nerves of the subbasal plexus without any effect on systemic glycemic control[15].

Yang *et al*[10] investigated the relationship between TI and the Wnt/ β -catenin signaling pathway in corneal epithelial healing and corneal nerve repair in diabetic mice. Type 1 diabetes was induced in 6- to 8-year-old male C57BL/6J mice. TI (3 μ L) was administered four times daily one week before and one week after corneal scraping. This study showed that TI stimulated the accumulation of β -catenin in the cell, activated the Wnt/ β -catenin signaling pathway, and finally stimulated cell proliferation. In addition, a preliminary study of this research showed that TI also promoted epithelial healing in mice with type 2 diabetes after corneal injury[10].

Clinical studies

Bastion and Ling[16] retrospectively reviewed 15 eyes of 14 patients who underwent corneal epithelial debridement during vitreoretinal surgery to improve the surgeon's view in 2010 over a 10-mo period. This study compared three groups: Patients with diabetes treated with TI 1 U/drop four times daily in addition to conventional postoperative therapy, patients with diabetes treated with conventional therapy, namely, topical antibiotics and steroids only, and nondiabetic patients treated with conventional therapy. TI (1 U) was prepared using Actrapid HM, Novo Nordisk, Denmark to provide 50 U/mL insulin at approximately 1 U per drop 4 times per day. Patients with diabetes treated with TI had significantly smaller defect sizes at 24, 36 and 48 h than patients with diabetes treated with conventional therapy. In addition, insulin-treated diabetic eyes re-epithelialized within 48 h, whereas conventionally treated eyes re-epithelialized within 72 h[16].

Fai *et al*[3] prospectively studied the effect of TI at three concentrations (0.5, 1, and 2 U per drop) *vs* placebo four times daily on the postoperative wound healing of corneal epithelium in patients with diabetes after vitreoretinal surgery. This work was a randomized, controlled, double-blind study. Thirty-two eyes of 32 patients with diabetes who underwent intraoperative corneal debridement with a Tooke's knife with resulting epithelial defects of various sizes were randomized into 3 different concentrations of TI or placebo. The insulin used was Actrapid HM 100 U/mL, as in the study by Bastion and Ling[16]. The results of this study showed that TI (0.5 U) was superior to the other insulin concentrations in achieving a 100% healing rate within 72 h. TI (0.5 U) 4 times a day (QID) was found to be most effective for healing corneal epithelial defects in patients with diabetes in this study compared to placebo and insulin at higher concentrations after vitrectomy. TI was also shown to be safe for use in the human eye[3].

Aniah Azmi and Bastion[17] evaluated the short-term effects of TI (1 U per drop) four times daily for one month on patients with diabetic dry eye disease (DDED). This work was a randomized, double-blind intervention study involving patients with diabetes with dry eye who were randomly assigned to

Table 1 Summary of the key characteristics of the included animal studies

Ref.	Country	Aim	Study design	Subject groups (number)	Insulin type and dose	Results
Nakamura <i>et al</i> [13], 2003	Japan	To study the effect of the combination of FGLM-NH2 and IGF-1 on corneal epithelial wound healing in rats with diabetes	Animal	4-wk-old male Sprague-Dawley Streptozocin-induced diabetic rats; 100 g (<i>n</i> = 20)	FGLM-NH2 (1 mmol/L) and IGF-1 (1 µg/mL) 6 times per day	Similar wound healing processes were observed in normal rats and diabetic rats treated with FGLM-NH2 and IGF-1. Wound closure was significantly faster in diabetic rats treated with FGLM-NH2 and IGF-1 than in those treated with vehicle
Zagon <i>et al</i> [14], 2007	United States	To determine TI normalizes delayed corneal wound healing in rats with diabetes	Animal	Male Sprague-Dawley Streptozocin-induced diabetic rats; 165 g (38 diabetic rats; 11 nondiabetic rats)	Bovine insulin 1, 2, or 5 U. Single drop (20 µL)	TI normalizes corneal re-epithelialization in diabetic rats. No difference in efficacy of insulin dose of 1, 2, or 5 U and safe for cornea
Chen <i>et al</i> [15], 2013	United States	To determine corneal nerve depletion in type 1 diabetes rats using corneal confocal microscopy and its relationship with TI	Animal	Female Swiss Webster Streptozocin-induced diabetic mice; 25-30 g (8 diabetic mice; 8 control)	0.1 IU of regular U-100 Humulin (Lilly, Indianapolis, IN, United States) in 10 µL saline	TI prevent depletion of nerve occupancy in the subbasal nerve plexus of the cornea without affecting systemic glycemic control
Yang <i>et al</i> [10], 2020	China	To investigate the relationship between TI and Wnt/β-catenin signaling pathway in corneal epithelial healing and corneal nerve repair in diabetic mice	Animal	Streptozocin-induced diabetic mice (6 to 8-year-old-male C57BL/6J mice)	Human neural insulin (Lilly France S.A., Fegersheim, France). 3 µL QID (1 IU/mL)	Insulin contributes to diabetic corneal epithelial wound healing and nerve injury healing <i>via</i> Wnt signaling, making it a potential protective factor for diabetic corneal epithelial wounds and nerve injuries

IGF-1: Insulin-like growth factor-1; FGLM-NH2: Substance P-derived tetrapeptide; TI: Topical insulin; U: Unit.

be treated with TI or artificial tears (AT). The insulin used was actrapid HM (Novo Nordisk, Bagsvaerd, Denmark). Patients were assessed at baseline, week 2, and week 4 of treatment. This study showed that TI and AT produced similar improvements in the Ocular Surface Disease Index in the treatment of dry eye in patients with diabetes, whose symptoms had improved after both therapies. However, TI worsened tear break-up time compared with baseline, but this did not differ from that of the AT group. Nevertheless, after one month of treatment, symptoms or clinical signs of DDED did not significantly differ between TI and AT[17].

Quiroz-Mendoza *et al*[18] compared the effect of TI and sodium hyaluronate on the healing of corneal epithelial defects in patients with diabetes after corneal epithelial debridement during pars plana vitrectomy. This study was a controlled clinical trial in which patients were randomly assigned to groups treated with TI 0.5 (IU/drops), 0.15% topical sodium hyaluronate (Hyabak®, Laboratorios Théa® México), or combined treatment with 0.5 IU/drop TI and 0.15% sodium hyaluronate. Insulin was prepared using recombinant human insulin (Humulin® R, Eli Lilly and Company, Indiana, United States). Patients were required to instill TI 4 times per day. Both treatments, *i.e.*, 0.5 IU/drop TI as monotherapy and TI combined with 0.15% sodium hyaluronate, were effective in treating corneal epithelial defects resulting from intraoperative corneal debridement during pars plana vitrectomy in patients with diabetes. The addition of sodium hyaluronate to TI did not provide a greater benefit than TI alone. No adverse effects were noted in this study[18].

Clinical studies on TI in other eye conditions

Wang *et al*[19] reviewed 6 patients with refractory neurotropic ulcers treated with TI. This study was a retrospective study of 6 patients with neurotropic corneal ulcers who did not respond to conventional medical and surgical treatments. The addition of TI resulted in rapid and complete corneal re-epithelialization after the initiation of treatment[19].

Diaz-Valle *et al*[20] evaluated treatment with TI for persistent epithelial defects (PED) refractory to conventional treatment. This study was a prospective, nonrandomized study that enrolled patients with refractory PEDs who did not respond to usual treatment. Patients were treated with insulin eye drops four times daily. This study demonstrated that TI accelerates corneal re-epithelialization and improves and safety promotes healing in PED patients who are not responsive to standard treatment[20].

Tong *et al*[21] reported a case of bilateral neurotropic keratitis that was unresponsive to conventional therapy and was successfully treated with 25 IU/mL TI six times daily in each eye. The neurotropic ulcers dramatically re-epithelialized within 1 wk. In this instance, TI was evidently successful in promoting re-epithelialization where other forms of treatment had failed[21].

Galvis *et al*[22] discussed a case diagnosed with exposure keratopathy after acoustic neuroma resection with involvement of the facial nerve and trigeminal nerve that developed into infectious

Table 2 Summary of the key characteristics of the included clinical studies

Ref.	Country	Aim	Study design	Subject groups (number)	Insulin type and dose	Results
Bastion and Ling [16], 2003	Malaysia	To determine whether TI improve healing rate of corneal epithelial erosion during vitreoretinal surgery	Retrospective review	Human (15 eyes of 14 patients underwent corneal debridement during vitreoretinal surgery)	Actrapid HM, Novo Nordisk 1 U QID (50 UI/mL)	Delayed epithelial healing in diabetic eyes compared with normal eyes. Diabetic eyes treated with TI had significantly smaller defect size than diabetic eyes treated with conventional therapy
Fai <i>et al</i> [3], 2017	Malaysia	To investigate the effect of 3 concentration of TI in corneal epithelial wound healing in postoperative patient with diabetes	Double blind randomized controlled	Human (32 eyes of 32 diabetic patient underwent corneal debridement during vitreoretinal surgery)	Actrapid HM, Novonordisk 0.5, 1, 2 U QID	TI 0.5 U QID is most effective for corneal re-epithelialization in patients with diabetes after vitrectomy surgery as compared with placebo and higher concentrations. TI is safe for human ocular use
Aniah Azmi and Bastion [17], 2020	Malaysia	To determine the short-term effects of TI on symptoms and signs of dry eye disease in patients with diabetes	Randomized, double-blind interventional study	Human (320 eyes of 160 patients with diabetes for treatment of dry eyes)	Actrapid HM, Novo Nordisk 1 U QID (25 UI/mL)	Similar improvement in the Ocular Surface Disease Index score for TI 1 U QID and standard artificial tears in the treatment of dry eye in patients with diabetes
Quiroz-Mendoza <i>et al</i> [18], 2021	Mexico	To compare the effect of TI and sodium hyaluronate in epithelial defects postoperative in patients with diabetes	Controlled human clinical trial	Human (36 eyes of 36 patients with diabetes who underwent corneal debridement during vitreoretinal surgery)	Recombinant human insulin (Humulin® R, Eli Lilly and Company, Indiana, United States) 0.5 IU/drop QID (25 IU/mL)	TI 0.5 IU/drops monotherapy and combined treatment with 0.15% sodium hyaluronate is effective in healing corneal epithelial defects after intraoperative corneal debridement in patients with diabetes. Adding sodium hyaluronate to TI did not provide additional benefit

TI: Topical insulin; U: Unit; QID: 4 times a day.

keratitis 2 wks after surgery. The patient had a persistent epithelial defect despite topical antibiotics, steroids, autologous serum drops, and bandage contact lenses. TI (1 UI/mL) was administered as adjuvant therapy four times daily, and the epithelial defect closed completely after 2 wks[22].

Ocular surface toxicity from insulin

Bartlett *et al* [23] conducted a prospective, randomized, single-masked study in 8 healthy volunteers on the safety of TI. Subjects were administered different concentrations: 0, 0.1, 1.0, 10.0, and 100 IU/mL TI in one eye and placebo in the other eye. They were evaluated immediately after instillation and 2 h after instillation. Several parameters were measured: Stinging, burning, tearing, itching, foreign body sensation, visual acuity and slit lamp examination. The results showed no significant difference in toxicity between the eyes receiving TI and those receiving placebo[23]. No adverse effect was observed in any of the published cases with the use of TI at concentrations up to 100 IU/mL.

Although all clinical data support the safety of TI, a stable formulation of TI is currently not commercially available. Le Nguyen *et al* [24] first introduced information on the stability of 1 UI/mL insulin eye drops. This study utilized the concentration reported for the effective treatment of refractory epithelial defects in both diabetic and nondiabetic eyes. The physicochemical and microbiological stability of the formulation of TI eye drops were evaluated. TI was prepared by diluting commercial Humalog insulin Lispro solution (100 UI/mL) with polyethylene and propylene glycol-based artificial eye drops to a concentration of 1 UI/mL. The resultant solution was stored in a multidose eyedropper made of low-density polyethylene. The stability of this TI formulation was studied at 4 °C for 12 mo in unopened eyedroppers and under stimulated use conditions at 4 °C and 25 °C for 30 d. The parameters studied for physicochemical stability were visual inspection, pH, turbidity, ultraviolet spectral absorption and osmolality.

In addition, insulin and m-cresol concentrations were tested using a new size-exclusion chromatographic method. The results showed that all tested parameters were favorable, and unopened eye droppers were physicochemically and microbiologically stable at 4 °C for 12 mo. Under stimulated eye conditions, these parameters also remained stable at 4 °C for one month. Furthermore, a similar result was observed when solutions were stored at 25 °C under stimulated eye conditions, with no effect of potential temperature increases on the insulin and m-cresol concentrations in the insulin eyedropper [24]. Studies on the stability of studies utilizing higher concentrations of insulin, such as those described in the various clinical studies on diabetic eyes with epithelial defects or DDED mentioned earlier in this review, are currently lacking. Studies on the stability of TI in various types of AT are also lacking.

Applications of machine-learning analysis

Artificial intelligence (AI) has been developed and used in the field of ophthalmology. The majority of AI research in the past has focused on posterior segment diseases, such as glaucoma, retinopathy of prematurity, and optic neuropathy[25]. In recent years, an increasing number of studies have employed AI to recognize different keratopathies. The use of AI in DED, particularly automatic DED detection and categorization, has tremendous potential[26]. The study of DED using machine learning may aid in the diagnosis and monitoring of treatments, such as TI.

Limitations

This study was subject to limitations. The literature included in this study used a variety of types, dosages and methods of dilution of TI. The methodology to assess outcomes in each study, such as cornea wound size and rate, also varied. For animal studies, different types of rats and ages were used, and the sample sizes were small. In addition, the sample sizes of clinical studies were also small, and the types of diabetic keratopathies were different.

CONCLUSION

Treatment with TI is effective in treating DK, including DDED, epithelial defects after corneal debridement and refractory epithelial defects. It offers many advantages, including excellent tolerability, availability, cost-effectiveness and, most importantly, safety when applied to the human eye, without adverse events. More studies are needed to determine its stability in normal saline and in AT of various types, and the advantage of combining TI with AT to increase its contact time and reduce the need for frequent dosing warrants further study.

ARTICLE HIGHLIGHTS

Research background

Diabetic keratopathy (DK) is one of the complications of diabetes mellitus. In diabetic patients, any corneal epithelial defect or ulcer takes longer to heal and persists longer. Treatment with topical insulin (TI) is effective in treating DK.

Research motivation

Insulin is an effective factor in wound healing. The ability of systemic insulin to rapidly heal burn wounds has been reported for nearly a century, but only a few studies have been performed on the effects of TI on the eye.

Research objectives

The aim of the study is to review clinical and experimental animal studies providing evidence for the efficacy of TI to heal corneal wounds.

Research methods

To evaluate the efficacy of TI application on corneal wound healing, the published literature was reviewed systematically for publication. The available data was then thoroughly reviewed.

Research results

Eight articles in total, comprising four animal studies and four clinical studies, were identified and discussed. According to the studies conducted, TI is effective for corneal re-epithelialization in patients with diabetes based on corneal wound size and healing rate.

Research conclusions

Treatment with TI is effective in treating DK. It offers many advantages, including excellent tolerability, availability, cost-effectiveness and, most importantly, safety when applied to the human eye, without adverse events. Further studies are needed to enhance our knowledge and understanding of TI in the healing of DK.

Research perspectives

TI promotes corneal wound healing and was not associated with adverse effects in any of the published cases. More studies are needed to determine its stability in normal saline and in artificial tear (AT) of various types, and the advantage of combining TI with AT to increase its contact time and reduce the need for frequent dosing warrants further study.

FOOTNOTES

Author contributions: Leong CY, Naffi AA, Bastion MLC and Wan Abdul Hamid WH designed the research study; all authors performed the research and screened for relevant articles; Leong CY and Naffi AA analyzed the data and wrote the manuscript; Bastion MLC revised the manuscript and formatted the article; Wan Abdul Hamid WH evaluated the writing and made further amendments to it.

Conflict-of-interest statement: Bastion MLC received fees for serving as a speaker and/or an advisory board member for Novartis, Alcon, and Santen. She received fees for serving as a speaker for Bayer, Lumibird, and Allergan. She has received research funding from Alcon, Novartis, Santen, TRB Chemedica, IDB healthcare, and National University of Malaysia. She is an employee of the National University of Malaysia. Wan Abdul Halim WH received travel funding from Santen. She is also a key opinion leader for Oculus GMBH. She is an employee of Universiti Kebangsaan Malaysia. Leong CY and Naffi AA have no conflict of interest to disclose.

PRISMA 2009 Checklist statement: The authors have read the PRISMA 2009 Checklist, and the manuscript was prepared and revised according to the PRISMA 2009 Checklist.

Open-Access: This article is an open-access article that was selected by an in-house editor and fully peer-reviewed by external reviewers. It is distributed in accordance with the Creative Commons Attribution NonCommercial (CC BY-NC 4.0) license, which permits others to distribute, remix, adapt, build upon this work non-commercially, and license their derivative works on different terms, provided the original work is properly cited and the use is non-commercial. See: <https://creativecommons.org/licenses/by-nc/4.0/>

Country/Territory of origin: Malaysia

ORCID number: Ching Yee Leong 0000-0002-3779-1032; Ainal Adlin Naffi 0000-0002-4682-6620; Wan Haslina Wan Abdul Halim 0000-0001-9140-4040; Mae-Lynn Catherine Bastion 0000-0002-6856-8052.

S-Editor: Wang JJ

L-Editor: A

P-Editor: Cai YX

REFERENCES

- 1 **Cho NH**, Shaw JE, Karuranga S, Huang Y, da Rocha Fernandes JD, Ohlrogge AW, Malanda B. IDF Diabetes Atlas: Global estimates of diabetes prevalence for 2017 and projections for 2045. *Diabetes Res Clin Pract* 2018; **138**: 271-281 [PMID: 29496507 DOI: 10.1016/j.diabres.2018.02.023]
- 2 **Priyadarsini S**, Whelchel A, Nicholas S, Sharif R, Riaz K, Karamichos D. Diabetic keratopathy: Insights and challenges. *Surv Ophthalmol* 2020; **65**: 513-529 [PMID: 32092364 DOI: 10.1016/j.survophthal.2020.02.005]
- 3 **Fai S**, Ahem A, Mustapha M, Mohd Noh UK, Bastion MC. Randomized Controlled Trial of Topical Insulin for Healing Corneal Epithelial Defects Induced During Vitreoretinal Surgery in Diabetics. *Asia Pac J Ophthalmol (Phila)* 2017; **6**: 418-424 [PMID: 28828764 DOI: 10.22608/APO.201780]
- 4 **Milner MS**, Beckman KA, Luchs JI, Allen QB, Awdeh RM, Berdahl J, Boland TS, Buznego C, Gira JP, Goldberg DF, Goldman D, Goyal RK, Jackson MA, Katz J, Kim T, Majmudar PA, Malhotra RP, McDonald MB, Rajpal RK, Raviv T, Rowen S, Shamie N, Solomon JD, Stonecipher K, Tauber S, Trattler W, Walter KA, Waring GO 4th, Weinstock RJ, Wiley WF, Yeu E. Dysfunctional tear syndrome: dry eye disease and associated tear film disorders - new strategies for diagnosis and treatment. *Curr Opin Ophthalmol* 2017; **27** Suppl 1: 3-47 [PMID: 28099212 DOI: 10.1097/01.icu.0000512373.81749.b7]
- 5 **Dogru M**, Okada N, Asano-Kato N, Tanaka M, Igarashi A, Takano Y, Fukagawa K, Shimazaki J, Tsubota K, Fujishima H. Atopic ocular surface disease: implications on tear function and ocular surface mucins. *Cornea* 2005; **24**: S18-S23 [PMID: 16227818 DOI: 10.1097/01.icu.0000178741.14212.53]
- 6 **Zhang X**, Zhao L, Deng S, Sun X, Wang N. Dry Eye Syndrome in Patients with Diabetes Mellitus: Prevalence, Etiology, and Clinical Characteristics. *J Ophthalmol* 2016; **2016**: 8201053 [PMID: 27213053 DOI: 10.1155/2016/8201053]
- 7 **Georgakopoulos CD**, Makri OE, Pagoulatos D, Vasilakis P, Peristeropoulou P, Kouli V, Eliopoulou MI, Psachoulia C. Effect of Omega-3 Fatty Acids Dietary Supplementation on Ocular Surface and Tear Film in Diabetic Patients with Dry Eye. *J Am Coll Nutr* 2017; **36**: 38-43 [PMID: 27797641 DOI: 10.1080/07315724.2016.1170643]
- 8 **Midena E**, Brugin E, Ghirlando A, Somavilla M, Avogaro A. Corneal diabetic neuropathy: a confocal microscopy study. *J Refract Surg* 2006; **22**: S1047-S1052 [PMID: 17444092 DOI: 10.3928/1081-597X-20061102-08]
- 9 **Shanley LJ**, McCaig CD, Forrester JV, Zhao M. Insulin, not leptin, promotes *in vitro* cell migration to heal monolayer wounds in human corneal epithelium. *Invest Ophthalmol Vis Sci* 2004; **45**: 1088-1094 [PMID: 15037573 DOI: 10.1167/iovs.03-1064]
- 10 **Yang S**, Zhang Y, Zhang Z, Dan J, Zhou Q, Wang X, Li W, Zhou L, Yang L, Xie L. Insulin Promotes Corneal Nerve Repair and Wound Healing in Type 1 Diabetic Mice by Enhancing Wnt/ β -Catenin Signaling. *Am J Pathol* 2020; **190**: 2237-2250 [PMID: 32858016 DOI: 10.1016/j.ajpath.2020.08.006]
- 11 **Cruz-Cazarim ELC**, Cazarim MS, Ogunjimi AT, Petrilli R, Rocha EM, Lopez RFV. Prospective insulin-based ophthalmic delivery systems for the treatment of dry eye syndrome and corneal injuries. *Eur J Pharm Biopharm* 2019;

- 140: 1-10 [PMID: [31015020](#) DOI: [10.1016/j.ejpb.2019.04.014](#)]
- 12 **Rocha EM**, Cunha DA, Carneiro EM, Boscherio AC, Saad MJ, Velloso LA. Identification of insulin in the tear film and insulin receptor and IGF-1 receptor on the human ocular surface. *Invest Ophthalmol Vis Sci* 2002; **43**: 963-967 [PMID: [11923235](#)]
- 13 **Nakamura M**, Kawahara M, Morishige N, Chikama T, Nakata K, Nishida T. Promotion of corneal epithelial wound healing in diabetic rats by the combination of a substance P-derived peptide (FGLM-NH₂) and insulin-like growth factor-1. *Diabetologia* 2003; **46**: 839-842 [PMID: [12764579](#) DOI: [10.1007/s00125-003-1105-9](#)]
- 14 **Zagon IS**, Kloczek MS, Sassani JW, McLaughlin PJ. Use of topical insulin to normalize corneal epithelial healing in diabetes mellitus. *Arch Ophthalmol* 2007; **125**: 1082-1088 [PMID: [17698755](#) DOI: [10.1001/archophth.125.8.1082](#)]
- 15 **Chen DK**, Frizzi KE, Guernsey LS, Ladit K, Mizisin AP, Calcutt NA. Repeated monitoring of corneal nerves by confocal microscopy as an index of peripheral neuropathy in type-1 diabetic rodents and the effects of topical insulin. *J Peripher Nerv Syst* 2013; **18**: 306-315 [PMID: [24147903](#) DOI: [10.1111/jns5.12044](#)]
- 16 **Bastion ML**, Ling KP. Topical insulin for healing of diabetic epithelial defects? *Med J Malaysia* 2013; **68**: 208-216 [PMID: [23749008](#)]
- 17 **Aniah Azmi N**, Bastion MC. Short-Term Results of Trial of Topical Insulin for Treatment of Dry Eyes in Diabetics. *Eye Contact Lens* 2020; **46** Suppl 1: S25-S32 [PMID: [31145207](#) DOI: [10.1097/ICL.0000000000000623](#)]
- 18 **Quiroz-Mendoza JL**, Garcia Roa MR, Marlon VR, Valera-Cornejo DA, Vazquez Membrillo MA, Ramirez Neria P, Villalpando-Gomez Y, Garcia-Franco Y. Clinical trial of topical insulin and sodium hyaluronate in the treatment of epithelial defects produced by intraoperative corneal epithelial debridement during pars plana vitrectomy in diabetics. *Revista Mexicana de Oftalmología (English Edition)* 2021; **95** [DOI: [10.24875/RMOE.M21000157](#)]
- 19 **Wang AL**, Weinlander E, Metcalf BM, Barney NP, Gamm DM, Nehls SM, Struck MC. Use of Topical Insulin to Treat Refractory Neurotrophic Corneal Ulcers. *Cornea* 2017; **36**: 1426-1428 [PMID: [28742619](#) DOI: [10.1097/ICO.0000000000001297](#)]
- 20 **Diaz-Valle D**, Burgos-Blasco B, Gegundez-Fernandez JA, Garcia-Caride S, Puebla-Garcia V, Peña-Urbina P, Benitez-Del-Castillo JM. Topical insulin for refractory persistent corneal epithelial defects. *Eur J Ophthalmol* 2021; **31**: 2280-2286 [PMID: [32951459](#) DOI: [10.1177/1120672120958307](#)]
- 21 **Tong CM**, Iovieno A, Yeung SN. Topical insulin for neurotrophic corneal ulcers. *Can J Ophthalmol* 2020; **55**: e170-e172 [PMID: [32416928](#) DOI: [10.1016/j.cjco.2020.04.001](#)]
- 22 **Galvis V**, Niño CA, Tello A, Grice JM, Gómez MA. Topical insulin in neurotrophic keratopathy after resection of acoustic neuroma. *Arch Soc Esp Oftalmol (Engl Ed)* 2019; **94**: 100-104 [PMID: [30025986](#) DOI: [10.1016/j.oftal.2018.06.003](#)]
- 23 **Bartlett JD**, Turner-Henson A, Atchison JA, Woolley TW, Pillion DJ. Insulin administration to the eyes of normoglycemic human volunteers. *J Ocul Pharmacol* 1994; **10**: 683-690 [PMID: [7714412](#) DOI: [10.1089/jop.1994.10.683](#)]
- 24 **Le Nguyen MH**, Naoum MS, Andre C, Lethier L, Limat S, Fagnoni-Legat C, Guillaume Y, Gauthier AS. Physicochemical and microbiological stability of insulin eye drops in an artificial tear vehicle used in the treatment of refractory neurotrophic keratopathy. *J Fr Ophthalmol* 2022; **45**: 860-871 [PMID: [35914962](#) DOI: [10.1016/j.jfo.2022.04.008](#)]
- 25 **Ji Y**, Liu S, Hong X, Lu Y, Wu X, Li K, Liu Y. Advances in artificial intelligence applications for ocular surface diseases diagnosis. *Front Cell Dev Biol* 2022; **10**: 1107689 [PMID: [36605721](#) DOI: [10.3389/fcell.2022.1107689](#)]
- 26 **Storås AM**, Strömke I, Riegler MA, Grauslund J, Hammer HL, Yazidi A, Halvorsen P, Gundersen KG, Uttheim TP, Jackson CJ. Artificial intelligence in dry eye disease. *Ocul Surf* 2022; **23**: 74-86 [PMID: [34843999](#) DOI: [10.1016/j.jtos.2021.11.004](#)]



Published by **Baishideng Publishing Group Inc**
7041 Koll Center Parkway, Suite 160, Pleasanton, CA 94566, USA

Telephone: +1-925-3991568

E-mail: bpgoffice@wjgnet.com

Help Desk: <https://www.f6publishing.com/helpdesk>

<https://www.wjgnet.com>

