

# World Journal of *Clinical Cases*

*World J Clin Cases* 2023 August 26; 11(24): 5628-5839



## MINIREVIEWS

- 5628 Effect of pesticides on phosphorylation of tau protein, and its influence on Alzheimer's disease  
*Torres-Sánchez ED, Ortiz GG, Reyes-Urbe E, Torres-Jasso JH, Salazar-Flores J*

## ORIGINAL ARTICLE

## Case Control Study

- 5643 Reduction rate of monoclonal protein as a useful prognostic factor in standard-risk group of newly diagnosed multiple myeloma  
*Liu M, Zhang JY*

## Retrospective Cohort Study

- 5653 Effectiveness of treating menorrhagia using microwave endometrial ablation at a frequency of 2.45 GHz  
*Kakinuma T, Kaneko A, Kakinuma K, Matsuda Y, Yanagida K, Takeshima N, Ohwada M*
- 5660 Benefits of laparoscopy-assisted ileostomy in colorectal cancer patients with bowel obstruction  
*Wang YJ, Lin KH, Kang JC, Hu JM, Chen CY, Pu TW*

## Retrospective Study

- 5666 Hypopharyngeal cancer trends in a high-incidence region: A retrospective tertiary single center study  
*Cordunianu AGV, Ganea G, Cordunianu MA, Cochior D, Moldovan CA, Adam R*
- 5678 Relevant detection indicator of prethrombotic state in patients with primary hypertension  
*Luo J, Yang T, Ding L, Xiong JH, Ying T, Xu F*
- 5692 Clinical study of extrahepatic biliary adenoma  
*Li W, Tao J, Song XG, Hou MR, Qu K, Gu JT, Yan XP, Yao BW, Qin YF, Dong FF, Sha HC*

## SYSTEMATIC REVIEWS

- 5700 Sodium-glucose cotransporter-2 inhibitor-associated euglycemic diabetic ketoacidosis in COVID-19-infected patients: A systematic review of case reports  
*Khedr A, Hennawi HA, Khan MK, Eissa A, Mir M, Rauf I, Nitesh J, Surani S, Khan SA*

## META-ANALYSIS

- 5710 Efficacy and safety of Huangqi Jianzhong decoction in the treatment of chronic atrophic gastritis: A meta-analysis  
*Yan XP, Si W, Ding MS, Tian YF, Guo Z*

## CASE REPORT

- 5721** Malignant melanoma of the prostate: Primary or metastasis? A case report  
*Zhao H, Liu C, Li B, Guo JM*
- 5729** Intravenous leiomyoma of the uterus extending to the pulmonary artery: A case report  
*Huang YQ, Wang Q, Xiang DD, Gan Q*
- 5736** Percutaneous endoscopic necrosectomy for walled-off necrosis in the retroperitoneal space of the elderly: A case report  
*Sato K, Shibukawa G, Ueda K, Nakajima Y, Togashi K, Ohira H*
- 5742** Acute exacerbation of idiopathic pulmonary fibrosis treated using the Feibi recipe: Two case reports  
*Liu ZH, Li GD, Hao QX, Cao F, Cheng Y, Kou MJ, Jiao Y*
- 5749** Neonatal erythema multiforme associated with a rotavirus infection: A case report  
*Kim JJ, Lee JK*
- 5755** Hemorrhagic Bartholin's cyst in a woman using anti-platelet medication: A case report and review of the literature  
*Li YR, Ding DC*
- 5762** Subintimal recanalization for non-acute occlusion of intracranial vertebral artery in an emergency endovascular procedure: A case report  
*Fu JF, Zhang XL, Lee SY, Zhang FM, You JS*
- 5772** Synchronous rectal adenocarcinoma and intestinal mantle cell lymphoma: A case report  
*Vu KV, Trong NV, Khuyen NT, Huyen Nga D, Anh H, Tien Trung N, Trung Thong P, Minh Duc N*
- 5780** Focal lymphoblastic transformation of chronic myelogenous leukemia develops into erythroid leukemia: A case report  
*Wang W, Chen YL, Gou PP, Wu PL, Shan KS, Zhang DL*
- 5789** Intraoperative sudden arrhythmias in cervical spine surgery adjacent to the stellate ganglion: A case report  
*Seo JH, Cho SY, Park JH, Seo JY, Lee HY, Kim DJ*
- 5797** Papillary thyroid carcinoma with nodular fasciitis-like stroma - an unusual variant with distinctive histopathology: A case report  
*Hu J, Wang F, Xue W, Jiang Y*
- 5804** Malignant form of hidroacanthoma simplex: A case report  
*Yang YF, Wang R, Xu H, Long WG, Zhao XH, Li YM*
- 5811** Penile and scrotal strangulation by stainless steel rings in an human immunodeficiency virus positive man: A case report  
*Usuda D, Kaminishi N, Kato M, Sugawara Y, Shimizu R, Inami T, Tsuge S, Sakurai R, Kawai K, Matsubara S, Tanaka R, Suzuki M, Shimozawa S, Hotchi Y, Osugi I, Katou R, Ito S, Mishima K, Kondo A, Mizuno K, Takami H, Komatsu T, Oba J, Nomura T, Sugita M*

- 5817** Persistent postoperative hypotension caused by subclinical empty sella syndrome after a simple surgery: A case report  
*Zhao KM, Hu JS, Zhu SM, Wen TT, Fang XM*
- 5823** Rare *ROS1-CENPW* gene in pancreatic acinar cell carcinoma and the effect of crizotinib plus AG chemotherapy: A case report  
*Wang T, Shen YY*
- 5830** Fecal transplantation in patient with metastatic melanoma refractory to immunotherapy: A case report  
*del Giglio A, Atui FC*
- 5835** Left hepatic artery pseudoaneurysm complicating endoscopic retrograde cholangiopancreatography: A case report  
*Li QM, Ye B, Yang SW, Zhao H*

**ABOUT COVER**

Editorial Board Member of *World Journal of Clinical Cases*, Kelser de Souza Kock, PhD, Physiotherapist, Professor, Department of Physiotherapy/Medicine, University of South of Santa Catarina, Tubarão 88700000, SC, Brazil. [kelserkock@yahoo.com.br](mailto:kelserkock@yahoo.com.br)

**AIMS AND SCOPE**

The primary aim of *World Journal of Clinical Cases* (*WJCC*, *World J Clin Cases*) is to provide scholars and readers from various fields of clinical medicine with a platform to publish high-quality clinical research articles and communicate their research findings online.

*WJCC* mainly publishes articles reporting research results and findings obtained in the field of clinical medicine and covering a wide range of topics, including case control studies, retrospective cohort studies, retrospective studies, clinical trials studies, observational studies, prospective studies, randomized controlled trials, randomized clinical trials, systematic reviews, meta-analysis, and case reports.

**INDEXING/ABSTRACTING**

The *WJCC* is now abstracted and indexed in Science Citation Index Expanded (SCIE, also known as SciSearch®), Journal Citation Reports/Science Edition, Current Contents®/Clinical Medicine, PubMed, PubMed Central, Reference Citation Analysis, China National Knowledge Infrastructure, China Science and Technology Journal Database, and Superstar Journals Database. The 2023 Edition of Journal Citation Reports® cites the 2022 impact factor (IF) for *WJCC* as 1.1; IF without journal self cites: 1.1; 5-year IF: 1.3; Journal Citation Indicator: 0.26; Ranking: 133 among 167 journals in medicine, general and internal; and Quartile category: Q4.

**RESPONSIBLE EDITORS FOR THIS ISSUE**

Production Editor: *Ying-Yi Yuan*; Production Department Director: *Xu Guo*; Editorial Office Director: *Jin-Lei Wang*.

**NAME OF JOURNAL**

*World Journal of Clinical Cases*

**ISSN**

ISSN 2307-8960 (online)

**LAUNCH DATE**

April 16, 2013

**FREQUENCY**

Thrice Monthly

**EDITORS-IN-CHIEF**

Bao-Gan Peng, Jerzy Tadeusz Chudek, George Kontogeorgos, Maurizio Serati, Ja Hyeon Ku

**EDITORIAL BOARD MEMBERS**

<https://www.wjgnet.com/2307-8960/editorialboard.htm>

**PUBLICATION DATE**

August 26, 2023

**COPYRIGHT**

© 2023 Baishideng Publishing Group Inc

**INSTRUCTIONS TO AUTHORS**

<https://www.wjgnet.com/bpg/gerinfo/204>

**GUIDELINES FOR ETHICS DOCUMENTS**

<https://www.wjgnet.com/bpg/GerInfo/287>

**GUIDELINES FOR NON-NATIVE SPEAKERS OF ENGLISH**

<https://www.wjgnet.com/bpg/gerinfo/240>

**PUBLICATION ETHICS**

<https://www.wjgnet.com/bpg/GerInfo/288>

**PUBLICATION MISCONDUCT**

<https://www.wjgnet.com/bpg/gerinfo/208>

**ARTICLE PROCESSING CHARGE**

<https://www.wjgnet.com/bpg/gerinfo/242>

**STEPS FOR SUBMITTING MANUSCRIPTS**

<https://www.wjgnet.com/bpg/GerInfo/239>

**ONLINE SUBMISSION**

<https://www.f6publishing.com>



## Malignant melanoma of the prostate: Primary or metastasis? A case report

Hong Zhao, Chun Liu, Bin Li, Jian-Ming Guo

**Specialty type:** Medicine, research and experimental

**Provenance and peer review:** Unsolicited article; Externally peer reviewed.

**Peer-review model:** Single blind

**Peer-review report's scientific quality classification**

Grade A (Excellent): A  
Grade B (Very good): 0  
Grade C (Good): C, C, C  
Grade D (Fair): 0  
Grade E (Poor): 0

**P-Reviewer:** Bagheri-Mohammadi S, Iran; Sahin TT, Turkey; Sarier M, Turkey

**Received:** April 5, 2023

**Peer-review started:** April 5, 2023

**First decision:** May 15, 2023

**Revised:** May 24, 2023

**Accepted:** August 3, 2023

**Article in press:** August 3, 2023

**Published online:** August 26, 2023



**Hong Zhao**, Department of Urology, Shanghai Xu-Hui Central Hospital, Shanghai 200001, China

**Chun Liu**, Department of Radiology, Shanghai Xu-Hui Central Hospital, Shanghai 200001, China

**Bin Li**, Department of Pathology, Shanghai Xu-Hui Central Hospital, Shanghai 200001, China

**Jian-Ming Guo**, Department of Urology, Zhongshan Hospital, Fudan University, Shanghai 200001, China

**Corresponding author:** Jian-Ming Guo, MD, PhD, Academic Editor, Doctor, Department of Urology, Zhongshan Hospital, Fudan University, No. 180 Fenglin Road, Shanghai 200001, China. [drguojm@126.com](mailto:drguojm@126.com)

### Abstract

#### BACKGROUND

Malignant melanoma of the prostate is rare. Twenty-five studies describing 45 cases have been reported. Prostate melanoma is characterized by an insidious onset and poor prognosis. The prognosis and treatment vary according to primary or secondary melanoma.

#### CASE SUMMARY

A 75-year-old man attended the hospital due to low back pain of 2 mo duration. He denied a history of trauma or abnormal urinary symptoms. Digital rectal examination showed indentation in the left lobe of the prostate, 1 cm in diameter. His prostate-specific antigen was 5.6 ng/mL and  $^{18}\text{F}$ -fluorodeoxyglucose positron emission tomography computed tomography ( $^{18}\text{F}$ -FDG-PET/CT) showed focal glucose metabolism in the left lobe. Imaging showed bone metastases to T12 and bilateral ribs. Transperineal prostate biopsy was done and three tissue specimens on the left side showed prostate adenocarcinoma (Gleason score  $3 + 3 = 6$ ), but the specimen on the right side showed malignant melanoma. The patient underwent T12 tumor resection and pathology findings indicated metastatic malignant melanoma. The patient underwent gastroscopy and colonoscopy, and gastroscopy revealed multiple mucosal black spots in the gastric body and fundus. The patient was diagnosed with secondary malignant prostate melanoma and primary gastric disease.

#### CONCLUSION

Diagnosis of primary prostate melanoma requires caution and  $^{18}\text{F}$ -FDG-PET/CT may result in false-negative detection of melanoma.

**Key Words:** Melanoma; Prostate; Primary; Metastases; Diagnosis; Case report

©The Author(s) 2023. Published by Baishideng Publishing Group Inc. All rights reserved.

**Core Tip:** Malignant melanoma of the prostate is rare. To date, 25 studies describing 45 cases have been reported. There is a significant difference in prognosis between primary and secondary cases. We report a case of secondary malignant prostate melanoma with primary gastric disease. We also review the literature on 10 cases of primary prostate melanoma, and found that most cases did not receive sufficient tests and  $^{18}\text{F}$ -fluorodeoxyglucose positron emission tomography computed tomography ( $^{18}\text{F}$ -FDG-PET/CT) was false-negative. We conclude that caution should be used in the diagnosis of primary prostate melanoma, and  $^{18}\text{F}$ -FDG-PET/CT may result in false-negative detection of melanoma.

**Citation:** Zhao H, Liu C, Li B, Guo JM. Malignant melanoma of the prostate: Primary or metastasis? A case report. *World J Clin Cases* 2023; 11(24): 5721-5728

**URL:** <https://www.wjgnet.com/2307-8960/full/v11/i24/5721.htm>

**DOI:** <https://dx.doi.org/10.12998/wjcc.v11.i24.5721>

## INTRODUCTION

Malignant melanoma, derived from melanocytes, mainly occurs in the skin, but can also be seen in the mucosa and internal organs, accounting for approximately 3% of all tumors[1]. Melanoma of the genitourinary tract is a rare disease, representing < 1% of all melanomas in men[2]. The majority develop from the penis and distal urethra, and melanoma of the prostate is even rarer; most are of prostatic urothelial origin or secondary to metastatic disease[3], and only 10 cases of primary melanoma of the prostate[4-13] and several cases of metastasis[14-17] have been reported in the English-language literature.

## CASE PRESENTATION

### Chief complaints

A 75-year-old man attended the hospital due to low back pain of 2 mo duration.

### History of present illness

The patient had no history of trauma, tumor, and skin melanoma, and no recent weight loss. He also had no urinary symptoms.

### History of past illness

The patient had a free previous medical history.

### Personal and family history

The patient denied family history of melanoma.

### Physical examination

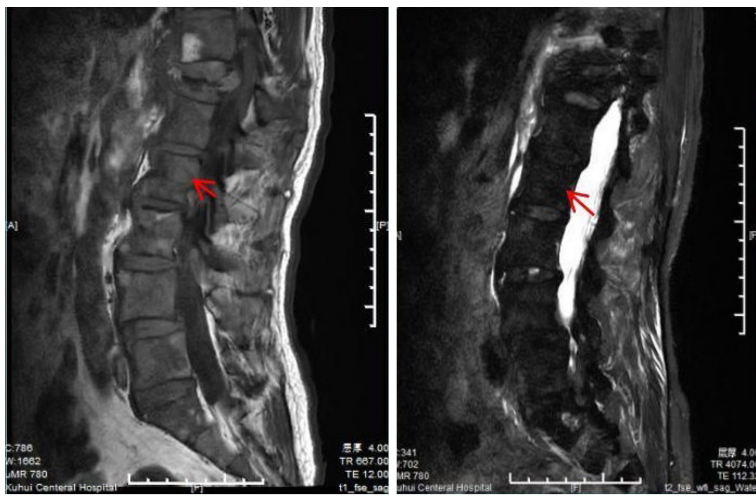
Digital rectal examination showed an indentation in the left lobe of the prostate, which was 1 cm in diameter.

### Laboratory examinations

Laboratory tests showed an abnormal level of prostate-specific antigen (PSA), which was 5.6 ng/mL, and free PSA/total PSA was 13.19%. His hemoglobin was 114 g/L and lactate dehydrogenase was 376 U/L. Other biochemical tests were within the reference range.

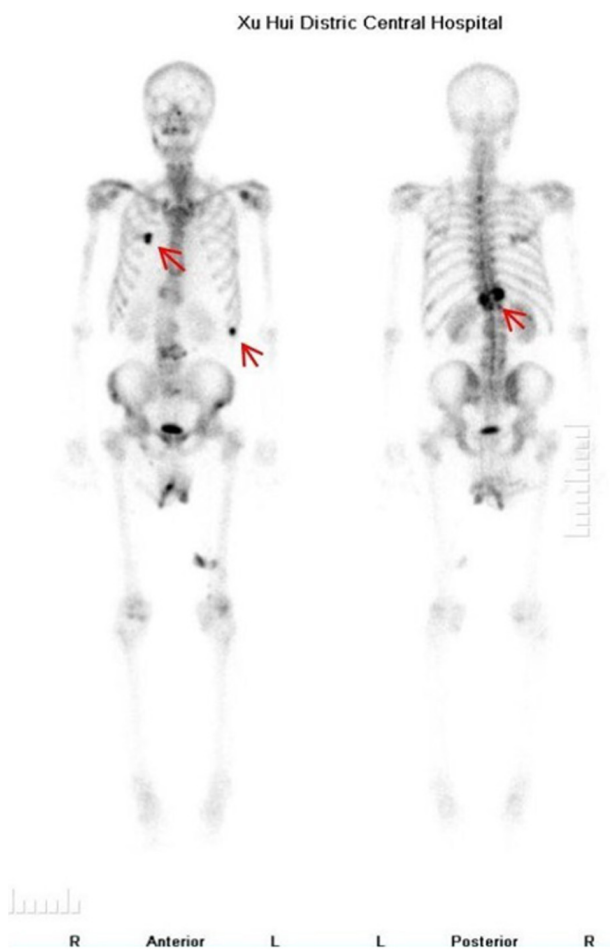
### Imaging examinations

Lumbar magnetic resonance imaging (MRI) showed multiple abnormal signals in the bone, indicating possible metastatic tumors, and compressed bone in thoracic (T12) vertebrae (Figure 1), with a high T1 signal and a low T2 signal. Bone single photon emission computed tomography showed T12 compression of whole body bone, with a concentration of radioactivity in bilateral ribs, and bone metastases were considered (Figure 2).



DOI: 10.12998/wjcc.v11.i24.5721 Copyright ©The Author(s) 2023.

Figure 1 Compressed bone of thoracic 12 vertebrae showing a high T1 signal and low T2 signal.

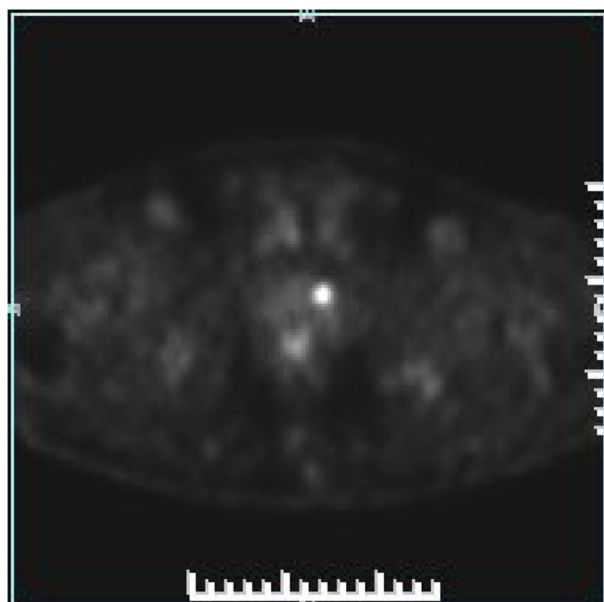


DOI: 10.12998/wjcc.v11.i24.5721 Copyright ©The Author(s) 2023.

Figure 2 Bone single photon emission tomography/computed tomography showing T12 compression of the whole body bone, and the concentration of radioactivity in bilateral ribs, thus bone metastasis was considered.

Positron emission tomography (PET)/computed tomography (CT) showed benign prostate hyperplasia, focal glucose metabolism in the left lobe, a malignant tumor waiting to be excreted, and puncture biopsy was recommended. Extensive bone lesions in the whole body were considered large metastases, and multiple small lymph nodes in the retroperitoneal and left pelvic wall required close follow-up (Figure 3).





DOI: 10.12998/wjcc.v11.i24.5721 Copyright ©The Author(s) 2023.

**Figure 3**  $^{18}\text{F}$ -fluorodeoxyglucose positron emission tomography/computed tomography showing focal glucose metabolism in the left lobe of the prostate, and a malignant tumor waiting to be excreted.

### Further diagnostic work-up

The patient underwent a transperineal prostate biopsy. Six tissue specimens were obtained. Three on the left side showed prostate adenocarcinoma (Gleason score 3+3=6), grade 1 (Figure 4A), and one on the right side showed small foci of melanocytes in the proliferative prostate tissue (Figure 4B). Immunohistochemical results were as follows: S100<sup>+</sup>, Ki-67<sup>+</sup> 10%, CD68, SOX10<sup>+</sup>, Melan A<sup>+</sup>, P40, and HMB45<sup>+</sup> (Figure 4C).

The patient underwent gastroscopy and colonoscopy, and gastroscopy revealed multiple mucosal black spots in the body and fundus of the stomach (Figure 5A). A mucosal biopsy showed acute chronic nonatrophic gastritis in the antrum. Alcian Blue-Periodic Acid-Schiff in the gastric body suggested malignant melanoma. Immunohistochemical results were as follows: tumor cells S100<sup>+</sup>, HMB45<sup>+</sup>, AE1/AE3, p53<sup>+</sup>, Ki-67<sup>+</sup> 3%, CD68, SOX10<sup>+</sup>, and Melan A<sup>+</sup> (Figure 5B).

The patient underwent T12 tumor resection, spinal canal decompression and vertebroplasty. Black lesions were found on the thoracic vertebrae and lumbar appendages. Pathology findings indicated metastatic malignant melanocytoma.

## FINAL DIAGNOSIS

This patient was diagnosed with primary prostate adenocarcinoma, gastric melanoma with bone metastases, and prostate metastases.

## TREATMENT

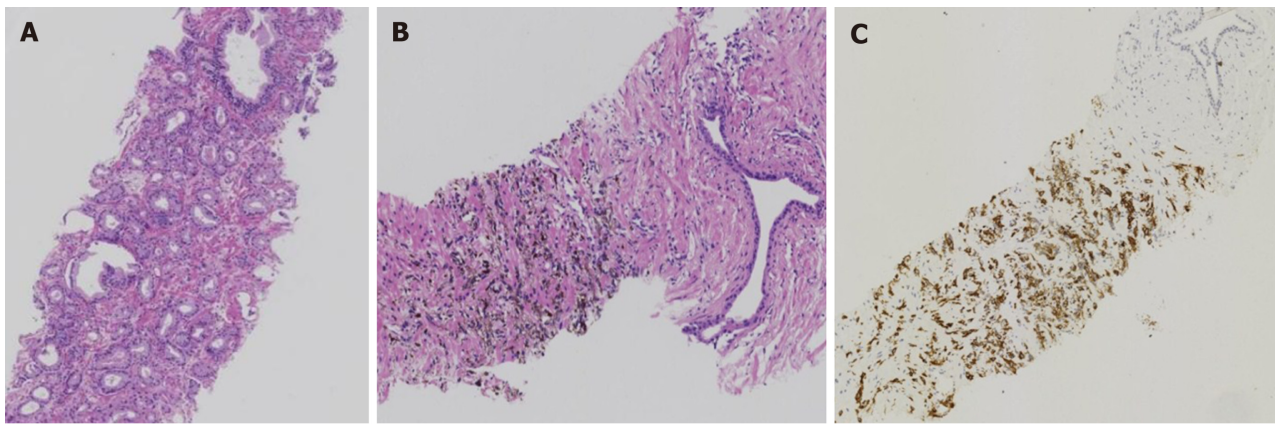
Following bone surgery (T12 tumor resection, spinal canal decompression and vertebroplasty), the patient received dacarbazine + cisplatin chemotherapy and (Rh-endostatin) targeted therapy for four courses.

## OUTCOME AND FOLLOW-UP

The patient died within 11 mo.

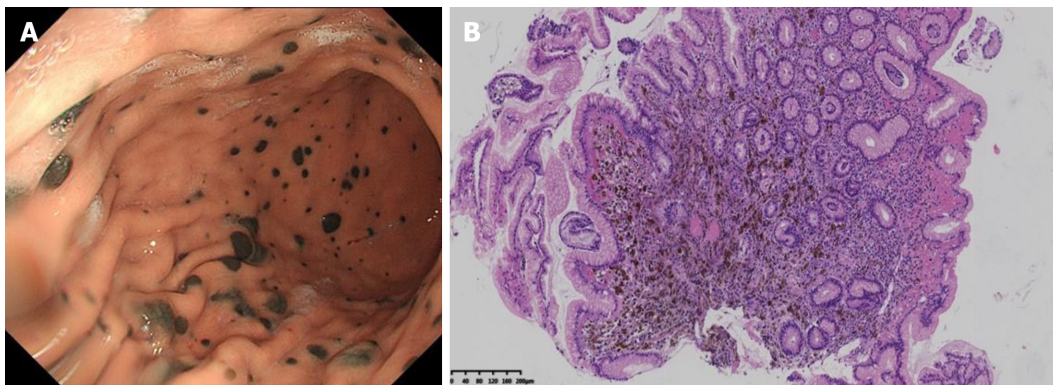
## DISCUSSION

Melanoma is a malignant tumor arising from pigment-containing cells, known as melanocytes, which are mainly located in cutaneous tissue. Prostate malignant melanoma may be primary or secondary[2], and a total of 46 cases have been reported to date including our patient. The median age of the patients was 61 years ranging from 29 to 84 years[1].



DOI: 10.12998/wjcc.v11.i24.5721 Copyright ©The Author(s) 2023.

**Figure 4 Histopathology.** A: Prostate adenocarcinoma [Hematoxylin and eosin (HE), original magnification, 25 ×]; B: Small foci of melanocytes in the proliferative prostate tissue (HE, original magnification, 25 ×); C: Immunohistochemical results: HMB45\* (HE, original magnification, 25 ×).



DOI: 10.12998/wjcc.v11.i24.5721 Copyright ©The Author(s) 2023.

**Figure 5 Gastroscopy findings.** A: Multiple mucosal black spots in the body and fundus of the stomach; B: Microscopic small foci of melanocytes in the gastric mucosa (hematoxylin-eosin, original magnification, 25 ×).

The most common presentation is obstructive lower urinary tract symptoms. Diagnosis needs histological analysis during transurethral resection of the prostate or core-biopsy material. When a diagnosis of prostate melanoma is made, it is important to distinguish between primary and secondary lesions, so it is important to look for melanoma lesions in other sites.

Our patient had primary gastric malignant melanoma with multiple metastases to the prostate and bone. In this case,  $^{18}\text{F}$ -FDG-PET/CT showed high glucose metabolism on the left side of the prostate. The final pathological findings confirmed that it was prostate carcinoma. Melanoma has the lowest glucose metabolism of all malignant tumors. The lesions in the right prostate, gastric mucosa and ribs were not observed by  $^{18}\text{F}$ -FDG-PET/CT.  $^{18}\text{F}$ -FDG-PET/CT may result in a false-negative diagnosis. Teoh *et al*[18] and colleagues found that glutamine metabolism was more specific than deoxyribose metabolism both in melanoma and prostate cancer. In 2017, the United States Food and Drug Administration approved  $^{18}\text{F}$ -FDG-PET/CT for imaging of recurrent prostate cancer. Fluciclovine also has the potential ability to selectively image T-cell modulation in the tumor microenvironment. Thus,  $^{18}\text{F}$ -FDG-PET/CT may perform better than  $^{18}\text{F}$ -FDG-PET/CT in the detection of prostate melanoma.

MRI manifestations of bone metastases from prostate carcinoma are generally T1 signal hypointensity and T2 hyperintensity. MR images in our patient were characterized by T1 enhancement and T2 attenuation, which can be used to differentiate between melanoma and prostate carcinoma of bone metastasis.

Following MRI, PET/CT and prostate biopsy, our patient underwent gastroenteroscopy, which revealed the primary lesion in the stomach. In the 10 cases of primary prostate melanoma reviewed in the present study (Table 1), it was found that there was a lack of thorough examination in most cases. Only three cases underwent endoscopy of the gastrointestinal tract and two received  $^{18}\text{F}$ -FDG-PET/CT. The prognosis in these patients also varied, ranging from 1 to 84 mo[1-14]. We suggest that some patients diagnosed with primary prostate melanoma may have metastatic lesions at the time of diagnosis.

In the only systematic review presented to date on all cases of prostate melanoma, Caputo *et al*[14] summarized 45 cases both in English and non-English literature. The median age of patients was 61 years and only 10 primary prostatic cases have been reported so far. Caputo's team found that patients with prostatic metastases from melanoma had a dismal prognosis with a median survival of 3 mo (range 7 d to 6 mo). The prognosis of primary prostatic melanoma was

**Table 1** Clinicopathological characteristics of the 10 primary prostatic melanomas included in the present review

Ref.	Age	History disease	Symptoms	Other test	Treatment	Stage	Time to recurrence	Metastases	Secondly treatment	OS
Berry and Reese[4], 1953	38	No	Luts	n/m	Cystoprostatectomy	n/m	7 mo	n/m	n/m	36 mo
Hübner <i>et al</i> [5], 1980	n/f	n/f	n/f	n/f	n/f	n/f	n/f	n/f	n/f	n/f
Wang[6], 2001	61	n/m	BPH	(1) Physical examination of the whole body skin surface, oral cavity, and mucosa and optic fundus; (2) CT and MRI of the brain, abdo_x005f men and pelvic cavity; and (3) endoscopy of gastrointestinal tract	TURP	T1N0M0	n/m	n/m	No	84 mo
Wong and Bell[8], 2006	71	n/f	Urinary retention	n/f	TURP	n/f	n/f	n/f	n/f	5 mo
Wong <i>et al</i> [7], 2008	n/f	n/f	n/f	n/f	n/f	n/f	n/f	n/f	n/f	n/f
Doublali <i>et al</i> [9], 2010	75	n/m	Urinary tract obstruction. Urethrosocopy had revealed black discoloration of the prostate	(1) Physical examination of body skin surface, mucosa; (2) CT of brain, abdomen and pelvis; and (3) colonoscopy and gastroscopy	TURP	n/m	n/m	n/m	No	1 mo
Ma <i>et al</i> [10], 2010	29	n/m	Disuria Digital rectal examination and Transrectal Ultrasound of a mass	Pelvic CT scan with contrast	Radical prostatectomy	T2N0M0	n/m	n/m	n/m	3 mo
Tosev <i>et al</i> [11], 2015	37	Hodgkin's disease	Hematuria and urinary retention. In-house cystoscopy showed an asymmetric prostate enlargement with purple discoloration Prostate biopsy	(1) Skin of the body; (2) colonoscopy and gastroscopy; (3) CT of chest and abdomen; and (4) pelvic MRI	Open retropubic radical prostatectomy with extended lymph-node dissection	n/m	4 mo	Lung	Dacarbazine, ipilimumab, nivolumab	16 mo
Li <i>et al</i> [12], 2019	42	No	Hematuria Accepy PVP. Intraoperatively, a dark lesion was noted in the patient's prostatic urethra	(1) CT of the chest, abdomen, and pelvis; (2) brain MRI; (3) bone scan; and (4) <sup>18</sup> F-FDG PET/CT scan	RRP and PLND	T2N1M0	3 mo	Lesion along the right iliac artery, pulmonary nodule	Biochemotherapy for 6 cycles dacarbazine, vinblastine, cisplatin, IL2	84 mo
Parmar <i>et al</i> [13], 2019	65	No	Acute urinary retention	(1) Physical examination of whole body skin surface, oral cavity and anal mucosa; and (2) PET-CT	TURP, Dacarbazine, Chemotherapy	n/m	3 mo	n/m	n/m	n/m

n/f: Full text not found; n/m: Not mentioned; no: None; LUTS: Lower urinary tract symptoms; TURP: Transurethral resection of the prostate; PVP: Photoselective vaporization of the prostate; RRP: Radical retropubic prostatectomy; PLND: Pelvic lymph node dissection; MRI: Magnetic resonance imaging; <sup>18</sup>F-FDG PET/CT: <sup>18</sup>F-fluorodeoxyglucose positron emission tomography computed tomography; IL: Interleukin.

not as bad as expected. Of the seven available cases with at least 1 year of follow-up, two survived for > 5 years, while the remaining five died after an average of 1 year.

It is important to distinguish between primary and secondary melanoma. Radical surgery followed by adjuvant chemo-/immunotherapy represents the most reasonable therapeutic strategy. For patients with primary disease, a more aggressive approach may provide better benefits.

## CONCLUSION

Malignant melanoma of the prostate is rare. There have been 46 cases reported including our patient. There is a significant difference in the prognosis between primary and secondary cases<sup>[14]</sup> (3 mo *vs* 12 mo). The diagnosis of primary prostate melanoma has important implications for treatment. For accurate diagnosis, physical examination of the body skin surface, CT of the whole body, and endoscopy including the urinary tract and gastrointestinal tract should be conducted. <sup>18</sup>F-FDG-PET may result in false-negative findings in the detection of melanoma both in the prostate and gastric mucosa.

## FOOTNOTES

**Author contributions:** Zhao H contributed to study protocol and manuscript writing; Liu C contributed to the manuscript writing; Li B contributed to data collection; Guo JM contributed to project development; Zhao H and Liu C contributed equally to this work; All authors have read and approved the final version to be submitted.

**Informed consent statement:** The patient has provided informed consent.

**Conflict-of-interest statement:** The authors declare that there are no financial and personal relationships with other people or organizations that could inappropriately influence our work. There is no professional or other personal interest of any nature in any product, service and/or company that could be construed as influencing the position presented in, or the review of this manuscript.

**CARE Checklist (2016) statement:** The authors have read the CARE Checklist (2016), and the manuscript was prepared and revised according to the CARE Checklist (2016).

**Open-Access:** This article is an open-access article that was selected by an in-house editor and fully peer-reviewed by external reviewers. It is distributed in accordance with the Creative Commons Attribution NonCommercial (CC BY-NC 4.0) license, which permits others to distribute, remix, adapt, build upon this work non-commercially, and license their derivative works on different terms, provided the original work is properly cited and the use is non-commercial. See: <https://creativecommons.org/licenses/by-nc/4.0/>

**Country/Territory of origin:** China

**ORCID number:** Hong Zhao 0000-0001-7741-930X; Jian-Ming Guo 0000-0002-3654-5518.

**S-Editor:** Fan JR

**L-Editor:** Kerr C

**P-Editor:** Zhang YL

## REFERENCES

- 1 Humphrey PA, Moch H, Cubilla AL, Ulbright TM, Reuter VE. The 2016 WHO Classification of Tumours of the Urinary System and Male Genital Organs-Part B: Prostate and Bladder Tumours. *Eur Urol* 2016; **70**: 106-119 [PMID: 26996659 DOI: 10.1016/j.eururo.2016.02.028]
- 2 Sánchez-Ortiz R, Huang SF, Tamboli P, Prieto VG, Hester G, Pettaway CA. Melanoma of the penis, scrotum and male urethra: a 40-year single institution experience. *J Urol* 2005; **173**: 1958-1965 [PMID: 15879790 DOI: 10.1097/01.ju.0000159207.91737.53]
- 3 Paner GP, Aron M, Hansel DE, Amin MB. Non-epithelial neoplasms of the prostate. *Histopathology* 2012; **60**: 166-186 [PMID: 22212085 DOI: 10.1111/j.1365-2559.2011.04020.x]
- 4 Berry NE, Reese L. Malignant melanoma which had its first clinical manifestations in the prostate gland. *J Urol* 1953; **69**: 286-290 [PMID: 13023825 DOI: 10.1016/S0022-5347(17)68061-3]
- 5 Hübler J, Pajor L, Kincses I. [Primary malignant melanoma of the prostate]. *Acta Chir Acad Sci Hung* 1980; **21**: 239-243 [PMID: 7324720]
- 6 Wang CJ. Followup of primary malignant melanoma of the prostate. *J Urol* 2001; **166**: 214 [PMID: 11435865]
- 7 Wong J, Wise GJ, Clark B. Malignant melanoma of the prostate: a case report. *Can J Urol* 2008; **15**: 4027-4029 [PMID: 18405456]
- 8 Wong JA, Bell DG. Primary malignant melanoma of the prostate: case report and review of the literature. *Can J Urol* 2006; **13**: 3053-3056 [PMID: 16672119]
- 9 Doublali M, Chouaib A, Khallouk A, Tazi MF, El Fassi MJ, Farih MH, Elfatmi H, Bendahou M, Benlemlih A, Lamarti O. Primary malignant melanoma of prostate. *Urol Ann* 2010; **2**: 76-77 [PMID: 20882159 DOI: 10.4103/0974-7796.65105]
- 10 Ma L, Liu W, Sun F. Primary malignant melanoma of the prostate. *Int J Urol* 2010; **17**: 94-95 [PMID: 20377830 DOI: 10.1111/j.1442-2042.2009.02418.x]
- 11 Tosev G, Kuru TH, Huber J, Freier G, Bergmann F, Hassel JC, Pahernik SA, Hohenfellner M, Hadaschik BA. Primary melanoma of the prostate: case report and review of the literature. *BMC Urol* 2015; **15**: 68 [PMID: 26169921 DOI: 10.1186/s12894-015-0052-3]

- 12 **Li R**, Zhang M, Duplisea JJ, Troncso P, Ward JF. Detection and Treatment of Primary Prostatic Melanoma. *Urology* 2019; **123**: 16-19 [PMID: 30195014 DOI: 10.1016/j.urology.2018.08.035]
- 13 **Parmar K**, Khanna A, Singh SK, Sharma M. A rare cause of acute urinary retention- Primary malignant melanoma of prostate. *Asian J Urol* 2019; **6**: 380-382 [PMID: 31768327 DOI: 10.1016/j.ajur.2019.01.003]
- 14 **Caputo A**, Addesso M, Zeppa P, D'Antonio A. Malignant melanoma of the prostate gland: A systematic review. *Pathol Res Pract* 2021; **226**: 153594 [PMID: 34481214 DOI: 10.1016/j.prp.2021.153594]
- 15 **Sella A**, Ro JY. Renal cell cancer: best recipient of tumor-to-tumor metastasis. *Urology* 1987; **30**: 35-38 [PMID: 3603907 DOI: 10.1016/0090-4295(87)90568-1]
- 16 **Grignon DJ**, Ro JY, Ayala AG. Malignant melanoma with metastasis to adenocarcinoma of the prostate. *Cancer* 1989; **63**: 196-198 [PMID: 2910417 DOI: 10.1002/1097-0142(19890101)63:1<196::aid-cnrcr2820630131>3.0.co;2-o]
- 17 **Snow H**, Hazell S, Francis N, Mohammed K, O'Neill S, Davies E, Mansfield D, Messiou C, Hujairi N, Nicol D, Harrington K, Smith M. Prostate-specific membrane antigen expression in melanoma metastases. *J Cutan Pathol* 2020; **47**: 1115-1122 [PMID: 32529651 DOI: 10.1111/cup.13774]
- 18 **Teoh EJ**, Tsakok MT, Bradley KM, Hyde K, Subesinghe M, Gleeson FV. Recurrent Malignant Melanoma Detected on 18F-Fluciclovine PET/CT Imaging for Prostate Cancer. *Clin Nucl Med* 2017; **42**: 803-804 [PMID: 28806256 DOI: 10.1097/RLU.0000000000001789]



Published by **Baishideng Publishing Group Inc**  
7041 Koll Center Parkway, Suite 160, Pleasanton, CA 94566, USA

**Telephone:** +1-925-3991568

**E-mail:** [bpgoffice@wjgnet.com](mailto:bpgoffice@wjgnet.com)

**Help Desk:** <https://www.f6publishing.com/helpdesk>

<https://www.wjgnet.com>

