

World Journal of *Gastroenterology*

World J Gastroenterol 2023 May 7; 29(17): 2515-2703



REVIEW

- 2515 Novel biomarkers for early detection of gastric cancer
Matsuoka T, Yashiro M
- 2534 Non-invasive evaluation of liver steatosis with imaging modalities: New techniques and applications
Zeng KY, Bao WYG, Wang YH, Liao M, Yang J, Huang JY, Lu Q
- 2551 Alcohol-related hepatitis: A review article
Chaudhry H, Sohal A, Iqbal H, Roytman M
- 2571 Current and novel approaches in the pharmacological treatment of hepatocellular carcinoma
Villarruel-Melquiades F, Mendoza-Garrido ME, García-Cuellar CM, Sánchez-Pérez Y, Pérez-Carreón JI, Camacho J

MINIREVIEWS

- 2600 Difficult colorectal polypectomy: Technical tips and recent advances
Pattarajierapan S, Takamaru H, Khomvilai S

ORIGINAL ARTICLE

Basic Study

- 2616 Cryptotanshinone induces apoptosis of activated hepatic stellate cells *via* modulating endoplasmic reticulum stress
Hou XX, Li YW, Song JL, Zhang W, Liu R, Yuan H, Feng TT, Jiang ZY, Li WT, Zhu CL
- 2628 *Lafoensia pacari* alleviates intestinal damage by modulating cyclooxygenase-2: *In silico* and *in vivo* evaluation in a colitis model
Peiter GC, Moesch Queiroz TK, Michalkiewicz Jr EL, Chappuis RH, Luz JS, Casagrande Piovezani LH, Ferreira Silva C, Nozomi Tsutumi M, Fernandes Chaves A, Luiz RM, Façanha Wendel C, Zarpelon-Schutz AC, Teixeira KN
- 2642 Establishment and characterization of a new human ampullary carcinoma cell line, DPC-X1
Xu H, Chai CP, Miao X, Tang H, Hu JJ, Zhang H, Zhou WC

Retrospective Study

- 2657 Mucosal patterns change after *Helicobacter pylori* eradication: Evaluation using blue laser imaging in patients with atrophic gastritis
Nishikawa Y, Ikeda Y, Murakami H, Hori SI, Yoshimatsu M, Nishikawa N

Randomized Controlled Trial

- 2666 Fecal microbiota transplantation for the maintenance of remission in patients with ulcerative colitis: A randomized controlled trial
Lahtinen P, Jalanka J, Mattila E, Tillonen J, Bergman P, Satokari R, Arkkila P

SYSTEMATIC REVIEWS

- 2679** Different types of fruit intake and colorectal cancer risk: A meta-analysis of observational studies
Wu ZY, Chen JL, Li H, Su K, Han YW

LETTER TO THE EDITOR

- 2701** T cells in pancreatic cancer stroma: Tryptophan metabolism plays an important role in immunoregulation
Yang T, Li QQ, Liu YM, Yang B

ABOUT COVER

Editorial Board Member of *World Journal of Gastroenterology*, Mohamad Amin Pourhoseingholi, PhD, Associate Professor, Gastroenterology and Liver Diseases Research Center, Research Institute for Gastroenterology and Liver Diseases, Shahid Beheshti University of Medical Sciences, Tehran 19835, Iran. aminphg@gmail.com

AIMS AND SCOPE

The primary aim of *World Journal of Gastroenterology* (WJG, *World J Gastroenterol*) is to provide scholars and readers from various fields of gastroenterology and hepatology with a platform to publish high-quality basic and clinical research articles and communicate their research findings online. WJG mainly publishes articles reporting research results and findings obtained in the field of gastroenterology and hepatology and covering a wide range of topics including gastroenterology, hepatology, gastrointestinal endoscopy, gastrointestinal surgery, gastrointestinal oncology, and pediatric gastroenterology.

INDEXING/ABSTRACTING

The WJG is now abstracted and indexed in Science Citation Index Expanded (SCIE, also known as SciSearch®), Current Contents/Clinical Medicine, Journal Citation Reports, Index Medicus, MEDLINE, PubMed, PubMed Central, Scopus, Reference Citation Analysis, China National Knowledge Infrastructure, China Science and Technology Journal Database, and Superstar Journals Database. The 2022 edition of Journal Citation Reports® cites the 2021 impact factor (IF) for WJG as 5.374; IF without journal self cites: 5.187; 5-year IF: 5.715; Journal Citation Indicator: 0.84; Ranking: 31 among 93 journals in gastroenterology and hepatology; and Quartile category: Q2. The WJG's CiteScore for 2021 is 8.1 and Scopus CiteScore rank 2021: Gastroenterology is 18/149.

RESPONSIBLE EDITORS FOR THIS ISSUE

Production Editor: *Ying-Yi Yuan*; Production Department Director: *Xu Guo*; Editorial Office Director: *Jia-Ru Fan*.

NAME OF JOURNAL

World Journal of Gastroenterology

ISSN

ISSN 1007-9327 (print) ISSN 2219-2840 (online)

LAUNCH DATE

October 1, 1995

FREQUENCY

Weekly

EDITORS-IN-CHIEF

Andrzej S Tarnawski

EDITORIAL BOARD MEMBERS

<http://www.wjgnet.com/1007-9327/editorialboard.htm>

PUBLICATION DATE

May 7, 2023

COPYRIGHT

© 2023 Baishideng Publishing Group Inc

INSTRUCTIONS TO AUTHORS

<https://www.wjgnet.com/bpg/gerinfo/204>

GUIDELINES FOR ETHICS DOCUMENTS

<https://www.wjgnet.com/bpg/GerInfo/287>

GUIDELINES FOR NON-NATIVE SPEAKERS OF ENGLISH

<https://www.wjgnet.com/bpg/gerinfo/240>

PUBLICATION ETHICS

<https://www.wjgnet.com/bpg/GerInfo/288>

PUBLICATION MISCONDUCT

<https://www.wjgnet.com/bpg/gerinfo/208>

ARTICLE PROCESSING CHARGE

<https://www.wjgnet.com/bpg/gerinfo/242>

STEPS FOR SUBMITTING MANUSCRIPTS

<https://www.wjgnet.com/bpg/GerInfo/239>

ONLINE SUBMISSION

<https://www.f6publishing.com>



Difficult colorectal polypectomy: Technical tips and recent advances

Sukit Pattarajierapan, Hiroyuki Takamaru, Supakij Khomvilai

Specialty type: Gastroenterology and hepatology

Provenance and peer review: Invited article; Externally peer reviewed.

Peer-review model: Single blind

Peer-review report's scientific quality classification

Grade A (Excellent): 0
Grade B (Very good): B, B, B
Grade C (Good): C
Grade D (Fair): D
Grade E (Poor): 0

P-Reviewer: Argyriou K, Greece; Gao SG, China; Ichita C, Japan; Rasa K, Turkey

Received: January 29, 2023

Peer-review started: January 29, 2023

First decision: February 14, 2023

Revised: February 24, 2023

Accepted: April 12, 2023

Article in press: April 12, 2023

Published online: May 7, 2023



Sukit Pattarajierapan, Supakij Khomvilai, Surgical Endoscopy Colorectal Division, Department of Surgery, Faculty of Medicine, Chulalongkorn University, Bangkok 10330, Thailand

Hiroyuki Takamaru, Endoscopy Division, National Cancer Center Hospital, Tokyo 104-0045, Japan

Corresponding author: Sukit Pattarajierapan, MD, Doctor, Surgeon, Surgical Endoscopy Colorectal Division, Department of Surgery, Faculty of Medicine, Chulalongkorn University, 1873 Rama IV Road, Pathumwan, Bangkok 10330, Thailand. sukit.p@chulahospital.org

Abstract

Colonoscopy has been shown to be an effective modality to prevent colorectal cancer (CRC) development. CRC reduction is achieved by detecting and removing adenomas, which are precursors of CRC. Most colorectal polyps are small and do not pose a significant challenge for trained and skilled endoscopists. However, up to 15% of polyps are considered “difficult”, potentially causing life-threatening complications. A difficult polyp is defined as any polyp that is challenging for the endoscopist to remove owing to its size, shape, or location. Advanced polypectomy techniques and skills are required to resect difficult colorectal polyps. There were various polypectomy techniques for difficult polyps such as endoscopic mucosal resection (EMR), underwater EMR, Tip-in EMR, endoscopic submucosal dissection (ESD), or endoscopic full-thickness resection. The selection of the appropriate modality depends on the morphology and endoscopic diagnosis. Several technologies have been developed to aid endoscopists in performing safe and effective polypectomies, especially complex procedures such as ESD. These advances include video endoscopy system, equipment assisting in advanced polypectomy, and closure devices/techniques for complication management. Endoscopists should know how to use these devices and their availability in practice to enhance polypectomy performance. This review describes several useful strategies and tips for managing difficult colorectal polyps. We also propose the stepwise approach for difficult colorectal polyps.

Key Words: Adenoma; Colonic polyps; Colonoscopy; Endoscopic mucosal resection; Endoscopic submucosal dissection; Polypectomy

©The Author(s) 2023. Published by Baishideng Publishing Group Inc. All rights reserved.

Core Tip: Most colorectal polyps are small and do not pose a significant challenge to resection. However, up to 15% of polyps are considered “difficult” because of their size, shape, or location. Advanced polypectomy techniques and skills are required for the resection of difficult colorectal polyps. Recent advancements in techniques and devices for endoscopic mucosal resection, endoscopic submucosal dissection, and endoscopic full-thickness resection allow curative therapy of these difficult polyps and avoid unnecessary surgery that carries the risk of morbidity and mortality. However, the proper selection of adjunct endoscopic devices/techniques and stepwise training for skill improvement are critical for successful advanced polypectomy.

Citation: Pattarajierapan S, Takamaru H, Khomvilai S. Difficult colorectal polypectomy: Technical tips and recent advances. *World J Gastroenterol* 2023; 29(17): 2600-2615

URL: <https://www.wjgnet.com/1007-9327/full/v29/i17/2600.htm>

DOI: <https://dx.doi.org/10.3748/wjg.v29.i17.2600>

INTRODUCTION

In 2020, colorectal cancer (CRC) was the fourth most common malignancy worldwide, with 1.9 million new cases recorded[1]. Colonoscopy has been shown to be an effective modality to prevent CRC development. Previous studies have shown a 60%-90% reduction in CRC incidence after screening colonoscopy[2,3]. CRC reduction is achieved by detecting and removing adenomas, which are precursors of CRC. Most colorectal polyps detected during colonoscopy are small, benign, and easily resected by skilled endoscopists. However, 10%-15% of colorectal polyps are classified as “difficult” colorectal polyps[4,5]. Generally, difficult colorectal polyps are defined as any polyps that are technically challenging for endoscopic resection because of their size (> 20 mm), morphology (pedunculated polyp with a thick stalk, laterally spreading tumor), or location (ileocecal valve, appendiceal orifice, dentate line)[5,6].

Endoscopic resection of difficult polyps is associated with an increased risk of incomplete resection and serious adverse events, including intra-procedural massive bleeding and perforation. Therefore, difficult polypectomy should be performed or supervised by an experienced endoscopist. This review describes helpful strategies and tips for dealing with difficult colorectal polyps.

THE STEPWISE APPROACH FOR DIFFICULT COLORECTAL POLYPS

Lesion assessment

The first step in managing colorectal polyps is lesion assessment. Dye-based chromoendoscopy and image-enhanced endoscopy (IEE) with magnifying observation should be used to distinguish benign lesions, adenomas, and adenocarcinomas. Dye-based chromoendoscopy with indigo carmine and crystal violet enables pit pattern diagnosis based on Kudo’s classification[7]. However, IEE techniques such as narrow-band imaging (NBI) and blue laser imaging are more common than chromoendoscopy in clinical practice outside Japan. IEE can diagnose lesions by visualizing surface patterns and microvessels based on the NBI International Colorectal Endoscopic (NICE) and Japan NBI Expert Team (JNET) classification[8,9] (Table 1). The accuracy of discriminating non-neoplastic from neoplastic lesions was 95% for magnifying observation with IEE and 96%-98% for pit pattern observation with chromoendoscopy, while the accuracy for discriminating adenomas from adenocarcinomas was 70%-90% for both IEE and chromoendoscopy[10].

Colorectal cancers with submucosal invasion have a 7%-14% risk of lymph node metastasis[11-14]. For submucosal cancers, it is crucial to differentiate between superficial (< 1000 μ m) and deep submucosal invasive (\geq 1000 μ m) cancer. Current evidence strongly supports the theory that superficial cancer with submucosal invasion < 1000 μ m without lymphovascular invasion, grade 2/3 tumor budding, or poorly differentiated component have no risk of lymph node metastasis[15,16]. A Japanese study suggested that magnifying chromoendoscopy with crystal violet is the best modality for estimating the invasion depth in early colorectal lesions. Matsuda *et al*[17] found that the diagnostic accuracy of the invasive pattern in magnifying chromoendoscopy with crystal violet to differentiate superficial (< 1000 μ m) and deep submucosal invasive (\geq 1000 μ m) cancers was 98.8%. Patients with submucosal invasive cancer should undergo radical colectomy considering the risk of nodal metastasis, whereas patients with adenoma or cancer with submucosal superficial invasion are candidates for endoscopic resection. It should be noted that experienced examiners performed magnifying chromoendoscopy in this study; therefore, the effectiveness of magnifying chromoendoscopy should be revalidated in general endoscopists. Togashi *et al*[18] reported a minimum experience of observing 200

Table 1 The Japan Narrow-band Imaging Expert Team classification[8]

	Type 1	Type 2A	Type 2B	Type 3
Vessel pattern	Invisible	Regular caliber, regular distribution (meshed/spiral pattern)	Variable caliber, irregular distribution	Loose vessel areas, interruption of thick vessels
Surface pattern	Regular dark or white spots, similar to surrounding normal mucosa	Regular (tubular/branched/papillary)	Irregular or obscure	Amorphous areas
Suspected pathology	Hyperplastic polyp/sessile serrated polyp	Low grade intramucosal neoplasia	High grade intramucosal neoplasia/shallow submucosal invasive cancer	Deep submucosal invasive cancer

lesions with magnifying chromoendoscopy is needed to understand pit pattern diagnosis. Moreover, the limited availability of crystal violet outside Japan makes this approach difficult to apply in clinical practice.

Identification of the causes of difficult polypectomy

Table 2 shows the causes of difficult polypectomy. The difficulty might arise from the size, location, morphology, or other specific conditions. Possible solutions for each complex polyp character or situation are described in the following subsections.

The Size, Morphology, Site, Access (SMSA) classification system has been proposed by Gupta *et al*[19] for stratifying lesion complexity (Table 3). This stratifies polyps into 4 levels of difficulty, with level 1 being the easiest to resect by all endoscopists and level 4 being very difficult to resect. Longcroft-Wheaton *et al*[20] validated the SMSA system in a prospective study of 220 lesions ≥ 20 mm in diameter. They found that lesions with SMSA level 4 had higher complication rates (8.6% *vs* 0%, $P = 0.007$) and lower complete resection rates (87.5% *vs* 97.5%, $P = 0.009$) than the lesions with SMSA level 2 and 3. European Society of Gastrointestinal Endoscopy guideline for colorectal polypectomy and endoscopic mucosal resection (EMR) recommends using the SMSA system to assess large and complex polyps. If the lesions have SMSA level 4, they should be resected by experts at a high-volume tertiary care center [21].

Basic techniques of colorectal polypectomy

Endoscopists should have the appropriate basic skills to conduct a colorectal polypectomy. First, looping on the colonoscope should be unwound by shortening before performing polypectomy; otherwise, colonoscope manipulation would be paradoxical and troublesome. Second, endoscopists should position the polyp at 5-6 o'clock on the monitor because the instrument exits the colonoscope channel at 5 o'clock (Figure 1A). Finally, the base of the polyp, particularly that of a pedunculated polyp, should lie opposite to gravity. Polyp stretching by gravity improves the visualization of the polyp base, and this maneuver prevents blood pooling at the resected site (Figure 1B and C).

Selection of therapeutic modality for large colorectal polyps

The selection of the appropriate modality from various polypectomy techniques depends on the morphology and endoscopic diagnosis. Large pedunculated polyps are mainly resected by polypectomy with a prophylactic strategy against bleeding. The selection of a therapeutic modality for large non-pedunculated polyps, mostly laterally spreading tumors (LSTs), is highly debated. LST is defined as a lesion ≥ 10 mm in diameter, extending laterally with a low vertical axis[22]. The comparison between EMR and endoscopic submucosal dissection (ESD) is an important issue for large LSTs. ESD has higher *en bloc* resection and lower recurrence rates than EMR because the snare EMR method tends to result in piecemeal resection for large lesions[23,24]. Moreover, ESD allows accurate histopathologic diagnosis regarding the depth of invasion without segmentation of the carcinomatous part, which compromises the pathological diagnosis[25]. Nevertheless, colorectal ESD is one of the most challenging endoscopic procedures with high complications. The learning curve of colorectal ESD is steep, with approximately 80 procedures required to gain proficiency in large polyp resection[26]. Recently, Tip-in EMR was proposed as a promising modified EMR technique for the resection of large nonpedunculated polyps [27,28]. After the submucosal injection, the snare tip with a cut current was used to make a spot-shaped mucosal incision at the proximal side of the tumor. The small incision helps fix the snare tip in the submucosal layer during the snare placement; therefore, endoscopists could place the snare flexibly and repeatedly in the appropriate position. Takada *et al*[29] compared Tip-in EMR with ESD for the resection of 20- to 30-mm nonpedunculated polyp using propensity score matching. They found that Tip-in EMR had a lower *en bloc* resection (85% *vs* 99%, $P < 0.001$) and R0 resection rates (63% *vs* 91%, $P < 0.001$) than ESD; however, Tip-in had a shorter procedural time (8 min *vs* 60 min, $P < 0.001$) and comparable local recurrence rate (2% *vs* 0%, $P = 0.386$). They concluded that Tip-in EMR could be a feasible alternative to ESD for 20- to 30-mm nonpedunculated polyps.

Table 2 Characteristics of the difficult colorectal polyps

Size	> 20 mm
Location	Near or involving the appendiceal orifice
	Ileocecal valve
	Anorectal junction
	Behind the fold
	Angulated segment
Morphology	Pedunculated polyp with thick stalk and large head
	Laterally spreading tumor
	Submucosal fibrosis or positive non-lifting sign
Special situation	Recurrent lesion
	Strong colonic peristalsis

Table 3 Size/Morphology/Site/Access scoring system[19]

Parameter	Range	Score
Size	< 1 cm	1
	1.0-1.9 cm	3
	2.0-2.9 cm	5
	3.0-3.9 cm	7
	> 4 cm	9
Morphology	Pedunculated	1
	Sessile	2
	Flat	3
Site	Left	1
	Right	2
Access	Easy	1
	Difficult	3

Size/Morphology/Site/ Access (SMSA) level 1: 4-5 points, level 2: 6-8 points, level 3: 9-12 points, level 4: > 12 points.

LST is classified as granular type (LST-G), which has a nodular surface, or non-granular type (LST-NG), which has a smooth surface. These two types have different patterns of submucosal invasion. In a large retrospective cohort study by Yamada *et al*[30], 19% of the LST-G cases had submucosal invasion; the invasion site was the large nodule in 56%, the depression area in 28%, and multifocal in 16%. LST-NG showed 39% submucosal invasion, and the invasion site was 10% at submucosal mass-like elevation, 45% at depression, or 45% multifocal. Because of the substantial risk of multifocal submucosal invasion, ESD is warranted for LST-NG, and *en bloc* resection is required for large LST-G nodules. Table 4 shows the indications for colorectal ESD suggested by the 2020 Japan Gastroenterological Endoscopy Society (JGES) guidelines for colorectal ESD and EMR[10].

APPROACHES TO DIFFICULT POLYPECTOMY IN SPECIFIC SITUATIONS

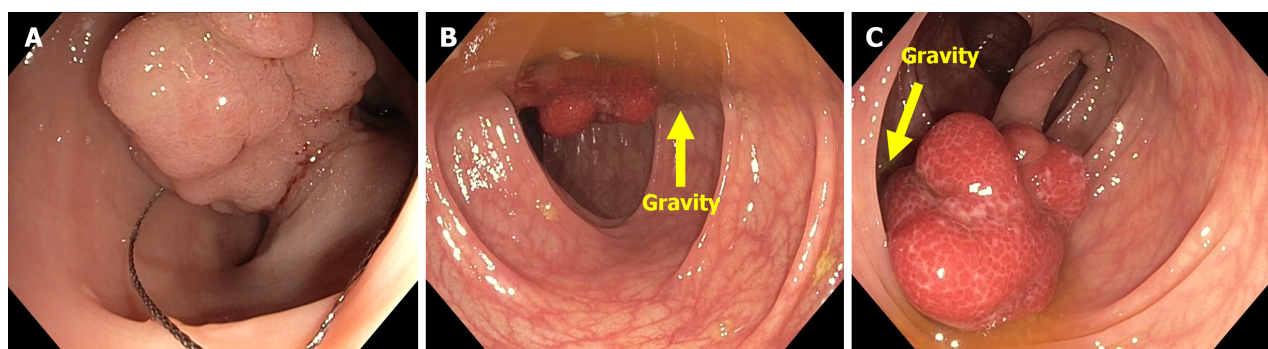
Pedunculated polyp with thick stalk and large head

The risk of bleeding after polypectomy of large pedunculated polyps with thick stalk increases due to the possibility of large blood vessels in the stalk. A prospective study found that pedunculated polyps with stalk diameter > 5 mm and polyp size > 17 mm are risk factors for post-polypectomy bleeding[31]. Therefore, prophylactic strategies against bleeding should be implemented prior to polypectomy.

Table 4 Indications for colorectal endoscopic submucosal dissection[10]

Lesions requiring <i>en bloc</i> resection	
1	Lesions which <i>en bloc</i> resection with EMR is difficult LST-NG, particularly LST-NG with pseudo-depressed type Lesions with V _I -type pit pattern Carcinoma with shallow T1 invasion Large depressed-type tumor Large protruded-type lesions suspected to be carcinoma
2	Mucosal tumors with submucosal fibrosis
3	Sporadic tumors in conditions of chronic inflammation such as ulcerative colitis
4	Local residual or recurrent early carcinomas after endoscopic resection

EMR: Endoscopic mucosal resection; LST-NG: Laterally spreading tumor non-granular type.



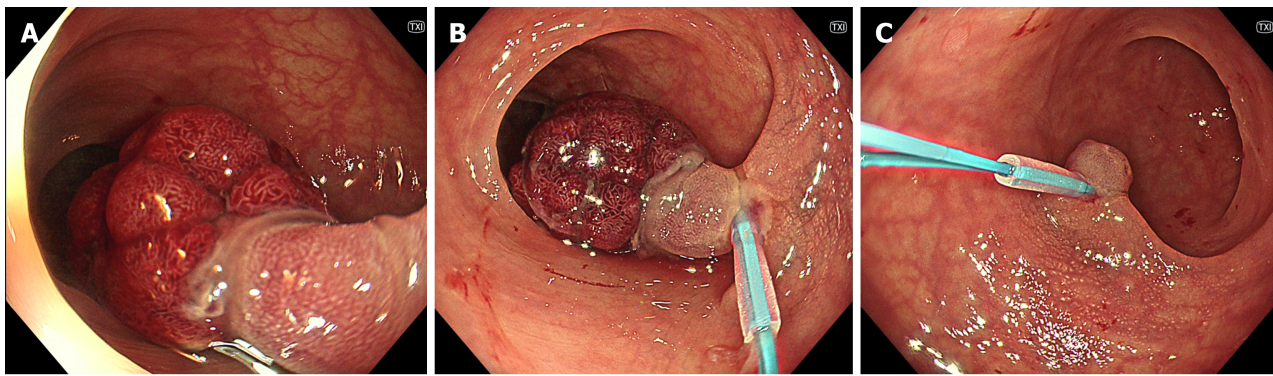
DOI: 10.3748/wjg.v29.i17.2600 Copyright ©The Author(s) 2023.

Figure 1 Basic maneuvers of polypectomy. A: Positioning the polyp at 5-6 o'clock on the monitor before polypectomy; B: The polyp's base lying on gravity, this leads to poor visualization of the resection area; therefore, the patient's position should be altered; C: The polyp's base lying opposite to gravity after changing the patient's position. This position change allows polyp stretching and avoids blood pooling on the resected site.

A randomized controlled trial (RCT) by Dobrowolski *et al*[32] found that colorectal polyps ≥ 1 cm that underwent prophylactic adrenaline injection at the stalk before polypectomy had a lower immediate bleeding rate than conventional polypectomy (2% *vs* 16%, $P < 0.05$). In contrast, another RCT by Lee *et al* [33] revealed no statistical difference in immediate and delayed post-polypectomy bleeding rates between the prophylactic adrenaline injection and control groups.

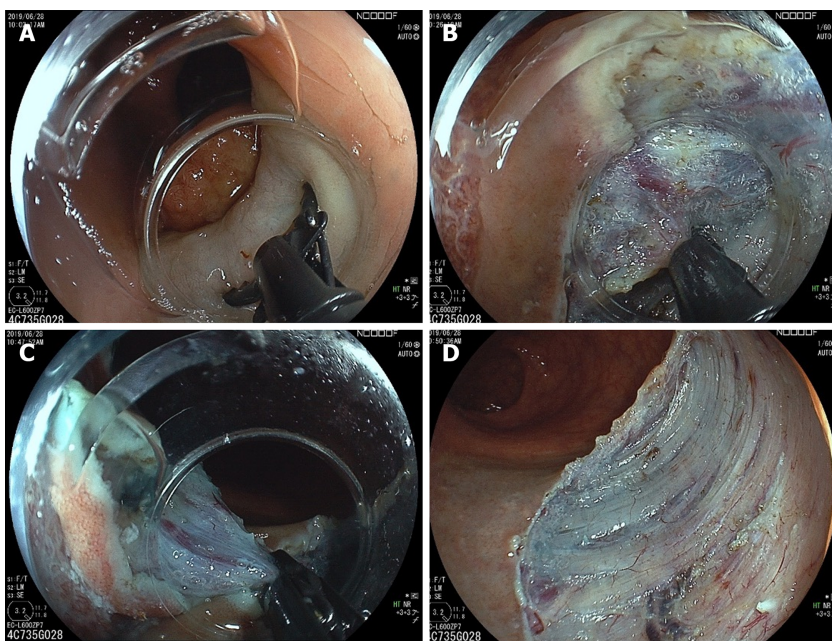
A detachable snare (endoloop) was developed by Hachisu to prevent post-polypectomy bleeding from large pedunculated polyps[34]. A nylon-thread loop is tightened around the polyp stalk to ensure hemostasis before polypectomy (Figure 2). Three RCTs confirmed that a detachable snare effectively prevents post-polypectomy bleeding in large colorectal polyps[35-37]. However, endoloop placement might not be possible for all polyps, especially those with a large head or a short stalk. A previous study reported an 8.3% failure rate in endoloop placement[37]. Although the largest available endoloop has an opening diameter of 30 mm, it is floppy and challenging to place at the stalk of large polyps. Moreover, the polyp stalk will be shortened after endoloop tightening; therefore, endoloop-assisted polypectomy might not be suitable for polyps with short stalks due to the possibility of incomplete resection. A case series reported successful ESD for large pedunculated polyps with failed endoloop placement using a scissor-type knife[38], which allows precise dissection with targeted hemostasis. With a scissor-type knife, the tissue and vessels could be grasped between two blades and pre-coagulated before cutting (Figure 3). In addition, a case report described successful ESD with a scissor-type knife for a large pedunculated polyp with a short, thick stalk[39].

Prophylactic clip application at the thick stalk before polypectomy may prevent post-polypectomy bleeding (Figure 4). Soh *et al*[40] conducted an RCT of 137 pedunculated polyps ≥ 1 cm in 116 patients and found that prophylactic clip application before polypectomy significantly decreased immediate bleeding compared with conventional polypectomy [odds ratio (OR): 0.22; 95% confidence interval (95%CI): 0.08-0.57]. The delayed bleeding rate did not differ between the two groups. However, this technique is difficult to apply to polyps with a short thick stalk due to the risk of incomplete resection, and endoscopists should be aware of transmural burns from electrical current conducted by the



DOI: 10.3748/wjg.v29.i17.2600 Copyright ©The Author(s) 2023.

Figure 2 Endoloop-assisted polypectomy. A: A pedunculated polyp with a thick stalk; B: Endoloop tightening around the stalk before snaring, the polyp's color turned deep purple due to the ischemia; C: No bleeding evidence after the resection.



DOI: 10.3748/wjg.v29.i17.2600 Copyright ©The Author(s) 2023.

Figure 3 Endoscopic submucosal dissection with a scissor-type knife for a large subpedunculated polyp. A: After submucosal injection, a scissor-type knife could be used to perform mucosal incision; B: The tissue and vessels could be grasped between two blades and precoagulated before cutting; C: Final cut of the procedure; D: Mucosal defect after completed endoscopic submucosal dissection.

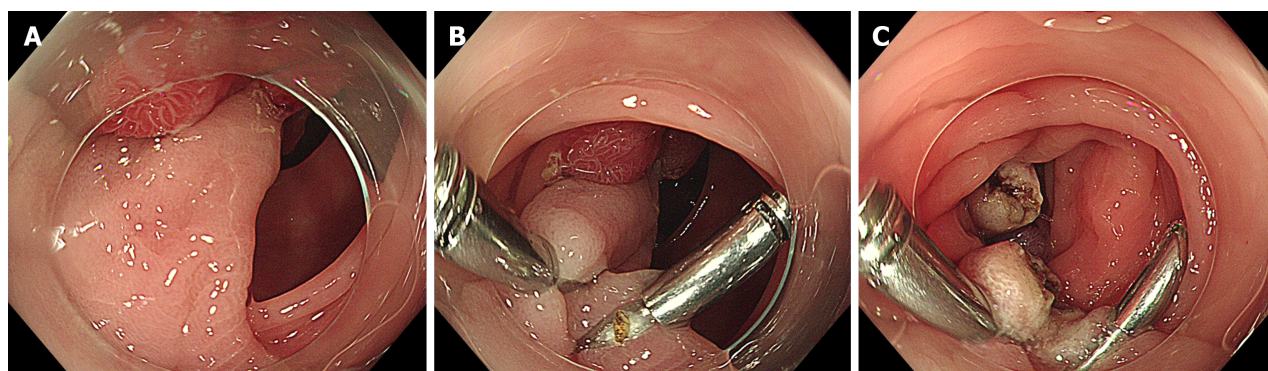
endoscopic clip.

A meta-analysis of 15 RCTs involving 3,462 patients found that both prophylactic adrenaline injection and mechanical therapy reduced the risk of early post-polypectomy bleeding [injection therapy, risk ratio (RR): 0.32; 95%CI: 0.11-0.67; mechanical therapy: RR: 0.13; 95%CI: 0.03-0.37], although no prophylactic therapy decreased the risk of delayed bleeding[41]. In conclusion, prophylactic therapy, including adrenaline injection, detachable snare, or clipping, should be performed before the resection of a pedunculated polyp with a thick stalk or large head. However, detachable snare placement or prophylactic clipping may not be possible for polyps with a short, thick stalk, which may be suitably resected using ESD.

Polyps involving the appendiceal orifice

Endoscopic resection of polyps involving the appendiceal orifice is technically challenging because of the poor-lifting nature of submucosal fibrosis, thin cecal wall, and inability to access the lesion extending deep into the appendiceal orifice. Traditionally, these polyps have been managed surgically. However, recent advances have allowed endoscopists to perform a safe endoscopic resection for these polyps.

A Japanese retrospective study revealed the safety and effectiveness of ESD for the treatment of polyps involving the appendiceal orifice. For a total of 76 lesions, the authors reported a 95.0% *en bloc*



DOI: 10.3748/wjg.v29.i17.2600 Copyright ©The Author(s) 2023.

Figure 4 Prophylactic clip application at the stalk before polypectomy. A: A pedunculated polyp with a thick stalk and large head. There were failed attempts placing the endoloop due to the large polyp head; B: Clip application before snaring; C: No bleeding evidence after the resection.

resection rate, 1.3% perforation, and 2.6% post-ESD appendicitis rate. However, they excluded patients with lesions deeply involving the orifice and without a history of appendectomy. The authors emphasized that ESD should be performed by experienced and skilled endoscopists in this situation[42].

Binmoeller *et al*[43] suggested the usefulness of underwater endoscopic mucosal resection (UEMR) without submucosal injection for polyps involving the appendiceal orifice. With a water-filled lumen, the floating effect facilitated snare capture (Figure 5). They reported an 89% success ratio for UEMR in 27 polyps involving the appendiceal orifice (rim, 5 patients; extending deep inside, 22 patients). There was no perforation or post-resection appendicitis; however, 7% of the patients had post-polypectomy syndrome. During surveillance, 10% of the patients had residual adenomas that could be treated endoscopically.

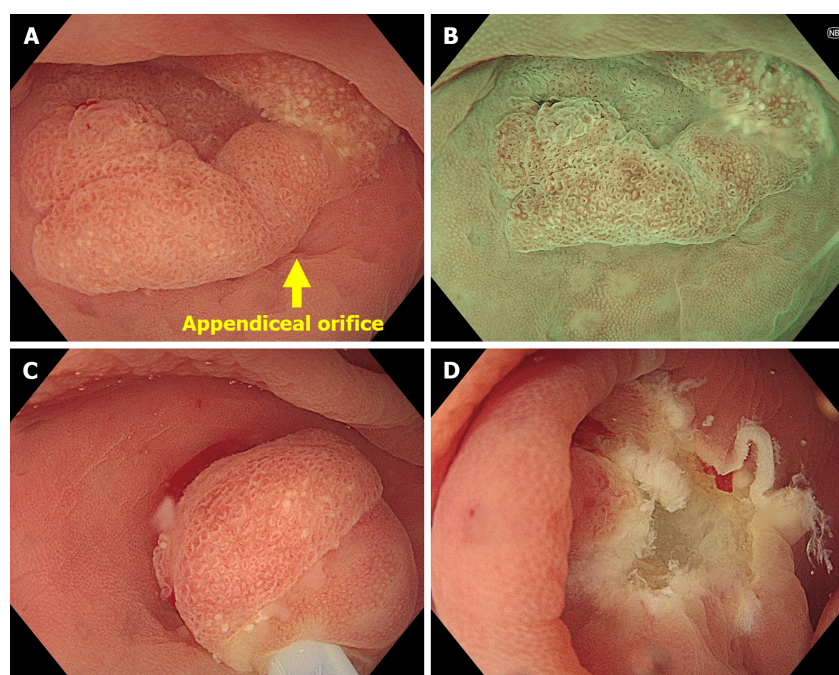
Endoscopic full-thickness resection (EFTR) has recently been employed for difficult polyps and is another suitable modality for polyps involving the appendiceal orifice. In a multicenter retrospective study, Schmidbaur *et al*[44] found that EFTR achieved R0 resection in 64% of 50 lesions involving the appendiceal orifice. However, 14% of patients developed acute appendicitis, and 42% of those with appendicitis required appendectomy. Similarly, a multicenter retrospective study by Ichkhanian *et al* [45], including 66 appendiceal orifice lesions (61% polyps extending deep into the appendiceal lumen) with a mean size of 14.5 mm, found that EFTR achieved an 89% technical success ratio and 93% R0 resection of the neoplastic lesions. Post-resection appendicitis occurred in 17% of patients without a prior history of appendectomy, and 60% (six patients) required appendectomy. Even with the promising outcomes of EFTR, the authors of both studies emphasized that patients must be counseled about the risk of post-resection appendicitis.

In summary, ESD is a viable option for polyps involving the rim of the appendiceal orifice for experienced endoscopists. However, ESD may not be feasible for lesions with a deep extension into the appendiceal orifice. UEMR is also a decent modality that is less technically demanding and has a high success rate. For lesions with deep extension into the appendiceal orifice, EFTR is the suitable option due to the high R0 resection rate. However, patients must be counseled regarding the risk of post-resection appendicitis.

Polyps on the ileocecal valve

Polyps on the ileocecal valve are technically challenging for endoscopic resection because the valve shape and orifice make it difficult to approach the lesions. Moreover, lesions may extend from the valve orifice to the terminal ileum. Therefore, resection is extremely difficult and associated with a high risk of recurrence[46]. A large retrospective study revealed a high complete resection rate (76.3%) of piecemeal EMR for polyps on the ileocecal valve, and the rate increased to 93.0% in the most recent eight years. Delayed bleeding and perforation occurred in 3.3% and 0% of the patients, and residual polyps were found in 16.5% and 18.6% during the first and second surveillance, respectively. They suggested four EMR keys for polyps on the ileocecal valve: (1) Use of a high-definition colonoscope; (2) use of a cap on the distal end of the scope; (3) inclusion of a dye in the injection fluid; and (4) initiating injection at the margin of the polyp with the valve orifice[47].

ESD for polyps on the ileocecal valve may be necessary for lesions suspected to be early carcinomas. However, ESD in this area is technically challenging because of the valve anatomy and composition. The ileocecal valve has abundant submucosal fatty tissue; consequently, the colonoscope lens often becomes cloudy during dissection. Yoshizaki *et al*[48] found no difference in the *en bloc* resection and perforation rates between ESD of lesions involving the ileocecal valve and lesions that did not involve it. Lesions involving the ileocecal valve were reported to have a 97% *en bloc* resection rate without perforation. The authors highlighted the critical steps for successful ESD. The mucosal incision should be started on the ileal side of the tumor to prevent the tumor from prolapsing into the terminal ileum.



DOI: 10.3748/wjg.v29.i17.2600 Copyright ©The Author(s) 2023.

Figure 5 Underwater endoscopic mucosal resection for a polyp involving appendiceal orifice. A: Endoscopic image showing a 15-mm sessile polyp involving the appendiceal orifice; B: Magnifying narrow-band image showing a type 1 polyp of the Japan Narrow-band Imaging Expert Team classification with open pit pattern. The most likely diagnosis was sessile serrated lesion; C: Underwater snaring without submucosal injection; D: Mucosal defect after completed underwater endoscopic mucosal resection.

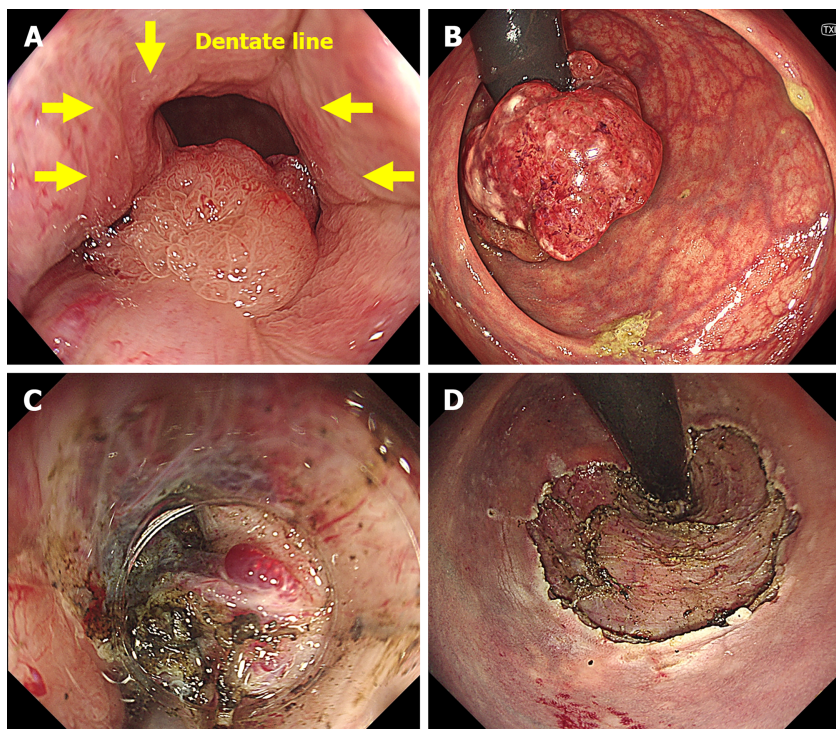
For areas with abundant submucosal fatty tissue, the electrical setting should be changed from the forced coagulation mode to the endocut or swift coagulation mode to enhance tissue cutting. Recently, Tanaka *et al*[49] conducted a study to evaluate the outcomes of ESD for polyps of the ileocecal valve with extension into the terminal ileum. They found that ESD of lesions with or without extension into the terminal ileum showed no difference in the *en bloc* resection rate (95% *vs* 94%, $P = 0.79$), R0 resection rate (90% *vs* 89%, $P = 0.89$), postoperative bleeding (5% *vs* 3%, $P = 0.79$), intraoperative perforation (0% *vs* 4%, $P = 0.34$), or delayed perforation (0% *vs* 0%, respectively). Therefore, ESD for polyps involving the ileocecal valve with extension into the terminal ileum is safe and effective in expert hands.

Polyps at the anorectal junction

Polyps close to the dentate line can be challenging to resect because of the risk of bleeding from the hemorrhoids. Polypectomy in this area is painful due to the sensory nerves in the squamous epithelium below the dentate line. Moreover, the anatomy of the anal sphincter makes it difficult to maintain good visualization[50]. For polyps at the anorectal junction that are indicated for ESD, Imai *et al*[51] proposed the following strategies: (1) Using a cap on the distal end of the scope to maintain good visualization in the narrow space of the anal canal; (2) addition of 1% lidocaine to the submucosal injection solution to prevent pain; (3) employing a horizontal approach with an endoscopic knife to minimize thermal damage to the muscular layer; and (4) performing preventive hemostasis when thick hemorrhoidal vessels are observed. With these strategies, they reported an *en bloc* resection rate of 95.6% and an R0 resection rate of 53.3%. The low R0 resection rate was due to burning artifacts on the anal side of the specimens. They reported a 4.4% perforation and a 2.2% postoperative bleeding rate. Tamaru *et al*[52] investigated the outcomes of ESD for polyps at the anorectal junction in patients with and without hemorrhoids. They found no differences in *en bloc* resection (93% *vs* 95%) or postoperative bleeding (16% *vs* 11%) rates between patients with and without hemorrhoids. Therefore, ESD is safe and effective for patients with lesions near the anorectal junction and hemorrhoids. Similarly, several studies have shown the safety and effectiveness of ESD for polyps at the anorectal junction[53-55]. In conclusion, ESD for polyps at the anorectal junction is safe even in the presence of hemorrhoids, and special strategies to prevent bleeding and pain should be implemented (Figure 6).

Locally recurrent colorectal polyps

Locally recurrent polyps mostly result from incomplete resections. A systematic review and meta-analysis found that local recurrence after EMR of non-pedunculated polyps occurred in 3% of *en bloc* resections and 20% of piecemeal resections, and 90% of recurrences were detected within 6 mo after EMR[56]. Locally recurrent polyps without risk factors for lymph node metastasis and positive vertical margins can be resected endoscopically[57]. However, endoscopic resection of locally recurrent polyps



DOI: 10.3748/wjg.v29.i17.2600 Copyright ©The Author(s) 2023.

Figure 6 Endoscopic submucosal dissection for a polyp involving the anorectal junction. A: Endoscopic image showing a 6-cm laterally spreading tumor involving the dentate line; B: Retroflexed view of the same polyp; C: Hemorrhoidal plexus at the anus makes the endoscopic submucosal dissection (ESD) challenging with the bleeding risk; D: Mucosal defect after completed ESD.

is extraordinarily challenging because it is associated with poor lifting with submucosal injection from submucosal fibrosis[58].

The 2020 JGES guidelines for colorectal ESD and EMR suggest that local recurrence of early carcinoma after endoscopic resection is an indication of ESD[10]. A Japanese retrospective study revealed that ESD had a higher *en bloc* resection rate than EMR for locally recurrent lesions (56% *vs* 39%, respectively), although the lesions in the ESD group were significantly larger than those in the EMR group (mean size; 25.3 mm *vs* 7.8 mm, $P = 0.001$)[59]. Perforations were not observed in the ESD group. However, this study was conducted at a single center with expertise in ESD. ESD for locally recurrent lesions is technically demanding and requires high operator skills. It is noted that the *en bloc* resection rate of locally recurrent polyps was much lower than their previous report of colorectal ESD (168/200 patients, 84%)[60]. Ide *et al*[61] conducted a retrospective study comparing ESD with the pocket-creation method using a traction device and conventional ESD for locally recurrent lesions. They found that ESD using the pocket-creation method with a traction device had higher *en bloc* resection and R0 resection rates than conventional ESD (100% *vs* 78%, $P = 0.008$, and 97% *vs* 66%, $P = 0.001$, respectively). Therefore, the combination of the pocket creation method and traction device is a promising strategy for the resection of locally recurrent polyps.

UEMR without submucosal injection has been reported as a promising technique for the salvage treatment of recurrent adenomas. Fibrosis prevents elevation of the recurrent lesion after submucosal injection, while the surrounding normal mucosa still elevates around the non-lifting lesion after the injection. This makes snare capture difficult. The floating effect after UEMR facilitates snare capture with minimal risk of perforation because the colonic muscularis propria remains circular with a water-filling lumen. Kim *et al*[62] conducted a retrospective, cross-sectional study involving patients with recurrent adenomas after piecemeal resection of colorectal LSTs. They found that the *en bloc* resection and complete resection rates were higher in the UEMR group than in the EMR group (47.2% *vs* 15.9%, $P = 0.002$, and 88.9% *vs* 31.8%, $P < 0.001$, respectively). The recurrence rate on surveillance colonoscopy was lower in the UEMR group than in the EMR group (10.0% *vs* 39.4%, $P = 0.020$). In this study, UEMR was an independent predictor of *en bloc* resection and complete removal.

In summary, ESD and UEMR are the appropriate modalities for treating locally recurrent colorectal polyps. Previous studies have shown a higher *en bloc* resection rate with ESD than with UEMR and ESD using the pocket-creation method and a traction device is a promising strategy for locally recurrent polyps. However, ESD for locally recurrent lesions is only suitable for centers with high ESD expertise because it is technically difficult, even with advances in ESD devices and techniques. In extremely difficult cases, endoscopists may consider surgery if the anticipated risk of complications is too high.

Polypectomy in patients with strong colonic peristalsis

Strong colonic spasm is a common obstacle during colorectal polypectomy, limiting visualization and scope manipulation. In this situation, endoscopists generally use antispasmodic drugs. Hyoscine butylbromide is the most common antispasmodic agent in practice, and the recommended dose is 20 mg *via* intravenous injection. Hyoscine butylbromide exerts an antimuscarinic anticholinergic effect that reduces the smooth muscle tone at multiple sites in the gastrointestinal tract. Contraindications of hyoscine butylbromide include cardiovascular disease, glaucoma, myasthenia gravis, and hypersensitivity to the drug[63]. In patients with these contraindications, other antispasmodic agents, including glucagon or peppermint oil, should be administered. The dose of glucagon is 1 mg *via* intravenous injection, which is contraindicated in patients with pheochromocytoma[64]. Peppermint oil was administered *via* intraluminal application of 20 mL of 1.6% L-menthol solution without contraindications[65]. Topical lidocaine, a local anesthetic, also functions as an antispasmodic agent by blocking the Na⁺ channels. It was administered *via* the intraluminal application of 30 mL of 2% lidocaine hydrochloride. An RCT found no difference in the inhibitory duration between topical lidocaine and peppermint oil; however, topical lidocaine significantly decreased rebound spasm[66].

In specific situations with intense colonic spasms, even with the administration of antispasmodic drugs, UEMR may be a decent modality. Another advantage of the water-filled lumen in UEMR is the stabilized visualization of the lumen. Pattarajierapan *et al*[67] reported successful UEMR for rectal adenoma in the non-distensible rectum due to severe fecal incontinence and intense colonic peristalsis. Therefore, UEMR may be a suitable option for patients with intense colonic spasms who have failed medication.

RECENT ADVANCES IN POLYPECTOMY DEVICES AND TECHNIQUES

Several technologies have been developed to aid endoscopists in performing safe and effective polypectomies, especially complex procedures such as ESD. These advances include video endoscopy system, equipment assisting in advanced polypectomy, and closure devices/techniques for complication management. Endoscopists should know how to use these devices and their availability in practice to enhance polypectomy performance, particularly in challenging cases.

Video endoscopy system

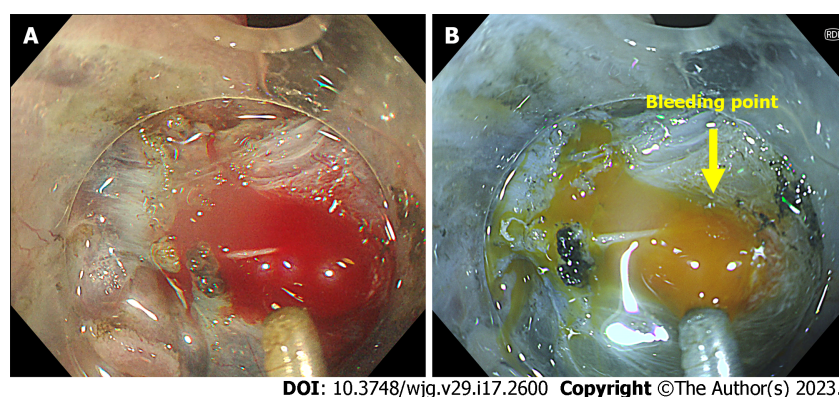
Red dichromatic imaging (RDI) was recently installed in the latest Olympus endoscopy system EVIS X1. RDI utilizes two long-wavelength lights (600 nm and 630 nm), which improve the visibility of thick blood vessels in deep tissues[68,69]. Therefore, easier identification of bleeding sources during polypectomy is expected in the RDI mode (Figure 7). Fujimoto *et al*[69] conducted an RCT comparing hemostatic procedures using RDI and white-light imaging (WLI). Although they found that RDI did not shorten the hemostatic time, it significantly reduced psychological stress compared to WLI. They concluded that it is safe and reasonable to use the RDI during hemostatic procedures to reduce the psychological stress experienced by endoscopists.

Equipment assisting advanced polypectomy

Although ESD has been widely accepted as a standard procedure for colorectal polyps that require *en bloc* resection, a limited number of endoscopists outside East Asia are competent owing to the difficulty of the method[70]. Colorectal ESD is more technically demanding than gastric or esophageal ESD because of its thin colonic wall and narrow colonic lumen, as well as peristalsis and respiratory movement. In addition to good training with experienced endoscopists, the recent development of traction devices and techniques may facilitate the procedure. The lack of traction during dissection contributes to the technical difficulty of ESD; therefore, various traction devices and techniques have been proposed (Figure 8). These devices include the clip-line method[71], S-O clip[72], double clips and rubber band traction[73], and traction wire[74]. To date, there have been no head-to-head comparisons of these traction devices, and the traction method has been selected based on tumor location and preference[75]. The clip-line method is helpful for rectal lesions but may not be feasible for colon lesions. For colonic ESD, endoscopists can use an S-O clip, double clips and rubber band traction, or traction wire. Without traction devices, ESD using the pocket creation method is a special technique that maintains a stable scope position inside the pocket while sustaining good traction[76,77]. This technique starts with an initial small mucosal incision, the creation of a submucosal pocket under most of the tumor, and then the completion of opening the pocket in a step-by-step manner.

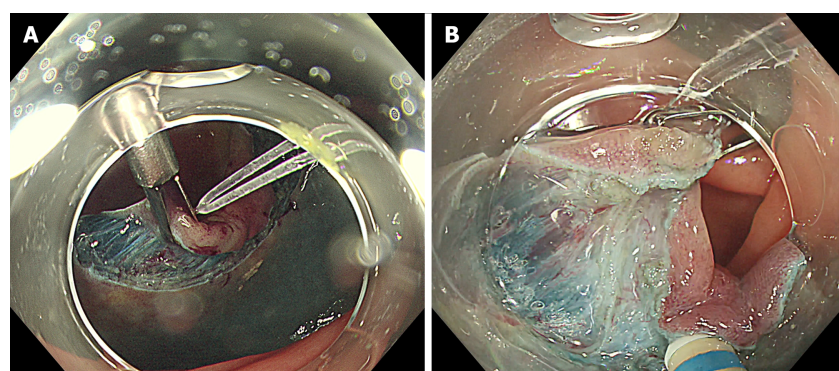
Closure devices and techniques for complication management

Perforation is the most feared complication of polypectomy. With advances in closure devices, most perforations after polypectomy can be closed endoscopically, thereby eliminating the need for surgery, which is associated with morbidity and mortality[78]. Endoscopic closure devices can be classified into through-the-scope clips (TTSC), over-the-scope clips (OTSC), and suturing devices. Useful modified



DOI: 10.3748/wjg.v29.i17.2600 Copyright ©The Author(s) 2023.

Figure 7 Bleeding during endoscopic submucosal dissection. A: Endoscopic image in white light imaging showing the bleeding from the large vessels of the polyp; B: Identification of bleeding sources during polypectomy is easier in the Red Dichromatic Imaging (RDI) mode. RDI mode also reduces the endoscopists' psychological stress by turning the blood color yellow.



DOI: 10.3748/wjg.v29.i17.2600 Copyright ©The Author(s) 2023.

Figure 8 Traction device during endoscopic submucosal dissection. A: Rubber band traction clip facilitating endoscopic submucosal dissection of a laterally spreading tumor with submucosal fibrosis; B: Traction force from the device helping during the submucosal dissection.

techniques in TTSC include the hold-and-drag closure technique using reopenable clips[78], mucosal incision method[79], endoloop-assisted clip closure[80], over-the-line clip method[80], and dual-action clip closure[81]. To date, no RCT has compared these closure techniques after colorectal polypectomy. Modified techniques in TTSC help close defects larger than the width of the clips. Therefore, endoscopists should learn these modified techniques, which are feasible for their centers because they may occasionally be necessary.

The OTSC system is a super-elastic nitinol clip that must be mounted at the end of an endoscope before deployment. This results in full-thickness closure of the teeth arranged in a bear-trap shape[78]. The reported successful closure rate for iatrogenic colon perforation for OTSC is 89%-100%[82-85]. However, the limitations of OTSC include lower success rates in the right colon compared with the left side and limited availability.

Endoscopic suturing is a promising method for defect closure with a 100% success rate in a report of 16 patients[86]. The endoscopic suturing device consists of a curved needle placed on the endoscope tip, a catheter-based suture anchor, and an operating handle attached to the neck of the instrument channel of the endoscope[87]. Limitations to the suturing device include the requirement of a double-channel endoscope and special training in endoscopic suturing to become competent in this technique. In addition, endoscopic suturing devices are expensive and limited in availability.

CONCLUSION

Recent advancements in EMR, ESD, and EFTR techniques and devices allow curative therapy of difficult colorectal polyps and prevent unnecessary surgery that carries the risk of morbidity and mortality. Moreover, these advancements also help endoscopists cope with feared complications, such as massive intra-procedural bleeding and perforation. However, proper selection of adjunct endoscopic devices/techniques according to polyp characteristics and step-by-step training for skill improvement are critical for successful advanced polypectomies. Based on current evidence, we summarize the stepwise

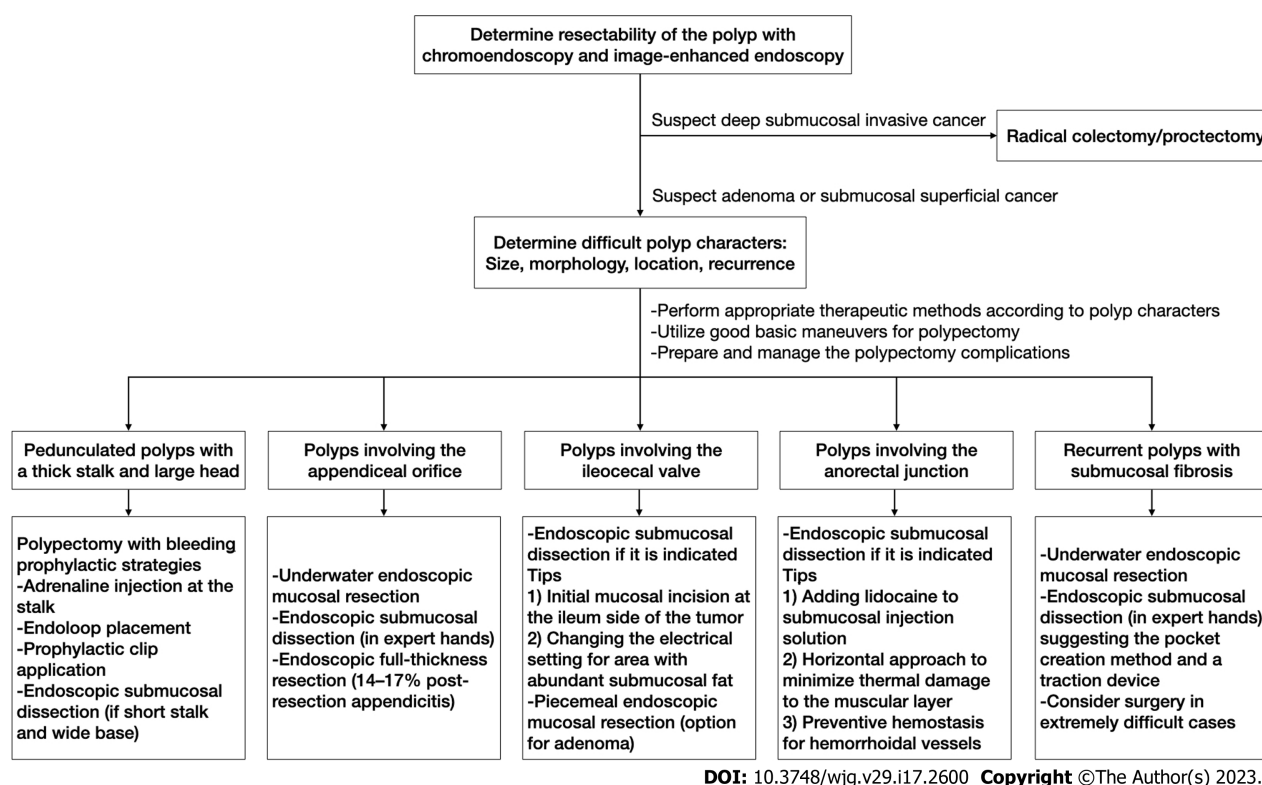


Figure 9 Stepwise approach for difficult colorectal polyps.

approach (Figure 9) that might help endoscopists make better decisions for the treatment of difficult colorectal polyps.

FOOTNOTES

Author contributions: Pattarajierapan S wrote the article; Takamaru H and Khomvilai S made substantial contributions to the content, offered critical revisions, and approved the final version of the article.

Conflict-of-interest statement: The authors have no conflicts of interest or financial ties to disclose.

Open-Access: This article is an open-access article that was selected by an in-house editor and fully peer-reviewed by external reviewers. It is distributed in accordance with the Creative Commons Attribution NonCommercial (CC BY-NC 4.0) license, which permits others to distribute, remix, adapt, build upon this work non-commercially, and license their derivative works on different terms, provided the original work is properly cited and the use is non-commercial. See: <https://creativecommons.org/licenses/by-nc/4.0/>

Country/Territory of origin: Thailand

ORCID number: Sukit Pattarajierapan 0000-0003-1042-8476; Hiroyuki Takamaru 0000-0002-7019-6331; Supakij Khomvilai 0000-0002-9703-9627.

Corresponding Author's Membership in Professional Societies: American Society for Gastrointestinal Endoscopy, No. 162994.

S-Editor: Chen YL

L-Editor: A

P-Editor: Cai YX

REFERENCES

- Sung H, Ferlay J, Siegel RL, Laversanne M, Soerjomataram I, Jemal A, Bray F. Global Cancer Statistics 2020: GLOBOCAN Estimates of Incidence and Mortality Worldwide for 36 Cancers in 185 Countries. *CA Cancer J Clin* 2021; 71: 209-249 [PMID: 33538338 DOI: 10.3322/caac.21660]

- 2 **Winawer SJ**, Zauber AG, Ho MN, O'Brien MJ, Gottlieb LS, Sternberg SS, Wayne JD, Schapiro M, Bond JH, Panish JF. Prevention of colorectal cancer by colonoscopic polypectomy. The National Polyp Study Workgroup. *N Engl J Med* 1993; **329**: 1977-1981 [PMID: [8247072](#) DOI: [10.1056/NEJM199312303292701](#)]
- 3 **Baxter NN**, Warren JL, Barrett MJ, Stukel TA, Doria-Rose VP. Association between colonoscopy and colorectal cancer mortality in a US cohort according to site of cancer and colonoscopist specialty. *J Clin Oncol* 2012; **30**: 2664-2669 [PMID: [22689809](#) DOI: [10.1200/JCO.2011.40.4772](#)]
- 4 **Gallegos-Orozco JF**, Gurudu SR. Complex colon polypectomy. *Gastroenterol Hepatol (N Y)* 2010; **6**: 375-382 [PMID: [20733940](#)]
- 5 **Ngamruengphong S**, Pohl H, Haito-Chavez Y, Khashab MA. Update on Difficult Polypectomy Techniques. *Curr Gastroenterol Rep* 2016; **18**: 3 [PMID: [26714965](#) DOI: [10.1007/s11894-015-0476-7](#)]
- 6 **Mann R**, Gajendran M, Umapathy C, Perisetti A, Goyal H, Saligram S, Echavarria J. Endoscopic Management of Complex Colorectal Polyps: Current Insights and Future Trends. *Front Med (Lausanne)* 2021; **8**: 728704 [PMID: [35127735](#) DOI: [10.3389/fmed.2021.728704](#)]
- 7 **Kudo S**, Tamura S, Nakajima T, Yamano H, Kusaka H, Watanabe H. Diagnosis of colorectal tumorous lesions by magnifying endoscopy. *Gastrointest Endosc* 1996; **44**: 8-14 [PMID: [8836710](#) DOI: [10.1016/s0016-5107\(96\)70222-5](#)]
- 8 **Sano Y**, Tanaka S, Kudo SE, Saito S, Matsuda T, Wada Y, Fujii T, Ikematsu H, Uraoka T, Kobayashi N, Nakamura H, Hotta K, Horimatsu T, Sakamoto N, Fu KI, Tsuruta O, Kawano H, Kashida H, Takeuchi Y, Machida H, Kusaka T, Yoshida N, Hirata I, Terai T, Yamano HO, Kaneko K, Nakajima T, Sakamoto T, Yamaguchi Y, Tamai N, Nakano N, Hayashi N, Oka S, Iwatate M, Ishikawa H, Murakami Y, Yoshida S, Saito Y. Narrow-band imaging (NBI) magnifying endoscopic classification of colorectal tumors proposed by the Japan NBI Expert Team. *Dig Endosc* 2016; **28**: 526-533 [PMID: [26927367](#) DOI: [10.1111/den.12644](#)]
- 9 **Hayashi N**, Tanaka S, Hewett DG, Kaltenbach TR, Sano Y, Ponchon T, Saunders BP, Rex DK, Soetikno RM. Endoscopic prediction of deep submucosal invasive carcinoma: validation of the narrow-band imaging international colorectal endoscopic (NICE) classification. *Gastrointest Endosc* 2013; **78**: 625-632 [PMID: [23910062](#) DOI: [10.1016/j.gie.2013.04.185](#)]
- 10 **Tanaka S**, Kashida H, Saito Y, Yahagi N, Yamano H, Saito S, Hisabe T, Yao T, Watanabe M, Yoshida M, Saitoh Y, Tsuruta O, Sugihara KI, Igarashi M, Toyonaga T, Ajioka Y, Kusunoki M, Koike K, Fujimoto K, Tajiri H. Japan Gastroenterological Endoscopy Society guidelines for colorectal endoscopic submucosal dissection/endoscopic mucosal resection. *Dig Endosc* 2020; **32**: 219-239 [PMID: [31566804](#) DOI: [10.1111/den.13545](#)]
- 11 **Tateishi Y**, Nakanishi Y, Taniguchi H, Shimoda T, Umemura S. Pathological prognostic factors predicting lymph node metastasis in submucosal invasive (T1) colorectal carcinoma. *Mod Pathol* 2010; **23**: 1068-1072 [PMID: [20473277](#) DOI: [10.1038/modpathol.2010.88](#)]
- 12 **Yamaoka Y**, Shiomi A, Kagawa H, Hino H, Manabe S, Chen K, Nanishi K, Notsu A. Lymph node metastasis in T1 colorectal cancer with the only high-risk histology of submucosal invasion depth $\geq 1000 \mu\text{m}$. *Int J Colorectal Dis* 2022; **37**: 2387-2395 [PMID: [36283994](#) DOI: [10.1007/s00384-022-04269-6](#)]
- 13 **Suh JH**, Han KS, Kim BC, Hong CW, Sohn DK, Chang HJ, Kim MJ, Park SC, Park JW, Choi HS, Oh JH. Predictors for lymph node metastasis in T1 colorectal cancer. *Endoscopy* 2012; **44**: 590-595 [PMID: [22638780](#) DOI: [10.1055/s-0031-1291665](#)]
- 14 **Kikuchi R**, Takano M, Takagi K, Fujimoto N, Nozaki R, Fujiyoshi T, Uchida Y. Management of early invasive colorectal cancer. Risk of recurrence and clinical guidelines. *Dis Colon Rectum* 1995; **38**: 1286-1295 [PMID: [7497841](#) DOI: [10.1007/BF02049154](#)]
- 15 **Kitajima K**, Fujimori T, Fujii S, Takeda J, Ohkura Y, Kawamata H, Kumamoto T, Ishiguro S, Kato Y, Shimoda T, Iwashita A, Ajioka Y, Watanabe H, Watanabe T, Muto T, Nagasako K. Correlations between lymph node metastasis and depth of submucosal invasion in submucosal invasive colorectal carcinoma: a Japanese collaborative study. *J Gastroenterol* 2004; **39**: 534-543 [PMID: [15235870](#) DOI: [10.1007/s00535-004-1339-4](#)]
- 16 **Nakadoi K**, Tanaka S, Kanao H, Terasaki M, Takata S, Oka S, Yoshida S, Arihiro K, Chayama K. Management of T1 colorectal carcinoma with special reference to criteria for curative endoscopic resection. *J Gastroenterol Hepatol* 2012; **27**: 1057-1062 [PMID: [22142484](#) DOI: [10.1111/j.1440-1746.2011.07041.x](#)]
- 17 **Matsuda T**, Fujii T, Saito Y, Nakajima T, Uraoka T, Kobayashi N, Ikehara H, Ikematsu H, Fu KI, Emura F, Ono A, Sano Y, Shimoda T, Fujimori T. Efficacy of the invasive/non-invasive pattern by magnifying chromoendoscopy to estimate the depth of invasion of early colorectal neoplasms. *Am J Gastroenterol* 2008; **103**: 2700-2706 [PMID: [18853968](#) DOI: [10.1111/j.1572-0241.2008.02190.x](#)]
- 18 **Togashi K**, Konishi F, Ishizuka T, Sato T, Senba S, Kanazawa K. Efficacy of magnifying endoscopy in the differential diagnosis of neoplastic and non-neoplastic polyps of the large bowel. *Dis Colon Rectum* 1999; **42**: 1602-1608 [PMID: [10613481](#) DOI: [10.1007/BF02236215](#)]
- 19 **Gupta S**, Miskovic D, Bhandari P, Dolwani S, McKaig B, Pullan R, Rembacken B, Riley S, Rutter MD, Suzuki N, Tsiamoulos Z, Valori R, Vance ME, Faiz OD, Saunders BP, Thomas-Gibson S. A novel method for determining the difficulty of colonoscopic polypectomy. *Frontline Gastroenterol* 2013; **4**: 244-248 [PMID: [28839733](#) DOI: [10.1136/flgastro-2013-100331](#)]
- 20 **Longcroft-Wheaton G**, Duku M, Mead R, Basford P, Bhandari P. Risk stratification system for evaluation of complex polyps can predict outcomes of endoscopic mucosal resection. *Dis Colon Rectum* 2013; **56**: 960-966 [PMID: [23838864](#) DOI: [10.1097/DCR.0b013e31829193e0](#)]
- 21 **Ferlitsch M**, Moss A, Hassan C, Bhandari P, Dumonceau JM, Paspatis G, Jover R, Langner C, Bronzwaer M, Nalankilli K, Fockens P, Hazzan R, Gralnek IM, Gschwantler M, Waldmann E, Jeschek P, Penz D, Heresbach D, Moons L, Lemmers A, Paraskeva K, Pohl J, Ponchon T, Regula J, Repici A, Rutter MD, Burgess NG, Bourke MJ. Colorectal polypectomy and endoscopic mucosal resection (EMR): European Society of Gastrointestinal Endoscopy (ESGE) Clinical Guideline. *Endoscopy* 2017; **49**: 270-297 [PMID: [28212588](#) DOI: [10.1055/s-0043-102569](#)]
- 22 **Kudo Se**, Lambert R, Allen JI, Fujii H, Fujii T, Kashida H, Matsuda T, Mori M, Saito H, Shimoda T, Tanaka S, Watanabe H, Sung JJ, Feld AD, Inadomi JM, O'Brien MJ, Lieberman DA, Ransohoff DF, Soetikno RM, Triadafilopoulos G, Zauber

- A, Teixeira CR, Rey JF, Jaramillo E, Rubio CA, Van Gossum A, Jung M, Vieth M, Jass JR, Hurlstone PD. Nonpolypoid neoplastic lesions of the colorectal mucosa. *Gastrointest Endosc* 2008; **68**: S3-47 [PMID: [18805238](#) DOI: [10.1016/j.gie.2008.07.052](#)]
- 23 **Hotta K**, Fujii T, Saito Y, Matsuda T. Local recurrence after endoscopic resection of colorectal tumors. *Int J Colorectal Dis* 2009; **24**: 225-230 [PMID: [18972121](#) DOI: [10.1007/s00384-008-0596-8](#)]
 - 24 **Oka S**, Tanaka S, Saito Y, Iishi H, Kudo SE, Ikematsu H, Igarashi M, Saitoh Y, Inoue Y, Kobayashi K, Hisabe T, Tsuruta O, Sano Y, Yamano H, Shimizu S, Yahagi N, Watanabe T, Nakamura H, Fujii T, Ishikawa H, Sugihara K; Colorectal Endoscopic Resection Standardization Implementation Working Group of the Japanese Society for Cancer of the Colon and Rectum, Tokyo, Japan. Local recurrence after endoscopic resection for large colorectal neoplasia: a multicenter prospective study in Japan. *Am J Gastroenterol* 2015; **110**: 697-707 [PMID: [25848926](#) DOI: [10.1038/ajg.2015.96](#)]
 - 25 **Tanaka S**, Saitoh Y, Matsuda T, Igarashi M, Matsumoto T, Iwao Y, Suzuki Y, Nozaki R, Sugai T, Oka S, Itabashi M, Sugihara KI, Tsuruta O, Hirata I, Nishida H, Miwa H, Enomoto N, Shimosegawa T, Koike K. Evidence-based clinical practice guidelines for management of colorectal polyps. *J Gastroenterol* 2021; **56**: 323-335 [PMID: [33710392](#) DOI: [10.1007/s00535-021-01776-1](#)]
 - 26 **Hotta K**, Oyama T, Shinohara T, Miyata Y, Takahashi A, Kitamura Y, Tomori A. Learning curve for endoscopic submucosal dissection of large colorectal tumors. *Dig Endosc* 2010; **22**: 302-306 [PMID: [21175483](#) DOI: [10.1111/j.1443-1661.2010.01005.x](#)]
 - 27 **Chien H**, Imai K, Hotta K, Ito S, Yamaguchi Y, Kawata N, Tanaka M, Takizawa K, Kakushima N, Matsubayashi H, Ono H. Tip-in EMR for R0 resection for a large flat colonic tumor. *Gastrointest Endosc* 2016; **84**: 743 [PMID: [27207826](#) DOI: [10.1016/j.gie.2016.05.017](#)]
 - 28 **Sato Y**, Ozawa SI, Yasuda H, Kato M, Kiyokawa H, Yamashita M, Matsuo Y, Yamamoto H, Itoh F. Tip-in endoscopic mucosal resection for large colorectal sessile polyps. *Surg Endosc* 2021; **35**: 1820-1826 [PMID: [32356110](#) DOI: [10.1007/s00464-020-07581-w](#)]
 - 29 **Takada K**, Hotta K, Imai K, Ito S, Kishida Y, Minamide T, Yamamoto Y, Yabuuchi Y, Yoshida M, Maeda Y, Kawata N, Takizawa K, Ishiwatari H, Matsubayashi H, Kawabata T, Ono H. Tip-in EMR as an alternative to endoscopic submucosal dissection for 20- to 30-mm nonpedunculated colorectal neoplasms. *Gastrointest Endosc* 2022; **96**: 849-856.e3 [PMID: [35798055](#) DOI: [10.1016/j.gie.2022.06.030](#)]
 - 30 **Yamada M**, Saito Y, Sakamoto T, Nakajima T, Kushima R, Parra-Blanco A, Matsuda T. Endoscopic predictors of deep submucosal invasion in colorectal laterally spreading tumors. *Endoscopy* 2016; **48**: 456-464 [PMID: [26919264](#) DOI: [10.1055/s-0042-100453](#)]
 - 31 **Dobrowolski S**, Dobosz M, Babicki A, Glowacki J, Nałecz A. Blood supply of colorectal polyps correlates with risk of bleeding after colonoscopic polypectomy. *Gastrointest Endosc* 2006; **63**: 1004-1009 [PMID: [16733117](#) DOI: [10.1016/j.gie.2005.11.063](#)]
 - 32 **Dobrowolski S**, Dobosz M, Babicki A, Dymecki D, Hać S. Prophylactic submucosal saline-adrenaline injection in colonoscopic polypectomy: prospective randomized study. *Surg Endosc* 2004; **18**: 990-993 [PMID: [15108107](#) DOI: [10.1007/s00464-003-9214-6](#)]
 - 33 **Lee SH**, Chung IK, Kim SJ, Kim JO, Ko BM, Kim WH, Kim HS, Park DI, Kim HJ, Byeon JS, Yang SK, Jang BI, Jung SA, Jeon YT, Choi JH, Choi H, Han DS, Song JS. Comparison of postpolypectomy bleeding between epinephrine and saline submucosal injection for large colon polyps by conventional polypectomy: a prospective randomized, multicenter study. *World J Gastroenterol* 2007; **13**: 2973-2977 [PMID: [17589949](#) DOI: [10.3748/wjg.v13.i21.2973](#)]
 - 34 **Hachisu T**. A new detachable snare for hemostasis in the removal of large polyps or other elevated lesions. *Surg Endosc* 1991; **5**: 70-74 [PMID: [1948617](#) DOI: [10.1007/BF00316840](#)]
 - 35 **Di Giorgio P**, De Luca L, Calcagno G, Rivellini G, Mandato M, De Luca B. Detachable snare vs epinephrine injection in the prevention of postpolypectomy bleeding: a randomized and controlled study. *Endoscopy* 2004; **36**: 860-863 [PMID: [15452780](#) DOI: [10.1055/s-2004-825801](#)]
 - 36 **Kouklakis G**, Mpoumponaris A, Gatopoulou A, Efraimidou E, Manolas K, Lirantzopoulos N. Endoscopic resection of large pedunculated colonic polyps and risk of postpolypectomy bleeding with adrenaline injection vs endoloop and hemoclip: a prospective, randomized study. *Surg Endosc* 2009; **23**: 2732-2737 [PMID: [19430833](#) DOI: [10.1007/s00464-009-0478-3](#)]
 - 37 **Paspatis GA**, Paraskeva K, Theodoropoulou A, Mathou N, Vardas E, Oustamanolakis P, Chlouverakis G, Karagiannis I. A prospective, randomized comparison of adrenaline injection in combination with detachable snare vs adrenaline injection alone in the prevention of postpolypectomy bleeding in large colonic polyps. *Am J Gastroenterol* 2006; **101**: 2805; quiz 2913 [PMID: [17026560](#) DOI: [10.1111/j.1572-0241.2006.00855.x](#)]
 - 38 **Jawaid S**, Draganov PV, Yang D. Endoscopic resection of large pedunculated colon polyps using only a scissor-type knife: a case series. *VideoGIE* 2020; **5**: 264-266 [PMID: [32529165](#) DOI: [10.1016/j.vgie.2020.02.016](#)]
 - 39 **Yamamoto S**, Shafazand M. Endoscopic submucosal dissection with scissor-type knife for pedunculated polyp with short and thick stalk. *VideoGIE* 2018; **3**: 189-190 [PMID: [30128383](#) DOI: [10.1016/j.vgie.2018.04.001](#)]
 - 40 **Soh JS**, Seo M, Kim KJ. Prophylactic clip application for large pedunculated polyps before snare polypectomy may decrease immediate postpolypectomy bleeding. *BMC Gastroenterol* 2020; **20**: 68 [PMID: [32164613](#) DOI: [10.1186/s12876-020-01210-5](#)]
 - 41 **Park CH**, Jung YS, Nam E, Eun CS, Park DI, Han DS. Comparison of Efficacy of Prophylactic Endoscopic Therapies for Postpolypectomy Bleeding in the Colorectum: A Systematic Review and Network Meta-Analysis. *Am J Gastroenterol* 2016; **111**: 1230-1243 [PMID: [27402502](#) DOI: [10.1038/ajg.2016.287](#)]
 - 42 **Jacob H**, Toyonaga T, Ohara Y, Tsubouchi E, Takihara H, Baba S, Yoshizaki T, Kawara F, Tanaka S, Ishida T, Hoshi N, Morita Y, Umegaki E, Azuma T. Endoscopic submucosal dissection of cecal lesions in proximity to the appendiceal orifice. *Endoscopy* 2016; **48**: 829-836 [PMID: [27467815](#) DOI: [10.1055/s-0042-110396](#)]
 - 43 **Binmoeller KF**, Hamerski CM, Shah JN, Bhat YM, Kane SD. Underwater EMR of adenomas of the appendiceal orifice (with video). *Gastrointest Endosc* 2016; **83**: 638-642 [PMID: [26375437](#) DOI: [10.1016/j.gie.2015.08.079](#)]
 - 44 **Schmidbauer S**, Wannhoff A, Walter B, Meier B, Schäfer C, Meining A, Caca K. Risk of appendicitis after endoscopic

- full-thickness resection of lesions involving the appendiceal orifice: a retrospective analysis. *Endoscopy* 2021; **53**: 424-428 [PMID: 32894866 DOI: 10.1055/a-1227-4555]
- 45 **Ichkhaniyan Y**, Barawi M, Seoud T, Thakkar S, Kothari TH, Halabi ME, Ullah A, Edris W, Aepli P, Kowalski T, Shinn B, Shariha RZ, Mahadev S, Mosko JD, Andrisani G, Di Matteo FM, Albrecht H, Giap AQ, Tang SJ, Naga YM, van Geenen E, Friedland S, Tharian B, Irani S, Ross AS, Jamil LH, Lew D, Nett AS, Farha J, Runge TM, Jovani M, Khashab MA. Endoscopic full-thickness resection of polyps involving the appendiceal orifice: a multicenter international experience. *Endoscopy* 2022; **54**: 16-24 [PMID: 33395714 DOI: 10.1055/a-1345-0044]
 - 46 **Nanda KS**, Tuticci N, Burgess NG, Sonson R, Williams SJ, Bourke MJ. Endoscopic mucosal resection of laterally spreading lesions involving the ileocecal valve: technique, risk factors for failure, and outcomes. *Endoscopy* 2015; **47**: 710-718 [PMID: 25763831 DOI: 10.1055/s-0034-1391732]
 - 47 **Ponugoti PL**, Broadley HM, Garcia J, Rex DK. Endoscopic management of large ileocecal valve lesions over an 18-year interval. *Endosc Int Open* 2019; **7**: E1646-E1651 [PMID: 31788547 DOI: 10.1055/a-0990-9035]
 - 48 **Yoshizaki T**, Toyonaga T, Tanaka S, Ohara Y, Kawara F, Baba S, Tsubouchi E, Takihara H, Watanabe D, Ishida T, Hoshi N, Morita Y, Umegaki E, Azuma T. Feasibility and safety of endoscopic submucosal dissection for lesions involving the ileocecal valve. *Endoscopy* 2016; **48**: 639-645 [PMID: 26990510 DOI: 10.1055/s-0042-102783]
 - 49 **Tanaka H**, Oka S, Kunihiro M, Nagata S, Kitamura S, Kuwai T, Hiraga Y, Furudoi A, Tanaka S. Endoscopic submucosal dissection for tumors involving the ileocecal valve with extension into the terminal ileum: a multicenter study from the Hiroshima GI Endoscopy Research Group. *Surg Endosc* 2023; **37**: 958-966 [PMID: 36070146 DOI: 10.1007/s00464-022-09542-x]
 - 50 **Nakadoi K**, Tanaka S, Hayashi N, Ozawa S, Terasaki M, Takata S, Kanao H, Oka S, Chayama K. Clinical outcomes of endoscopic submucosal dissection for rectal tumor close to the dentate line. *Gastrointest Endosc* 2012; **76**: 444-450 [PMID: 22817799 DOI: 10.1016/j.gie.2012.04.004]
 - 51 **Imai K**, Hotta K, Yamaguchi Y, Shinohara T, Ooka S, Shinoki K, Kakushima N, Tanaka M, Takizawa K, Matsubayashi H, Oishi T, Ono H. Safety and efficacy of endoscopic submucosal dissection of rectal tumors extending to the dentate line. *Endoscopy* 2015; **47**: 529-532 [PMID: 25502418 DOI: 10.1055/s-0034-1391078]
 - 52 **Tamaru Y**, Oka S, Tanaka S, Hiraga Y, Kunihiro M, Nagata S, Furudoi A, Ninomiya Y, Asayama N, Shigita K, Nishiyama S, Hayashi N, Chayama K. Endoscopic submucosal dissection for anorectal tumor with hemorrhoids close to the dentate line: a multicenter study of Hiroshima GI Endoscopy Study Group. *Surg Endosc* 2016; **30**: 4425-4431 [PMID: 26895899 DOI: 10.1007/s00464-016-4761-9]
 - 53 **Tanaka S**, Toyonaga T, Morita Y, Hoshi N, Ishida T, Ohara Y, Yoshizaki T, Kawara F, Umegaki E, Azuma T. Feasibility and safety of endoscopic submucosal dissection for lower rectal tumors with hemorrhoids. *World J Gastroenterol* 2016; **22**: 6268-6275 [PMID: 27468216 DOI: 10.3748/wjg.v22.i27.6268]
 - 54 **Matsumoto S**, Mashima H. The efficacy of endoscopic submucosal dissection for colorectal tumors extending to the dentate line. *Int J Colorectal Dis* 2017; **32**: 831-837 [PMID: 28188417 DOI: 10.1007/s00384-017-2775-y]
 - 55 **Probst A**, Ebigo A, Märkl B, Ting S, Schaller T, Anthuber M, Fleischmann C, Messmann H. Endoscopic submucosal dissection for rectal neoplasia extending to the dentate line: European experience. *Endosc Int Open* 2018; **6**: E1355-E1362 [PMID: 30410957 DOI: 10.1055/a-0749-8735]
 - 56 **Belderbos TD**, Leenders M, Moons LM, Siersema PD. Local recurrence after endoscopic mucosal resection of nonpedunculated colorectal lesions: systematic review and meta-analysis. *Endoscopy* 2014; **46**: 388-402 [PMID: 24671869 DOI: 10.1055/s-0034-1364970]
 - 57 **Shichijo S**, Takeuchi Y, Uedo N, Ishihara R. Management of local recurrence after endoscopic resection of neoplastic colonic polyps. *World J Gastrointest Endosc* 2018; **10**: 378-382 [PMID: 30631401 DOI: 10.4253/wjge.v10.i12.378]
 - 58 **Sato K**, Ito S, Kitagawa T, Kato M, Tominaga K, Suzuki T, Maetani I. Factors affecting the technical difficulty and clinical outcome of endoscopic submucosal dissection for colorectal tumors. *Surg Endosc* 2014; **28**: 2959-2965 [PMID: 24853849 DOI: 10.1007/s00464-014-3558-y]
 - 59 **Sakamoto T**, Saito Y, Matsuda T, Fukunaga S, Nakajima T, Fujii T. Treatment strategy for recurrent or residual colorectal tumors after endoscopic resection. *Surg Endosc* 2011; **25**: 255-260 [PMID: 20559661 DOI: 10.1007/s00464-010-1169-9]
 - 60 **Saito Y**, Uraoka T, Matsuda T, Emura F, Ikehara H, Mashimo Y, Kikuchi T, Fu KI, Sano Y, Saito D. Endoscopic treatment of large superficial colorectal tumors: a case series of 200 endoscopic submucosal dissections (with video). *Gastrointest Endosc* 2007; **66**: 966-973 [PMID: 17524403 DOI: 10.1016/j.gie.2007.02.053]
 - 61 **Ide D**, Ohya TR, Ishioka M, Enomoto Y, Nakao E, Mitsuoyoshi Y, Tokura J, Suzuki K, Yakabi S, Yasue C, Chino A, Igarashi M, Nakashima A, Saruta M, Saito S, Fujisaki J. Efficacy of the pocket-creation method with a traction device in endoscopic submucosal dissection for residual or recurrent colorectal lesions. *Clin Endosc* 2022; **55**: 655-664 [PMID: 35636748 DOI: 10.5946/ce.2022.009]
 - 62 **Kim HG**, Thosani N, Banerjee S, Chen A, Friedland S. Underwater endoscopic mucosal resection for recurrences after previous piecemeal resection of colorectal polyps (with video). *Gastrointest Endosc* 2014; **80**: 1094-1102 [PMID: 25012560 DOI: 10.1016/j.gie.2014.05.318]
 - 63 **Sanagapalli S**, Agnihotri K, Leong R, Corte CJ. Antispasmodic drugs in colonoscopy: a review of their pharmacology, safety and efficacy in improving polyp detection and related outcomes. *Therap Adv Gastroenterol* 2017; **10**: 101-113 [PMID: 28286563 DOI: 10.1177/1756283X16670076]
 - 64 **Hosseinezhad A**, Black RM, Aeddula NR, Adhikari D, Trivedi N. Glucagon-induced pheochromocytoma crisis. *Endocr Pract* 2011; **17**: e51-e54 [PMID: 21324811 DOI: 10.4158/EP10388.CR]
 - 65 **Inoue K**, Dohi O, Gen Y, Jo M, Mazaki T, Tokita K, Yoshida N, Okayama T, Kamada K, Katada K, Uchiyama K, Ishikawa T, Handa O, Takagi T, Konishi H, Wakabayashi N, Yagi N, Naito Y, Itoh Y. L-menthol improves adenoma detection rate during colonoscopy: a randomized trial. *Endoscopy* 2014; **46**: 196-202 [PMID: 24573731 DOI: 10.1055/s-0034-1365035]
 - 66 **Nemoto D**, Utano K, Isohata N, Endo S, Kumamoto K, Koshimizu TA, Lefor A, Togashi K. Topical lidocaine inhibits spasm during colonoscopy: a double-blind, randomized controlled trial (with video). *Endosc Int Open* 2017; **5**: E402-E407 [PMID: 28573171 DOI: 10.1055/s-0043-105489]

- 67 **Pattarajierapan S**, Khomvilai S. Underwater endoscopic mucosal resection of a rectal adenoma in the nondistensible rectum from severe fecal incontinence. *VideoGIE* 2021; **6**: 275-276 [PMID: [34141972](#) DOI: [10.1016/j.vgie.2021.02.014](#)]
- 68 **Uraoka T**, Igarashi M. Development and clinical usefulness of a unique red dichromatic imaging technology in gastrointestinal endoscopy: A narrative review. *Therap Adv Gastroenterol* 2022; **15**: 17562848221118302 [PMID: [36082177](#) DOI: [10.1177/17562848221118302](#)]
- 69 **Fujimoto A**, Saito Y, Abe S, Hoteya S, Nomura K, Yasuda H, Matsuo Y, Uraoka T, Kuribayashi S, Tsuji Y, Ohki D, Maehata T, Kato M, Yahagi N. Clinical usefulness of red dichromatic imaging in hemostatic treatment during endoscopic submucosal dissection: First report from a multicenter, open-label, randomized controlled trial. *Dig Endosc* 2022; **34**: 379-390 [PMID: [34775648](#) DOI: [10.1111/den.14191](#)]
- 70 **Ma MX**, Bourke MJ. Endoscopic submucosal dissection in the West: Current status and future directions. *Dig Endosc* 2018; **30**: 310-320 [PMID: [28884493](#) DOI: [10.1111/den.12960](#)]
- 71 **Yamasaki Y**, Takeuchi Y, Uedo N, Kanesaka T, Kato M, Hamada K, Tonai Y, Matsuura N, Akasaka T, Hanaoka N, Higashino K, Ishihara R, Okada H, Iishi H. Efficacy of traction-assisted colorectal endoscopic submucosal dissection using a clip-and-thread technique: A prospective randomized study. *Dig Endosc* 2018; **30**: 467-476 [PMID: [29424030](#) DOI: [10.1111/den.13036](#)]
- 72 **Sakamoto N**, Osada T, Shibuya T, Beppu K, Matsumoto K, Shimada Y, Konno A, Kurosawa A, Nagahara A, Ohkusa T, Ogihara T, Watanabe S. The facilitation of a new traction device (S-O clip) assisting endoscopic submucosal dissection for superficial colorectal neoplasms. *Endoscopy* 2008; **40** Suppl 2: E94-E95 [PMID: [19085712](#) DOI: [10.1055/s-2007-995603](#)]
- 73 **Oung B**, Rivory J, Chabrun E, Legros R, Faller J, Léger-Nguyen F, Rostain F, Ber CE, Hervieu V, Saurin JC, Ponchon T, Jacques J, Pioche M. ESD with double clips and rubber band traction of neoplastic lesions developed in the appendiceal orifice is effective and safe. *Endosc Int Open* 2020; **8**: E388-E395 [PMID: [32118111](#) DOI: [10.1055/a-1072-4830](#)]
- 74 **Bhatt A**, Hwang JH, Sharma NR, Waxman I. Traction wire endoscopic submucosal dissection: tips and techniques from 4 institutions. *VideoGIE* 2022; **7**: 21-22 [PMID: [35059534](#) DOI: [10.1016/j.vgie.2021.08.011](#)]
- 75 **Abe S**, Wu SYS, Ego M, Takamaru H, Sekiguchi M, Yamada M, Nonaka S, Sakamoto T, Suzuki H, Yoshinaga S, Matsuda T, Oda I, Saito Y. Efficacy of Current Traction Techniques for Endoscopic Submucosal Dissection. *Gut Liver* 2020; **14**: 673-684 [PMID: [31887810](#) DOI: [10.5009/gnl19266](#)]
- 76 **Hayashi Y**, Sunada K, Takahashi H, Shinhata H, Lefor AT, Tanaka A, Yamamoto H. Pocket-creation method of endoscopic submucosal dissection to achieve en bloc resection of giant colorectal subpedunculated neoplastic lesions. *Endoscopy* 2014; **46** Suppl 1 UCTN: E421-E422 [PMID: [25314173](#) DOI: [10.1055/s-0034-1377438](#)]
- 77 **Hayashi Y**, Miura Y, Yamamoto H. Pocket-creation method for the safe, reliable, and efficient endoscopic submucosal dissection of colorectal lateral spreading tumors. *Dig Endosc* 2015; **27**: 534-535 [PMID: [25708068](#) DOI: [10.1111/den.12465](#)]
- 78 **Raju GS**. Closure of Defects and Management of Complications. *Gastrointest Endosc Clin N Am* 2019; **29**: 705-719 [PMID: [31445692](#) DOI: [10.1016/j.giec.2019.06.005](#)]
- 79 **Otake Y**, Saito Y, Sakamoto T, Aoki T, Nakajima T, Toyoshima N, Matsuda T, Ono H. New closure technique for large mucosal defects after endoscopic submucosal dissection of colorectal tumors (with video). *Gastrointest Endosc* 2012; **75**: 663-667 [PMID: [22341112](#) DOI: [10.1016/j.gie.2011.10.037](#)]
- 80 **Nomura T**, Sugimoto S, Temma T, Oyama J, Ito K, Kamei A. Suturing techniques with endoscopic clips and special devices after endoscopic resection. *Dig Endosc* 2023; **35**: 287-301 [PMID: [35997063](#) DOI: [10.1111/den.14427](#)]
- 81 **Wei MT**, Friedland S. Use of a novel dual-action clip for closure of complex endoscopic resection defects. *VideoGIE* 2022; **7**: 389-391 [PMID: [36407049](#) DOI: [10.1016/j.vgie.2022.08.005](#)]
- 82 **Verlaan T**, Voermans RP, van Berge Henegouwen MI, Bemelman WA, Fockens P. Endoscopic closure of acute perforations of the GI tract: a systematic review of the literature. *Gastrointest Endosc* 2015; **82**: 618-28.e5 [PMID: [26005015](#) DOI: [10.1016/j.gie.2015.03.1977](#)]
- 83 **Voermans RP**, Le Moine O, von Renteln D, Ponchon T, Giovannini M, Bruno M, Weusten B, Seewald S, Costamagna G, Deprez P, Fockens P; CLIPPER Study Group. Efficacy of endoscopic closure of acute perforations of the gastrointestinal tract. *Clin Gastroenterol Hepatol* 2012; **10**: 603-608 [PMID: [22361277](#) DOI: [10.1016/j.cgh.2012.02.005](#)]
- 84 **Gubler C**, Bauerfeind P. Endoscopic closure of iatrogenic gastrointestinal tract perforations with the over-the-scope clip. *Digestion* 2012; **85**: 302-307 [PMID: [22614286](#) DOI: [10.1159/000336509](#)]
- 85 **Kirschniak A**, Subotova N, Zieker D, Königsrainer A, Kratt T. The Over-The-Scope Clip (OTSC) for the treatment of gastrointestinal bleeding, perforations, and fistulas. *Surg Endosc* 2011; **25**: 2901-2905 [PMID: [21424197](#) DOI: [10.1007/s00464-011-1640-2](#)]
- 86 **Kantsevov SV**, Bitner M, Hajiyeva G, Mirovski PM, Cox ME, Swope T, Alexander K, Meenaghan N, Fitzpatrick JL, Gushchin V. Endoscopic management of colonic perforations: clips versus suturing closure (with videos). *Gastrointest Endosc* 2016; **84**: 487-493 [PMID: [26364965](#) DOI: [10.1016/j.gie.2015.08.074](#)]
- 87 **Staudenmann D**, Choi KKH, Kaffes AJ, Saxena P. Current endoscopic closure techniques for the management of gastrointestinal perforations. *Ther Adv Gastrointest Endosc* 2022; **15**: 26317745221076705 [PMID: [35252863](#) DOI: [10.1177/26317745221076705](#)]



Published by **Baishideng Publishing Group Inc**
7041 Koll Center Parkway, Suite 160, Pleasanton, CA 94566, USA

Telephone: +1-925-3991568

E-mail: bpgoffice@wjgnet.com

Help Desk: <https://www.f6publishing.com/helpdesk>

<https://www.wjgnet.com>

