

# World Journal of *Clinical Cases*

*World J Clin Cases* 2023 December 6; 11(34): 8094-8241



## Contents

Thrice Monthly Volume 11 Number 34 December 6, 2023

## EDITORIAL

- 8094** Advances and future directions in keloid research: Pathogenesis, diagnosis and personalized treatment strategies

*Zhao SY, Wu D, Cheng C, Xie JH*

## OPINION REVIEW

- 8099** Mental health implications of suicide rates in South Africa

*Edeh NC, Eseadi C*

- 8106** Artificial intelligence in sleep medicine: Present and future

*Verma RK, Dhillon G, Grewal H, Prasad V, Munjal RS, Sharma P, Buddhavarapu V, Devadoss R, Kashyap R, Surani S*

## REVIEW

- 8111** Research progress on the relationship between Paneth cells-susceptibility genes, intestinal microecology and inflammatory bowel disease

*Zhou QM, Zheng L*

## ORIGINAL ARTICLE

## Case Control Study

- 8126** Case-control analysis of venous thromboembolism risk in non-alcoholic steatohepatitis diagnosed by transient elastography

*Suresh MG, Gogtay M, Singh Y, Yadukumar L, Mishra AK, Abraham GM*

## Retrospective Study

- 8139** Efficacy and safety of tenofovir alafenamide in patients with chronic hepatitis B exhibiting suboptimal response to entecavir

*Yuan GC, Chen AZ, Wang WX, Yi XL, Tu L, Peng F, Qiu ZH*

## Prospective Study

- 8147** Arthroscopic findings after manipulation under anesthesia in idiopathic capsulitis of the shoulder: A prospective study

*Malv SK, Mittal R, Chauhan N*

## CASE REPORT

- 8153** Intra-arterial lipo-prostaglandin E1 infusion for arterial spasm in liver transplantation: A case report

*Kim M, Lee HW, Yoon CJ, Lee B, Jo Y, Cho JY, Yoon YS, Lee JS, Han HS*

- 8158** Pulmonary fungal infection in a neonate with methylmalonic acidemia: A case report

*Gao CF, Wang D, Zeng LK, Tao XW*

- 8164** Adult localized Langerhans cell histiocytosis: A case report  
*Yang PP, Hu SY, Chai XY, Shi XM, Liu LX, Li LE*
- 8170** Venous adventitial cystic disease is a very rare disease that can cause deep vein thrombosis: A case report  
*Bae M, Huh U, Lee CW, Kim JW*
- 8176** Rare case of lupus enteritis presenting as colorectum involvement: A case report and review of literature  
*Gan H, Wang F, Gan Y, Wen L*
- 8184** Repeated atrial arrhythmia induced by cochineal red poisoning: A case report  
*Yang H, Wang YJ, Xu BP, Peng HW, Xu Q, Yu HB*
- 8192** Anti-glial fibrillary acidic protein antibody and anti-aquaporin-4 antibody double-positive neuromyelitis optica spectrum disorder: A case report  
*Jin TY, Lin BT, Dai LJ, Lu X, Gao H, Hu J*
- 8200** Thoracic duct cannulation during left internal jugular vein cannulation: A case report  
*Hwang GH, Eom W*
- 8205** Long-term survival of the Sister Mary Joseph nodule originating from breast cancer: A case report  
*Kanayama K, Tanioka M, Hattori Y, Iida T, Okazaki M*
- 8212** Hemophagocytic lymphohistiocytosis with jaundice as first manifestation: A case report  
*Wang DD, Wu S, Kong BB, Song LL*
- 8219** Comprehensive treatment of deep frostbite of multiple fingers after trauma: A case report  
*Wang XH, Li M, Cheng Y, Wang GJ, Lin GL, Liu WN*
- 8228** Bilateral snapping triceps syndrome: A case report  
*Cho CH, Lim KH, Kim DH*
- 8235** Management of post-liver transplantation biliary stricture inaccessible by endoscopic retrograde cholangiopancreatography: A case report  
*Lee Y, Park CH, Cho E, Kim KH*

**ABOUT COVER**

Editorial Board Member of *World Journal of Clinical Cases*, Dong-Ling Dai, MBBS, PhD, Chief Doctor, Professor, Department of Endoscopy Center and Gastroenterology, Shenzhen Children's Hospital, Shenzhen 518036, Guangdong Province, China. daidong3529@sina.com

**AIMS AND SCOPE**

The primary aim of *World Journal of Clinical Cases* (WJCC, *World J Clin Cases*) is to provide scholars and readers from various fields of clinical medicine with a platform to publish high-quality clinical research articles and communicate their research findings online.

WJCC mainly publishes articles reporting research results and findings obtained in the field of clinical medicine and covering a wide range of topics, including case control studies, retrospective cohort studies, retrospective studies, clinical trials studies, observational studies, prospective studies, randomized controlled trials, randomized clinical trials, systematic reviews, meta-analysis, and case reports.

**INDEXING/ABSTRACTING**

The WJCC is now abstracted and indexed in Science Citation Index Expanded (SCIE, also known as SciSearch®), Journal Citation Reports/Science Edition, Current Contents®/Clinical Medicine, PubMed, PubMed Central, Reference Citation Analysis, China Science and Technology Journal Database, and Superstar Journals Database. The 2023 Edition of Journal Citation Reports® cites the 2022 impact factor (IF) for WJCC as 1.1; IF without journal self cites: 1.1; 5-year IF: 1.3; Journal Citation Indicator: 0.26; Ranking: 133 among 167 journals in medicine, general and internal; and Quartile category: Q4.

**RESPONSIBLE EDITORS FOR THIS ISSUE**

Production Editor: Si Zhao; Production Department Director: Xu Guo; Editorial Office Director: Jin-Lei Wang.

**NAME OF JOURNAL**

*World Journal of Clinical Cases*

**ISSN**

ISSN 2307-8960 (online)

**LAUNCH DATE**

April 16, 2013

**FREQUENCY**

Thrice Monthly

**EDITORS-IN-CHIEF**

Bao-Gan Peng, Salim Surani, Jerzy Tadeusz Chudek, George Kontogeorgos, Maurizio Serati

**EDITORIAL BOARD MEMBERS**

<https://www.wjgnet.com/2307-8960/editorialboard.htm>

**PUBLICATION DATE**

December 6, 2023

**COPYRIGHT**

© 2023 Baishideng Publishing Group Inc

**INSTRUCTIONS TO AUTHORS**

<https://www.wjgnet.com/bpg/gerinfo/204>

**GUIDELINES FOR ETHICS DOCUMENTS**

<https://www.wjgnet.com/bpg/GerInfo/287>

**GUIDELINES FOR NON-NATIVE SPEAKERS OF ENGLISH**

<https://www.wjgnet.com/bpg/gerinfo/240>

**PUBLICATION ETHICS**

<https://www.wjgnet.com/bpg/GerInfo/288>

**PUBLICATION MISCONDUCT**

<https://www.wjgnet.com/bpg/gerinfo/208>

**ARTICLE PROCESSING CHARGE**

<https://www.wjgnet.com/bpg/gerinfo/242>

**STEPS FOR SUBMITTING MANUSCRIPTS**

<https://www.wjgnet.com/bpg/GerInfo/239>

**ONLINE SUBMISSION**

<https://www.f6publishing.com>



## Intra-arterial lipo-prostaglandin E1 infusion for arterial spasm in liver transplantation: A case report

Moonhwan Kim, Hae Won Lee, Chang Jin Yoon, Boram Lee, Yeongsoo Jo, Jai Young Cho, Yoo-Seok Yoon, Jun Suh Lee, Ho-Seong Han

**Specialty type:** Transplantation

**Provenance and peer review:**

Unsolicited article; Externally peer reviewed.

**Peer-review model:** Single blind

**Peer-review report's scientific quality classification**

Grade A (Excellent): 0

Grade B (Very good): 0

Grade C (Good): C, C, C, C, C

Grade D (Fair): 0

Grade E (Poor): 0

**P-Reviewer:** Gupta R, India; Li HL, China; Surani S, United States; Teragawa H, Japan

**Received:** July 12, 2023

**Peer-review started:** July 12, 2023

**First decision:** August 24, 2023

**Revised:** October 18, 2023

**Accepted:** November 27, 2023

**Article in press:** November 27, 2023

**Published online:** December 6, 2023



**Moonhwan Kim, Hae Won Lee, Boram Lee, Yeongsoo Jo, Jai Young Cho, Yoo-Seok Yoon, Jun Suh Lee, Ho-Seong Han**, Department of Surgery, Seoul National University Bundang Hospital, Seoul National University College of Medicine, Seongnam-si 13620, Gyeonggi-do, South Korea

**Chang Jin Yoon**, Department of Radiology, Seoul National University, Seongnam 463-707, South Korea

**Corresponding author:** Hae Won Lee, MD, PhD, Professor, Department of Surgery, Seoul National University Bundang Hospital, Seoul National University College of Medicine, Gumi-ro 173 Beon-gil, Bundang-gu, Seongnam-si 13620, Gyeonggi-do, South Korea.

[lansh@hanmail.net](mailto:lansh@hanmail.net)

### Abstract

#### BACKGROUND

Hepatic artery obstruction is a critical consideration in graft outcomes after living donor liver transplantation. We report a case of diffuse arterial vasospasm that developed immediately after anastomosis and was managed with an intra-arterial infusion of lipo-prostaglandin E1 (PGE1).

#### CASE SUMMARY

A 57-year-old male with hepatitis B virus-related liver cirrhosis and hepatocellular carcinoma underwent ABO-incompatible living donor liver transplant. The grafted hepatic artery was first anastomosed to the recipient's right hepatic artery stump. However, the arterial pulse immediately weakened. Although a new anastomosis was performed using the right gastropiploic artery, the patient's arterial pulse rate remained poor. We attempted angiographic intervention immediately after the operation; it showed diffuse arterial vasospasms like 'beads on a string'. We attempted continuous infusion of lipo-PGE1 overnight *via* an intra-arterial catheter. The next day, arterial flow improved without any spasms or strictures. The patient had no additional arterial complications or related sequelae at the time of writing, 1-year post-liver transplantation.

#### CONCLUSION

Angiographic evaluation is helpful in cases of repetitive arterial obstruction, and intra-arterial infusion of lipo-PGE1 may be effective in treating diffuse arterial spasms.

**Key Words:** Liver transplantation; Hepatic artery; Vasospasm; Prostaglandin E1; Intervention; Case report

©The Author(s) 2023. Published by Baishideng Publishing Group Inc. All rights reserved.

**Core Tip:** Diffuse arterial spasms are difficult to correct surgically, and there are no clear standard management protocols. This short report shows that angiography is helpful for evaluating the hepatic artery after liver transplantation and that intra-arterial infusion of lipo-prostaglandin E1 might be an effective non-surgical treatment option for diffuse arterial spasms.

**Citation:** Kim M, Lee HW, Yoon CJ, Lee B, Jo Y, Cho JY, Yoon YS, Lee JS, Han HS. Intra-arterial lipo-prostaglandin E1 infusion for arterial spasm in liver transplantation: A case report. *World J Clin Cases* 2023; 11(34): 8153-8157

**URL:** <https://www.wjgnet.com/2307-8960/full/v11/i34/8153.htm>

**DOI:** <https://dx.doi.org/10.12998/wjcc.v11.i34.8153>

## INTRODUCTION

Liver transplantation (LT) is a favorable treatment option for advanced liver cirrhosis, hepatocellular carcinoma (HCC), and other life-threatening diseases. However, LT can be complicated depending on the recipient's condition, immunological issues, and technical difficulties. Problems with LT include primary non-function, rejection, and biliary or vascular complications. Hepatic artery complications, such as thrombosis or stenosis, are among the most critical complications of LT[1,2]. They are more frequent in living donor LTs (LDLT) and can lead to anastomotic rupture, sepsis, diffuse intrahepatic biliary stricture, and graft failure[3-5]. Thus, arterial flow is usually evaluated using a duplex Doppler ultrasound scan before the operation is completed and again during the early postoperative period. Although hepatic artery complications are usually managed with thrombectomy and re-anastomosis, they can often be controlled with radiological intervention and medical management. Recently, we encountered a case of LT with diffuse arterial spasm that was not surgically corrected but was successfully managed with intra-arterial lipo-prostaglandin E1 (PGE1).

## CASE PRESENTATION

### Chief complaints

A 57-year-old male patient presented with hepatitis B virus-related liver disease and multiple HCCs.

### History of present illness

Eventually, the patient underwent ABO-incompatible LDLT from his 29-year-old daughter despite having good liver function (Child-Pugh score, 5; Model for end-stage liver disease score, 8).

### History of past illness

Although he underwent radiofrequency ablation for HCC, followed by four rounds of transarterial chemoembolization for two years, subsequent imaging studies still showed multiple dysplastic nodules or possible HCCs.

### Personal and family history

He presented with hepatitis B virus-related liver disease and multiple HCCs.

### Laboratory examinations

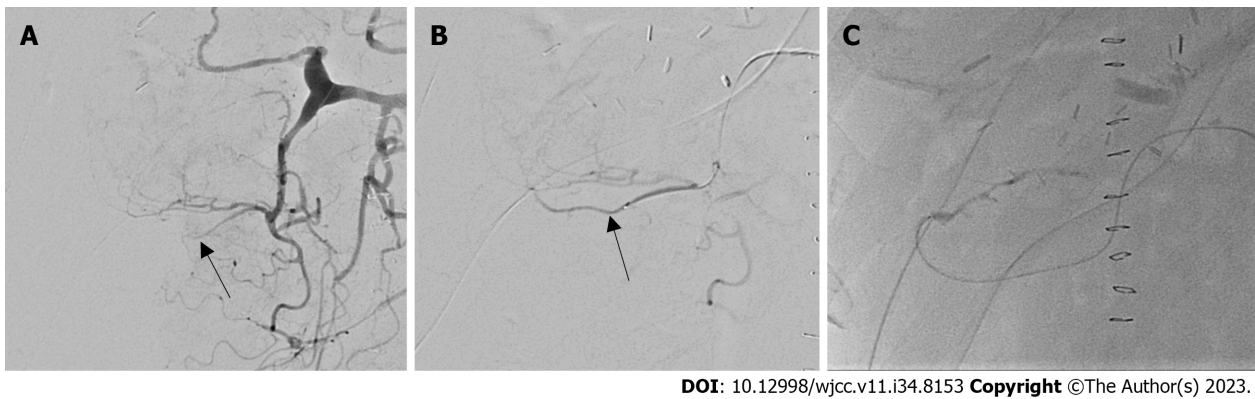
The patient's blood type was B+, whereas the donor's was AB+. The patient was treated with rituximab and plasmapheresis before transplantation. Rituximab was administered at a single dose of 300 mg/m<sup>2</sup> body surface area. Plasmapheresis was performed in triplicate. The final anti-A isoagglutinin titer was 1:8 before LT.

### Operation process

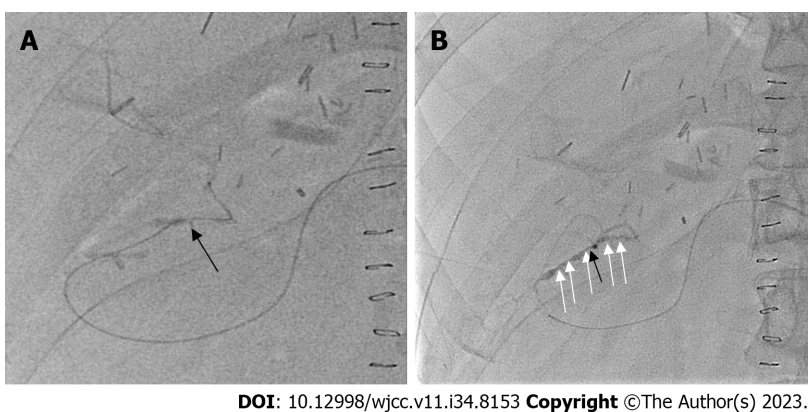
The right liver graft was retrieved laparoscopically, and the hepatic vein branch from segment 5 was reconstructed using a polytetrafluoroethylene artificial graft. No events occurred during the donor or bench surgeries. The graft weight was 654 g, and the graft-to-recipient weight ratio was 0.99. Anastomoses of the hepatic and portal veins were performed, and reperfusion was uneventful. The first and second warm ischemia times were 12 and 55 min, respectively, whereas the cold ischemia time was 58 min.

The graft hepatic artery was first anastomosed end-to-end to the recipient's right hepatic artery stump using interrupted 8-0 nylon. The first pulse of the hepatic artery was good after the anastomosis. However, the arterial pulse was much weaker when rechecked after the bile duct anastomosis. We were unable to detect arterial flow in the graft using intraoperative Doppler imaging; thus, we removed the anastomosis and attempted re-anastomosis. No definitive





**Figure 1 Angiography immediately following liver transplantation.** A: The hepatic artery and right gastroepiploic artery (RGEA) were not initially delineated (black arrow); B: RGEA (black arrow) was gradually visualized using thrombolysis; C: Anastomotic site between the RGEA and the graft artery.



**Figure 2 Diffuse arterial spasm on angiography.** A: Guidewire passed through the anastomotic site (black arrow); B: Diffuse arterial spasm (white arrows) in the right gastroepiploic artery and graft artery.

arterial thrombosis was observed. After heparin injection into both arteries, re-anastomosis was performed in the same manner; however, the arterial pulse weakened. We decided to change the artery on the recipient's side because of the poor quality of the recipient's hepatic artery from the previous chemoembolization. We carefully dissected the right gastroepiploic artery (RGEA) from the lower body of the gastric greater curvature and created a new anastomosis in the same manner. However, the pulse rate of the hepatic artery was poor. We decided to perform an angiographic intervention immediately after the operation.

## MULTIDISCIPLINARY EXPERT CONSULTATION

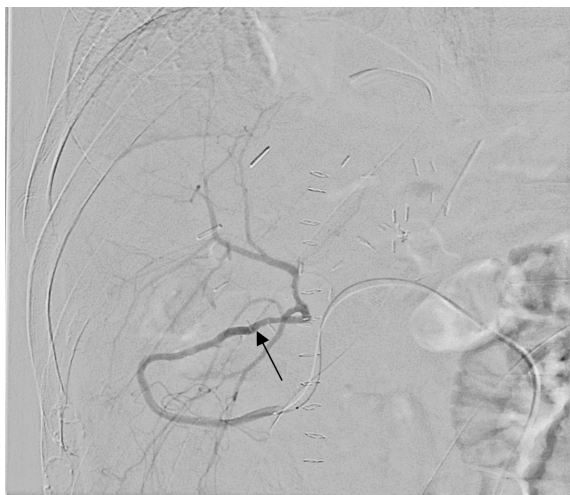
The RGEA was not well-delineated on the first angiography (Figure 1). Thrombolysis was induced by injecting heparin and a tissue plasminogen activator into the gastroduodenal artery just once. After thrombolysis, the RGEA and hepatic artery anastomosis sites were delineated.

## FINAL DIAGNOSIS

Although there was no mechanical stricture at the anastomosis site, multiple irregular constrictions were found in the RGEA and graft hepatic artery, which looked like 'beads on a string' (Figure 2).

## TREATMENT

We attempted infusion of lipo-PGE1 *via* an arterial catheter for diffuse arterial spasm. We observed improvement in the spasm 10-20 min later. Thus, we decided to maintain the intra-arterial infusion of lipo-PGE1 overnight at 6 µg/h, in addition to an intravenous infusion of 20 µg/h, based on the routine protocol. Since there was no study of complications



DOI: 10.12998/wjcc.v11.i34.8153 Copyright ©The Author(s) 2023.

**Figure 3** Angiography after overnight intra-arterial infusion of lipo-prostaglandin E1. Good arterial flow with no spasms or anastomotic strictures (black arrow).

after such a liver transplant, there was no exact criterion for doses, so I started with a 1/3 dose of the Systemic Dose and then used a method of gradually increasing the spasm when F/U Angiography done on the following day revealed excellent arterial flow without spasms or strictures (Figure 3). Diffuse arterial spasms completely disappeared. We stopped the continuous infusion of intra-arterial PGE1 and removed the arterial catheter on the second postoperative day (POD).

## OUTCOME AND FOLLOW-UP

Vascular flow was repeatedly evaluated using Doppler ultrasound every day until the third POD with dynamic computed tomography (CT) on the sixth POD. The arterial flow was good in all examinations, and no additional intervention was required. Intravenous lipo-PGE1 was administered until sixth postoperative POD. The patient was discharged on the thirteenth POD. A recent CT scan performed 10 mo post-LT also showed good arterial flow. Eventually, the patient had no additional arterial complications or related sequelae at the time of writing, 1-year post-LT.

## DISCUSSION

Many studies have been published on hepatic artery complications after LT. The treatment of choice for these complications is revascularization by surgery or radiological intervention. However, because the anastomosis is very narrow and the arterial course may be tortuous in LDLT, an interventional approach may be difficult. If both surgery and intervention fail to correct these complications, the only way forward may be observation with or without medical treatment, and retransplantation may be needed in many situations[6].

Diffuse vasospasm of the hepatic artery is rare in LT, and its standard management remains unclear. Delayed cerebral ischemia due to cerebral vasospasm is known to be one of the most fatal complications after subarachnoid hemorrhage [7]. Treatment options for cerebral vasospasm include intravenous volume expansion, radiological interventions, such as balloon angioplasty, and intra-arterial injection of a vasodilator[7,8]. Diffuse arterial spasms are difficult to treat surgically. Although the spasm may be transient and leave no sequelae, it still needs to be thoroughly evaluated and managed because arterial flow disturbances in the early postoperative period can lead to diffuse intrahepatic cholangiopathy and graft failure.

As a vasodilator, PGE1 acts directly on the vascular smooth muscles and decreases the response to vasoconstriction[9]. PGE1 is commonly used in LT because of its effects on graft protection, including an increase in hepatic blood flow, enhanced recovery of mitochondrial respiration function after reperfusion, and stabilization of membrane microviscosity [10]. According to our LT protocol, we infuse lipo-PGE1 intravenously immediately after reperfusion, and continuous infusion of 20 µg/h is maintained through the sixth POD. In this case, we added lipo-PGE1 at 6 µg/h *via* an intra-arterial catheter. Diffuse spasms completely blocked arterial flow despite the administration of intravenous lipo-PGE1. Fortunately, intra-arterial infusion led to a quick improvement in the spasm, which resolved the next day.

The cause of the diffuse arterial spasm was not clarified in this case. Such an event is rare, and the present case represents our first experience. Hepatic artery vasospasms can resolve without treatment. Hepatic artery flow, however, is critical to the viability of the bile duct, and its insufficiency can cause fatal outcomes in LT.



## CONCLUSION

Our experience shows that angiography is helpful for evaluating the hepatic artery after LT and that intra-arterial infusion of lipo-PGE1 may be effective in treating diffuse arterial spasms. Therefore, we suggest that early angiographic evaluation can be attempted in suspected post-LT arterial insufficiency cases, and intra-arterial PGE1 can be considered in patients with severe arterial spasms.

## FOOTNOTES

**Author contributions:** Kim M and Lee HW participated in the research design; Yoon CJ, Lee B, Jo Y, Cho JY, Yoon YS, Lee JS, and Han HS participated in the performance of the research and in the data analysis; Kim M and Lee HW participated in the writing of the article.

**Informed consent statement:** Informed written consent was obtained from the patient for publication of this report and any accompanying images.

**Conflict-of-interest statement:** There are no conflicts of interest to report.

**CARE Checklist (2016) statement:** The authors have read the CARE Checklist (2016), and the manuscript was prepared and revised according to the CARE Checklist (2016).

**Open-Access:** This article is an open-access article that was selected by an in-house editor and fully peer-reviewed by external reviewers. It is distributed in accordance with the Creative Commons Attribution NonCommercial (CC BY-NC 4.0) license, which permits others to distribute, remix, adapt, build upon this work non-commercially, and license their derivative works on different terms, provided the original work is properly cited and the use is non-commercial. See: <https://creativecommons.org/licenses/by-nc/4.0/>

**Country/Territory of origin:** South Korea

**ORCID number:** Moonhwan Kim 0000-0003-2772-0836; Hae Won Lee 0000-0002-3312-9295; Chang Jin Yoon 0000-0002-7660-0489; Boram Lee 0000-0003-1567-1774; Yeongsoo Jo 0000-0002-9385-3058; Jai Young Cho 0000-0002-1376-956X; Yoo-Seok Yoon 0000-0001-7621-8557; Jun Suh Lee 0000-0001-9487-9826; Ho-Seong Han 0000-0001-9659-1260.

**S-Editor:** Yan JP

**L-Editor:** A

**P-Editor:** Yan JP

## REFERENCES

- Oh CK, Pelletier SJ, Sawyer RG, Dacus AR, McCullough CS, Pruett TL, Sanfey HA. Uni- and multi-variate analysis of risk factors for early and late hepatic artery thrombosis after liver transplantation. *Transplantation* 2001; **71**: 767-772 [PMID: 11330540 DOI: 10.1097/00007890-200103270-00014]
- Silva MA, Jambulingam PS, Gunson BK, Mayer D, Buckels JA, Mirza DF, Bramhall SR. Hepatic artery thrombosis following orthotopic liver transplantation: a 10-year experience from a single centre in the United Kingdom. *Liver Transpl* 2006; **12**: 146-151 [PMID: 16382467 DOI: 10.1002/Lt.20566]
- Bekker J, Ploem S, de Jong KP. Early hepatic artery thrombosis after liver transplantation: a systematic review of the incidence, outcome and risk factors. *Am J Transplant* 2009; **9**: 746-757 [PMID: 19298450 DOI: 10.1111/j.1600-6143.2008.02541.x]
- Abbasoglu O, Levy MF, Vodapally MS, Goldstein RM, Husberg BS, Gonwa TA, Klintmalm GB. Hepatic artery stenosis after liver transplantation--incidence, presentation, treatment, and long term outcome. *Transplantation* 1997; **63**: 250-255 [PMID: 9020326 DOI: 10.1097/00007890-199701270-00013]
- Saad WE, Davies MG, Sahler L, Lee DE, Patel NC, Kitanosono T, Sasson T, Waldman DL. Hepatic artery stenosis in liver transplant recipients: primary treatment with percutaneous transluminal angioplasty. *J Vasc Interv Radiol* 2005; **16**: 795-805 [PMID: 15947043 DOI: 10.1097/01.RVI.0000156441.12230.13]
- Piardi T, Lhuire M, Bruno O, Memeo R, Pessaux P, Kianmanesh R, Sommacale D. Vascular complications following liver transplantation: A literature review of advances in 2015. *World J Hepatol* 2016; **8**: 36-57 [PMID: 26783420 DOI: 10.4254/wjh.v8.i1.36]
- Romner B, Reinstrup P. Triple H therapy after aneurysmal subarachnoid hemorrhage. A review. *Acta Neurochir Suppl* 2001; **77**: 237-241 [PMID: 11563296 DOI: 10.1007/978-3-7091-6232-3\_51]
- Lennihan L, Mayer SA, Fink ME, Beckford A, Paik MC, Zhang H, Wu YC, Klebanoff LM, Raps EC, Solomon RA. Effect of hypervolemic therapy on cerebral blood flow after subarachnoid hemorrhage : a randomized controlled trial. *Stroke* 2000; **31**: 383-391 [PMID: 10657410 DOI: 10.1161/01.str.31.2.383]
- Sinclair S, Levy G. Eicosanoids and the liver. *Ital J Gastroenterol* 1990; **22**: 205-213 [PMID: 2131947]
- Ogawa M, Mori T, Mori Y, Ueda S, Yoshida H, Kato I, Iesato K, Wakashin Y, Wakashin M, Okuda K. Inhibitory effects of prostaglandin E1 on T-cell mediated cytotoxicity against isolated mouse liver cells. *Gastroenterology* 1988; **94**: 1024-1030 [PMID: 3257931 DOI: 10.1016/0016-5085(88)90562-8]



Published by **Baishideng Publishing Group Inc**  
7041 Koll Center Parkway, Suite 160, Pleasanton, CA 94566, USA

**Telephone:** +1-925-3991568

**E-mail:** [bpgoffice@wjgnet.com](mailto:bpgoffice@wjgnet.com)

**Help Desk:** <https://www.f6publishing.com/helpdesk>

<https://www.wjgnet.com>

